

## Case report

## Subdeltoideus Bursitis Manifested as Gigantic Cystic Supraclavicular and Lateralcervical Tumour

A. DEMETRIAN<sup>(1)</sup>, R. MELINTE<sup>(2)</sup>, I. MÂNDRILĂ<sup>(1)</sup>, RODICA DILOF<sup>(1)</sup>

<sup>(1)</sup> Thoracic Surgery Department – Craiova Emergency County University Hospital; <sup>(2)</sup> Orthopedy Department - Craiova Emergency County University Hospital

**ABSTRACT** The authors present a case of a left gigantic supraclavicular and lateralcervical tumor with rapid growth, which has turned out to be a subdeltoideus bursitis.

**KEY WORDS** *subdeltoideus bursitis, cystic tumour, supraclavicular, synovial liquid*

### Case report

We present the case of a 79 years old patient, who was admitted to the hospital for the emergence within a relatively short interval (approximately two weeks) of a right supraclavicular pseudotumoral formation of large dimensions (12/10 cm), in the absence of any notion of trauma, intense effort, insect bite, surgical intervention or local diagnosing procedure (puncture).

The formation presents characters of liquid fluctuation, without signs of local inflammation, discretely painful at feeling and with minimum signs of compression at the level of the brachial plexus (pain and moderate paresthesia at the level of the upper right limb).

The movements in the right scapularhumeral joint, although possible and painless, proved to be limited by the volume of the formation.

The thorax examination highlighted a minimum diminishing of the vesicular murmur in the upper third of the right hemithorax, without clinical signs of pleuresis of the large right cavity.

During the commitment period, the formation's increase in volume continued, with a right lateralcervical evolution, maintaining the fluctuant character at feeling.

The cervical-thoracic computer-tomographic examination indicated the presence of a formation with cystic aspect, oval-like, well bordered, of 7.6/6.4 cm, situated supraclavicular right, located medial of the trapezius muscle, lateral of the scapula lifting muscle and the medial and posterior scalene muscles; the carotid artery and the jugular vein without visible modifications (fig. 1).

The imagistic data and the clinical aspect suggested the existence of a subdeltoideus bursitis.

We performed the formation draining puncture through a posterior percutaneous abord, with the draining of 400 ml serous citrin liquid and the subsequent total disappearance of the regional deformation.

The cytologic examination of the liquid extracted indicated an inflammatory aspect with rare cellular elements (lymphocytes, polymorphonuclear leucocytes, cropped out nuclei, red blood corpuscles and cellular detritus).

The evolution was favourable, with the total disappearance of the cystic formation and of the minimum symptomatology described previously.

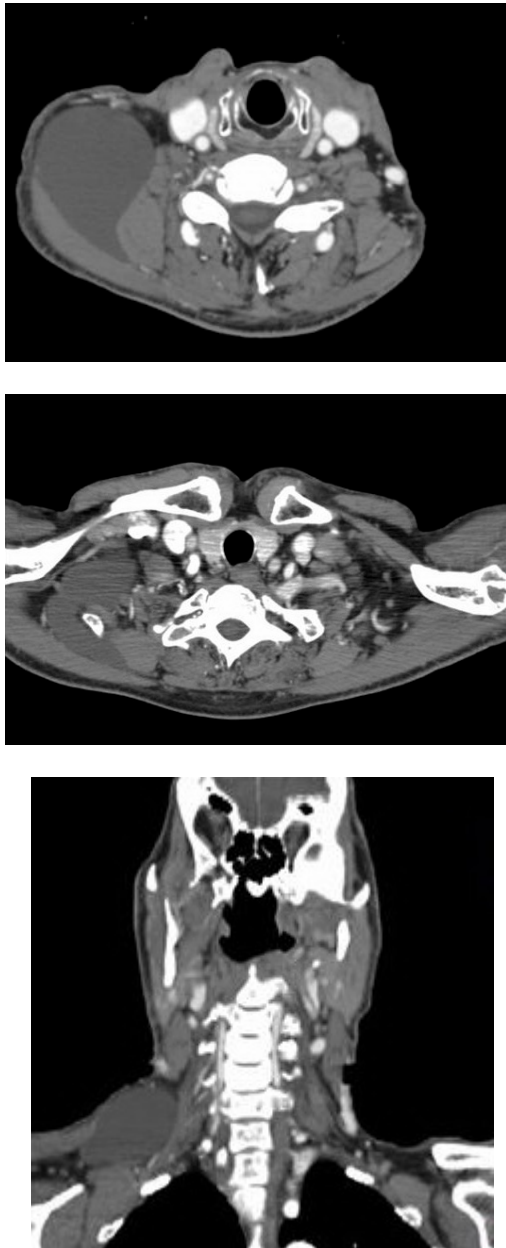
### Anatomy

The shoulder is not constituted solely of the glenohumeral joint, but from several joints that make up the shoulder's articular system. The number of joints is different, the authors including in this articular complex 7 (Cailliet R., 1984), 5 (Kapandji I. A., 1966) or 3 (Bonnell F., 1988) joints[1].

The variety of the complex movements performed in these joints is possible also due to the existence of the periarticular muscles and of the perihumeral synovial bursae.

The vast space occupied by the synovial cavities within the shoulder's articular system raises the issue of the *role of the synovia in the biomechanics of this system*, the synovia behaving as a *intermuscular liquid cushion* with role in

modulating the movements of the shoulder and arm [2].



**Fig. 1 Computer-tomograph images**

By means of a minute dissection in the deltopectoral space, with the clavicular desinsertion of the deltoid muscle and the removal towards the side of the obtained flap, it is possible to visualize the prominences of the upper humerus extremity: the small tuberculum and the large tuberculum, separated by a depression well visible due to the transparency of the conjunctive structures.

In the intertubercular space there is identified the tendon of the long biceps portion, with its synovial bursa homologated as "vagina synovialis intertubercularis". It is a synovial covering considered as an extension of the sinovia of the

glenohumeral joint which accompanies the bicipital tendon for 4-5 cm in the intertubercular channel.

Lateral and superior of the prominence determined by the large tuberculum of the humerus, it is located the synovial subdeltoideus bursa, which presents as a sliding space between the acromioclavicular arch and the deltoid muscle. After the opening of this bursa, the space under the acromioclavicular arch can be easily explored [3].

In a profound foreground there is the conjunctive acromioclavicular arch underneath which it is possible to enter the subacromial bursa interposed between the acromial arch and the acromioclavicular ligament. After the sectioning of this ligament in a sagittal plan, one can visualize the posterior extension of the subacromioclavicular space.

The scapulothoracic joint, also described by *Gill* and named by *Latarjet* "scapulothoracic junction" [4], is a physiological joint which has two sliding spaces: the omodentatus space and the parietodentatus space. These spaces are occupied by sinovial bursae: a superficial bursa, inconstant, present between the inferior angle of the scapula and the latissimus dorsi muscle; the scapulothoracic bursa, between the superior angle of the scapula and the trapezius muscle; two deep bursae, the scapulothoracic bursa bordered by the anterior dentatus muscle and the thoracic wall and the subscapular bursa between the anterior dentatus and the subscapular muscles [5].

## Discussions

The scapulothoracic bursitis can cause important pain and the limiting of movements in the scapular-humeral joint. The diagnosis is often one of exclusion, many times being made after a long period in which the symptoms persist or aggravate [6].

In our case, this interval was relatively short due to the impressive volume and the rapid growth pace which determined the patient to come to the physician.

The affection can be idiopathic (the case presented) or due to an abnormal mechanics between the scapula and the secondary ribs' grid, to a bone focal lesion (elastofibroma, osteochondroma) or to the altered morphology of the thoracic wall posttraumatic or postsurgery [7].

Sometimes, the existence of a bursitis can cause crepitations during movements.

The diagnostic arsenal comprises the echography, the computer-tomography and the nuclear magnetic resonance.

The medical treatment consists of non steroid anti-inflammatories and cyclooxygenase inhibitors. Sometimes, the local application of ice or heat can be benefic. Some rheumatologists practice locale injections with corticoids inside the bursa.

In our patient, we considered the liquid draining procedure more adequate than the treatment described above for two reasons: the total absence of the pain syndrome and the impressive dimension of the formation.

In case of relapse (important re-accumulation of liquid), we would have been forced to resort to the arthroscopic removal of the bursa walls.

### References

1. Bonnel F., Blotman F., Mansat M. – L'épaule . L'épaule degenerative, l'épaule traumatique, l'épaule du sportif. Diagnostique – Reeducation – Chirurgie – Arthroscopie. 1994. 3-65.
2. Melinte Rodica, Dragoi G.S., Melinte P. Razvan, Dogaru C. Raluca - A new Concept for describing the movements in the glenohumeral joint - The 13th European Conference of Biomechanics, September 2-4, 2002, Wroclaw, Poland. In: Acta of Bioengineering and Biomechanics, vol. 4, suppl. 1, 2002, pag. 626-627.
3. Drăgoi S. G., Rodica Melinte, Mândrilă I., Mihaela Niculescu, Melinte V. R. - Contribuții la studiul evaluării handicapului și prejudiciilor aduse structurilor sistemului articular al umărului. Implicații în expertiza clinică medico-legală, Revista Română de Medicină Legală, Volume 7, Number 3, September, 1999, pages 216-232.
4. Testut L, Latarjet A.,: Traite d'Anatomie humaine, huitieme edition, revue corrigees et augmentees par Latarjet, 1928.
5. Williams G.R., Shakil M., Klimkiewicz J., Iannotti J.P., Anatomy of the scapulothoracic articulation, Clin Orthop Relat Res., 1999 Feb;(359):237-46.
6. Saboeiro G. R., Carolyn M. Sofka, Imaging-Guided Treatment of Scapulothoracic Bursitis, HSS J. 2007 September; 3(2): 213–215.
7. Fujikawa A, Oshika Y, Tamura T, Naoi Y (2004) Chronic scapulothoracic bursitis associated with thoracoplasty. AJR Am J Roentgenol 183(5):1487–1488.

---

*Corresponding Adress: A. Demetrian, MD; Thoracic Surgery Department – Craiova Emergency County University Hospital*