



Case Report

Cervical spinal extradural arteriovenous fistula successfully treated using transarterial balloon-assisted coil embolization

Jung-Sik Park, Min-Yong Kwon, Chang-Young Lee

Department of Neurosurgery, Dongsan Medical Center, Keimyung University School of Medicine, Daegu, Korea

J Cerebrovasc Endovasc Neurosurg.
2020 September;22(3):182-189

Received: 27 April 2020

Revised: 5 August 2020

Accepted: 6 August 2020

Correspondence to Chang-Young Lee

Department of Neurosurgery, Keimyung
University Dongsan Medical Center,
1035 Dalgubeol-daero, Dalseo-gu,
Daegu 42601, Korea

Tel +82-53-258-7846

Fax +82-53-258-4388

E-mail nslyc@dsmc.or.kr

ORCID <http://orcid.org/0000-0001-6046-2571>

We present the case of a patient who developed compressive radiculopathy that was found to be associated with a spinal extradural arteriovenous fistula. The fistula was successfully obliterated with transarterial balloon-assisted coiling, after which the patient was symptom-free. Although spinal extradural arteriovenous fistula is rare, this pathology should be considered in the differential diagnosis of spinal radiculopathy or myelopathy. Endovascular treatment appears to have been successful in resolving the symptoms associated with this pathology.

Keywords Spinal extradural arteriovenous fistula, Vertebral arteriovenous fistula, Endovascular treatment, Transarterial embolization, Balloon-assisted coiling

INTRODUCTION

Spinal extradural arteriovenous fistula (SEDAVF) is defined as an abnormal direct connection between paraspinal or paravertebral arterial system and neighboring veins, particularly those of the extradural venous plexus, without any intervening vessels such as normal capillaries or dysplastic nidus.¹⁾⁶⁾¹¹⁾ It is known as an exceedingly rare disease that arises secondarily after iatrogenic or mechanical trauma and occurs spontaneously in connective tissue disease.¹²⁾

SEDAVF can cause compressive radiculopathy or myelopathy due to mechanical compression of root sleeve or thecal sac by dilated extradural venous plexus,¹⁴⁾²²⁾²⁷⁾ and congestive myelopathy due to increased medullary venous pressure by intradural retrograde blood reflux.¹³⁾¹⁷⁾ In addition, in the case of high-flow arteriovenous shunting in which arterial feeder occurs directly in vertebral artery (VA), there can be not only sensations of bruit or tinnitus,⁷⁾¹⁹⁾²⁰⁾²⁸⁾ but also cerebellar symptoms such as

This is an Open Access article distributed under the terms of the Creative Commons Attribution Non-Commercial License (<http://creativecommons.org/licenses/by-nc/3.0/>) which permits unrestricted noncommercial use, distribution, and reproduction in any medium, provided the original work is properly cited.

vertigo and ataxia caused by vascular steal effect.¹⁶⁾

Because of the complicated anatomical structures, uncommon nature and diverse clinical manifestations of SEDAVF, early diagnosis and proper treatment of the disease are not easy. The treatment goal in SEDAVF is to obliterate the vascular shunting point, blocking all anomalous pathways. In the present study, we report a rare case of cervical SEDAVF presenting compressive radiculopathy of right upper extremity and treated using transarterial balloon-assisted coil embolization.

CASE REPORT

A 77-year-old woman complained of radiating pain in right posterior neck and shoulder that had lasted a month, as well as intermittent tingling sensation from posterior neck to fingertips that had persisted for 2 weeks. The woman had no mechanical trauma history but had undergone internal jugular catheterization for mitral valve replacement operation 4 years ago. A local spine clinic made a provisional diagnosis of cervical spondylosis, and multiple osteophytes of cervical spine were observed in cervical spine computed tomography (CT) without contrast medium. The patient underwent a nerve block to relieve pain, and the pain was somewhat relieved. According to the doctor's advice, she took oral medication for pain relief and had enough rest for 2 weeks.

However, the patient visited the emergency medical center at our hospital immediately upon discovering subjective weakness of right shoulder abduction and elbow flexion. Upon physical examination, the patient showed a manual muscle testing (MMT) grade of 4 for both right shoulder abduction and elbow flexion, accompanied by hypoesthesia of light touch in the right C6 dermatome. The deep tendon reflex (DTR) of her right biceps and brachioradial muscle were reduced, but those of her right triceps muscle were normal, and no upper motor neuron sign was observed.

Cervical spine magnetic resonance imaging (MRI) without contrast medium showed no signs of high signal

intensity or swelling in the spinal cord, but axial T2-weighted images revealed multiple abnormal flow voids in the right intervertebral foramina at C1-2, C2-3, C3-4, C4-5, and C5-6. Subsequently, because we suspected that these lesions are due to the spinal vascular malformation, we performed MRI with contrast medium, which clearly showed irregular enhanced lesion at the same levels. However, there were no signs of spinal cord compression, intradural flow voids, or enhanced perimedullary vessels penetrating inside the thecal sac (Fig. 1). In maximum intensity projection reconstruction of neck carotid magnetic resonance angiography (MRA), an engorged paraspinal venous system was observed in most cervical spine. Using volume-rendered images of computed tomographic angiography (CTA), we found anomalous fistulous communication between the extraosseous VA and its adjacent vertebral vein, just before entry into the C6 transverse foramen (Fig. 2).

The patient was hospitalized to allow digital subtraction angiography (DSA), which provided a definitive diagnosis of spinal arteriovenous shunting. Meanwhile, her MMT grades for right shoulder abduction and elbow flexion had worsened to 2 and 3, respectively. The thyrocervical and costocervical trunks of the right subclavian artery were not involved in the pathological lesion, nor were any branches of the external carotid artery. Selective injection into the right VA revealed a high-flow fistula occurring directly at the C6-7 level and draining into the neighboring extradural venous plexus. Consequently, abnormal observations of the vertebral vein, intervertebral vein, and anterior internal vertebral venous plexus were made in the arterial phase (Fig. 3).

Based on cervical spine MRI, neck carotid CTA, and DSA, the patient was diagnosed with a high-flow cervical SEDAVF of the vertebro-vertebral subtype with a single orifice and without intradural perimedullary venous reflux, which appears to be caused iatrogenically by internal jugular catheterization. The patient's symptoms were manifestations of compressive radiculopathy caused by a dilated paraspinal venous system. We decided to obliterate this pathological lesion using endovascular treatment. To eliminate the fistula, we scheduled

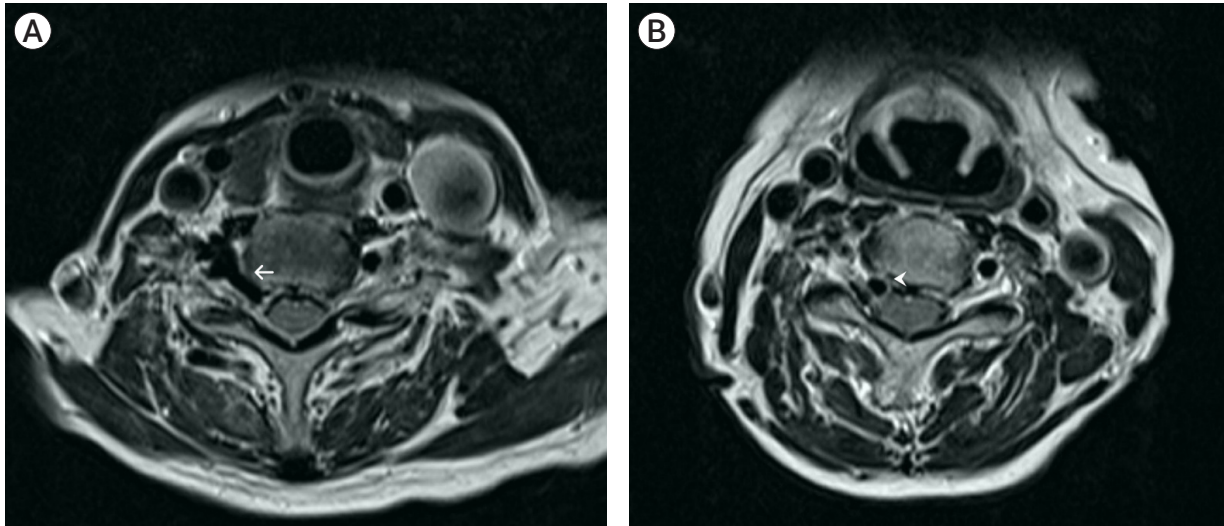


Fig. 1. Axial T2-weighted cervical spine magnetic resonance shows abnormal flow voids on the right C5-6 (A) and C4-5 (B) intervertebral foramina. Abnormally dilated right C5-6 intervertebral vein is seen entering the right ventral epidural space within the vertebral canal (arrow). The right anterior internal vertebral venous plexus compresses the nerve root passing the C4-5 intervertebral foramen (arrowhead). However, the image does not show any deviation due to spinal cord compression or high signal intensity in spinal cord.

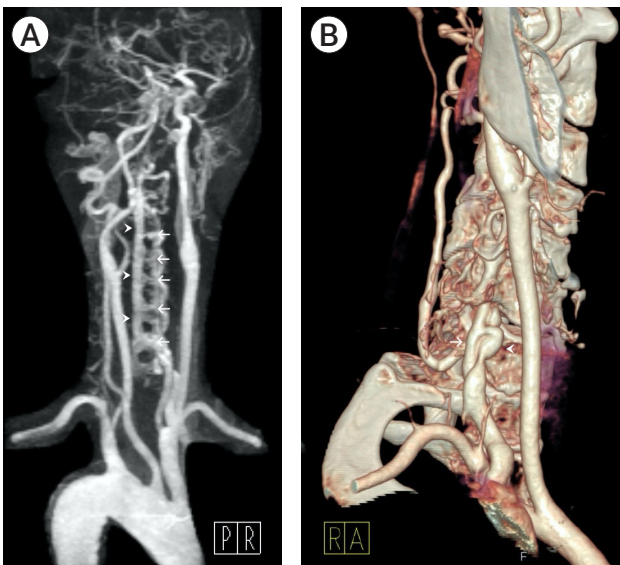


Fig. 2. (A) Maximum intensity projection reconstruction of neck carotid magnetic resonance angiography shows dilated intervertebral veins (arrows) and anterior internal vertebral venous plexus (arrowheads) in the cervical spine from C1 to C6. (B) Volume-rendered images of neck carotid computed tomographic angiography reveal a fistulous connection between the extraosseous right vertebral artery (arrow) and its adjacent vertebral vein (arrowhead) just before entry into C6 transverse foramen.

transarterial balloon-assisted coil embolization and administered 100 mg of aspirin and 75 mg of clopidogrel daily for 1 week before the operation.

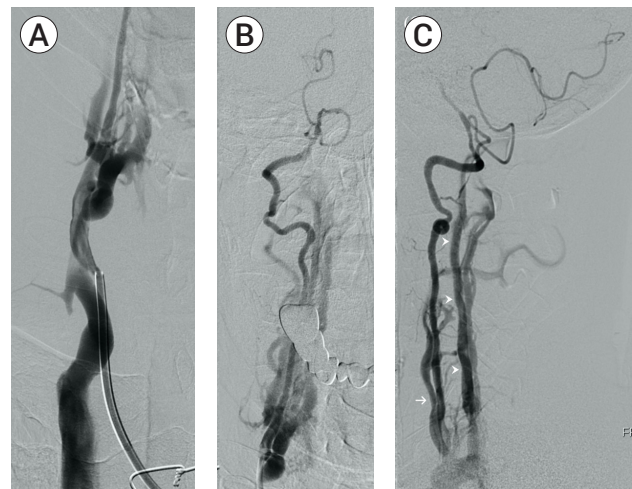


Fig. 3. Digital subtraction angiography of the right vertebral artery (VA). (A) The high-flow fistula occurring directly on the right VA at the C6-7 level flows backward to the adjacent extradural venous plexus. (B) Distal flow in the right VA is poor beyond the fistula in the anteroposterior view, but the right posterior inferior cerebellar artery is properly opacified. (C) Marked dilation of vertebral vein (arrow) and anterior internal vertebral venous plexus (arrowheads) is observed in the lateral view.

Under local anesthesia and systemic heparinization, a 5-Fr diagnostic catheter (Simmons®; Terumo, Tokyo, Japan) was inserted into the left femoral artery to confirm the flow of the left VA responsible for the blood supply of the posterior circulation. A 6-Fr guiding catheter

(Envoy[®]; Codman, MA, USA) was then inserted into the right femoral artery and guided to the right VA for fistula obliteration. Distal 1.7-Fr and proximal 2.4-Fr microcatheters (Headway 17[®]; Microvention, CA, USA), along with 0.014 inch microwire (Transend[®]; Stryker, MI, USA), were navigated to the right VA as close to the shunt point as possible through the right-side guiding catheter, and then entered into the oval venous pouch of the right vertebral vein. To prevent coil herniation, balloon inflation was performed in front of the fistula orifice during embolization using a 4×15 mm (diameter×length) occlusion balloon (Scepter C[®]; Microvention, CA, USA). Five varied sizes of detachable coils (10×34 mm [Presidio[®]; Codman, FL, USA], 6×10 mm, 5×20 mm, 4×10 mm [Axiom[®]; Medtronic, MN, USA], and 3×6 mm [Orbit Galaxy[®]; Codman, FL, USA]) were deployed into the venous pouch of the SEDAVF and repositioned carefully until a stable position was obtained. Blood flow to the fistula was significantly reduced by packing the coils and the arteriovenous connection of the right VA and vertebral vein was finally occluded (Fig. 4).

No new neurological complications occurred, and the

radiating pain in the woman's right posterior neck and shoulder dramatically improved, as did the tingling sensation in her right arm. Brain MRI showed no ischemic or hemorrhagic lesions. The patient was discharged with a prescription of 100 mg of aspirin daily. Since the procedure, the patient has continued to participate in clinical follow-ups through outpatient department. After 5 months, the patient's MMT grade for right shoulder abduction and elbow flexion improved significantly to 4, and her motor weakness and pain completely disappeared after 8 months, although she remained slight hypoesthesia in right wrist. Neck carotid CTA performed after 12 and 24 months showed no signs of fistula recurrence (Fig. 5).

DISCUSSION

Unlike spinal dural arteriovenous fistula (AVF), whose shunt point can be predicted relatively well and which has a higher prevalence among spinal vascular malformations, the concept and classification of SEDAVF

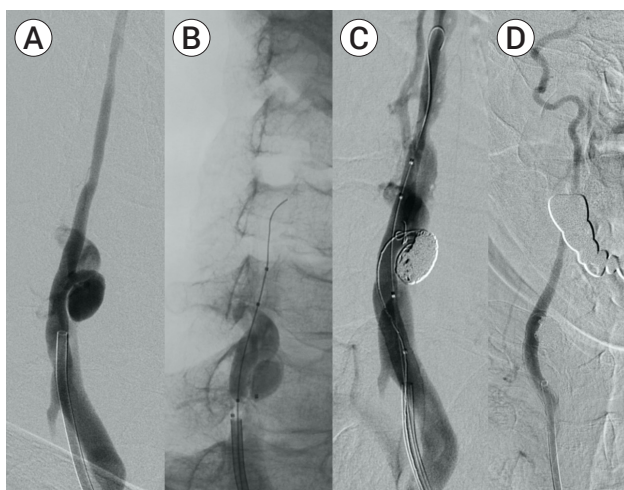


Fig. 4. (A) A 6-Fr guiding catheter inserted into the right femoral artery was delivered to the right vertebral artery to obliterate the fistula. (B) A 1.7-Fr microcatheter and 0.014 inch microwire were entered into the oval venous pouch of the right vertebral vein, and a 4×15 mm balloon inflation was performed in front of the fistula orifice during embolization. (C) As the five varied sizes of detachable coils were carefully deployed, blood flow to the fistula was gradually decreased. (D) Post-embolization angiography after balloon deflation showed total obliteration of the fistula.

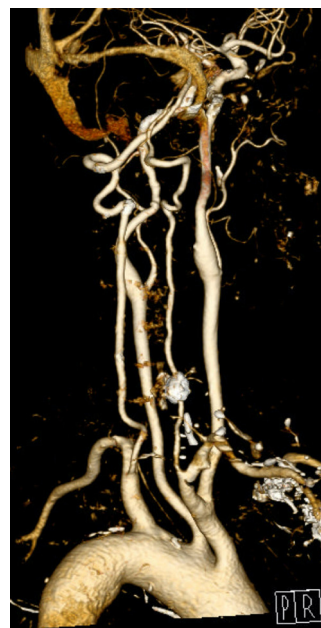


Fig. 5. Since the procedure, the patient has been in clinical follow-ups through outpatient department, and neck carotid computed tomographic angiography performed after 24 months showed no signs of fistula recurrence.

remains unclear as seen in mixed terminologies, such as paraspinous AVF, paravertebral AVF, vertebro-vertebral AVF, vertebro-jugular AVF, and intercostal AVF. SEDAVF is difficult to diagnose early because this clinical entity is too rare to be reported only in case reports or small case series, and it presents a wide range of clinical manifestations depending on the location of the fistula and on whether intradural drainage is present.²³⁾²⁴⁾ Unfortunately, in our case, it was regarded as a common cervical spondylosis in the elderly, so the low possibility of spinal vascular malformation was not predicted until motor weakness occurred. In addition, some reported cases involving venous hypertension in the spinal cord have led to irreversible results within a short period, with patients suffering permanent disability.⁵⁾⁹⁾¹³⁾¹⁷⁾¹⁸⁾ Thus, early detection and evaluation are the first key to achieving favorable outcome.

SEDAVF shows different neuropathological characteristics depending on whether there is intradural involvement.²³⁾²⁴⁾ SEDAVF with pure extradural drainage causes compressive radiculopathy or myelopathy due to mass effect by engorgement of extradural venous plexus.¹⁴⁾²²⁾²⁷⁾ The patient's right C5 and C6 radiculopathy was attributable to the dilation of the right intervertebral veins and anterior internal vertebral venous plexus. SEDAVF with intradural perimedullary venous drainage causes congestive myelopathy by prolonged chronic high pressure, and if left unrecognized, it can also trigger spinal cord infarction or hemorrhage,⁵⁾⁹⁾¹⁷⁾ and even subarachnoid hemorrhage at high cervical location.¹³⁾¹⁸⁾ High-flow SEDAVF with direct shunting of VA uniquely causes cerebellar symptoms by vertebrobasilar insufficiency as well as pulsatile bruit or tinnitus,⁷⁾¹⁶⁾¹⁹⁾²⁰⁾²⁸⁾ but our patient did not show such a distinctive symptom. Therefore, although SEDAVF is rare, this pathology should be considered in the differential diagnosis of spinal radiculopathy or myelopathy and other mentioned symptoms.

Endovascular treatment is currently the favored initial method of treatment in cases of SEDAVF due to its lesser invasiveness.¹⁾¹¹⁾²³⁾ Trying direct surgical manipulation on multiple arterial feeders, large venous pouch, high

flow fistula, or involvement at multiple spinal levels is a risk of massive bleeding. Various endovascular techniques and instruments used in cerebral vascular disease, are similarly used to successfully eliminate lesions. However, unlike the brain, there are some differences and limitations. Onyx is a liquid embolic agent that can safely permeates small, tortuous, and distal vessels, but liquid agents are inappropriate because they can trigger unintentional migration in high-flow SEDAVF with large-volume venous pouches, such as that seen in the present case. For this reason, it is limitedly used as a supplementary purpose for embolizing the remaining fistulas after coil packing.²¹⁾ A transvenous route through the dural sinus can be useful in the brain, but in the spine, it can be very restrictively considered only when the location of the fistula is accessible from vertebral vein or internal jugular vein.¹⁹⁾ Therefore, it is vital that clinicians plan appropriate treatments for which approach routes to access and which embolic materials to apply through a comprehensive understanding of the vascular structure of the arterial feeders, fistulas, and draining veins.

Complete obstruction of the parent artery where the fistula is located is probably the most effective method to block the shunt, but a few studies have reported vertebrobasilar ischemia or infarction when the VA is sacrificed.³⁾⁴⁾ This is likely to be more likely with dominant VA, but the risk for this has not been clearly identified, so some studies have attempted to block the lesions while preserving the parent artery (Table 1). In some limited cases with a single arterial feeder or a small fistula orifice, selective coil packing was possible only in the fistula.²⁾³⁾¹⁰⁾²⁵⁾ When embolization was not feasible with transarterial coiling alone, the balloon and covered stent were used as alternatives. The balloon assistance, as in our case, can be used to reduce the high-flow of fistula and prevent coil herniation or migration.¹⁹⁾ The sole use of detachable balloon was also reported,⁸⁾ but it has not been approved in our country. The covered stent can be used when the fistula has a large orifice or there is a risk of exacerbation of compressive symptoms resulting from coil embolization.⁷⁾¹⁵⁾²⁸⁾ However, it might be somewhat inappropriate in the tortuous upper segment of VA be-

Table 1. Summary of cases of cervical spinal extradural arteriovenous fistula attempting to block the shunt while preserving parent artery

Study	Age/Sex	Cause	Onset	Symptom	Location	Drainage	Neurologic finding	Approach	Treatment
Tenjin et al. (2005) ⁽²⁴⁾	72/F	Iatrogenic	4 yrs	Paresthesia, motor weakness	Rt. VA at C5 level	Epidural venous plexus	Spinal cord compression	Transarterial	Coiling
Brigantii et al. (2013) ⁽³⁾	56/F	Spontaneous	-	Bruit, radiating pain	Rt. VA at C3-4 level	Epidural venous plexus	Nerve root Compression	Transarterial	Coiling
Honarmand et al. (2013) ⁽¹⁰⁾	8/M	Congenital	-	Bruit	Rt. VA at C2 level	Paraspinal venous plexus, epidural venous plexus	Normal	Transarterial	Coiling
Walcott et al. (2013) ⁽²⁶⁾	69/M	Spontaneous	-	Loss of consciousness	Rt. VA at C2 level	Epidural venous plexus, suboccipital vein, clival venous plexus	SAH & IVH	Transarterial	Coiling & Onyx
Li et al. (2014) ⁽¹⁵⁾	40/F	Mechanical	2 mo	Bruit, pulsatile mass	Lt. VA at C5-6 level	Paravertebral venous plexus	Normal	Transarterial	Covered stent
Yeh et al. (2014) ⁽²⁸⁾	43/F	Mechanical	1 mo	Neck pain, tinnitus	Lt. VA at C3 level	Paraspinal venous plexus, epidural venous plexus	Normal	Transarterial	Covered stent
Ashour et al. (2015) ⁽²⁾	52/M	Mechanical	1 day	Neck pain, bruit	Lt. VA at C1-2 level	Paraspinal venous plexus	Normal	Transarterial	Covered stent (recurrent), coiling & NBCA (VA sacrifice)
Guneyli et al. (2016) ⁽⁸⁾	4/F	Congenital	-	Bruit	Rt. VA at C6-7 level	Epidural venous plexus	Normal	Transarterial	Coiling
Rajadurai et al. (2018) ⁽²⁰⁾	8/M	Congenital	-	Bruit	Rt. VA at C6-7 level	Epidural venous plexus	Normal	Transarterial	Coiling (Penumbra occlusion device)
Geng et al. (2019) ⁽⁷⁾	5/F	Congenital	-	Bruit	Rt. VA at C1 level	Paraspinal venous plexus	Normal	Transarterial	Detachable balloon
Ono et al. (2019) ⁽¹⁹⁾	54/M	Mechanical	1 mo	Tinnitus, bruit	Lt. VA at C1 level	Paraspinal venous plexus, epidural venous plexus, posterior fossa	Normal	Transarterial	Flow-diverting stent
Our case	46/M	Mechanical	2 mo	Tinnitus	Rt. VA at C1 level	Paraspinal venous plexus, epidural venous plexus	Normal	Transarterial	Covered stent
	32/M	Iatrogenic	8 days	Bruit	Rt. VA at C6-7 level	Epidural venous plexus	Normal	Transarterial & Transvenous	Balloon-assisted coiling
	77/F	Iatrogenic	4 yrs	Radiating pain, paresthesia, motor weakness	Rt. VA at C6-7 level	Epidural venous plexus	Nerve root compression	Transarterial	Balloon-assisted coiling

VA, vertebral artery; SAH, subarachnoid hemorrhage; IVH, intraventricular hemorrhage; NBCA, N-butyl cyanoacrylate

cause of the stiffness of covered stent and the risk of occlusion of small branch vessels. No best treatment guideline has yet been established so far, and further research such as systemic review and meta-analysis is required.

CONCLUSIONS

It should be recognized that the SEDAVF can be a causative disease in patients with spinal radiculopathy or myelopathy. It is also important to precisely diagnose using comprehensive radiologic imaging modalities. That is, prompt detection and evaluation, accurate diagnosis, and proper treatment can lead to a good clinical outcome despite the complexity and peculiarity of SEDAVF. Through the endovascular treatment with transarterial balloon-assisted coil embolization, we were able to obtain complete closure of SEDAVF with preservation of the parent artery by occluding only the venous pouch.

Disclosure

The authors report no conflict of interest concerning the materials or methods used in this study or the findings specified in this paper.

REFERENCES

1. Aljobeh A, Sorenson TJ, Bortolotti C, Cloft H, Lanzino G. Vertebral arteriovenous fistula: a review article. *World Neurosurg*. 2019 Feb;122:e1388-97.
2. Ashour R, Orbach DB. Lower vertebral-epidural spinal arteriovenous fistulas: a unique subtype of vertebrovertebral arteriovenous fistula, treatable with coil and Penumbra Occlusion Device embolization. *J Neurointerv Surg*. 2016 Jun;8(6):643-7.
3. Briganti F, Tedeschi E, Leone G, Marseglia M, Cicala D, Giandomo M, et al. Endovascular treatment of vertebro-vertebral arteriovenous fistula. A report of three cases and literature review. *Neuroradiol J*. 2013 Jun;26(3):339-46.
4. Briganti F, Tortora F, Elefante A, Volpe A, Bruno MC, Panagiotopoulos K. An unusual case of vertebral arteriovenous fistula treated with electrodetachable coil embolization. *Minim Invasive Neurosurg*. 2004 Dec;47(6):386-8.
5. Brinjikji W, Colombo E, Lanzino G. Clinical and angioarchitectural characteristics of spinal vascular malformations of the cervical spine. *J Neurosurg Spine*. 2020 Jan;1-8.
6. Brinjikji W, Yin R, Nasr DM, Lanzino G. Spinal epidural arteriovenous fistulas. *J Neurointerv Surg*. 2016 Dec;8(12):1305-10.
7. Geng J, Hu P, Ma Y, Zhang P, Zhang H. Endovascular treatment of V3 segment vertebro-vertebral arteriovenous fistula with Willis covered stent: Case report and literature review. *Interv Neuroradiol*. 2019 Feb;25(1):97-101.
8. Guneyli S, Cinar C, Bozkaya H, Korkmaz M, Oran I. Endovascular management of congenital arteriovenous fistulae in the neck. *Diagn Interv Imaging*. 2016 Sep;97(9):871-5.
9. Hiramatsu M, Sugiu K, Ishiguro T, Kiyosue H, Sato K, Takai K, et al. Angioarchitecture of arteriovenous fistulas at the craniocervical junction: a multicenter cohort study of 54 patients. *J Neurosurg*. 2018 Jun;128(6):1839-49.
10. Honarmand AR, Ansari SA, Alden TD, Soltanolkotabi M, Schoeneman SE, Hurley MC, et al. Endovascular management of pediatric high-flow vertebro-vertebral fistula with reversed basilar artery flow. A case report and review of the literature. *Interv Neuroradiol*. 2013 Jun;19(2):215-21.
11. Huang W, Gross BA, Du R. Spinal extradural arteriovenous fistulas: clinical article. *J Neurosurg Spine*. 2013 Nov;19(5):582-90.
12. Hughes DG, Alleyne CH Jr. Rare giant traumatic cervical arteriovenous fistula in neurofibromatosis type 1 patient. *BMJ Case Rep*. 2012 Jun;2012:bcr1220115354.
13. Inoue T, Endo T, Sato K, Fesli R, Ogawa Y, Fujimura M, et al. Massive intramedullary hemorrhage after subarachnoid hemorrhage in patient with vertebrovertebral arteriovenous fistula. *World Neurosurg*. 2019 Sep;129:432-6.
14. Kawabori M, Hida K, Yano S, Asano T, Iwasaki Y. Cervical epidural arteriovenous fistula with radiculopathy mimicking cervical spondylosis. *Neurol Med Chir (Tokyo)*. 2009 Mar;49(3):108-13.
15. Li F, Song X, Liu C, Liu B, Zheng Y. Endovascular stent-graft treatment for a traumatic vertebrovertebral arteriovenous fistula with pseudoaneurysm. *Ann Vasc Surg*. 2014 Feb;28(2):489.e11-4.
16. Miralbes S, Cattin F, Andrea I, Bonneville JF. Vertebral arteriovenous fistula: endovascular treatment with electrodetachable coils. *Neuroradiology*. 1998 Nov;40(11):761-2.
17. Miyamoto N, Naito I, Takatama S, Iwai T, Tomizawa S, Inoue HK. Spinal epidural arteriovenous fistulas with unusual manifestation of sudden onset of severe neurological deficits: case report. *Neurol Med Chir (Tokyo)*. 2013;53(12):896-901.

18. Nakagawa I, Park HS, Hironaka Y, Wada T, Kichikawa K, Nakase H. Cervical spinal epidural arteriovenous fistula with coexisting spinal anterior spinal artery aneurysm presenting as subarachnoid hemorrhage--case report. *J Stroke Cerebrovasc Dis.* 2014 Nov-Dec;23(10):e461-5.
19. Ono I, Satow T, Ito Y, Hamano E, Matsubara H, Kataoka H, et al. Case of iatrogenic vertebro-vertebral arteriovenous fistula treated by combination of double-catheter and balloon anchoring techniques. *World Neurosurg.* 2019 Aug;128:98-101.
20. Rajadurai S, Muthukumaraswamy S, Hussain Z. Endovascular treatment of vertebral-venous fistula with flow-diverting stent. *World Neurosurg.* 2019 Jan;121:33-6.
21. Rangel-Castilla L, Holman PJ, Krishna C, Trask TW, Klucznik RP, Diaz OM. Spinal extradural arteriovenous fistulas: a clinical and radiological description of different types and their novel treatment with Onyx. *J Neurosurg Spine.* 2011 Nov;15(5):541-9.
22. Shirakawa M, Nishioka T, Yamashita K, Maeda Y, Arita N. Traumatic vertebro-vertebral arteriovenous fistula manifesting as radiculopathy. Case report. *Neurol Med Chir (Tokyo).* 2008 Apr;48(4):167-70.
23. Takai K, Shojima M, Imai H, Saito N, Taniguchi M. Microsurgical and endovascular treatments of spinal extradural arteriovenous fistulas with or without intradural venous drainage. *World Neurosurg.* 2018 Mar;111:e819-29.
24. Takai K, Taniguchi M. Comparative analysis of spinal extradural arteriovenous fistulas with or without intradural venous drainage: a systematic literature review. *Neurosurg Focus.* 2012 May;32(5):E8.
25. Tenjin H, Kimura S, Sugawa N. Coil embolization of vertebro-vertebral arteriovenous fistula: a case report. *Surg Neurol.* 2005 Jan;63(1):80-3; discussion 83.
26. Walcott BP, Berkhemer OA, Leslie-Mazwi TM, Chandra RV, Ogilvy CS, Yoo AJ. Multimodal endovascular treatment of a vertebrovertebral fistula presenting with subarachnoid hemorrhage and hydrocephalus. *J Clin Neurosci.* 2013 Sep;20(9):1295-8.
27. Wang Q, Song D, Chen G. Endovascular treatment of high-flow cervical direct vertebro-vertebral arteriovenous fistula with detachable coils and Onyx liquid embolic agent. *Acta Neurochir (Wien).* 2011 Feb;153(2):347-52.
28. Yeh CH, Chen YL, Wu YM, Huang YC, Wong HF. Anatomically based approach for endovascular treatment of vertebro-vertebral arteriovenous fistula. *Interv Neuroradiol.* 2014 Dec;20(6):766-73.