



A rare case of mosaic 45,X/47,XX,+13 in 28-year-old women with secondary amenorrhoea: A case report and literature review



Mohit Kumar^{a,b}, Vandana Lal^a, Shilpa Chapadgaonkar^b,
Saurabh Kumar Bhattacharya^{a,*}

^a Dr. Lal Path Labs Pvt. Ltd., National Research Laboratory, Block E, Sector 18, Rohini, New Delhi 110085, India

^b Department of Biotechnology, Manav Rachna International University, Faridabad, Haryana, India

ARTICLE INFO

Article history:

Received 12 May 2014

19 July 2014

Accepted 26 November 2014

Available online 12 December 2014

Keywords:

Trisomy 13

Turner syndrome

FISH

Karyotype analysis

ABSTRACT

In the present paper we report an extremely rare case of mosaicism of 45,X/47,XX,+13 in a 28-year-old women. The patient was referred for cytogenetic evaluation for secondary amenorrhoea. The patient was found to have some mild characteristic features of Turner syndrome such as wide carrying angle and short stature. Ultrasound examination revealed the presence of a small sized uterus and bilateral streak ovaries. G-banded chromosome analysis revealed a mosaic female karyotype involving two different cell lines. One cell line (72% of analysed metaphases) presented monosomy of X while the remaining 28% of cells showed trisomy of chromosome 13. Fluorescence in situ hybridization (FISH) with locus specific probe for trisomy 13 and CEP X for monosomy X substantiated the results obtained from karyotyping.

© 2014 The Authors. Published by Elsevier B.V. This is an open access article under the CC BY-NC-ND license

(<http://creativecommons.org/licenses/by-nc-nd/3.0/>).

Introduction

Trisomy 13 represents the third most prevalent autosomal aneuploidy affecting about 1:12,000 to 1:29,000 children at birth (Carey, 2010). Trisomy 13 also known as Patau syndrome is characterised by visible abnormalities such as cleft palate, microphthalmia and polydactyly (Patau et al., 1960), also owing to abnormalities involving almost all of the organ systems. Patients with trisomy 13 do not survive beyond one-year. Till date, there are only six reported cases of patients with Patau syndrome who have survived beyond 10 years of age (Iliopoulos et al., 2006; Reardon et al., 1981; Redheendran et al., 1981; Singh, 1990; Tunca et al., 2001; Zoll et al., 1993). Here we report a patient with Patau syndrome who has survived unusually

* Corresponding author at: Cytogenetics Department, Dr. Lal Path Labs Pvt. Ltd., National Research Laboratory, Block E, Sector-19, Rohini, New Delhi, India. Tel.: +91 11 30244157.

E-mail address: saurabh.bhattacharya@lalpathlabs.com (S.K. Bhattacharya).

for more than 28 years of age from western India. This patient is a mosaic having karyotype 45,X[36]/47,XX,+13[14], which is extremely rare.

Materials and methods

Case report

The patient is a 28-year-old women who had been referred to our unit for karyotype analysis. On physical examination, it was observed that, she had a short stature (143 cm), short neck, wide carrying angle, poorly formed vagina and poorly developed secondary sexual characteristics. Ultrasonography findings revealed a small uterus with thin endometrium and bilateral streak ovaries. The biochemical analysis for gonadotropic hormones such as FSH, LH and TSH was performed. The levels of FSH, LH and TSH were found to be 103.54, 40.25 and 6.69 mIU/mL respectively. All the hormonal levels were found to be elevated from the normal range. The patient was given a diagnosis of secondary amenorrhoea with secondary ovarian failure.

Conventional cytogenetic analysis

Routine cytogenetic analysis was performed with 3 mL heparinized peripheral blood using method described earlier (Bhattacharya et al., 2013). At least 20 metaphases were observed and analysed through GTG banding with over 550 band resolutions observed. Karyotype was designated as per ISCN (Shaffer et al., 2013).

Molecular cytogenetic analysis

FISH analysis was performed with AneuVysion assay kit (Abbott-Vysis, USA). The protocol involved direct culture of cells obtained from the blood sample. At least 500 interphase cells were analysed and signals were counted accordingly. Images were recorded using Olympus fluorescence microscope equipped with a CCD camera and analysed using Cytovision 3.9 V software.

Results

Cytogenetics

The analysis of 50 metaphases shows the presence of two different cell lines. About 72% of the cells showed monosomy of chromosome X (45,X) while 28% of cells presented trisomy of chromosome 13 (47,XX) karyotype. The final karyotype was identified as 45,X[36]/47,XX,+13[14] (Fig. 1).

Molecular cytogenetics

FISH analysis was carried out on Interphase cells using LSI 13 probe for chromosome 13 and CEP X probe for X chromosome. The result of FISH analysis is shown in Fig. 2. Three green signals given by LSI 13 probe confirm the presence of trisomy 13 and CEP X probe shows only one green signal pertaining to monosomy X.

Discussion

Trisomy 13 (Patau syndrome) constitutes approximately 5% of all trisomies. Phenotype of real trisomy 13 is very broad; it is usually characterised by congenital anomalies and mild-to-severe intellectual disabilities. A person with trisomy 13 has rarely been found to have normal intelligence. Usually, detection of trisomy 13 in prenatal diagnosis creates a difficult genetic counselling situation. Trisomy 13 cells are believed to be confined to placental cells; however, foetal mosaicism is also possible. Even low-level mosaicism of trisomy 13 cannot be excluded. Trisomy 13 cells can possibly be found in the gonadal cells of an individual. Those individuals who have undergone a prenatal diagnosis for presence of mosaic trisomy 13 with normal chromosomes in peripheral blood should be offered prenatal diagnosis, given the possibility that very low-level mosaicism may

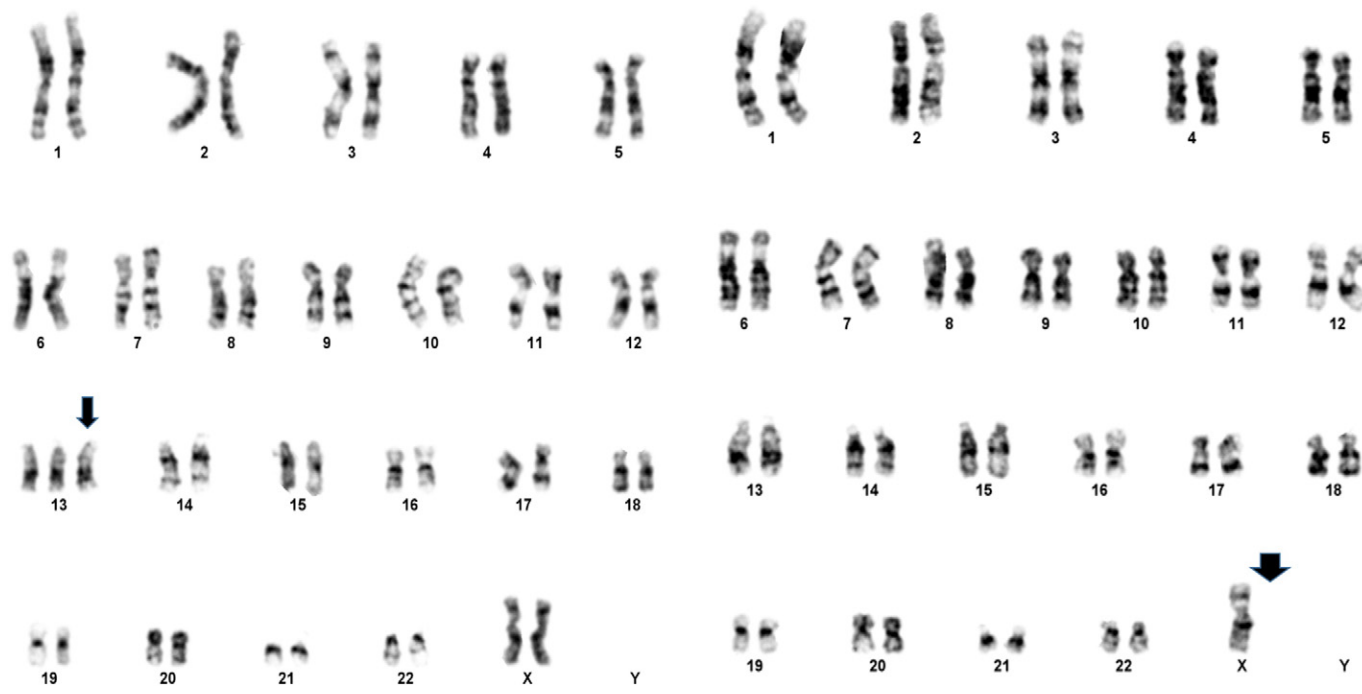


Fig. 1. G-banding karyotype aberrant blood cells of the patient showing trisomy 13 and monosomy X with an arrow.

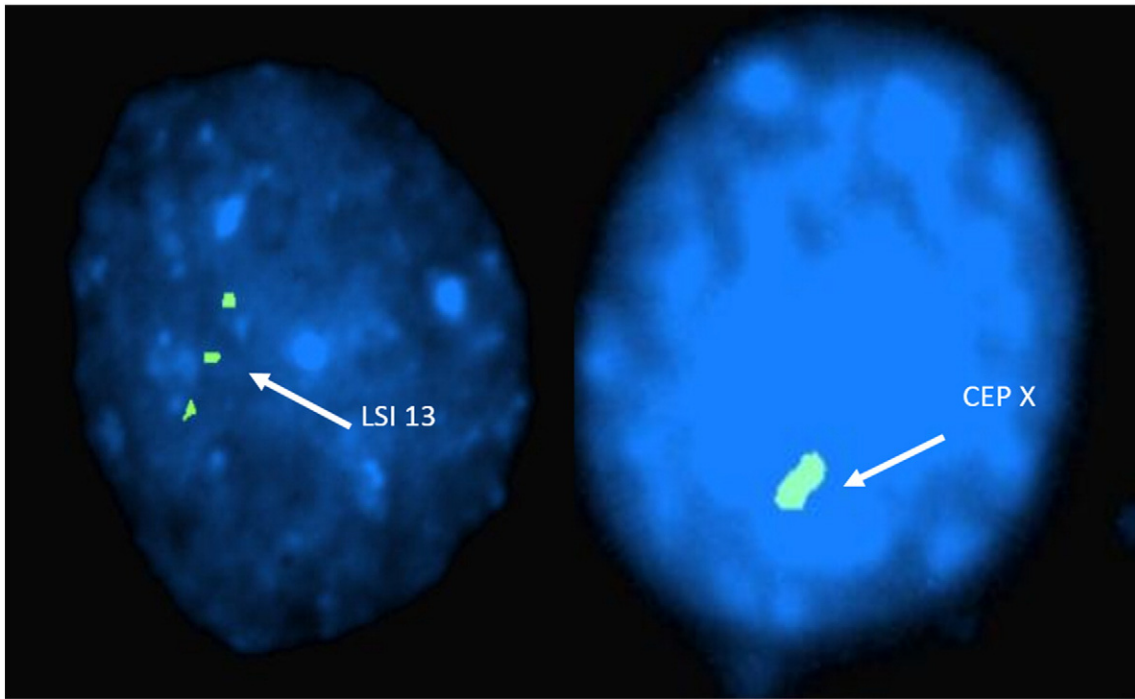


Fig. 2. Interphases FISH result of the patient using LSI 13 and CEP X probe shows two cells, three green signals of LSI 13 probe indicates trisomy 13 and presence of one green signal of CEP X indicates monosomy X.

Table 1

Literature review of the cases with mosaic trisomy 13 and monosomy X.

Case no.	Age	Sex	Percentage of trisomic cells	Specific clinical features	Growth parameters	Mental development	References
1.	19 years	F	Lymphocytes – 82% Skin – 24%	Primary amenorrhoea, secondary sexual characteristics absent, broad forehead, prominent chin, short neck, cubitus valgus	Short stature (148 cm)	Moderate intellectual disability	Prieur et al., 1976
2.	18 years	F	Lymphocytes – 100%	Mammary gland absent, sparse pubic and axillary hairs	Short stature (145 cm)	Normal	Eiben et al., 1989
3.	8.5 years	F	Lymphocytes – 35%	All the features of Turner syndrome, bicornate uterus, prominent ears, Crohn's disease	Poor growth	Normal	Knudtson et al., 1988
4.	3 years	F	Lymphocytes – 82%	Short neck, hypertelorism, facial dysmorphisms, ASD, SNHL	Below 5th centile	Poor development	Tang et al., 2014
5.	28 years	F	Lymphocytes – 28%	Short stature, short neck, wide carrying angle, poorly formed vagina, small sized uterus and secondary amenorrhoea	Short stature (143 cm)	Normal	Present case

ASD – Atrial septal defect, SNHL – Sensorineural hearing loss.

include the gonads. Mosaicism has three possible mechanisms. The first mechanism is the fertilisation between normal gamete and abnormal trisomic gamete, resulting in the trisomic zygote (47,XX,+13). This could lead to subsequent non-disjunction in meiosis I or II, resulting in double aneuploidy as seen in our case. The second mechanism is the fertilization of two gametes, one with an extra chromosome and another with monosomy, that can produce double aneuploidy zygote (47,XX,+13 and 45,X). The third possibility is anaphase lag, which can lead to double aneuploidy.

One of the possible theories proposed for formation of trisomy 13 is that zygote possessed +13 but it was lost during early postzygotic division (Tang et al., 2014). To the best of our knowledge there are only four previous reports describing mosaicism of trisomy 13 with monosomy X (Table 1). A case presented by Prieur et al., 1976 shows 45,X/47,XX,+13 mosaicism in a 19-year-old patient with low intellectual disability, features of Turner syndrome with primary amenorrhoea (Prieur et al., 1976). Eiben et al. (1989) described a case where the patient was an 18-year-old with trisomy 13 in all the lymphocytes studied and monosomy X in all other tissues (Eiben et al., 1989). Third case was an 8.5-year-old with a complaint of webbed neck, prominent ears, widely spaced nipples and all other features of Turner syndrome but no symptoms of Patau syndrome at all. The girl was suffering from Crohn's disease which is somewhat associated with Turner syndrome (Knudtson et al., 1988). Recently Tang et al., 2014 reported a case of 3-year-old female with very short height and weight below 5th centile. She had global developmental delay with poor mental development. 85% of lymphocytes were found to have trisomy 13 (Tang et al., 2014).

Poor growth or pubertal delay are highly characteristic, but majority of the girls with Turner syndrome do not have all of the spectrum of features like the short stature, streak ovary and lack of puberty, primary amenorrhoea and normal intelligence. Features are less severe in the case of mosaicism (Savendahl and Davenport, 2000). This phenomenon can be observed in the present case, where some of the typical features of Turner syndrome were present such as short stature, secondary amenorrhoea etc. The levels of FSH, LH and TSH were found to be elevated which is indicative of gonadal failure. In the present case the typical features of Patau syndrome were not presented. Therefore it can be said that each case of such mosaicism is unique and has to be studied individually. To the best of our knowledge, only four reports are available in literature for trisomy 13 and monosomy X.

References

- Bhattacharya, S.K., Nathawat, L.S., Damani, P., Choksi, A.K., Banik, A., Sinha, K., Bhattacharya, A.S., 2013. Assessment of potential in vitro genotoxic and cytotoxic effects of bupropion hydrochloride (Wellbutrin) in human peripheral lymphocytes and human cortical neuron. *Toxicol. Int.* 20, 11–18.

- Carey, J.C., 2010. Trisomy 18 and trisomy 13 syndromes. In: Cassidy, S.B., Allanson, J.E. (Eds.), *Management of genetic syndromes*. John Wiley & Sons, New York, pp. 807–823.
- Eiben, B., Hansen, S., Goebel, R., Hammans, W., 1989. Tissue-specific 45, X0/47, XY,+13 mosaicism in an 18-year-old woman. *Hum. Genet.* 82, 391–392.
- Iliopoulos, D., Sekerli, E., Vassiliou, G., Sidiropoulou, V., Topalidis, A., Dimopoulou, D., Voyiatzis, N., 2006. Patau syndrome with a long survival (146 months): a clinical report and review of literature. *Am. J. Med. Genet. A* 140, 92–93.
- Knudtzon, J., Ledaal, P., Middelthon-Moe, M., Aarskog, D., 1988. 45, X/47, XY,+13 mosaicism and Crohn's disease. *Acta Paediatr. Scand.* 77, 922–924.
- Patau, K., Smith, D.W., Therman, E., Inhorn, S.L., Wagner, H.P., 1960. Multiple congenital anomaly caused by an extra autosome. *Lancet* 1, 790–793.
- Prieur, M., Dutrillaux, B., Lafourcade, J., Roy, C., Lejeune, J., 1976. 45, X/47, XY, +13 mosaicism in a 19-year-old girl. *Ann. Genet.* 19, 199–202.
- Rearson, P.C., Greenstein, R.M., Howard, R.O., Gianacopolos, E.K., Breg, W.R., 1981. Unusual mosaicism of de novo structural abnormalities and ocular anomalies in a male with 13 trisomy syndrome. *Am. J. Med. Genet.* 10, 113–118.
- Redheendran, R., Neu, R.L., Bannerman, R.M., 1981. Long survival in trisomy-13-syndrome: 21 cases including prolonged survival in two patients 11 and 19 years old. *Am. J. Med. Genet.* 8, 167–172.
- Savendahl, L., Davenport, M.L., 2000. Delayed diagnoses of Turner's syndrome: proposed guidelines for change. *J. Pediatr.* 137, 455–459.
- Shaffer, L.G., McGowan-Jordan, J., Schmid, M., 2013. *ISCN (2013): An International System for Human Cytogenetic Nomenclature*. S. Karger, Basel.
- Singh, K.S., 1990. Trisomy 13 (Patau's syndrome): a rare case of survival into adulthood. *J. Ment. Defic. Res.* 34 (Pt 1), 91–93.
- Tang, H.W., Liao, S.F., Li, J.S., 2014. Development of patients with 47, XX,+13/45, X mosaics: case report and review of the literature. *Eur. J. Pediatr.* 173, 251–255.
- Tunca, Y., Kadandale, J.S., Pivnick, E.K., 2001. Long-term survival in Patau syndrome. *Clin. Dysmorphol.* 10, 149–150.
- Zoll, B., Wolf, J., Lensing-Hebben, D., Pruggmayer, M., Thorpe, B., 1993. Trisomy 13 (Patau syndrome) with an 11-year survival. *Clin. Genet.* 43, 46–50.