

MINI-FOCUS ISSUE: CORONARIES

INTERMEDIATE

CASE REPORT: CLINICAL CASE

Navigation of a Dormant AV Fistula for PCI in a Patient With High-Risk NSTEMI



Kevin A. Friede, MD,^{a,b} Zachary K. Wegermann, MD,^{a,b,c} Sunil V. Rao, MD^{b,c}

ABSTRACT

Arteriovenous (AV) fistulae for hemodialysis in patients with end-stage renal disease usually prevents ipsilateral transradial access (TRA) for coronary angiography. We present a case of coronary angiography and percutaneous coronary intervention via left TRA with navigation through a dormant AV fistula in a patient with limited vascular access. (**Level of Difficulty: Intermediate.**) (J Am Coll Cardiol Case Rep 2020;2:1671-4) © 2020 The Authors. Published by Elsevier on behalf of the American College of Cardiology Foundation. This is an open access article under the CC BY-NC-ND license (<http://creativecommons.org/licenses/by-nc-nd/4.0/>).

A 61-year-old male patient presented to the emergency department with acute dyspnea and productive cough. He was initially admitted to the hospital ward and treated presumptively for health care-associated pneumonia based on chest x-ray opacities and an elevated procalcitonin level. On hospital day 1 he had an acute change in status with a decrease in his blood pressure to 80s/40s mm Hg.

PAST MEDICAL HISTORY

Past medical history included end-stage renal disease (ESRD) on hemodialysis, peripheral artery disease (PAD) with prior right above-the-knee and left below-the-knee amputations, and type 2 diabetes mellitus. The patient had previously undergone creation of an AV fistula in the left forearm. Unfortunately, this fistula failed and the patient required placement of a tunneled right internal jugular vein hemodialysis catheter.

LEARNING OBJECTIVES

- To present the technical aspects of a challenging case involving the navigation of a dormant AV fistula, from peripheral arterial access through a venous segment and back to artery, for successful coronary angiography and LAD PCI in a patient with high-risk NSTEMI and cardiogenic shock.
- To discuss the limited evidence regarding the navigation of AV fistulae for interventional procedures and review the indications and pros and cons of such an approach.

DIFFERENTIAL DIAGNOSIS

The differential diagnosis included severe sepsis due to pneumonia, acute coronary syndrome complicated by cardiogenic shock, and acute pulmonary embolism.

INVESTIGATIONS

An electrocardiogram was obtained that showed new lateral T-wave inversions and his cardiac biomarkers were elevated, diagnostic for a non-ST-segment

From the ^aDivision of Cardiology, Duke University, Durham, North Carolina; ^bDivision of Cardiology, Durham VA Medical Center, Durham, North Carolina; and the ^cDuke Clinical Research Institute, Durham, North Carolina. The authors have reported that they have no relationships relevant to the contents of this paper to disclose.

The authors attest they are in compliance with human studies committees and animal welfare regulations of the authors' institutions and Food and Drug Administration guidelines, including patient consent where appropriate. For more information, visit the *JACC: Case Reports* [author instructions page](#).

Manuscript received January 27, 2020; revised manuscript received April 28, 2020, accepted May 12, 2020.

ABBREVIATIONS AND ACRONYMS

- AV** = arteriovenous
- BAT** = balloon-assisted tracking
- CICU** = cardiac intensive care unit
- ESRD** = end-stage renal disease
- LAD** = left anterior descending coronary artery
- NSTEMI** = non-ST-segment elevation myocardial infarction
- PAD** = peripheral artery disease
- PCI** = percutaneous coronary intervention
- TRA** = transradial access

elevation myocardial infarction (NSTEMI). He was admitted to the cardiac intensive care unit (CICU) and required norepinephrine to maintain a mean arterial pressure >65 mm Hg. A right radial arterial line was placed for monitoring. Transthoracic echocardiography showed an ejection fraction of 40% (previously normal) with anterior, septal, and apical wall motion abnormalities.

On examination, the patient's bilateral femoral arterial pulses were absent. The right radial site was used for an arterial line. He had a normal left radial and bounding left brachial pulse. Review of prior computed tomography angiography showed high-grade stenoses of the bilateral common iliac arteries that were felt to be likely to prevent crossing with a wire or catheter. Given

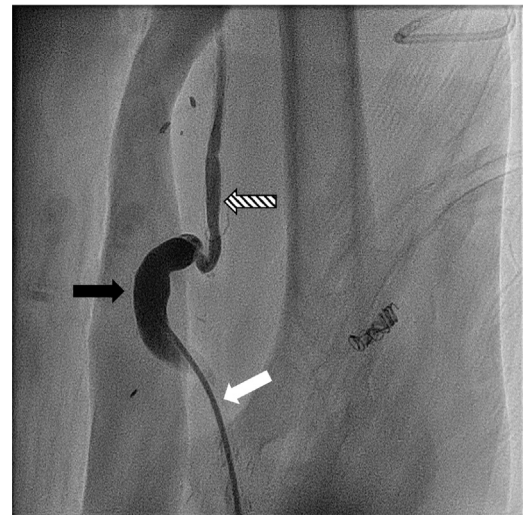
concern regarding the feasibility of femoral access due to severe PAD and the need for continued hemodynamic monitoring via the right radial artery, the decision was made to pursue coronary angiography via left radial arterial access through the dormant AV fistula.

MANAGEMENT

The left radial artery was accessed using the counterpuncture approach. A 6-F Glidesheath slender (Terumo Interventional Systems, Somerset, New Jersey) could not be fully advanced into the radial artery due to extensive calcification but was able to be seated well enough to provide adequate wire and catheter support. A 5-F JR 4 diagnostic catheter was introduced over a Baby-J guidewire into the forearm and advanced to the level of the fistula. Significant tortuosity in the AV fistula prevented further advancement. A radial arteriogram demonstrated occlusion of the distal brachial artery with a patulous vein segment connecting the proximal radial artery with the brachial artery (Figure 1). After unsuccessful attempts to navigate this segment with a 0.035-inch Wholey wire and an angled 0.035-inch Glidewire, the venous segment was crossed with a 0.014-inch Runthrough coronary wire (Terumo Interventional Systems) (Figure 2), and the diagnostic catheters were advanced through the dormant fistula to the level of the coronary sinus. Coronary angiography demonstrated a heavily calcified 99% lesion in the left anterior descending (LAD) and first diagonal coronary arteries and the decision was made to perform PCI (Figure 3A).

Exchange for a 6-F EBU 4 guide catheter (Medtronic, Minneapolis, Minnesota) over an

FIGURE 1 Radial Arteriogram of Arteriovenous Fistula



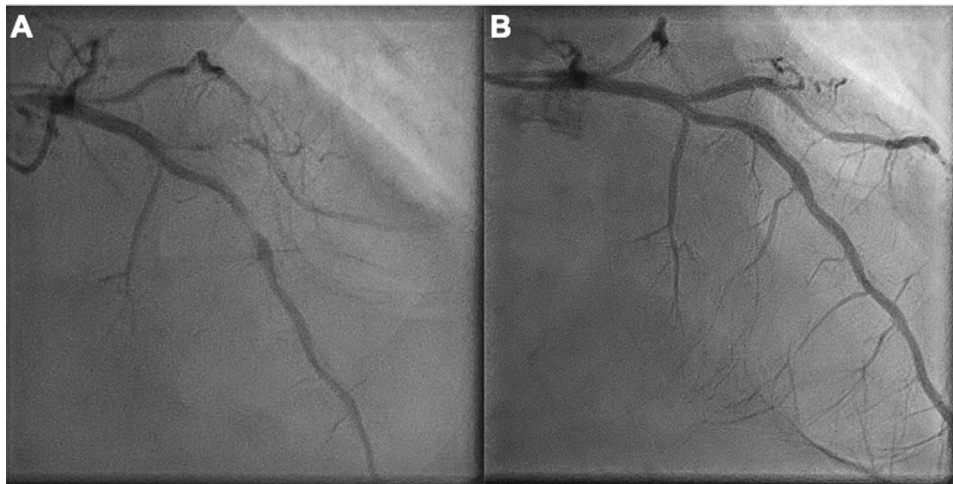
Radial arteriogram showing the arteriovenous fistula with venous connection (**black arrow**) between the proximal radial and proximal brachial (**striped arrow**) arteries. The distal brachial artery is occluded. (**white arrow**, with catheter in situ)

exchange-length 0.035-inch J wire failed due to redundancies in the venous segment of the AV fistula preventing catheter advancement. The 0.035-inch guidewire was exchanged for the 0.014-inch coronary wire; advancement of the guide catheter using the balloon-assisted tracking (BAT) technique (1) with

FIGURE 2 Navigation of the Arteriovenous Fistula Using a Coronary Wire

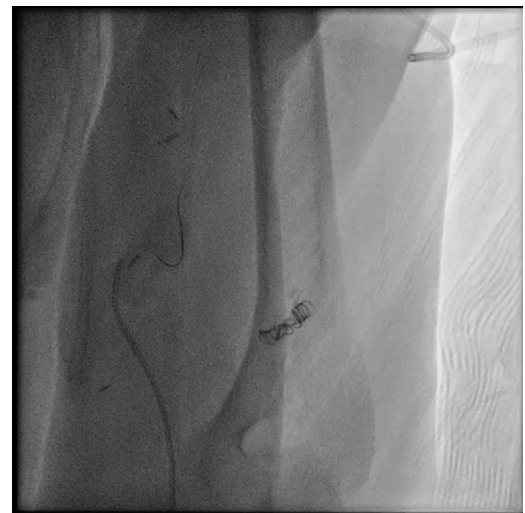

FIGURE 3 Left Coronary Angiography Before and After Left Anterior Descending Percutaneous Coronary Intervention



Left anterior descending and diagonal coronary artery lesions in the right anterior oblique cranial view seen before (A) and after (B) percutaneous coronary intervention.

a 2.0 × 20-mm Euphora balloon (Medtronic) was attempted but initially failed due to inability to cross the fistula due to guidewire kinking within the venous segment. Attempts to advance the guide catheter over a 0.038-inch Amplatz Super Stiff guidewire (Boston Scientific, Marlborough, Massachusetts) also failed. The guide catheter was downsized to a 5-F EBU 4 (Medtronic); again using BAT, which was able to pass with some difficulty through the AV fistula (Figure 4).

PCI was then successfully performed for the LAD lesion using predilatation with sequential 1.0 × 15-mm, 2.0 × 15-mm, and 2.5 × 15-mm Sapphire balloons (Cardiovascular Systems, St. Paul, MN) and then a 3.0 × 12-mm Resolute Onyx drug-eluting stent (Medtronic), which was postdilated using a 3.0 × 12-mm Sapphire balloon. PCI of the diagonal lesion was accomplished using 1.0 × 15-mm Sapphire and 2.0 × 20-mm Euphora balloons and then a 2.25 × 22-mm Resolute Onyx stent (Figure 3B).

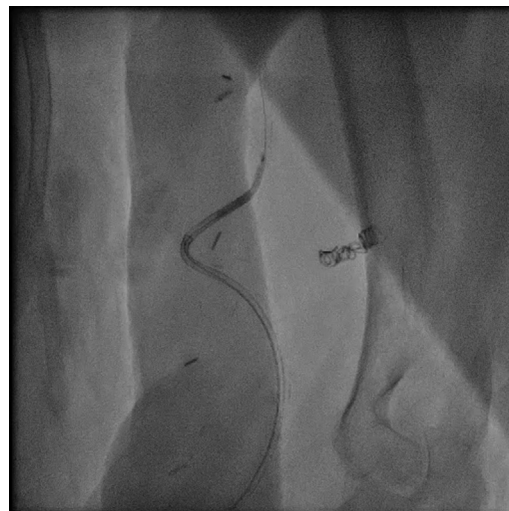DISCUSSION

We have described a complex case of diagnostic coronary angiography and PCI via a left radial artery approach requiring navigation through a dormant dialysis AV fistula in a NSTEMI patient with limited arterial access options. Significant tortuosity and redundancy were encountered that posed challenges to the standard techniques for catheter advancement. In this case, the combination of 2

techniques—downsizing of the guide catheter to a 5-French system and BAT—was critical for successful navigation of the AV fistula and ultimately, PCI.

Transradial access (TRA) for coronary angiography and PCI has become the preferred approach for many operators worldwide. TRA is considered the standard of care in the management of acute coronary syndromes in Europe (2) and a recent scientific statement published by the American Heart Association

FIGURE 4 Balloon-Assisted Tracking Was Used to Navigate the 5-F Guide Catheter Through the Arteriovenous Fistula



recommends the adoption of a “radial first” approach for PCI in the United States, based on evidence that this approach is associated with lower rates of bleeding and vascular complications compared with transfemoral access (3).

While the prevalence of ESRD has been stable since approximately 2,000 in the United States (4), there has been a trend toward increased use of the upper arm (rather than lower arm) as the location for AV fistula creation. This has raised concerns that patients, especially younger ones, may exhaust all available potential vascular access sites for hemodialysis access (5). Several studies have examined the reluctance of PCI operators to choose TRA in patients with ESRD due to concerns about radial artery occlusion (6,7). Meanwhile, patients with chronic kidney disease are at increased for coronary artery disease, PAD, and bleeding, with a predicted mortality rate of approximately 40% at 2 years for patients with ESRD after acute myocardial infarction (8). Clearly, vascular access can be very challenging in this patient population and radial access has the potential to significantly reduce bleeding and potentially mortality, especially in the setting of acute coronary syndromes (9). In the case presented, the patient’s right arm was being used for an arterial line in the setting of cardiogenic shock and both legs had severe PAD with absent pulses; however, similar access challenges may occur in a patient in whom both arms had been used for repeated AV fistula creation.

TRA has been demonstrated as a safe approach for catheter-based repair of AV fistulae, including radiocephalic anastomoses in the lower arm (10). Our case

demonstrates that in selected cases, navigation through a dormant AV fistula may be considered in clinical situations in which the usual arterial access options are unavailable. Although it was not necessary in our case, access via the ipsilateral distal radial artery (“snuffbox”) or ulnar artery could also be considered to limit the risk of proximal radial artery occlusion in patients with AV fistulae. It should be noted that our report should not be interpreted as advocating for coronary angiography through an active AV fistula.

FOLLOW-UP

After PCI, the patient was transferred back to the CICU, where his hemodynamics improved and he was rapidly weaned off vasopressors. He was discharged home on post-procedure day 14 and was doing well from a cardiac standpoint at 1 year of follow-up.

CONCLUSIONS

With use of upper-extremity AV fistulae as the first-choice option for dialysis access in patients with ESRD, radial access for coronary angiography may be limited in such patients. However, in absence of other vascular access options, navigation through a dormant AV fistula might be considered.

ADDRESS FOR CORRESPONDENCE: Dr. Kevin A. Friede, Duke University, 304 Research Drive, Durham, North Carolina 27708. E-mail: kevin.friede@duke.edu. Twitter: [@kevinfriede](https://twitter.com/kevinfriede).

REFERENCES

- Patel T, Shah S, Pancholy S, Rao S, Bertrand OF, Kwan T. Balloon-assisted tracking: a must-know technique to overcome difficult anatomy during transradial approach. *Catheter Cardiovasc Interv* 2014;83:211-20.
- Neumann F-J, Sousa-Uva M, Ahlsson A, et al. 2018 ESC/EACTS guidelines on myocardial revascularization. *Eur Heart J* 2018;40:87-165.
- Mason PJ, Shah B, Tamis-Holland JE, et al. An update on radial artery access and best practices for transradial coronary angiography and intervention in acute coronary syndrome: a scientific statement from the American Heart Association. *Circ Cardiovasc Interv* 2018;11:e000035.
- United States Renal Data System. Chapter 1: CKD in the general population. *Am J Kidney Dis* 2019;73:51-28.
- Pisoni RL, Zepel L, Fluck R, et al. International differences in the location and use of arteriovenous accesses created for hemodialysis: results from the Dialysis Outcomes and Practice Patterns Study (DOPPS). *Am J Kidney Dis* 2018;71:469-78.
- Kuno T, Hirano K, Imaeda S, et al. A transradial approach of cardiac catheterization for patients on dialysis. *J Invasive Cardiol* 2018;30:212-7.
- Wimmer NJ, Resnic FS, Mauri L, et al. Risk-treatment paradox in the selection of transradial access for percutaneous coronary intervention. *J Am Heart Assoc* 2013;2:e000174.
- United States Renal Data System. Chapter 4: Cardiovascular disease in patients with CKD. *Am J Kidney Dis* 2019;73:579-98.
- Andò G, Capodanno D. Radial versus femoral access in invasively managed patients with acute coronary syndrome: a systematic review and meta-analysis. *Ann Intern Med* 2015;163:932-40.
- Kawarada O, Yokoi Y, Nakata S, Morioka N, Takemoto K. Transradial intervention for native fistula failure. *Catheter Cardiovasc Interv* 2006; 68:513-20.

KEY WORDS coronary angiography, percutaneous coronary intervention, peripheral vascular disease