

## CASE REPORT

# Diagnosis and surgical treatment of bilateral ureteral calculi, hydronephrosis, pyometra, pyocolpos, vestibulovaginal stenosis, and imperforate hymen in a dog: A rare critical case report

Sehoon Kim<sup>1</sup>, Md. Mahbubur Rahman<sup>2</sup>, Park Chul<sup>3</sup>, Minju Kim<sup>4,5</sup>, In Seong Jeong<sup>1,2</sup>

<sup>1</sup>Department of Veterinary Surgery, Royal Animal Medical Center, Jungnang-gu, Seoul, Republic of Korea

<sup>2</sup>Research Center, KNOTUS Co., Ltd., Songdo-dong, Yeonsu-gu, Incheon, Republic of Korea

<sup>3</sup>Animal Medical Center W, Mapo-gu, Seoul, Republic of Korea

<sup>4</sup>Department of Veterinary Surgery, College of Veterinary Medicine, Chonbuk National University, Jeollabuk do, Republic of Korea

<sup>5</sup>25 Hours Animal Medical Center, Songpa-gu, Seoul, Republic of Korea

### ABSTRACT

**Objective:** Bilateral ureteral calculi, hydronephrosis, pyometra, pyocolpos, vestibulovaginal stenosis, and imperforate hymen in a dog are uncommon and can be difficult to diagnose. The aim of this article is to report diagnostic challenges and successful surgical treatment of this rare event and the long-term outcomes.

**Materials and methods:** A 5-year-old, spayed (partial ovariectomy) female dog was primarily diagnosed with bilateral hydronephrosis and ureter obstruction due to urolithiasis along with pyometra. The urolith was removed carefully by the right-side ureterectomy, an appropriate ureteral stent was inserted from the bladder to the right kidney, and then, a vasectomy and hysterectomy were performed. The dog improved and was discharged. However, 50 days after surgery, pyocolpos due to imperforate hymen and vestibulovaginal stenosis were diagnosed and surgically corrected, and the ureteral stent was removed because the ureter had completely healed.

**Results:** During the first admission, serum biochemistry results revealed the increased blood urea nitrogen (5.9 mg/dl), creatinine (116.2 mg/dl), amylase (1,345 U/l), and lipase (141 U/l) values. After surgical correction, all parameters returned to normal. However, 50 days after surgery, the C-reactive protein concentration (143 mg/l) and white blood cell level increased ( $18.4 \times 10^9/l$ ). After a second surgical correction, the dog recovered fully within 10 days, and no postoperative complications were observed during the follow-up of 6 months.

**Conclusion:** This report provides diagnostic assistance and surgical treatment options for a complex urogenital case. Careful examination during puberty is recommended to prevent the associated complications of this disorder.

### ARTICLE HISTORY

Received April 08, 2020

Revised May 07, 2020

Accepted May 09, 2020

Published June 29, 2020

### KEYWORDS

Dog; bilateral ureteral calculi; hydronephrosis; pyocolpos; imperforate hymen.



This is an Open Access article distributed under the terms of the Creative Commons Attribution 4.0 Licence (<http://creativecommons.org/licenses/by/4.0>)

### Case history

A 5-year-old, spayed female (ovariectomy was performed with a partial hysterectomy, and ovaries and uterine horns were removed but not the uterine body), 6.2 kg, Shih Tzu, visited the Royal Animal Medical Center hospital because of anorexia for 2 days and a depressed condition but normal urination according to the owner. The dog had been spayed at 15 months of age. The Committee for the Care of Animal Resources of the Royal Animal Medical

Center approved this study (approval number: 18-RAMC-005; 01 Feb 2018).

### Clinical examination (first round)

Hematology and serum biochemistry were analyzed by ADVIA 2120i™ (Siemens Healthcare Diagnostics) and Hitachi 7180, respectively [1]. The hematological test showed no remarkable changes (Table 1), but the serum

**Correspondence** In Seong Jeong ✉ [jung45457@hanmail.net](mailto:jung45457@hanmail.net) 📧 Royal Animal Medical Center, Jungnang-gu, Seoul, Republic of Korea.

**How to cite:** Kim S, Rahman MM, Chul P, Kim M, Jeong IS. Diagnosis and surgical treatment of bilateral ureteral calculi, hydronephrosis, pyometra, pyocolpos, vestibulovaginal stenosis, and imperforate hymen in a dog: A rare critical case report. *J Adv Vet Anim Res* 2020; 7(3):384–390.

**Table 1.** Pre- and postoperative hematological profiles of dog.

Clinical parameters	Reference range	First round of admission			Second round of admission		
		Day 0	Day 5	Day 11	Day 0	Day 5	Day 8
WBC	6~17 (10 <sup>9</sup> /l)	6.58	16.32	4.3	38.4 (H)	20.13 (H)	16.9
RBC	5.2~8.2 (10 <sup>12</sup> /l)	6.98	6.23	8.20	6.18	5.9	5.06
Hb	12~18 (gm/dl)	17.4	15	15.5	15.9	14.3	16.3
Hct	37~55 (%)	50.2	43.4	34.6	46.8	42.4	38.7
MCV	60~74 (fl)	71.9	69.6	67.3	75.7	71.9	76.5
MCH	19.5~24.5 (pg)	25	24	24.4	25.7	24.3	26.3
MCHC	31~36 (gm/dl)	34.8	34.5	36.2	34	33.8	34.4
Platelet	200~500 (10 <sup>9</sup> /l)	274	330	441	253	362	329
MPV	5~15 (fl)	8	9	10	8	11	8
pH	7.31~7.46 (pH)	7.43	7.37	–	7.35	–	7.42
pCO <sub>2</sub>	27~50 (mmHg)	43	44	–	40	–	45
pO <sub>2</sub>	24~58 (mmHg)	48	52	–	48	–	52
Na <sup>+</sup>	130~154 (mmol/l)	138	142	–	148	–	145
K <sup>+</sup>	3.9~5.1 (mmol/l)	3.4	3.1	–	4.05	–	4.15
Cl <sup>-</sup>	105~119 (mmol/l)	106	106	–	116	–	115
Ca <sup>2+</sup>	1.16~1.4 (mmol/l)	1.23	1.21	–	1.39	–	1.35
HCO <sub>3</sub> <sup>-</sup>	21~28 (mmol/l)	21.2	24	–	23.3	–	21.2
cBase (B)	-2~3 (mmol/l)	-1.3	-1.6	–	-1.1	–	-1.1
cBase(B, ox)	-2~3 (mmol/l)	-1.5	-1~7	–	-1.5	–	-1.5
Angap	7~16 (mmol/l)	10.8	12	–	8.7	–	8.8
Osm	290~330 (mOsm/l)	312	293	–	295	–	290

WBC = white blood cell; RBC = red blood cell; Hb = hemoglobin; Hct = hematocrit; MCV = mean corpuscular volume; MCH = mean corpuscular hemoglobin; MCHC = mean corpuscular hemoglobin concentration; MPV = mean platelet volume; pCO<sub>2</sub> = partial pressure of carbon dioxide; pO<sub>2</sub> = partial pressure of oxygen; Na = sodium; K = potassium; Cl = chloride; Ca = calcium; HCO<sub>3</sub><sup>-</sup> = bicarbonate; cBase (B) = base excess-blood; cBase (B, ox) = base excess-extracellular fluid; Angap = anionic gap; Osm = osmolality; H = higher than the reference level.

biochemistry results revealed increased blood urea nitrogen (BUN) of 5.9 mg/dl (H) and creatinine of 116.2 mg/dl (H) (Table 2). Besides, amylase of 1,345 U/l (H) and lipase 141 U/l (H) had also increased. A urinalysis revealed elevated leukocytes with protein (Table 3).

The radiographic study showed abnormalities: an enlarged and rounded left kidney more than 3.5 times the L<sub>2</sub> vertebral body length but a smooth margin and normal size of the right kidney, various sized radiopaque materials in the retroperitoneal space, a soft tissue opacity, tubular structure ventral to the colon, and cranial displacement of the urinary bladder that was diagnosed as left-sided hydronephrosis, in addition to ureteral calculi and uteromegaly (Fig. 1). Abdominal ultrasonography provided more information: kidney enlargement on the left side, severe dilation of the renal pelvis, mildly echogenic fluid within the dilated renal pelvis, and visualization of the small cortical area. Severe dilation of the left ureter (up to 10 mm) with multiple hyperechoic materials shadowing the dilated

ureter was also observed. However, for the right kidney, increased cortical echogenicity and moderate dilation of the right renal pelvis and marked dilation (up to 7 mm) of the right ureter with hyperechoic materials in the dilated right ureter were also observed. Besides, on the urinary bladder, cranial displacement and mild echogenic sludge within the bladder were noted, and on the uterus, up to 34 mm of echogenic fluid dilation was noted around the left horn or neck (Fig. 1). Altogether, severe hydronephrosis on the left, mild-to-moderate hydronephrosis on the right, and ureteral calculi on both the sides were diagnosed, along with pyometra.

### Surgical treatment (first round)

An intravenous (IV) administration of propofol, 8 mg/kg body weight, was used for general anesthesia, and sevoflurane inhalant (1%–5%) was used for maintaining anesthesia, as described previously [2,3]. At induction of

**Table 2.** Pre- and postoperative serum biochemical profiles of dog.

Clinical parameters	Reference range	First round of admission			Second round of admission		
		Day 0	Day 5	Day 11	Day 0	Day 5	Day 8
CRE	0.5~1.5 (mg/dl)	5.9 (H)	3.1	1.5	1.4	1	1.4
BUN	5~30 (mg/dl)	116.2 (H)	43.5(H)	11.7	14.3	8.3	9.4
Amylase	388~1,007 (U/l)	1345 (H)	978	623	979	875	821
Lipase	5~90 (U/l)	141 (H)	121	87	39	49	38
CRP	0~20 (mg/l)	21	17	–	143 (H)	58 (H)	20
TP	4.9~7.2 (gm/dl)	7.3	6.7	5.4	7.7	6.4	6.5
Albumin	2.3~3.9 (gm/dl)	3.0	2.7	2.3	2.8	2.3	2.1
ALP	20~155 (U/l)	37	94	–	118	–	132
ALT	3~50 (U/l)	13	29	–	12	–	23
AST	10~37 (U/l)	24	54	–	24	–	23
CK	25~167 (U/l)	111	135	–	81	–	85
GGT	4~25 (U/l)	22	10	–	11	–	–
LDH	65~269 (U/l)	271	105	–	182	–	179
T-Bil	0.1~0.7 (mg/dl)	0.4	0.5	–	0.2	–	0.5
Ca <sup>2+</sup>	9.1~11.7 (mg/dl)	11.3	9.7	–	10	–	7.6
TC	127~340 (mg/dl)	131	148	–	256	–	192
TG	21~116 (mg/dl)	92	112	–	56	–	–
Pi	2.4~6.4 (mg/dl)	6.1	4.8	–	2.5	–	3.8
Glucose	67~147 (mg/dl)	110	88	109	109	69	110

CRE = creatinine; BUN = blood urea nitrogen; CRP = C-reactive protein; TP = total protein; ALP = alkaline phosphatase; ALT = alanine aminotransferase; AST = aspartate aminotransferase; CK = creatinine kinase; GGT = gamma-glutamyltransferase; LDH = lactate dehydrogenase; T-Bil = total bilirubin; TC = total cholesterol; TG = triglyceride; Pi = inorganic phosphate; H = higher than the reference level.

**Table 3.** Pre- and postoperative urine analytical profiles of dog.

Clinical parameters	Reference range	First round of admission		Second round of admission	
		Day 0	Day 11	Day 0	Day 8
SG	1.001 ~ 1.030	1.015	1.016	1.016	1.017
pH	6~7.5	6.2	7.1	6.5	7.3
Blood		–	–	+++	–
Protein		+++	+	+	–
Leukocytes		++	–	+++	–
Nitrate		–	–	+	–

SG = specific gravity.

anesthesia, 0.9% normal saline (10 ml/kg/h, IV), analgesic (tramadol, 3 mg/kg, IV), and systemic antibiotics (enrofloxacin, 10 mg/kg, intramuscular (IM) and cephadrine, 30 mg/kg, IV) were administered, as described previously [3–5]. The urolith was removed by a tiny incision in the ureter on the right side, and a 3.7-Fr and 12-cm ureteral stent (Infiniti Medical, LLC, Redwood City, CA) was set from the right kidney to the bladder to improve the azotemia and to confirm

urinary patency. On the left side, a nephroureterectomy was performed as the left kidney and ureter were severely damaged. Finally, because severe pyometra was diagnosed, a hysterectomy was performed. Systemic antibiotics were administered postoperatively, and cephadrine (IV, bid), enrofloxacin (IM, bid), and tramadol (IV, bid) were continued with the dosages outlined above for days. Cimetidine (10 mg/kg, IV, bid) was also administered for 4 days [4].

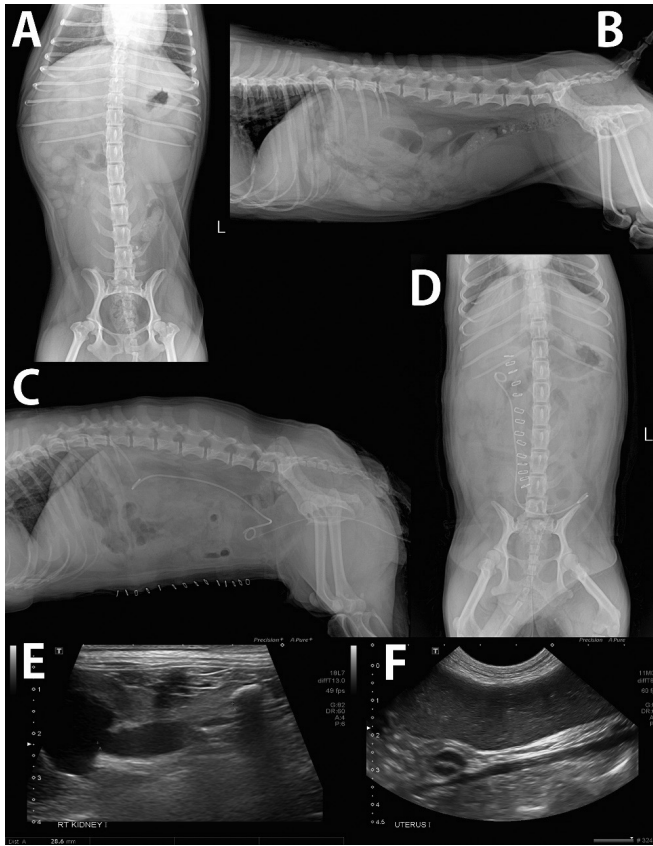
### Clinical examination (second round)

Fifty days after the first surgery, the patient was admitted again with dyschezia and dysuria. The history confirmed menstruation without bleeding and sterility after cross-breeding. The C-reactive protein (CRP) concentration was increased to 143 mg/l with a white blood cell (WBC) count that increased to  $18.4 \times 10^9/l$  (Table 2).

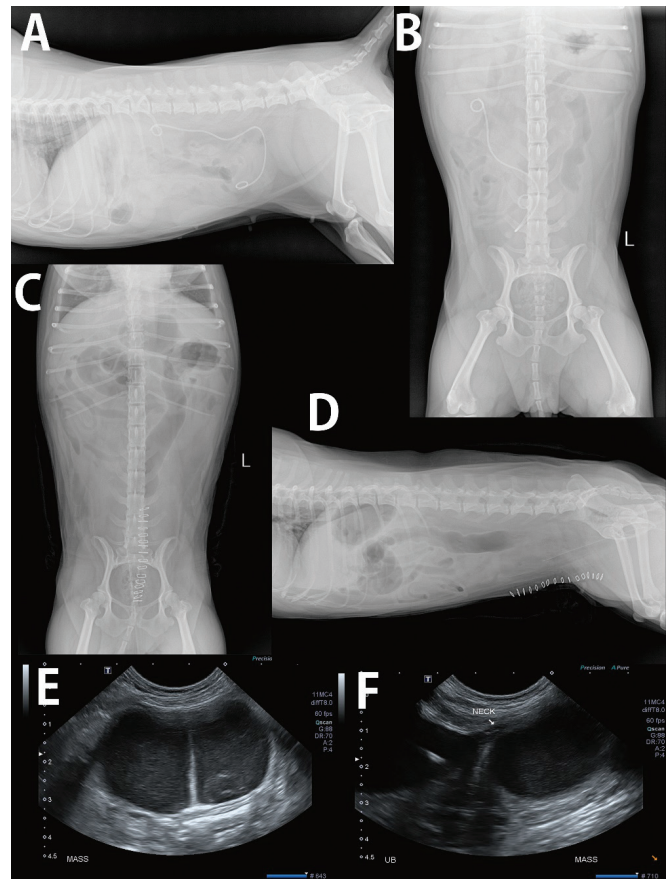
The dog had a history of dysuria and pollakiuria with ureterolith that was suspected to be a urinary tract infection; when the dog did not respond to amoxicillin–clavulanic acid, a free catch urine sample was submitted for

culture. The colonies of *Enterococcus faecium* were grown from the culture, and the treatment was changed to trimethoprim/sulfamethoxazole (26.4 mg/kg was divided into two equal parts at 12-h intervals) [6].

The radiographs showed an approximately 64 × 42-mm-sized homogenous soft tissue opacity, round mass from the cranial to the pelvic canal that displaced the urinary bladder and colon cranially and dorsally, respectively (Fig. 2). Based on these findings, a differential diagnosis of stump pyometra, hemometra, and abnormal vaginal dilation, including pyocolpos, hydrocolpos, and hemocolpos, was indicated. After ultrasonography, cranial displacement, slight thickening of the urinary bladder walls, and echogenic sludge in the urinary bladder were observed (Fig. 2).



**Figure 1.** Radiograph images of before (A–B) and after (C–D) operation, and ultrasonography images before operation during first round of admission. (A–B), Enlarged shape was observed on the left kidney. On the other hand, smooth margin and normal size of the right kidney. Soft tissue opacity tubular structure was observed ventral to the colon. The urinary bladder was displaced cranially. (C–D), The left kidney with ureter was removed. A calculus in the right ureter was removed. A ureteral catheter was inserted from the kidney to the bladder. (E) Increased cortical echo on the right kidney; moderate dilation of the right renal pelvis (up to 12.5 mm); marked dilation of the right ureter (up to 7–8 mm); and hyperechoic materials in the dilated right ureter (about 28 mm distal to the right renal pelvis) were observed. (F) Echogenic fluid dilation was characterized in the uterus (up to 34 mm, left horn or neck).



**Figure 2.** Radiograph images of before (A–B) and after (C–D) operation, and ultrasonography images before operation during second round of admission. (A–B), About 64 × 42-mm-sized homogenous soft tissue opacity round mass was observed cranial to pelvic canal. After surgery, the urinary bladder was displaced cranially with dorsal displacement of the colon (A). The mass in the pelvic canal was removed with ureteral catheter (C, D). On the ultrasonography, about 60 × 32-mm-sized fluid-filled cavitory lesion was observed just caudodorsal to UB, and echogenic cellular debris exists within the cystic lesion (E–F).



An approximately 60 × 32-mm-sized fluid-filled cavitory lesion was present just caudodorsal to the urinary bladder, which was filled with echogenic cellular debris (Fig. 2). A cavitory lesion in the caudal abdomen was suspected to be pyocolpos, mucocolpos, hemocolpos, or stump pyometra.

The attempted visualization of the hymen through the vagina using a stiff scope failed. An obstructed vaginal canal with an imperforate hymen accompanied by stenosis of the vaginal canal was noted on laparotomy (vestibulovaginal stenosis) (Fig. 3).

### Surgical treatment (second round)

A cross-shaped incision was made on the hymen, and pus was drained. Next, the excised redundant parts of the hymen were closed as close as possible to the vaginal wall, with special care to avoid tearing the vaginal wall. The stenotic region was resected, and then, vestibulovaginal anastomosis was performed through an episiotomy. Moreover, the cervical stump, which was severely damaged, was also extracted. The ureteral stent was removed through cystotomy. Anesthesia and therapeutic procedures were followed, as indicated in the first approach. One week after surgery, the patient showed improved general conditions and was discharged.

### Discussion

The ureter is a narrow small duct that passes urine from the kidney to the bladder [7,8]. Therefore, several pathological conditions can be caused by ureteral obstruction, such as increased ureteral hydrostatic pressure, uteromegaly, ureter rupture, intrarenal hydrostatic pressure, hydronephrosis, reduced glomerular filtration rate in the ipsilateral kidney, and life-threatening azotemia, especially when the contralateral kidney is affected [8,9].

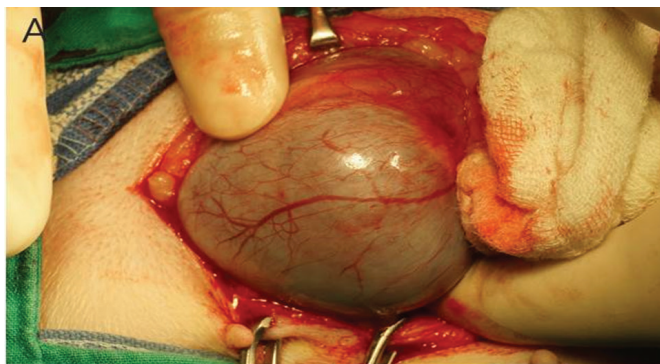
Pyocolpos is a rare congenital atresia of the vaginal orifice, with excessive retention of secondarily infected

cervical secretions. Imperforate hymen, transverse vaginal membrane, and vaginal atresias are the three main causes of pyocolpos [10]. The hymen is an embryological residue of mesodermal tissue formed from the fusion of the Mullerian ducts and the urogenital sinus [11,12]. In dogs, the hymen normally disappears or perforates during the later stages of embryonic development or after birth. If this membrane fails to perforate, it is called an imperforate hymen or persistent hymen that leads to blockage between the vagina and the vestibule, which is cranial to the opening of the urethra [13]. Imperforate hymen is characterized by a genital anomaly, in which the hymen has no opening and completely covers the vaginal introits. Consequently, the imperforate hymen is a congenital disease that may be associated with gradual and increasing complications such as hydrocolpos, pyocolpos, hydrometra, and hydrosalpinx and is often accompanied by renal dysplasia and uretero-hydronephrosis. Indeed, pyocolpos is a secondary disease, mainly resulting from imperforate hymen, and has been noted in several reports [11,14].

Pyocolpos due to the imperforate hymen is difficult to diagnose in dogs, and few cases have been reported in canines [11–14]. This is because it is difficult to make a diagnostic differentiation from pyometra. The presence of ureter obstruction, pyometra, congenital imperforate hymen, and pyocolpos simultaneously in a dog is rare. Therefore, the purpose of this article is to report the difficulties associated with the diagnosis and successful surgical treatment of this rare occurrence and the long-term outcomes. To the best of authors' knowledge, this is the first report of multiple urogenital diseases in a dog.

The serum biochemistry results revealed increased BUN and creatinine, and severe azotemia was diagnosed [8]. The increase in the levels of measured amylase and lipase indicates impaired renal function [15]. In urinalysis, the elevated leukocytes with protein detection indicate an inflammatory response [16]. These results clearly guided the diagnosis of kidney diseases. Additional confirmation radiographs and ultrasonography were performed, and a confirmatory diagnosis was made by observing severe hydronephrosis on the left, mild-to-moderate hydronephrosis on the right, and ureteral calculi on both sides, which were diagnosed along with pyometra. As the left kidney and ureter were severely damaged, the left ureteronephrectomy was performed, and a ureteral stent was installed to maintain urinary patency. Hysterectomy was performed to correct the pyometra.

The animal's condition improved, and the dog was discharged. However, 50 days later, the dog was admitted again due to dyschezia and dysuria, and we analyzed the extensive results of blood, serum, radiographs, and ultrasonography. From these results and clinical history (menstruation without bleeding and sterility after crossbreeding and



**Figure 3.** Direct observation of imperforate hymen after laparotomy.

neutering at 15 months of age), we preliminarily diagnosed urinary tract infection or imperforate hymen. Dyschezia and dysuria are the most common signs of imperforate hymen [11–14,17]. Therefore, we tried to observe the hymen through the vagina using a stiff scope, which was not possible. Of note, the failure to observe the hymen by vaginoscopy was also reported previously [11]. Besides, the age of the dog was 5 years, which added to the complexity. As a major surgery was performed previously, a urinary infection was the first diagnostic concern. Therefore, an antibiotic sensitivity test from the urine was performed, and the treatment was changed to trimethoprim/sulfamethoxazole, but the condition did not improve. Finally, pyocolpos due to imperforate hymen was confirmed by direct observation through laparotomy and corrected surgically by hymen perforation, and the pus was drained to prevent peritonitis or sepsis. Furthermore, the ureteral stent was removed by cystotomy as the urethra had healed adequately. The dog recovered fully within 10 days, and no postoperative complications were observed during 6 months of follow-up. All of these surgical approaches resulted in full recovery from this critical disease complex, and the dog has maintained proper vaginal outflow patency.

Similar cases are typically reported in humans, normally in newborns, or during puberty [18]. Newborn or childhood cases may occur due to maternal estrogenic stimulation that triggers uterovaginal secretions that are trapped by the obstructed vagina and can present with hydrocolpos. However, females are primarily diagnosed soon after menarche. In these cases, menstrual blood is stored in the vagina behind the imperforate hymen, which is known as hematocolpos. Consequently, hematometra, hematosalpinx, and pyocolpos may develop [18] and can be diagnosed by imperforate hymen. Interestingly, there are no reports of cases in newborn canines. However, similar to human cases, there are two reports during puberty: one case was in a 1-year-old Labrador Retriever (puberty between 1 and 2 years) [19] and the other was in a 1-year-old Golden Retriever (puberty around 9–11 months of age) [20]. Five reports in older ages were a 24-month-old Maltese Terrier (puberty around 4–8 months old), a 38-month-old Golden Retriever that presented with dysuria and dyschezia [11], an 8-year-old female spayed Dachshund [13], a 9-year-old intact Cavalier King Charles Spaniel (puberty around 9–11 months of age) [21], and a 9-year-old intact female Shih-Tzu (puberty around 8–9 months of age) [12]. This report presented a 5-year-old, spayed female Shih-Tzu. Therefore, to diagnose imperforate hymen, the age of the dog is not necessarily an important factor. Delayed diagnosis in canines may be due to delays in treatment because the owner may not notice symptoms or may not seek veterinary care promptly. Besides, imperforate hymen may be difficult to diagnose and could initially be confused with

other abdominal pain associated with other abdominal diseases without puberty.

## Conclusion

The surgical techniques applied in this case resolved the clinical symptoms and associated problems. Besides, the delayed diagnosis of imperforate hymen is a common feature in dogs and may cause disease complexity. Therefore, carefully checking the dog during puberty is recommended for an early diagnosis to prevent complications of this disorder. This report could provide diagnostic assistance and surgical treatment options for similar complex urogenital cases.

## Acknowledgments

This work has been supported by the Korea Animal Medical Science Institute and the Royal Animal Medical Center.

## Conflict of interest

There is no conflict of interest in the authors.

## Authors' contribution

Sehoon Kim, Park Chul, Minju Kim, and In Seong Jeong participated in clinical test, diagnosis, and surgery and collection the data. Sehoon Kim, Md. Mahbubur Rahman, and In Seong Jeong designed the study, analyzed the data, and wrote the article.

## References

- [1] Choi GC, Rahman MM, Kim H, Kim S, Jeong IS. Management of sternal dislocation with and without surgery in cats: owner-assessed long-term follow-up of two clinical cases. *J Vet Med Sci* 2018; 80(6):1001–6; <https://doi.org/10.1292/jvms.17-0307>
- [2] Seo BS, Rahman MM, Jeong IS. Importance of meniscal injury diagnosis and surgical management in dogs during reconstruction of cranial cruciate ligament rupture: a retrospective study. *J Adv Vet Anim Res* 2017; 4(3):311–8; <https://doi.org/10.5455/javar.2017.d223>
- [3] Rahman MM, Jeong IS, Kim NS. Application of minimally invasive plate osteosynthesis to tibial shaft fractures in dogs. *J Vet Clin* 2017; 34(3):200–3; <https://doi.org/10.17555/jvc.2017.06.34.3.200>
- [4] Jeong IS, Rahman M, Choi G, Seo B, Lee G, Kim S, et al. A retrospective study of canine cervical disk herniation and the beneficial effects of rehabilitation therapy after ventral slot decompression. *Vet Med* 2019; 64:251–9; <https://doi.org/10.17221/114/2018-VETMED>
- [5] Jeong IS, Piao Z, Rahman MM, Kim S, Kim NS. Canine thoracolumbar intervertebral disk herniation and rehabilitation therapy after surgical decompression: a retrospective study. *J Adv Vet Anim Res* 2019; 6(3):394–402; <https://doi.org/10.5455/javar.2019.f359>
- [6] Ling GV, Ruby AL. Trimethoprim in combination with a sulfonamide for oral treatment of canine urinary tract infections. *J Am Vet Med Assoc* 1979; 174(9):1003–5.
- [7] Jeong IS, Rahman MM, Kim H, Kim S. Surgical management of extramural ectopic ureter by modified colposuspension following ureteroneocystostomy in a young female Siberian Husky dog.

- J Adv Vet Anim Res 2017; 4(3):301–6; <https://doi.org/10.5455/javar.2017.d214>
- [8] Choi G, Jeong I, Seo B, Lee G, Kim YH, Rahman MM, et al. Surgical correction of ureter rupture due to stenosis induced secondary to accidental injury by placing nephrovesical subcutaneous ureteric bypass in a dog. J Adv Vet Anim Res 2018; 5(2):247–54; <https://doi.org/10.5455/javar.2018.e266>
- [9] Berent AC, Weisse CW, Todd KL, Bagley DH. Use of locking-loop pigtail nephrostomy catheters in dogs and cats: 20 cases (2004–2009). J Am Vet Med Assoc 2012; 241(3):348–57; <https://doi.org/10.2460/javma.241.3.348>
- [10] Agarwal N, Singh S, Dayal R, Pathak A. Pyocolpos in a 4 year old: a rare scenario. Int J Reprod Contracept Obstet Gynecol 2013; 2(3):488–90; <https://doi.org/10.5455/2320-1770.ijrcog20130956>
- [11] Tsumagari S, Takagi K, Takeishi M, Memon MA. A case of a bitch with imperforate hymen and hydrocolpos. J Vet Med Sci 2001; 63(4):475–7; <https://doi.org/10.1292/jvms.63.475>
- [12] Kim M, Kim KY, Park JH, Shin JI, Kim TH, Hong S, et al. Persistent hymen and pyocolpos in a female Shih-Tzu dog. J Vet Clin 2014; 31:246–9; <https://doi.org/10.17555/ksvc.2014.06.31.3.246>
- [13] Blackford Winders CL, Tobias KM. Perineal protrusion secondary to imperforate hymen and hydrocolpos in an 8-Year-Old spayed female dog. Case Rep Vet Med 2016; 2016:8067967; <https://doi.org/10.1155/2016/8067967>
- [14] Marinho G, Palhano H, Abidu-Figueiredo M, De Jesus V. Pyocolpos in a pinscher bitch: a case report. J Morphol Sci 2013; 30(3):206–8.
- [15] Jiang CF, Ng KW, Tan SW, Wu CS, Chen HC, Liang CT, et al. Serum level of amylase and li pase in various stages of chronic renal insufficiency. Zhonghua Yi Xue Za Zhi (Taipei) 2002; 65(2):49–54.
- [16] Yu Y, Sikorski P, Bowman-Gholston C, Cacciabeve N, Nelson KE, Pieper R. Diagnosing inflammation and infection in the urinary system via proteomics. J Transl Med 2015; 13:111; <https://doi.org/10.1186/s12967-015-0475-3>
- [17] McIntyre RL, Levy JK, Roberts JF, Reep RL. Developmental uterine anomalies in cats and dogs undergoing elective ovariohysterectomy. J Am Vet Med Assoc 2010; 237(5):542–6; <https://doi.org/10.2460/javma.237.5.542>
- [18] Rathod S, Samal SK, Rajsekaran A, Rani PR, Ghose S. Imperforate hymen and its complications: report of two cases and review of literature. Int J Reprod Contracept Obstet Gynecol 2014; 3(3):839–42; <https://doi.org/10.5455/2320-1770.ijrcog20140965>
- [19] Alonge S, Romussi S, Grieco V, Luvoni GC. Congenital abnormality of the vagina complicated by haemato-pyocolpos in a 1-year labrador retriever. Reprod Domest Anim 2015; 50(3):514–6; <https://doi.org/10.1111/rda.12491>
- [20] Viehoff FW, Sjollem BE. Hydrocolpos in dogs: surgical treatment in two cases. J Small Anim Pract 2003; 44(9):404–7; <https://doi.org/10.1111/j.1748-5827.2003.tb00176.x>
- [21] Van den Berghe F, Ponthier J, Parrilla Hernandez S, Deleuze S. Pyovagina caused by pyometra and a persistent hymen in a 9-year old bitch. Reprod Domest Anim 2013; 48(1):114.