

CASE REPORT

A rare cause of lumbar nerve root compression: Extramedullary hematopoiesis in a patient with thalassemia major

Hiba Boussaa^{1,2}  | Dhia Kaffel^{1,2} | Kaouther Maatallah^{1,2} |
Hanene Lassoued Ferjani^{1,2}  | Wafa Hamdi^{1,2}

¹University of Tunis El Manar, Faculty of Medicine of Tunis, Tunisia

²Department of Rheumatology, Mohamed Kassab Institute of Orthopedics, La Manouba, Tunisia

Correspondence

Hiba Boussaa, Department of Rheumatology, Mohamed Kassab Institute of Orthopedics, 2010 La Manouba, Tunisia.
Email: hibaboussaa@gmail.com

Abstract

Extramedullary hematopoiesis (EMH) can rarely involve the epidural space, leading to spinal cord compression syndrome. No treatment guidelines have been established yet.

KEYWORDS

extramedullary hematopoiesis, low back pain, radiculalgia, spinal cord compression, thalassemia

1 | INTRODUCTION

Extramedullary hematopoiesis (EMH) is a physiological compensatory reaction in β -thalassemia that can rarely involve the epidural space, leading to spinal cord compression syndrome. MRI is the gold standard for diagnosis and monitoring. No treatment guidelines have been established yet.

β -Thalassemia is a hereditary disease characterized by defective hemoglobin synthesis, which leads to ineffective erythropoiesis and chronic anemia through hemolysis.¹

Patients with β -thalassemia major require lifelong regular blood transfusions in order to prevent hepatosplenomegaly and suppress bone marrow expansion.²

Extramedullary hematopoiesis (EMH) is a physiological compensatory reaction in β -thalassemia characterized by the formation of hematopoietic elements outside the bone marrow. The most common affected sites are liver, spleen, and lymph nodes.³

Extramedullary hematopoiesis can rarely involve the epidural space, usually in the mid- and lower thoracic region, thereby causing compression of the spinal cord and the neighboring structures that may lead to neurological disorders of lower limbs.⁴

Herein, we present a case of a 23-year-old man with β -thalassemia major presenting with lumbar radicular compression due to EMH.

2 | CASE PRESENTATION

A 23-year-old man was diagnosed at the age of 12 months with β -thalassemia major. He had a splenectomy at the age of two and a half and had been receiving monthly blood transfusions in association with iron chelation therapy. Written informed consent was obtained from the patient for the publication of this case report.

He complained of mechanical low back pain resistant to symptomatic treatment associated with radiculalgia of the anterior aspect of the right thigh that had been gradually worsening over the last year. Otherwise, he did not report any low limb weakness or sphincter disorders.

Physical examination showed a restriction in the lumbar flexion using Schober's test (+2 cm) with paravertebral muscle spasm. Deep tendon reflexes were normal with bilateral flexor plantar response. There was neither sensitive deficit

This is an open access article under the terms of the Creative Commons Attribution-NonCommercial-NoDerivs License, which permits use and distribution in any medium, provided the original work is properly cited, the use is non-commercial and no modifications or adaptations are made.

© 2021 The Authors. *Clinical Case Reports* published by John Wiley & Sons Ltd.

nor motor impairment of the lower limbs. There is no saddle hypoesthesia, and anal sphincter contraction was conserved.

Laboratory investigations found hemoglobin rate at 9.1 g/dL, white blood cell count at 9600 elements/mm³, and platelets at 462 000 elements/mm³. The blood smear found anisopoikilocytosis, and circulating erythroblasts evaluated at 30%.

C-reactive protein was within the normal range and ESR rate at 39 mm. The infectious investigation was negative.

Medullary magnetic resonance imaging (MRI) revealed diffuse low signal intensity seen in the whole spine consistent with marrow reconversion, vertebral fractures of L1, L2, and L5 associated with anterior epidural masses causing dural sac compression, and almost total filling of the sacral canal with extension to the presacral space (Figure 1).

In this context, the diagnosis of β -thalassemia with radicular compression due to EMH was established. The patient underwent radiotherapy of the affected areas. An increase in the frequency of transfusions was also indicated in close collaboration with hematologists.

The follow-up at 2 months showed complete relief of the pain. Control MRI demonstrated significant regression of lumbar and sacral EMH of which only a small presacral mass

of 2 centimeters in diameter persisted. No evidence of cord compression was noted (Figure 2).

Regarding vertebral fractures, bone densitometry revealed osteoporosis with a Z-score of -3 SD at lumbar spine and -3.2 SD at femoral neck. A treatment with oral alendronate was started in association with calcium, vitamin D, and folic acid supplements.

3 | DISCUSSION

β -Thalassemia is an heterogeneous autosomal recessive hereditary anemia characterized by reduced or absent β -globin chain synthesis. It remains endemic around the Mediterranean basin. Thalassemia is a serious blood disorder characterized by reduced hemoglobinization of red cells, increased hemolysis, and ineffective erythropoiesis.¹

Regular transfusions and oral iron chelation therapy have significantly improved the quality of life in patients with β -thalassemia major.^{1,2}

Extramedullary hematopoiesis is a common compensatory reaction that mainly affects the liver, spleen, and lymph

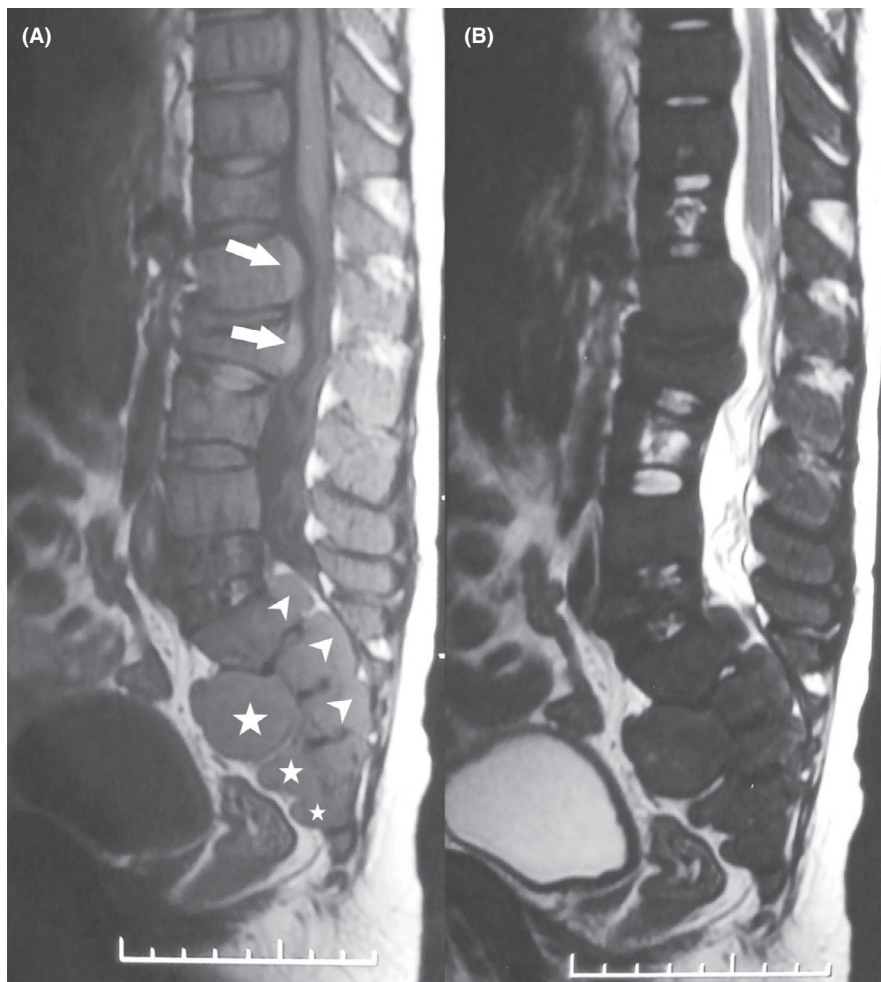
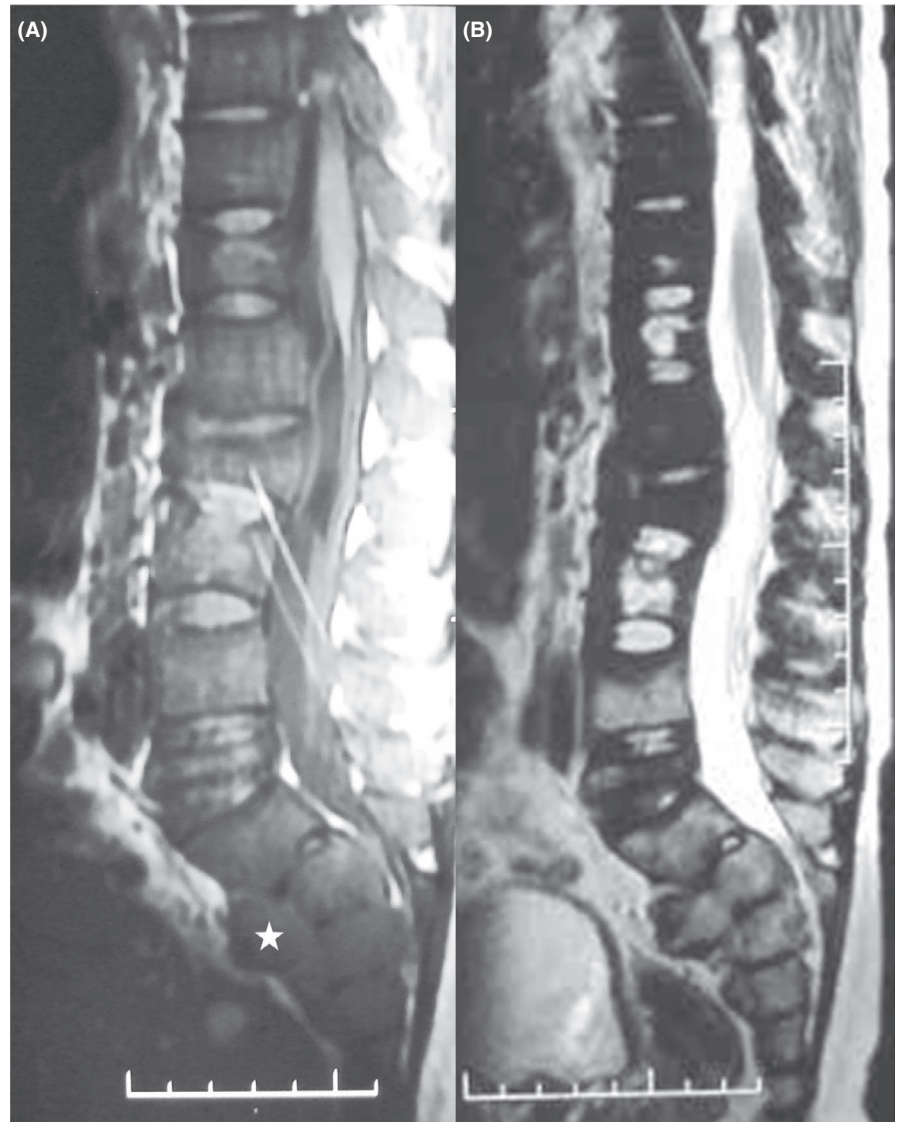


FIGURE 1 Magnetic resonance imaging sagittal T1 WI (A) and sagittal T2 WI (B) showing diffusely hypointense marrow, anterior epidural masses regarding L1 and L2 (arrows) causing dural sac compression, and in the sacral canal (head arrows) with extension to the presacral space (stars)

FIGURE 2 Control MRI sagittal T1 WI (A) and T2 WI (B) demonstrated significant regression of epidural masses, with persistence of a small presacral mass (white star)



nodes and rarely other tissues such as the adrenal glands, kidneys, breasts, prostate gland, adipose tissue, and skin.³

Since the first publication by Gatto et al in 1954,⁵ numerous cases with spinal cord compression (SCC) due to epidural EMH have been reported. This condition frequently involves the mid- or lower thoracic spine where the narrow spinal canal predisposes itself to cord compression.⁶ However, patients with lumbar radiculopathy secondary to EMH have to our knowledge been rarely reported.^{7,8}

The clinical presentation includes low back pain associated with radiculalgia. Gradually, paraparesis, sensory impairment, and sphincter disturbances may appear.⁴ Complete paraplegia has been rarely reported in thalassemia.⁶ The diagnosis must be suspected early in order to prevent irreversible neurological damages.

The current patient did not exhibit any neurologic disorder. Indeed, MRI showed that EMH involved the lumbar spine and the sacral canal with compression of the dural sac but with no evidence of SCC or cauda equina syndrome.

Magnetic resonance imaging is the gold standard for the diagnosis of EMH since the biopsy is highly risky of hemorrhage and thereby should be reserved for patients with severe SCC planned for laminectomy or in case of a doubtful diagnosis.⁹

The main differential diagnoses for epidural masses are tumors, abscesses, and metabolic disease. Low signal intensity on both unenhanced T1- and T2-weighted MR images is characteristic of iron deposition, which is strongly indicative of EMH.¹⁰

Treatment options are variable including blood transfusions, hydroxyurea, radiotherapy, and decompressive surgery. However, no guidelines for the optimal management of this condition have been established probably due to its rarity.

Hypertransfusion can reduce the body's need of EMH by correcting anemia which decreases the production of erythropoietin. Blood transfusion should be considered only as an adjunct to radiation or surgery given its incomplete and temporary action.¹¹ Besides, it is not a harmless procedure

with possible infectious complications, iron overload, and antibodies genesis.¹²

Cytostatic agents such as hydroxyurea, which increases fetal hemoglobin production, have been successfully used in EMH. However, symptom recurrence over several weeks has been reported and was managed with radiation therapy.¹³

Radiotherapy emerged as an efficient treatment of EMH.¹⁴ Indeed, radiotherapy alone was shown to treat many cases with SCC due to EMH reported in the literature.^{6,9,15,16} Tsitsopoulos et al were the first authors to describe a patient with solitary nerve root compression and subsequent severe radiculopathy successfully treated with radiation therapy alone.⁸ The advantages of this technique include immediate availability and rapid clinical improvement. Its inconveniences comprise myelosuppression which must be controlled and residual masses with potential risk of recurrence.¹⁷ Spinal cord edema reported in the acute phase can be prevented by a short course of corticosteroids.¹⁸

Surgery provides an immediate decompression and also allows an accurate histological diagnosis. However, this procedure can be associated with various risks such as hemorrhage, spinal instability, and cardiovascular stress in patients at risk. Another disadvantage is the high incidence of recurrence due to incomplete resection. This condition may be prevented using a low dose of radiation in consolidation with surgical decompression.¹²

In conclusion, EMH is a physiological reaction in patients with thalassemia that can rarely involve the epidural space and the neural structures. An early diagnosis must be established based on the clinical presentation and MRI findings. The treatment of EMH remains controversial, and no guidelines have yet been proposed.

ACKNOWLEDGMENTS

None.

CONFLICT OF INTEREST

The authors declare no conflicts of interest.

AUTHOR CONTRIBUTIONS

DK, KM, HF and WH: analyzed and interpreted the patient data and provided advice for treatment. DK: ensured the clinical follow-up of the patient. HB and DK: were major contributors in writing the manuscript, and all the authors: read, revised, and approved the final manuscript.

ETHICAL APPROVAL

Written informed consent was obtained from the patient for the publication of this case report.

DATA AVAILABILITY STATEMENT

The data that support the findings of this study are available from the corresponding author upon reasonable request.

ORCID

Hiba Boussaa  <https://orcid.org/0000-0002-4744-5766>

Hanene Lassoued Ferjani  <https://orcid.org/0000-0002-8658-0936>

REFERENCES

1. Origa R. β -Thalassemia. *Genet Med*. 2017;19(6):609-619.
2. Choudhry VP. Thalassemia minor and major: current management. *Indian J Pediatr*. 2017;84(8):607-611.
3. Kapatia G, Kaur A, Rastogi P, et al. Extramedullary hematopoiesis: clinical and cytological features. *Diagn Cytopathol*. 2020;48(3):191-196.
4. Salehi SA, Koski T, Ondra SL. Spinal cord compression in beta-thalassemia: case report and review of the literature. *Spinal Cord*. 2004;42(2):117-123.
5. Gatto I, Terrana V, Biondi L. Compression of the spinal cord due to proliferation of bone marrow in epidural space in a splenectomized person with Cooley's disease. *Haematologica*. 1954;38(1):61-76.
6. Malik M, Pillai LS, Gogia N, et al. Paraplegia due to extramedullary hematopoiesis in thalassemia treated successfully with radiation therapy. *Haematologica*. 2007;92(3):e28-e30.
7. Gouliamos A, Dardoufas C, Papailiou I, Kalovidouris A, Vlahos L, Papavasiliou C. Low back pain due to extramedullary hemopoiesis. *Neuroradiology*. 1991;33(3):284-285.
8. Tsitsopoulos P, Zevgaridis D, Tsitsopoulos P, Tsonidis C, Anagnostopoulos I, Marinopoulos D. Lumbar nerve root compression due to extramedullary hemopoiesis in a patient with thalassemia: complete clinical regression with radiation therapy. Case report and review of the literature. *J Neurosurg Spine*. 2007;6(2):156-160.
9. Ben Ammar L, Ferjani H, Maatallah K, et al. Spinal cord compression by extramedullary hematopoiesis in beta-thalassemia major. *Clin Case Rep*. 2020;8(8):1433-1436.
10. Tsitouridis J, Stamos S, Hassapoulou E, Tsitouridis K, Nikolopoulos P. Extramedullary paraspinous hematopoiesis in thalassemia: CT and MRI evaluation. *Eur J Radiol*. 1999;30(1):33-38.
11. Wang A, Carberry N, Solli E, Gillick J, Islam H, Hillard V. Spinal cord compression secondary to extramedullary hematopoiesis: case report and review of the literature. *Case Rep Oncol*. 2016;9(2):290-297.
12. Moncef B, Hafedh J. Management of spinal cord compression caused by extramedullary hematopoiesis in beta-thalassemia. *Intern Med*. 2008;47(12):1125-1128.
13. Gamberini MR, Fortini M, De Sanctis V. Paraplegia due to spinal cord compression by extramedullary erythropoietic tissue in a thalassaemia intermedia patient with gynecomastia secondary to cirrhosis: successful treatment with hydroxyurea. *Pediatr Endocrinol Rev*. 2004;2(Suppl 2):316-318.
14. Singhal S, Sharma S, Dixit S, et al. The role of radiation therapy in the management of spinal cord compression due to extramedullary haematopoiesis in thalassaemia. *J Neurol Neurosurg Psychiatry*. 1992;55(4):310-312.
15. Yathiraj PH, Singh A, Vidyasagar S, Varma M, Mamidipudi V. Excellent and durable response to radiotherapy in a rare case of spinal cord compression due to extra-medullary hematopoiesis in β -thalassemia intermedia: case report and clinicoradiological correlation. *Ann Palliat Med*. 2017;6(2):195-199.

16. Ruo Redda MG, Allis S, Reali A, et al. Complete recovery from paraparesis in spinal cord compression due to extramedullary haemopoiesis in beta-thalassaemia by emergency radiation therapy. *Intern Med J.* 2014;44(4):409-412.
17. Papavasiliou C, Sandilos P. Effect of radiotherapy on symptoms due to heterotopic marrow in beta-thalassaemia. *Lancet.* 1987;1(8523):13-14.
18. Tan T-C, Tsao J, Cheung F-C. Extramedullary haemopoiesis in thalassaemia intermedia presenting as paraplegia. *J Clin Neurosci.* 2002;9(6):721-725.

How to cite this article: Boussaa H, Kaffel D, Maatallah K, Lassoued Ferjani H, Hamdi W. A rare cause of lumbar nerve root compression: Extramedullary hematopoiesis in a patient with thalassaemia major. *Clin Case Rep.* 2021;9:e04119. <https://doi.org/10.1002/ccr3.4119>