



Contents lists available at ScienceDirect

## International Journal of Surgery Case Reports

journal homepage: [www.casereports.com](http://www.casereports.com)

# Left colic artery-preserving D3 lymphadenectomy using near-infrared spectroscopy was effective for double advanced cancers of the transverse colon and rectum: A case report

Masateru Yamamoto, Hiroyuki Egi\*, Masatoshi Kochi, Shoichiro Mukai, Hideki Ohdan

Department of Gastroenterological and Transplant Surgery, Graduate School of Biomedical and Health Science, Hiroshima University, 1-2-3, Kasumi, Minami-ku, Hiroshima City, Hiroshima, 734-8551, Japan

## ARTICLE INFO

### Article history:

Received 27 March 2018  
 Received in revised form 4 June 2018  
 Accepted 20 June 2018  
 Available online 28 June 2018

### Keywords:

Low tie  
 Near-infrared spectroscopy  
 Rectal cancer  
 Tissue oxygen saturation  
 Transverse colon cancer

## ABSTRACT

**INTRODUCTION:** Exact assessment of intestinal viability is necessary, since the risk of anastomotic complications increases due to the reduction in anastomotic blood supply. Near-infrared spectroscopy is useful in assessing blood flow because it allows real-time monitoring and quantifying of tissue oxygen saturation. Herein, we report a case in which two intestinal resections were performed safely by using near-infrared spectroscopy to evaluate the blood flow at the anastomotic sites.

**PRESENTATION OF CASE:** A 67-year-old man was diagnosed with multiple cancers of the transverse colon and rectum. Laparoscopic transverse colon resection and low anterior resection were performed along with left colic artery-preserving lymphadenectomy, including tissues around the origin of the inferior mesenteric artery. After mesenteric dissection, the tissue oxygen saturation of the proximal side and distal side stumps were 93% and 87%, respectively. The tissue oxygen saturation of the anastomotic proximal side after mesenteric dissection was 76%, thus confirming sufficient blood flow.

**DISCUSSION:** Performance of transverse colon resection and low anterior resection for multiple cancers of the transverse colon and rectum resulted in blockage of the blood flow to the descending colon; therefore, it was necessary to preserve the blood flow to the descending colon by preserving the left colic artery. Near-infrared spectroscopy was used to evaluate blood flow to the anastomotic sites, in order to perform the surgery safely.

**CONCLUSION:** Near-infrared spectroscopy is a safe, simple and low-cost method for assessing blood flow intraoperatively in conjunction with left colic artery-preserving surgery.

© 2018 The Authors. Published by Elsevier Ltd on behalf of IJS Publishing Group Ltd. This is an open access article under the CC BY-NC-ND license (<http://creativecommons.org/licenses/by-nc-nd/4.0/>).

## 1. Introduction

Anastomotic leakage and stenosis are serious complications of colorectal surgery. In addition to resulting in a longer hospital stays, morbidity and mortality rates may be raised, and disease-free survival and overall survival rates are potentially shortened in cancer patients [1]. The risk of such anastomotic complications increases with the reduction in anastomotic blood supply [2]; therefore, the exact assessment of intestinal viability is necessary. However, there are no standardized methods for assessing blood flow during the surgery. Recently, near-infrared spectroscopy (NIRS) was developed for quantifying tissue oxygen saturation (StO<sub>2</sub>) noninvasively. Moreover, NIRS is considered objective because it allows real-time monitoring and quantifying of StO<sub>2</sub> in the various organs and tissues directly beneath the sensor [3,4].

In cases of multiple cancers, such as transverse colon and rectal cancers, transverse colon resection and low anterior resection blocks the marginal arterial flow from the middle colic artery (MCA) to the descending colon. However, it is possible to preserve this blood flow by performing low anterior resection with preservation of the left colic artery (LCA). This is the surgical procedure that has been adopted in our department.

Herein, we report a case of surgery preserving the LCA that was performed safely by using NIRS to evaluate the blood flow at the anastomotic sites.

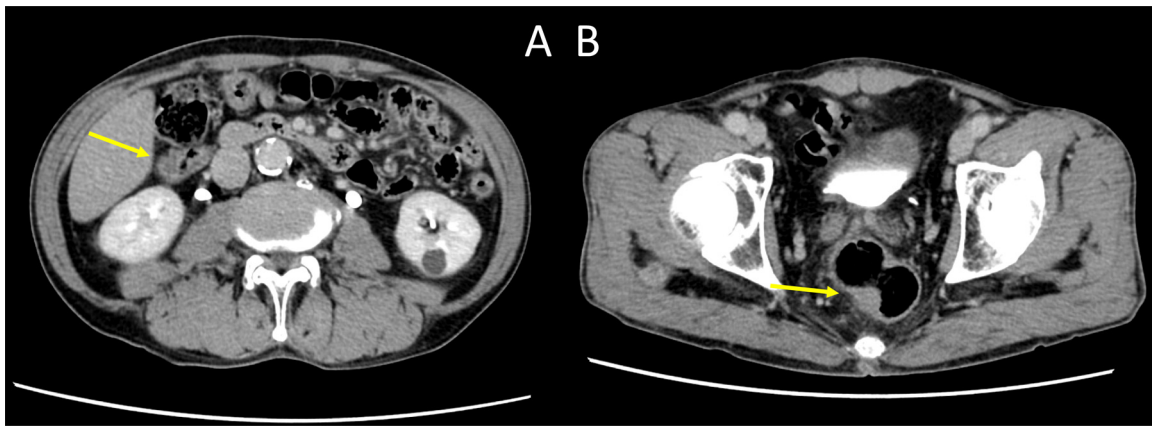
This case report has been reported in line with the SCARE criteria [5].

## 2. Presentation of case

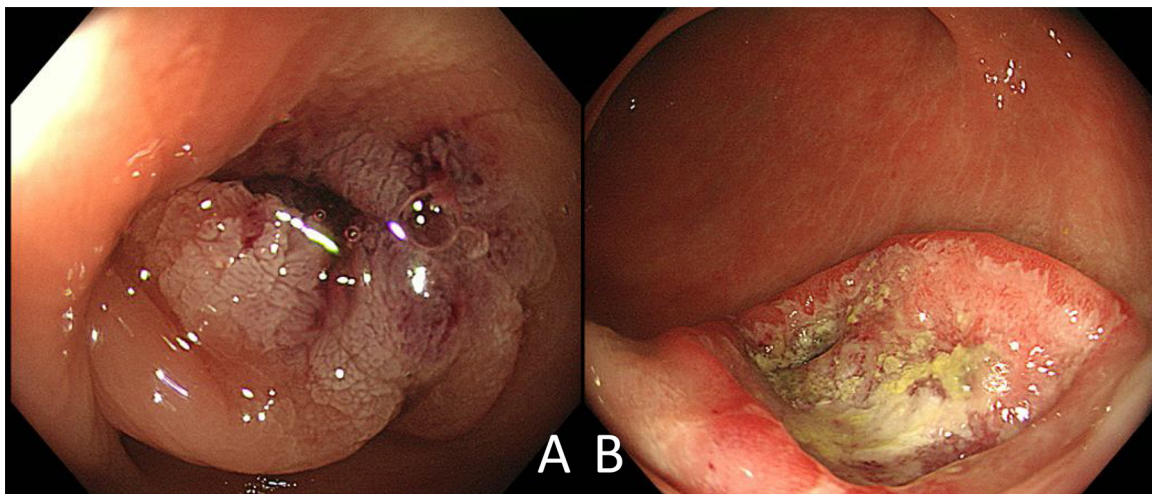
A 67-year-old man was undergoing treatment for chronic pancreatitis at our hospital. Since we detected an elevated of carcinoembryonic antigen level, which was regularly measured to prevent the development of pancreatic cancer, contrast-enhanced computed tomography was performed, revealing circumference wall thickening of the transverse colon (Fig. 1A) and semicircu-

\* Corresponding author.

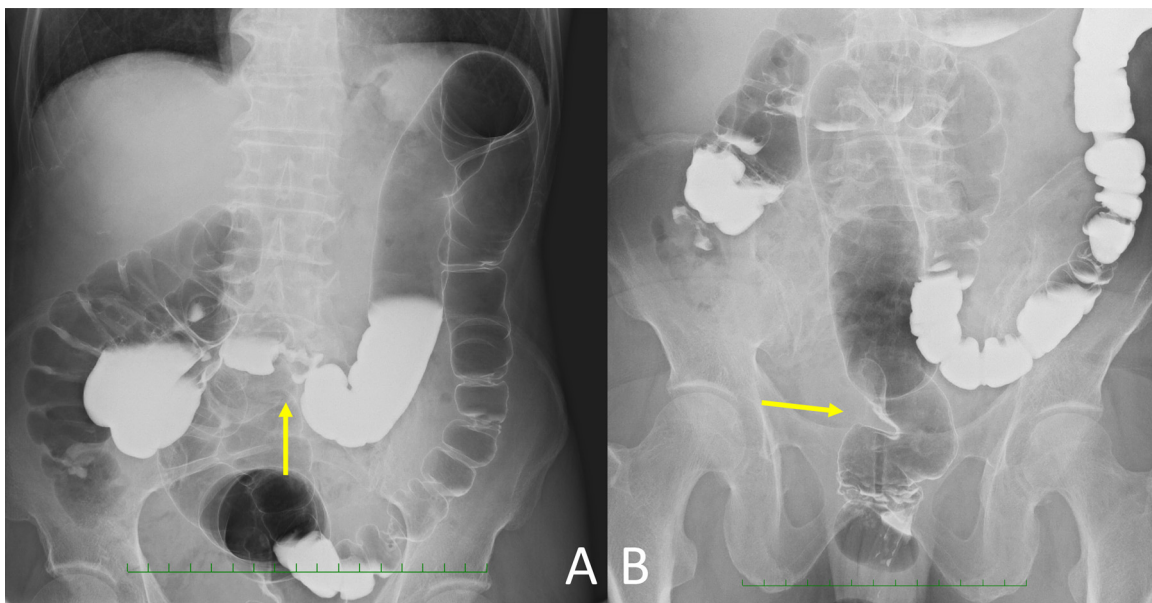
E-mail addresses: [indianajonese6055@gmail.com](mailto:indianajonese6055@gmail.com) (M. Yamamoto), [hiroegi@yahoo.co.jp](mailto:hiroegi@yahoo.co.jp) (H. Egi), [msts.luv4@gmail.com](mailto:msts.luv4@gmail.com) (M. Kochi), [mukais@hiroshima-u.ac.jp](mailto:mukais@hiroshima-u.ac.jp) (S. Mukai), [hohdan@hiroshima-u.ac.jp](mailto:hohdan@hiroshima-u.ac.jp) (H. Ohdan).



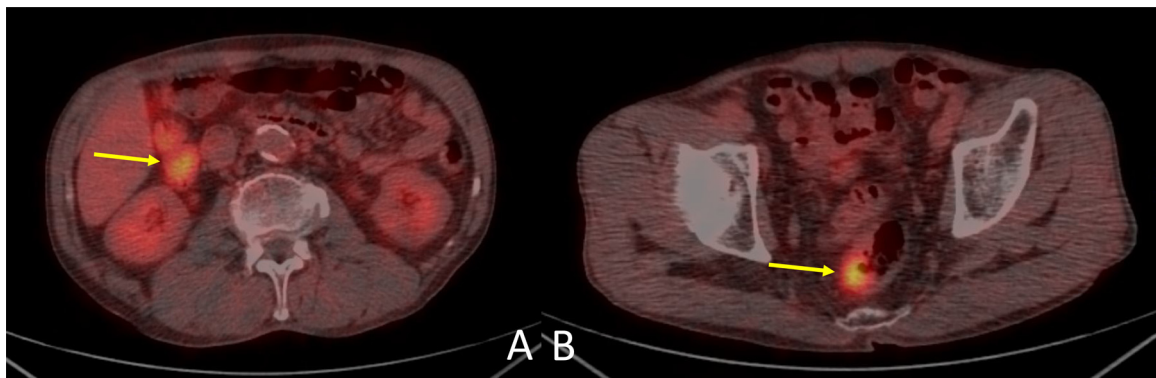
**Fig. 1.** Computed tomography findings: A, circumference wall thickening accompanied by contrast effect of the transverse colon (arrow); B, semicircular wall thickening accompanied by contrast effect of the proximal rectum (arrow).



**Fig. 2.** Colonoscopy findings: A, a 50-mm-diameter circumferential type 2 tumor in the transverse colon; B, a 30-mm-diameter type 2 tumor in the proximal rectum.



**Fig. 3.** Barium enema findings: A, a 50-mm-diameter circumferential type 2 tumor, the so-called apple core sign, in the middle of the transverse colon (arrow); B, a 30-mm-diameter type 2 tumor in the proximal rectum (arrow).



**Fig. 4.** Positron emission tomography findings: A, the standard uptake values was 4.6 in the transverse colon cancer (arrow); B, the standard uptake values was 5.0 in the rectal cancer (arrow).

lar wall thickening of the proximal rectum (Fig. 1B); therefore, further examination was performed. Colonoscopy revealed a 50-mm-diameter circumferential type 2 tumor in the transverse colon (Fig. 2A) and a 30-mm-diameter type 2 tumor in the rectum (Fig. 2B), and both biopsy findings indicated moderately differentiated adenocarcinoma. He was then referred to our department for surgical treatment. Physical examination was largely unremarkable. Laboratory findings showed a hemoglobin A1c level of 6.6. His carcinoembryonic antigen level was elevated, at 30.0 ng/mL, while his carbohydrate antigen 19-9 was within normal limits, at 11.0 U/mL. Similarly, a barium enema examination revealed a 50-mm-diameter circumferential type 2 tumor, the so-called apple core sign, in the middle of the transverse colon (Fig. 3A) and a 30-mm-diameter type 2 tumor in the proximal rectum (Fig. 3B). Positron emission tomography revealed the standard uptake levels for the transverse colon and rectum were 4.6 (Fig. 4A) and 5.0 (Fig. 4B), respectively.

Based on the preoperative findings, laparoscopic transverse colon resection and low anterior resection were performed for multiple cancers of the transverse colon and rectum, respectively. LCA-preserving D3 lymph node dissection was performed for the tumor located in the middle of the transverse colon. The origin of the MCA was ligated as a D3 lymph node dissection. After a small incision in the umbilicus, a transverse colon resection was performed by raising the transverse colon outside the abdominal cavity (Fig. 5A). StO<sub>2</sub> measurements were obtained at two points (proximal and distal sides of the anastomosis) on the antimesenteric position of the intestine before and after mesenteric dissection (Fig. 5B). Before MCA and mesenteric dissection, the StO<sub>2</sub> of the proximal-side stump was 94%, and that of the distal-side stump was 95%; after dissection, these values were 93% and 87%, respectively. Thus, colo-colo anastomosis was performed with end-to-end anastomosis using Albert-Lembert suture, after confirming there was sufficient blood flow. The rectum was then resected, and the proximal side stump was raised outside the abdominal cavity through the umbilical incision (Fig. 5C). We were unable to measure the StO<sub>2</sub> in the antimesenteric position of the rectum before mesenteric dissection because the dissection was performed by laparoscopic operation. The StO<sub>2</sub> of the anastomotic proximal side of the colorectal anastomosis after mesenteric dissection was 76% (Fig. 5D); thus, we judged that the colorectal anastomosis could be performed safely [2]. The colorectal anastomosis was also performed with end-to-end anastomosis by using the double stapling technique with confirmation of sufficient blood flow.

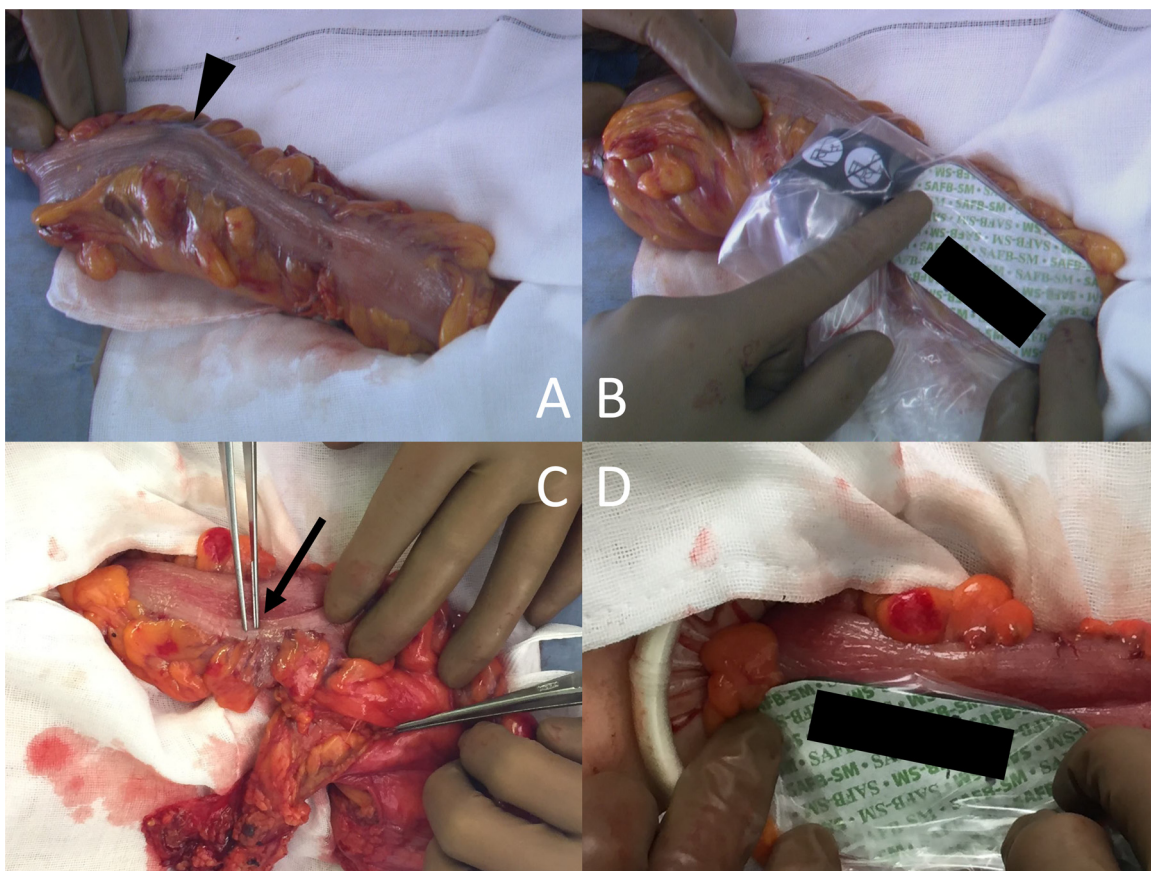
The patient's postoperative course was uneventful.

### 3. Discussion

When transverse colon resection is performed, division of the MCA blocks the blood flow to the proximal side of the colo-colo anastomotic site. When lower anterior resection is performed, the IMA is divided at the origin, whereby the blood flow to the distal side of the colo-colo anastomotic site is also blocked. Moreover, the blood flow to the proximal side of the colorectal anastomosis is blocked. In the present case, performing transverse colon resection and low anterior resection for multiple cancers of the transverse colon cancer and rectum, respectively, resulted in blockage of blood flow to the descending colon. Therefore, it was necessary for us to preserve the blood flow to the descending colon by preserving the LCA. In addition, we used NIRS to evaluate the blood flow at the anastomotic site in order to perform the surgery more safely. It is particularly important to confirm sufficient blood flow to the distal side of the colo-colo anastomosis site as well as to the proximal side of the colorectal anastomosis site.

Exact assessment of intestinal viability is necessary intraoperatively in intestinal anastomoses. Observation of clinical findings of the intestine, such as the serosal surface color, pulsation and bleeding from the marginal arteries, have been proposed to assess intestinal perfusion [6]. However, evaluation of intestinal viability from such intraoperative findings is subjective and based on the experience of the surgeon. Consequently, there are few criteria for setting an appropriate incision line on the intestine. It is known that 70% of mesenteric blood flows to the mucosa and submucosa of the intestine and the remaining flows through the muscular layer and the serosa [7]. Therefore, if the blood flow in the mesentery and the superficial vasa recta is directly restricted, the mucosa and the submucosa will be more seriously compromised than the muscular layer and the serosa will be. Thus, blood flow to the mucosa and submucosa may be deficient even if surface indicators may appear to be acceptable.

Some methods for evaluating visceral blood flow intraoperatively have been reported for the above reasons. Doppler ultrasonography has been used to assess vascularization of colorectal anastomosis; however, its sensitivity is low [6]. Intraoperative indocyanine green fluorescence angiography has been used to visualize blood flow; however, it does not provide an objective measurement. Moreover, these methods are inconvenient and invasive. NIRS was recently developed for quantifying StO<sub>2</sub> noninvasively, and it is considered objective because it allows real-time monitoring and quantifying of StO<sub>2</sub> in various organs and tissues [3,4]. Evaluation by using NIRS is completely noninvasive and simple to perform. Furthermore, the cost is low, because the master probe is reusable.



**Fig. 5.** A, raising the transverse colon outside the abdominal cavity through a small incision in the umbilicus and the tumor located in the middle of the transverse colon (arrow head); B, StO<sub>2</sub> measurements were obtained at two points (proximal and distal sides of the anastomosis) on the antimesenteric position of the intestine before and after mesenteric dissection; C, after resecting the rectum, the proximal stump was raised outside the abdominal cavity through the umbilical incision; D, StO<sub>2</sub> of the anastomotic proximal side of the colorectum after mesenteric dissection.

We routinely apply the technique to preserve LCA, so-called low tie, when performing low anterior resection. The low tie technique allows for an adequate blood supply to the proximal site of the anastomosis, whereas with division of the IMA proximal to the LCA (the so-called high tie), the vascularization of the left colon depends completely on the middle colic and marginal arteries [8]. High tie may compromise the blood supply, especially in mesenteric blood flow disorders, obesity and elderly cases, and may increase postoperative complications [9]. Moreover, extensive dissection of lymphatic tissues over the origin of the IMA will most likely injure the autonomic nerve plexus, which forms a dense network around the IMA, and, thus, could impair genitourinary function [10] and leads to a long denervated colon segment, causing defecatory dysfunction [11]. On the other hand, D3 lymph node dissection with preservation of the LCA can be performed with quick functional recovery, thus alleviating disorders for patients with distal rectal cancer and reducing the risk of colorectal anastomotic leakage [12]. Maintaining blood supply to the proximal colon with LCA preservation can prevent anastomotic leakage with distal rectal cancer surgery requiring considerably lower colorectal anastomosis [13]. In addition, the strategy of low tie makes sense oncologically because it has been shown that this level of IMA tie actually has no effect on patient survival rates despite the greater number of lymph nodes that can be harvested after high tie of the IMA [14].

The aforementioned articles provide insufficient evidence to support high tie as the first choice in resection surgeries; furthermore, high tie has been proven to result in decreased perfusion and innervation to the proximal limb. In addition, since the MCA

is divided when transverse colon resection is performed, by using the high tie strategy, blood flow from the marginal artery is also blocked. However, it is anatomically difficult to anastomose the ascending colon and the rectum when performing transverse colon resection and left hemicolectomy. Moreover, tension on the anastomosis is thought to increase the risk of anastomotic leakage [15]. Since overall survival is not improved by dividing the IMA at its origin, it is not useful to perform the left hemicolectomy with the high tie technique. Therefore, in some cases, the low tie strategy preserving the LCA may be the preferred method, as in the present case.

We measured StO<sub>2</sub> at two points (proximal and distal sides of the anastomosis) on the antimesenteric position of the intestine both before and after mesenteric dissection. Low StO<sub>2</sub> less than 60% on both sides of the anastomosis may indicate an increased risk of anastomotic complications [2]. Moreover, we measured StO<sub>2</sub> before and after MCA and mesenteric dissection and made judgments based on the rate of change. In the present case, blood flow was good in the colo-colo anastomosis on both proximal and distal sides. The blood flow of the proximal side is supplied via the marginal artery, while the distal side is supplied solely from the LCA, thus by dividing the MCA, the decrease in the StO<sub>2</sub> is expected to be extensive. Since the colorectal anastomosis was performed by laparoscopy, it was impossible to measure StO<sub>2</sub> before the mesenteric dissection; however, the anastomosis was performed, because the StO<sub>2</sub> of the proximal side of the anastomosis was greater than 70% [2].

#### 4. Conclusion

We herein reported a case in which surgical resection with preservation of the LCA was performed safely by using NIRS to evaluate the blood flow at the anastomotic site.

NIRS is not only safe, it is also a simple and low-cost method for assessing blood flow intraoperatively. Moreover, this technology could have great implications for use in various other surgeries.

#### Conflict of interest

None.

#### Funding

This research did not receive any specific grant from funding agencies in the public, commercial, or not-for-profit sectors.

#### Ethical approval

The procedure was approved by the Ethics Committee at the Hiroshima University.

#### Consent

Written informed consent was obtained from the patient for publication of this case report and any accompanying images.

#### Author contributions

**Masateru Yamamoto** contributed to conception of study, acquisition of data, analysis and interpretation of data, drafting the article. **Hiroyuki Egi** contributed to conception of study, management of case, revision of article. **Masatoshi Kochi** and **Shoichiro Mukai** contributed to acquisition of data, analysis of data. **Hideki Ohdan** contributed to final approval of the version to be submitted.

#### Registration of research studies

Not applicable.

#### Guarantor

Hiroyuki Egi.

#### Acknowledgements

All authors performed this procedure. This study was not funded by any grants. We would like to thank Editage ([www.editage.jp](http://www.editage.jp)) for English language editing.

#### References

- [1] F.J. Huttner, R. Warschkow, B.M. Schmied, M.K. Diener, I. Tarantino, A. Ulrich, Prognostic impact of anastomotic leakage after elective colon resection for cancer – a propensity score matched analysis of 628 patients, *Eur. J. Surg. Oncol.* (2018).
- [2] Y. Hirano, K. Omura, Y. Tatsuzawa, J. Shimizu, Y. Kawaura, G. Watanabe, Tissue oxygen saturation during colorectal surgery measured by near-infrared spectroscopy: pilot study to predict anastomotic complications, *World J. Surg.* 30 (3) (2006) 457–461.
- [3] M. Kawasuji, T. Yasuda, S. Tomita, N. Sakakibara, H. Takemura, Y. Watanabe, Near-infrared monitoring of myocardial oxygenation during intermittent warm blood cardioplegia, *Eur. J. Cardio Thorac. Surg.* 12 (2) (1997) 236–241.
- [4] J.M. Murkin, S.J. Adams, E. Parady, M. Quantz, F.N. McKenzie, L. Guo, Monitoring brain oxygen saturation during coronary bypass surgery improves outcomes in diabetic patients: a post hoc analysis, *Heart Surg. Forum* 14 (1) (2011) E1–6.
- [5] R.A. Agha, A.J. Fowler, A. Saeta, I. Barai, S. Rajmohan, D.P. Orgill, The SCARE statement: consensus-based surgical case report guidelines, *Int. J. Surg.* (Lond., Engl.) 34 (2016) 180–186.
- [6] L. Urbanavicius, P. Pattyn, D.V. de Putte, D. Venskutonis, How to assess intestinal viability during surgery: a review of techniques, *World J. Gastrointest. Surg.* 3 (5) (2011) 59–69.
- [7] B. Vollmar, M.D. Menger, Intestinal ischemia/reperfusion: microcirculatory pathology and functional consequences, *Langenbeck's Arch. Surg.* 396 (1) (2011) 13–29.
- [8] Y.J. Kawamura, M. Sakuragi, K. Togashi, M. Okada, H. Nagai, F. Konishi, Distribution of lymph node metastasis in T1 sigmoid colon carcinoma: should we ligate the inferior mesenteric artery? *Scand. J. Gastroenterol.* 40 (7) (2005) 858–861.
- [9] J. Hida, K. Okuno, High ligation of the inferior mesenteric artery in rectal cancer surgery, *Surg. Today* 43 (1) (2013) 8–19.
- [10] J.T. Liang, H.S. Lai, P.H. Lee, K.J. Chang, Laparoscopic pelvic autonomic nerve-preserving surgery for sigmoid colon cancer, *Ann. Surg. Oncol.* 15 (6) (2008) 1609–1616.
- [11] K. Koda, N. Saito, K. Seike, K. Shimizu, C. Kosugi, M. Miyazaki, Denervation of the neorectum as a potential cause of defecatory disorder following low anterior resection for rectal cancer, *Dis. Colon Rectum* 48 (2) (2005) 210–217.
- [12] M. Kobayashi, K. Okamoto, T. Namikawa, T. Okabayashi, K. Araki, Laparoscopic lymph node dissection around the inferior mesenteric artery for cancer in the lower sigmoid colon and rectum: is D3 lymph node dissection with preservation of the left colic artery feasible? *Surg. Endosc.* 20 (4) (2006) 563–569.
- [13] M. Nano, H. Dal Corso, M. Ferronato, M. Solej, J.P. Hornung, M. Dei Poli, Ligation of the inferior mesenteric artery in the surgery of rectal cancer: anatomical considerations, *Digest. Surg.* 21 (2) (2004) 123–126, discussion 6–7.
- [14] J.T. Liang, H.S. Lai, Surgical technique of robotic D3 lymph node dissection around the inferior mesenteric artery with preservation of the left colic artery and autonomic nerves for the treatment of distal rectal cancer, *Surg. Endosc.* 28 (5) (2014) 1727–1733.
- [15] M.M. Lange, M. Buunen, C.J. van de Velde, J.F. Lange, Level of arterial ligation in rectal cancer surgery: low tie preferred over high tie. A review, *Dis. Colon Rectum* 51 (7) (2008) 1139–1145.

#### Open Access

This article is published Open Access at [sciedirect.com](http://sciedirect.com). It is distributed under the [IJSCR Supplemental terms and conditions](#), which permits unrestricted non commercial use, distribution, and reproduction in any medium, provided the original authors and source are credited.