

## FOCUS ON: CHEST

Monday 16 October 2006, 14:00–15:30

# Solitary pulmonary nodule: detection and management

S Diederich\* and M Das†

\*Department of Diagnostic and Interventional Radiology and Nuclear Medicine, Marien Hospital, Düsseldorf, Germany; †Department of Diagnostic Radiology, RWTH Aachen University, Aachen, Germany

Corresponding address: Prof Dr med. Stefan Diederich, Department of Diagnostic and Interventional Radiology and Nuclear Medicine, Marien Hospital, Academic Teaching Hospital, Rochusstr. 2, D-40479 Düsseldorf, Germany. E-mail: s.diederich@marien-hospital.de

### Abstract

Pulmonary nodules are commonly detected at computed tomography (CT) of the chest. More than 95% are  $\leq 10$  mm; of these more than 95% are benign. Visual detection of pulmonary nodules by human readers is suboptimal, particularly with small nodules  $\leq 10$  mm. Computer-assisted detection can improve sensitivity and diagnostic confidence. Due to the high proportion of malignant lesions in nodules  $> 10$  mm immediate, often invasive work-up is required including contrast-enhanced dynamic CT, positron emission tomography (PET) or biopsy. However, in nodules  $\leq 10$  mm the high proportion of benign lesions requires a non-invasive work-up usually based on follow-up with unenhanced CT. Invasive procedures are only required for growing nodules. Stable nodules require further follow-up and decreasing nodules are considered benign.

**Keywords:** Lung cancer; metastases; computer-assisted diagnosis; volumetry; contrast-enhanced CT; biopsy.

### Introduction

Pulmonary nodules are a common radiological finding. In recent studies of low radiation dose unenhanced computed tomography (low-dose CT) in risk groups for lung cancer, spiral CT demonstrated non-calcified nodules in up to 66% of asymptomatic smokers with no history of malignancy. The proportion of individuals with nodules was higher with thin slice thickness and use of multidetector CT<sup>[1–10]</sup>.

The proportion of non-smokers or children with nodules is not precisely known but CT performed in these groups also frequently shows pulmonary nodules.

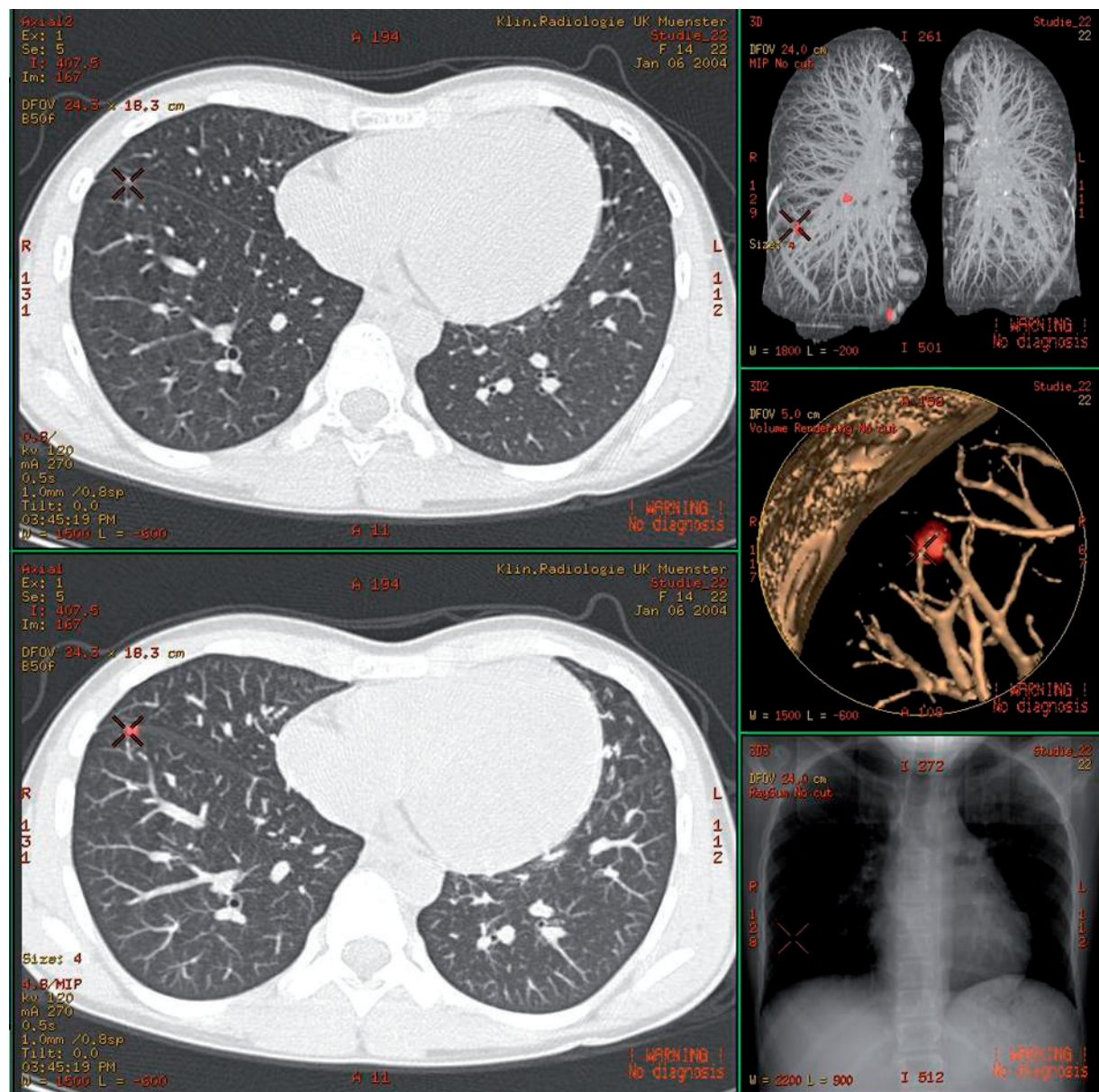
### Detection

Sensitivity for pulmonary nodules differs with different imaging modalities. Whereas the sensitivity of chest radiography is relatively low (solitary nodule rarely detected if  $< 5$  mm, 50% detected if 6–10 mm, may be missed even if as large as 35 mm)<sup>[11–13]</sup>, magnetic resonance imaging (MRI) is more sensitive with sensitivities of  $> 50\%$  for nodules  $> 5$  mm and almost 100% for nodules  $> 10$  mm<sup>[14,15]</sup>.

Computed tomography (CT), particularly spiral multidetector CT (MDCT) is the method of choice for detection of pulmonary nodules. In a study using surgical exploration of deflated lungs as the gold standard, even single slice spiral CT had a sensitivity of 95% for nodules  $> 5$  mm and 100% for nodules  $> 10$  mm<sup>[16]</sup>. MDCT has been shown to reveal nodules as small as 1–2 mm<sup>[17]</sup>. The good sensitivity is maintained with low radiation dose CT protocols<sup>[18–20]</sup>.

On the other hand, not every nodule exhibited by CT is actually diagnosed by the reporting radiologist. Nodules may be missed due to errors of detection (e.g. lack of concentration) and interpretation (e.g. confusion between nodules and vascular cross-sections)<sup>[11,13]</sup>.

It has been demonstrated, that in small nodules ( $\leq 10$  mm) the sensitivity of individual readers is only 60–70% depending on the nodule size, the expertise of the readers, the time allowed for the assessment, and viewing mode (monitor vs. film)<sup>[21–23]</sup>. Furthermore, this proportion has not significantly improved with multidetector technology, thinner slices or monitor reporting—the better spatial resolution may be compensated by the higher number of images.



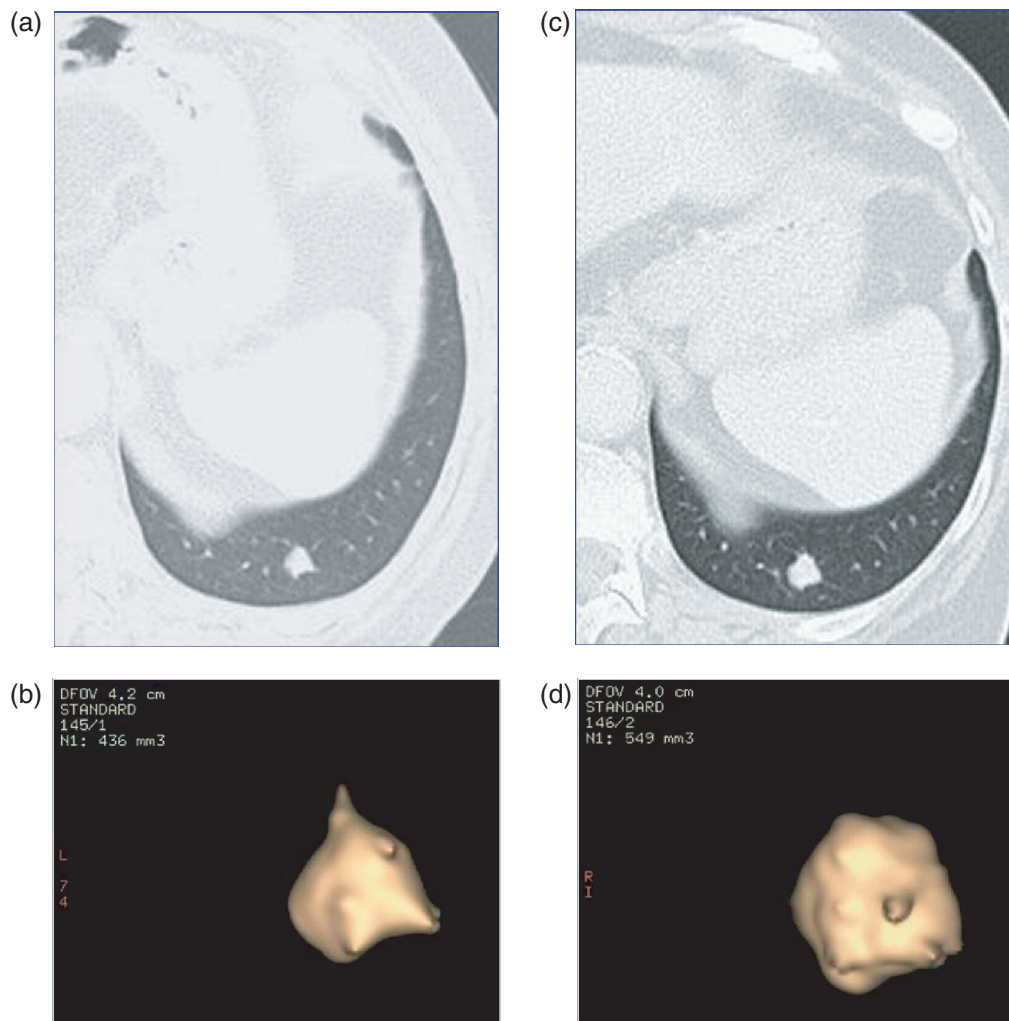
**Figure 1** Computer-assisted detection of pulmonary nodules. Screenshot of a commercially available software tool for automated detection (LungVCAR, GE Healthcare, Milwaukee, WI) providing: 3D-volume with red dot marking every detected nodule (top right), axial image (top left), thin-slab maximum intensity projection (TS-MIP) (bottom left), targeted 3D-reconstruction of nodule and adjacent structures (mid right), simulated scout view (bottom right).

Recently, computer-assisted detection (CAD) of pulmonary nodules has become available (Fig. 1). The technique is based on automatic identification of nodules as relatively round areas of increased density compared to surrounding lung with lower density. Adequate software algorithms allow differentiation between nodules and other areas of soft tissue attenuation with different shapes (vessels, mediastinum, chest wall). It has been shown that the application of these tools can increase the sensitivity of individual human readers for pulmonary nodules, particularly when small and central. This applies to readers with different degrees of experience but is most pronounced in relatively inexperienced readers. CAD and

visual reading is more sensitive than double reading by humans. This is probably due to the fact that humans tend to detect and miss the same nodules whereas CAD and humans detect and miss different nodules. At present, automated CAD tools should only be used in conjunction with visual reading due to false positive and false negative results<sup>[23–27]</sup>.

## Characterisation

Once detected, the key question for management of pulmonary nodules is their characterisation. More than a hundred different histological entities may present as



**Figure 2** Computer-assisted volumetry of a pulmonary nodule in a patient with colorectal cancer. (a) Thin-section CT: well-defined non-calcified pulmonary nodule in the posterobasal segment of the left lower lobe with a diameter of 9 mm; (b) computer-assisted volumetry of the nodule (LungVCAR, GE Healthcare, Milwaukee, WI) demonstrating a nodule volume of 436 mm<sup>3</sup>; (c) thin-section CT 6 months later: questionable growth of the nodule; (d) computer-assisted volumetry of the nodule demonstrating a nodule volume of 549 mm<sup>3</sup> corresponding to an increase in volume of 26%.

pulmonary nodules, however, in clinical practice, the single most important issue is the classification into benign or malignant lesions. Malignant nodules usually require therapy such as resection, chemotherapy or radiation therapy, whereas benign nodules are usually not treated.

Several features have been analysed in the hope of making this differentiation. In subjects with no history of previous malignancy only the person's age (<30 years), the presence of benign patterns of calcification (diffuse, peripheral, popcorn) and the presence of fat (hamartoma, lipoid pneumonia) allow reliable exclusion of malignancy. Other demographic (age >40, 60 years, etc., smoking habits) or morphologic (well-defined vs. ill-defined, smooth vs. lobulated contour, apical vs. basal or peripheral vs. central localisation etc.) features are not reliable in differentiating between benign and malignant lesions.

Nodule diameter, however, correlates with the likelihood of malignancy with a threshold of 10 mm detected empirically: 50% of nodules >10 mm are malignant, whereas less than 5% of nodules ≤10 mm are malignant<sup>[28]</sup>.

Several studies have shown that malignant nodules usually enlarge over time<sup>[4,29,30]</sup>. Typically, the nodule volume doubles within 30–400 days, whereas the volume in benign nodules doubles faster (e.g. inflammatory nodules) or slower (e.g. hamartomas). There is, however, an overlap in volume doubling times of benign and malignant nodules. In addition, doubling of the volume represents an increase in diameter of only 26%, e.g. growth from 4 to 5 mm, which may be difficult to detect visually. Again, computer-assisted diagnosis, namely volumetry can be applied to detect enlargement of nodules more precisely and, thus, earlier (Fig. 2(a)–(d))<sup>[31–33]</sup>.

However, it has been shown that accuracy and particularly reproducibility of volumetric measurements differs between different scanning protocols, CT scanners, software tools and versions and also between different nodule types (well-defined vs. ill-defined, adjacent to chest wall, vessels or surrounded only by pulmonary parenchyma)<sup>[31,34,35]</sup>.

Also, two functional imaging techniques have been introduced which are useful for classification of nodules. Contrast-enhanced CT (CE-CT) is applied to assess the perfusion of the lesions. Studies by Swensen and co-authors have demonstrated that lack of enhancement has a high negative predictive value for malignancy. Therefore, a nodule with no or minimal enhancement can be considered benign<sup>[36]</sup>. This has also been shown when perfusion is studied with MRI.

Positron emission tomography (PET) using [<sup>18</sup>F]fluorodeoxyglucose (FDG) has a sensitivity and specificity of >70–80% for malignancy, although false positive (inflammatory lesions) and false negative (well-differentiated adenocarcinoma, carcinoid tumours, lesions <10 mm) findings have been reported. Unfortunately, these techniques are not appropriate for application in the huge numbers of small nodules due to the use of contrast media (CE-CT), cost, availability, radiation exposure and the limited use in nodules ≤10 mm (PET).

The definitive means to assess the nature of a nodule is histology obtained from bronchoscopic (in central lesions), percutaneous CT-guided (in peripheral lesions) biopsies or resection of the nodule at video-assisted thoracoscopic surgery (VATS).

## Conclusions

Pulmonary nodules are common. They are mostly small (≤10 mm) and benign, even in risk groups. Detection of nodules is limited at chest radiography, better at MRI and best at CT, particularly with multidetector technology. Visual reading is limited even when reporting thin-slice MDCT scans on a monitor. Sensitivity can be improved by computer-assisted detection.

Nodules ≤10 mm should be followed with unenhanced CT and computer-assisted volumetry applied if possible. Invasive procedures should only be performed for growing nodules. In nodules >10 mm a more invasive work-up is usually required, using CE-CT, PET or biopsy. Guidelines suggesting the diagnostic algorithm for nodules with different size classes have recently been published<sup>[37]</sup>.

## References

- [1] Diederich S, Wormanns D, Semik M *et al.* Screening for early lung cancer with low-dose spiral computed tomography: results of baseline examinations in 817 asymptomatic smokers. *Radiology* 2002; 222: 773.
- [2] Diederich S, Thomas M, Semik M *et al.* Screening for early lung cancer with low-dose spiral computed

- tomography: Results of annual follow-up examinations in asymptomatic smokers. *Eur Radiol* 2004; 14: 691.
- [3] Diederich S. Screening for early lung cancer with low-dose spiral computed tomography. *Lancet* 2003; 362: 588.
- [4] Hasegawa M, Sone S, Takashima S *et al.* Growth rate of small lung cancers detected on mass CT screening. *Br J Radiol* 2000; 73: 1252.
- [5] Henschke CI, McCauley DI, Yankelevitz DF *et al.* Early lung cancer action project. overall design and findings from baseline screening. *Lancet* 1999; 354: 99.
- [6] Kaneko M, Eguchi K, Ohmatsu H *et al.* Peripheral lung cancer: screening and detection with low-dose spiral-CT versus radiography. *Radiology* 1996; 201: 798.
- [7] Nawa T, Nakagawa T, Kusano S *et al.* Lung cancer screening using low-dose spiral CT. *Chest* 2002; 122: 15.
- [8] Pastorino U, Bellomi M, Landoni C *et al.* Early lung-cancer detection with spiral CT and positron emission tomography in heavy smokers: 2-year results. *Lancet* 2003; 362: 593.
- [9] Sone S, Takashima S, Li F *et al.* Mass screening for lung cancer with mobile spiral computed tomography scanner. *Lancet* 1998; 351: 1242.
- [10] Swensen SJ, Jett JR, Hartman TE *et al.* Lung cancer screening with CT: Mayo Clinic experience. *Radiology* 2003; 226: 756.
- [11] Austin JHM, Romney BM, Goldsmith LS. Missed bronchogenic carcinoma: radiographic findings in 27 patients with a potentially resectable lesion evident in retrospect. *Radiology* 1992; 182: 115.
- [12] Brogdon BG, Kelsey CA, Moseley RD Jr. Factors affecting perception of pulmonary lesions. *Radiol Clin North Am* 1983; 21: 633.
- [13] Gurney JW. Missed lung cancer at CT: imaging findings in nine patients. *Radiology* 1996; 199: 117.
- [14] Feuerstein IM, Jicha DL, Pass HI *et al.* Pulmonary metastases: MR imaging with surgical correlation. *Radiology* 1992; 182: 123.
- [15] Kersjes W, Mayer E, Buchenroth M, Schunk K, Fouda N, Cagil H. Diagnosis of pulmonary metastases with turbo-SE MR imaging. *Eur Radiol* 1997; 7: 1190.
- [16] Diederich S, Semik M, Lentschig MG *et al.* Helical CT of pulmonary nodules in patients with extrathoracic malignancy: CT-surgical correlation. *AJR* 1998; 172: 353.
- [17] Fischbach F, Knollmann F, Griesshaber V, Freund T, Akkol E, Felix R. Detection of pulmonary nodules by multislice computed tomography: improved detection rate with reduced slice thickness. *Eur Radiol* 2003; 13: 2378.
- [18] Diederich S, Lenzen H, Windmann R *et al.* Low-dose CT of pulmonary nodules: experimental and clinical studies. *Radiology* 1999; 213: 289.
- [19] Gartenschläger M, Schweden F, Gast K *et al.* Pulmonary nodules: detection with low-dose vs. conventional-dose spiral CT. *Eur Radiol* 1996; 8: 609.
- [20] Rusinek H, Naidich DP, McGuinness G *et al.* Pulmonary nodule detection: low-dose vs. conventional CT. *Radiology* 1998; 209: 243.
- [21] Seltzer SE, Judy PF, Adams DF *et al.* Spiral CT of the chest: comparison of cine and film-based viewing. *Radiology* 1995; 197: 73.
- [22] Tillich M, Kammerhuber F, Reittner P *et al.* Detection of pulmonary nodules with helical CT: comparison of cine and film-based viewing. *AJR* 1997; 169: 1611.

- [23] Wormanns D, Beyer F, Diederich S, Ludwig K, Heindel W. Diagnostic performance of a commercially available computer-aided diagnosis system for automatic detection of pulmonary nodules: comparison with single and double reading. *RöFo* 2004; 176: 953.
- [24] Marten K, Seyfarth T, Auer F *et al.* Computer-assisted detection of pulmonary nodules: performance evaluation of an expert knowledge-based detection system in consensus reading with experienced and inexperienced chest radiologists. *Eur Radiol* 2004; 14: 1930.
- [25] Marten K, Engelke C, Seyfarth T, Grillhosl A, Obenaus S, Rummeny EJ. Computer-aided detection of pulmonary nodules: influence of nodule characteristics on detection performance. *Clin Radiol* 2005; 60: 196.
- [26] Wormanns D, Fiebich M, Saidi M, Diederich S, Heindel W. Automatic detection of pulmonary nodules at spiral CT: clinical application of a computer-aided diagnosis system. *Eur Radiol* 2002; 12: 1052.
- [27] Wormanns D, Ludwig K, Beyer F, Heindel W, Diederich S. Detection of pulmonary nodules at multirow-detector CT: effectiveness of double reading to improve sensitivity at standard-dose and low-dose chest CT. *Eur Radiol* 2005; 15: 14.
- [28] Kim YH, Lee KS, Primack SL *et al.* Small pulmonary nodules on CT accompanying surgically resectable lung cancer: likelihood of malignancy. *J Thorac Imaging* 2002; 17: 40.
- [29] Shyu CL, Lee YC, Perng RP. Fast-growing squamous cell lung cancer. *Lung Cancer* 2002; 36: 199.
- [30] Yankelevitz DF, Henschke CI. Does 2-year stability imply that pulmonary nodules are benign? *Am J Roentgenol* 1997; 168: 325.
- [31] Marten K, Auer F, Schmidt S, Kohl G, Rummeny EJ, Engelke C. Inadequacy of manual measurements compared to automated CT volumetry in assessment of treatment response of pulmonary metastases using RECIST criteria. *Eur Radiol* 2006; 16: 781.
- [32] Revel MP, Bissery A, Bienvenu M, Aycard L, Lefort C, Frija G. Are two-dimensional CT measurements of small noncalcified pulmonary nodules reliable? *Radiology* 2004; 231: 453.
- [33] Revel MP, Lefort C, Bissery A *et al.* Pulmonary nodules: preliminary experience with three-dimensional evaluation. *Radiology* 2004; 231: 459.
- [34] Go JM, Tongdee T, Tongdee R, Yeo K, Hildebold CF, Bae KT. Volumetric measurement of synthetic lung nodules with multi-detector row CT: effect of various image reconstruction parameters and segmentation thresholds on measurement accuracy. *Radiology* 2005; 235: 850.
- [35] Wormanns D, Kohl G, Klotz E *et al.* Volumetric measurements of pulmonary nodules at multi-detector CT: in vivo reproducibility. *Eur Radiol* 2004; 14: 86.
- [36] Swensen SJ, Viggiano RW, Midhun DE *et al.* Lung nodule enhancement at CT: Multicenter study. *Radiology* 2000; 214: 73.
- [37] MacMahon H, Austin JHM, Gamsu *et al.* Guideline for management of small pulmonary nodules detected on CT scans: a statement from the Fleischner Society. *Radiology* 2005; 237: 395.