



Since January 2020 Elsevier has created a COVID-19 resource centre with free information in English and Mandarin on the novel coronavirus COVID-19. The COVID-19 resource centre is hosted on Elsevier Connect, the company's public news and information website.

Elsevier hereby grants permission to make all its COVID-19-related research that is available on the COVID-19 resource centre - including this research content - immediately available in PubMed Central and other publicly funded repositories, such as the WHO COVID database with rights for unrestricted research re-use and analyses in any form or by any means with acknowledgement of the original source. These permissions are granted for free by Elsevier for as long as the COVID-19 resource centre remains active.



Letter to the Editor

Favourable outcome of coronavirus disease 2019 in a patient with anaplastic lymphoma kinase-positive non-small-cell lung cancer receiving alectinib

Michele Montrone ^{a,*}, Annamaria Catino ^a, Vincenzo O. Palmieri ^b, Vito Longo ^a, Domenico Galetta ^a

^a Medical Thoracic Oncology Unit, IRCCS Istituto Tumori “Giovanni Paolo II”, Bari, Italy

^b Division of Internal Medicine, Clinica Medica “Augusto Murri”, Department of Biomedical Sciences and Human Oncology, University of Bari Medical School, Piazza Giulio Cesare, 11, 70124, Bari, Italy

Received 3 June 2020; received in revised form 11 July 2020; accepted 26 July 2020

Available online 11 August 2020

Dear Editor,

Since February 21, 2020, when the first Italian patient was admitted to the hospital due to severe coronavirus disease 2019 (COVID-19) and found positive to the severe acute respiratory syndrome coronavirus 2 (SARS-CoV-2), this infection has spread through Italy, quickly becoming the largest COVID-19 outbreak outside Asia [1]. On March 12th, the World Health Organisation (WHO) declared COVID-19 a pandemic, placing the WHO European Region at the centre of the pandemic. Elderly people and those with pre-existing health conditions are most at risk of life-threatening complications [2].

A study published before this pandemic showed higher mortality from viral pneumonia in patients with cancer compared with patients without cancer, particularly from parainfluenza virus and coronavirus [3]. The number of patients with lung cancer and SARS-CoV-2

infection could be underestimated because the test is not routinely performed in all symptomatic patients and the number of tests performed is not homogeneous even within a single nation such as Italy, as reported by Carbone et al [4]; therefore, a large group of patients with lung cancer may be positive but not recognised as such.

An interesting report on 1590 Chinese patients showed that, among them, 18 had a history of cancer (1%) with lung cancer as the most frequent type (28%) and 25% received surgery or chemotherapy in the last month [5].

Here, we report the case of a 69-year-old male patient affected by non-squamous stage IV anaplastic lymphoma kinase (ALK)-positive non-small-cell lung cancer (NSCLC) treated with first-line alectinib, admitted on March 15 2020 to the emergency room of the local general hospital due to worsening dyspnoea, hacking cough and low-grade fever (37,5 C), unresponsive to acetaminophen and severe respiratory failure.

Therapy with alectinib started as first line at diagnosis in November 2018 and achieved partial response as the best response after 3 months. Response was still documented at the last computed tomography (CT) scan performed in February 2020 (Fig. 1A and B).

* Corresponding author: Medical Thoracic Oncology Unit, IRCCS Istituto Tumori “Giovanni Paolo II”, Viale Orazio Flacco, 65, Bari, 70124, Italy

E-mail address: m.montrone@oncologico.bari.it (M. Montrone).

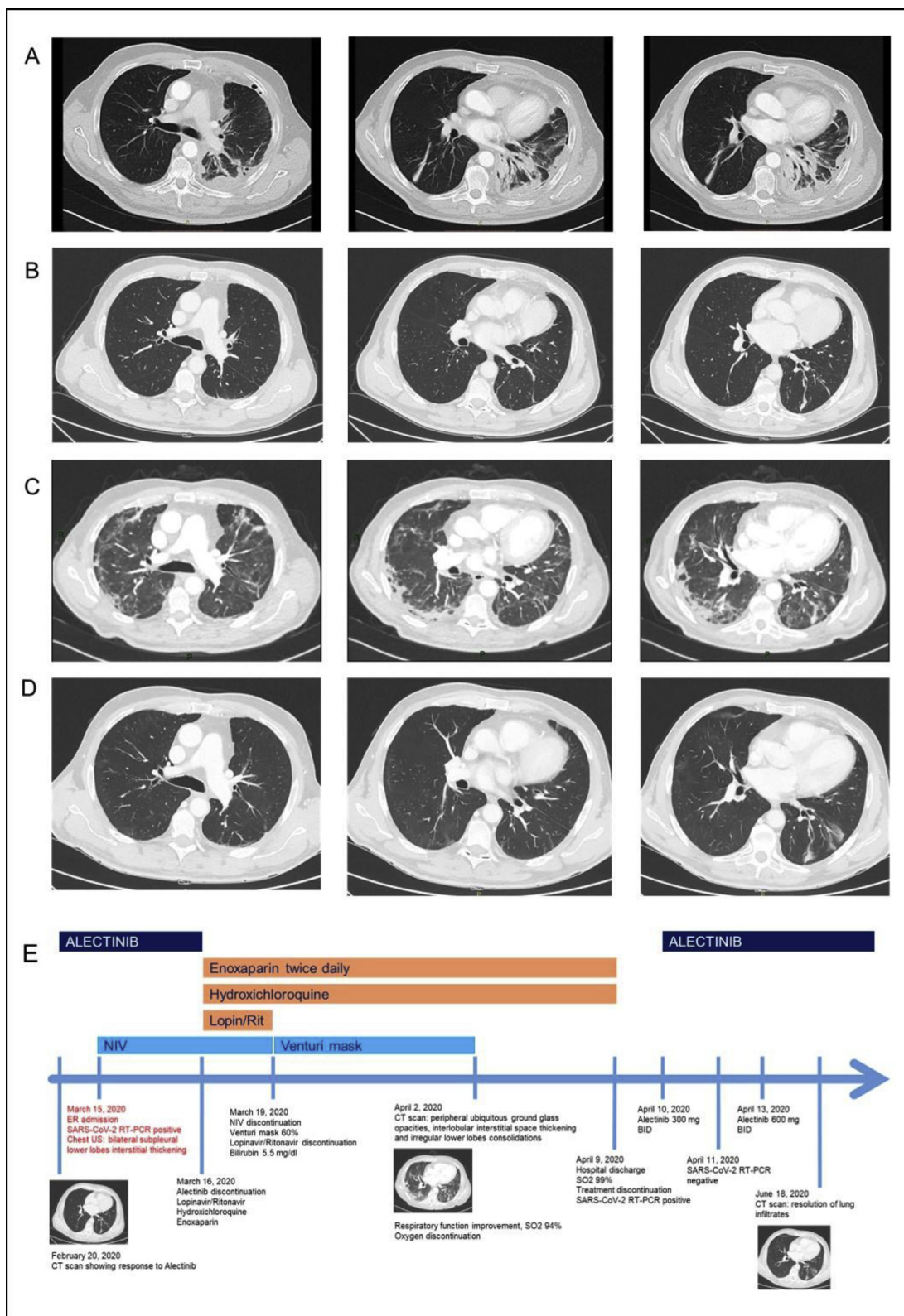


Fig. 1. A) CT scan findings at diagnosis of NSCLC. (B) CT scan findings before SARS-CoV-2 infection obtained 20 days before hospital admission, showing persistent response to alectinib. (C) CT scan findings during hospitalisation. (D) CT scan finding obtained two months after hospital discharge showing an almost complete resolution of lung infiltrates due to COVID-19; no clear radiological signs of cancer disease progression are evident. (E) Timeline summary displaying the clinical and radiological evolution of the disease. Lopin/Rit = lopinavir/ritonavir; CT = computed tomography; COVID-19 = coronavirus disease 2019; NSCLC = non-small-cell lung cancer; SARS-CoV-2 = severe acute respiratory syndrome coronavirus 2.

At hospital admittance, chest ultrasound showed bilateral subpleural interstitial thickening at lower lobes. Non-invasive ventilation (NIV) started soon due to severe hypoxia, and a throat swab was found positive for SARS-CoV-2 by real-time polymerase chain reaction (RT-PCR). Laboratory tests showed mild leucocytosis and a slight increase in C-reactive protein. Alectinib was stopped and treatment with lopinavir/ritonavir coupled with hydroxychloroquine and twice daily subcutaneous enoxaparin started. Lopinavir/Ritonavir was discontinued after three days, given the increase of total serum bilirubin levels (5.5 mg/dl). NIV continued for other 4 days, followed by Venturi mask at 60% with progressive respiratory improvement. Hydroxychloroquine and enoxaparin continued during hospitalisation. A CT scan on April 2 2020 showed peripheral ubiquitous ground glass opacities, interlobular interstitial space thickening and irregular lower lobes consolidations, more evident at the right lower lobe (Fig. 1C).

Respiratory function gradually improved, and no other signs or symptoms of infection emerged, including fever. The patient was finally discharged on April 09 2020, without symptoms and with oxygen saturation of 99%. No therapy was further suggested at home, and hydroxychloroquine was stopped. The first throat swab before patient discharge was still positive at RT-PCR; conversely, a second one performed few days after was found negative.

Alectinib was restarted the day after discharge at half dose for three days and then at full dose, without reporting any significant adverse event.

A new CT scan performed on June 18 2020 during the lung cancer follow-up showed an almost complete resolution of the lung infiltrates (Fig. 1D). At the last follow-up visit, the patient was still receiving alectinib at full dose without any symptom related to COVID-19 or NSCLC.

This is, to the best of our knowledge, the first reported case of ALK-positive advanced NSCLC successfully treated with alectinib developing SARS-CoV-2 infection and COVID-19 with severe respiratory failure during targeted therapy and reporting a favourable outcome.

Cancer is frequently associated with COVID-19, and lung cancer has been referred as the most frequent type among a large Chinese population; the 25% of patients with cancer received surgery or chemotherapy in the month before infection [5]. However, few cases of COVID-19 in patients with cancer have been reported to date.

Zhang et al [6] recently described the case of a patient with epidermal growth factor receptor-mutant NSCLC treated with osimertinib during COVID-19, demonstrating the potential of continuing targeted therapy

without any safety concern and maintaining response to osimertinib.

Conversely, a fatal and rapid evolution of COVID-19 has been reported in a patient with adenocarcinoma treated for a long time with nivolumab as second line [7], suggesting a deleterious effect of PD1/PDL1 blockade during infection. This could be due to overlapping immunotherapy-related lung toxicity and interstitial pneumonitis determined by SARS-CoV-2 or to enhanced immune function with immune-mediated lung injury facilitated by a ‘cytokine storm’ described during infection [8].

More recently, two cases of suspected SARS-CoV-2 infection have been described in an ALK-positive and a c-ros oncogene 1 (ROS1)-positive NSCLC receiving targeted therapy [9]. In both cases, RT-PCR on a nasopharyngeal swab was negative, even if radiological signs and symptoms were highly suspicious for infection. Targeted agents, alectinib and lorlatinib, were not discontinued [9].

In our case, first-line alectinib achieved a prompt radiological partial remission and a meaningful clinical improvement, persisting for 15 months until the occurrence of COVID-19. The patient experienced a favourable clinical evolution of COVID-19 without any significant worsening of NSCLC after a 20-day break of the targeted agent. It has been also remarkable that no safety issues have emerged at the resumption of alectinib, despite the increase of bilirubin serum level observed during antiviral treatment. However, we suggest caution during the coadministration of alectinib and lopinavir/ritonavir, given their inhibitory effect on CYP3A cytochrome with potential increased exposure to alectinib during the coadministration with hydroxychloroquine due to potential QTc prolongation.

Treatment guidance during the COVID-19 pandemic has been published [10], but no guideline has been published to date for the treatment of NSCLC during SARS-CoV-2 infection and COVID-19 in selected population as patients with oncogene-addicted cancers receiving targeted agents.

No definitive conclusion about alectinib treatment during SARS-CoV-2 infection and COVID-19 can be drawn by this case. Caution has to be suggested in symptomatic patients and those with life-threatening complications. Decision on continuing targeted agent must be carefully taken case by case, discussing also the potential interaction with other drugs administered to treat COVID-19 to avoid dangerous exposure.

No safety issues emerged about alectinib during SARS-CoV-2 infection.

Conflict of interest statement

None declared.

References

- [1] Spina S, Marrazzo F, Migliari M, Stucchi R, Sforza A, Fumagalli R. The response of milan's emergency medical system to the COVID-19 outbreak in Italy. *Lancet* 2020;395(10227): e49–50. [https://doi.org/10.1016/S0140-6736\(20\)30493-1](https://doi.org/10.1016/S0140-6736(20)30493-1).
- [2] WHO announces COVID-19 outbreak a pandemic. Published March 12, 2020. Accessed April 17, 2020. <http://www.euro.who.int/en/health-topics/health-emergencies/coronavirus-covid-19/news/news/2020/3/who-announces-covid-19-outbreak-a-pandemic>.
- [3] Kim Y-J, Lee ES, Lee Y-S. High mortality from viral pneumonia in patients with cancer. *Infectious Diseases* 2019;51(7):502–9. <https://doi.org/10.1080/23744235.2019.1592217>.
- [4] Carbone M, Green JB, Bucci EM, Lednický JJ. Editorial: coronaviruses: facts, myths and hypotheses. *J Thorac Oncol* 2020. <https://doi.org/10.1016/j.jtho.2020.02.024>. Published online March 5.
- [5] Liang W, Guan W, Chen R, Wang W, Li J, Xu K, et al. Cancer patients in SARS-CoV-2 infection: a nationwide analysis in China. *Lancet Oncol* 2020;21(3):335–7. [https://doi.org/10.1016/S1470-2045\(20\)30096-6](https://doi.org/10.1016/S1470-2045(20)30096-6).
- [6] Zhang H, Huang Y, Xie C. The treatment and outcome of a lung cancer patient infected with SARS-CoV-2. *J Thorac Oncol* 2020. <https://doi.org/10.1016/j.jtho.2020.02.025>. Published online March 5.
- [7] Bonomi L, Ghilardi L, Arnoldi E, Tondini CA, Bettini AC. A rapid fatal evolution of Coronavirus Disease-19 (COVID-19) in an advanced lung cancer patient with a long time response to nivolumab. *J Thorac Oncol* 2020. <https://doi.org/10.1016/j.jtho.2020.03.021>.
- [8] Xu Z, Shi L, Wang Y, Zhang J, Huang L, Zhang C, et al. Pathological findings of COVID-19 associated with acute respiratory distress syndrome. *Lancet Respir Med* 2020;18. [https://doi.org/10.1016/S2213-2600\(20\)30076-X](https://doi.org/10.1016/S2213-2600(20)30076-X). Published online February.
- [9] Leonetti A, Facchinetti F, Zielli T, Brianti E, Tiseo M. COVID-19 in lung cancer patients receiving ALK/ROS1 inhibitors. *Eur J Canc* 2020;132:122–4. <https://doi.org/10.1016/j.ejca.2020.04.004>.
- [10] Dingemans A-MC, Soo RA, Jazieh AR, Rice SJ, Kim YT, Teo LLS, et al. Treatment guidance for lung cancer patients during the COVID-19 pandemic. *J Thorac Oncol* 2020. <https://doi.org/10.1016/j.jtho.2020.05.001>.