

Trisomy 22 with long spina bifida occulta

A case report

Li Ma, MD^a, Yunshu Ouyang, MD^a, Qingwei Qi, MD^b, Na Hao, MD^b, Dachun Zhao, MD^c, Yuxin Jiang, MD^a, Hua Meng, MD^{a,*}

Abstract

Introduction: Complete non-mosaic trisomy 22 is a fatal chromosomal disorder that only few fetuses can survive over 12 weeks as reported. Prenatal sonographic findings combined with postnatal or postmortem discoveries showed characteristic multi-systematic anomalies.

Patient concerns: The unborn baby of a 35-year-old pregnant woman was found to have several anomalies during a prenatal sonographic scan, including intrauterine growth retardation, ventricular septal defect, flat facial profile, and unclear bilateral kidney structures.

Diagnoses: The fetus was diagnosed as having complete non-mosaic trisomy 22 by chromosomal analysis.

Interventions: The pregnancy was terminated at 24 weeks, and autopsy was permitted.

Outcomes: Postmortem examinations revealed additional long-sectional spina bifida occulta and imperforate anus.

Conclusions: This was the first time a case of spinal cord defect was reported in trisomy 22 fetuses. More attention should be paid to the spinal cord during sonographic examinations in trisomy 22 fetuses.

Abbreviations: CRL = crown-rump length, IUGR = intrauterine growth retardation, NT = nuchal translucency, VSD = ventricular septal defect.

Keywords: postmortem examinations, spina bifida occulta, trisomy 22

1. Introduction

Trisomy 22 is a common chromosomal trisomy that causes spontaneous miscarriages, accounting for 3% to 5% of all miscarriages.^[1,2] Partial or mosaic trisomy 22 fetuses are more common and usually compatible with life. The complete non-mosaic type of trisomy 22 is extremely rare, and most fetuses with this condition cannot survive to the second or third trimester.^[3] The reported incidence of live births was reported to be 1 in 30,000 to 50,000 births, with a median survival after birth of only 4 days.^[4,5]

The prenatal sonographic features of complete non-mosaic trisomy 22 were summarized as early intrauterine growth

retardation (IUGR) with multi-systematic defects such as abnormal extremities, cardiovascular defects, special craniofacial traits, brain malformations, and genitourinary systems.^[6] However, owing to the inaccessibility to postmortem examinations in most fetuses, certain types of anomalies may still remain undercover. Here, we report a case of a complete non-mosaic trisomy 22 fetus with several prenatal sonographic scans and chromosomal analysis. The pregnancy was terminated at 24 gestational weeks. Postmortem examinations surprisingly revealed long-sectional spina bifida occulta, which has never been reported in trisomy 22 fetuses.

2. Case report

A 35-year-old Chinese woman, gravida 3, para 1, had regular pregnancy tests in our hospital. She had no personal, family, and psychosocial histories. Her first sonographic scan (at 7+5 gestational weeks) showed a normal embryo bud with regular heartbeats. The second dated scan at 12 gestational weeks suggested an increased nuchal translucency (NT) of 0.30 to 0.31 cm, with the crown-rump length (CRL) fitting the gestational weeks (5.61 cm). Chorionic villus sampling was performed immediately. The GTG-banded karyotype analysis showed the 47, XX, +22 karyotype in all the analyzed cells. Another test by amniocentesis further confirmed this genetic result. Her third sonographic scan was performed at 23+6 gestational weeks. The biometry of the fetus (biparietal diameter, 4.9 cm; head circumference, 18.6 cm; femoral length, 3.6 cm; abdominal circumference, 14.3 cm) was below the third percentile, suggesting severe IUGR. A number of structural abnormalities were also revealed, including a ventricular septal defect (VSD) with a width of 0.2 to 0.3 cm, flat facial profile, unclear bilateral kidney structures, and a rocker-bottom right foot (Fig. 1A, B). Owing to the decreased movement of the fetus, the orbit cavity and lens,

Editor: N/A.

Ethics and informed consent: Ethics approval is not applicable in this case report, since it is a retrospective, descriptive study with no treatment interventions to the patient. Autopsy was permitted by our patients' mother (the pregnant woman as described in the report) with formal documents signed. Consent to participate and publication of this case report was obtained from our patient's mother.

The authors have no conflicts of interest to disclose.

^a Department of Ultrasound, ^b Department of Obstetrics and Gynecology, ^c Department of Pathology, Peking Union Medical College Hospital, Chinese Academy of Medical Sciences, Beijing, China.

* Correspondence: Hua Meng, Department of Ultrasound, Peking Union Medical College Hospital, Chinese Academy of Medical Sciences, Beijing, 100730, China (e-mail: menghua_pumch@163.com).

Copyright © 2018 the Author(s). Published by Wolters Kluwer Health, Inc. This is an open access article distributed under the terms of the Creative Commons Attribution-Non Commercial-No Derivatives License 4.0 (CCBY-NC-ND), where it is permissible to download and share the work provided it is properly cited. The work cannot be changed in any way or used commercially without permission from the journal.

Medicine (2018) 97:39(e12306)

Received: 16 May 2018 / Accepted: 16 August 2018

<http://dx.doi.org/10.1097/MD.00000000000012306>

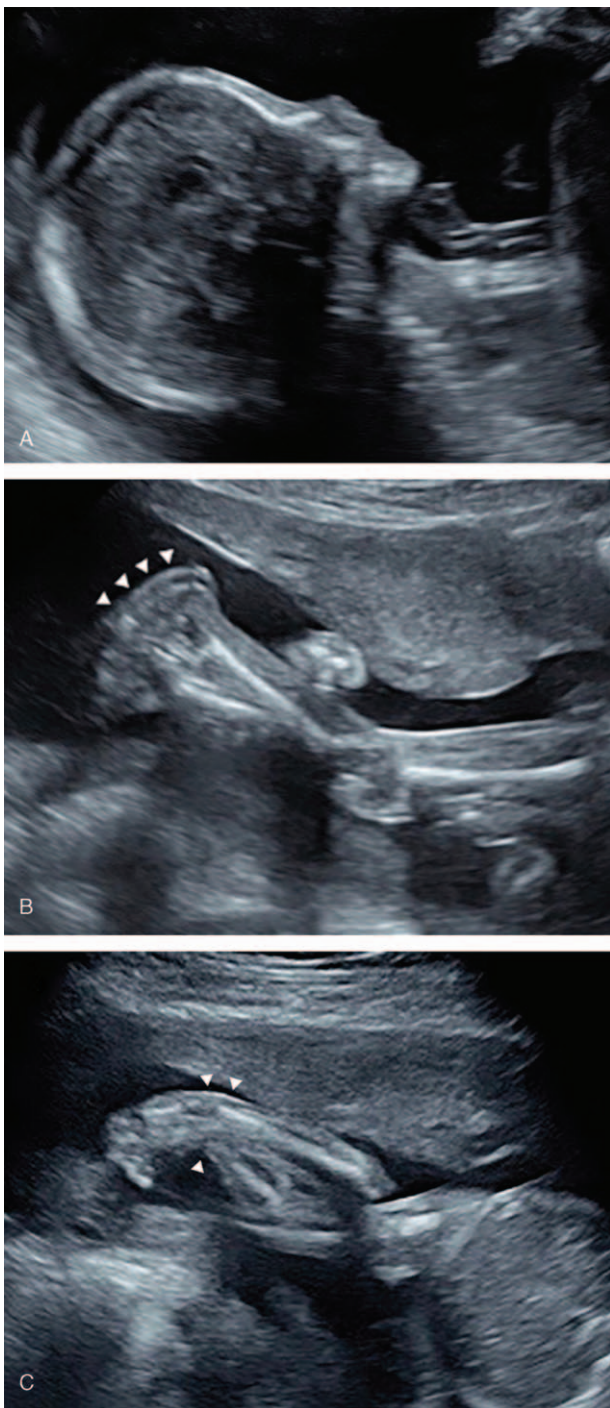


Figure 1. Prenatal sonography of the fetus with complete non-mosaic trisomy 22 at 23+6 gestational weeks. Selected deformities, such as flat facial profile (A), rocker-bottom foot (arrowheads) (B), and potential abnormal wrist position (arrowheads) (C) were showed here.

wrist position, stomach, and bladder were not clearly observed. These structures might have potential problems (Fig. 1C).

After genetic counseling, the woman decided to terminate the pregnancy at 24+5 gestational weeks. Postmortem examination was permitted. On physical examination, the fetus was found to be female with a flat facial profile, orbital hypertelorism, low-set ears, flat nasal bone and jawbone, a rocker-bottom right foot, a single transverse palm crease on the left hand, and a membranous imperforate anus (Fig. 2A). The wrist position tended to be

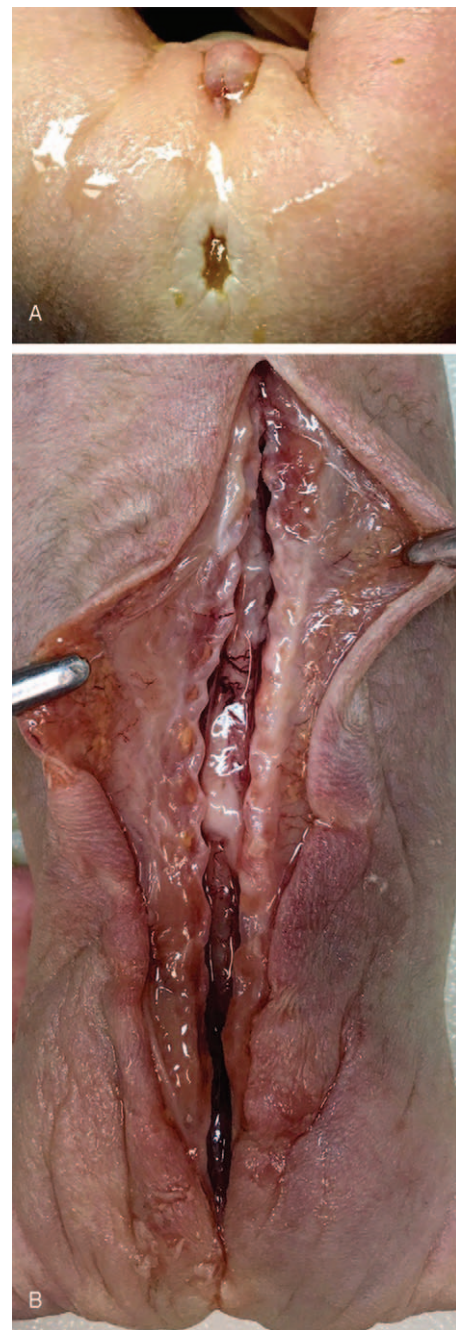


Figure 2. Postmortem examination of the fetus. Membranous imperforate anus (A) and long spina bifida occulta (B) were revealed.

normal. From the autopsy, the VSD and shrunken bilateral kidneys were found to be consistent with the sonographic results. A tiny bump but intact skin was noticed on the mid-line of the lower back. Surprisingly, cutting open the skin revealed severe spina bifida occulta from the thoracic vertebrae down to the coccygeal vertebrae (Fig. 2B).

3. Discussion

Complete non-mosaic trisomy 22 is a fatal autosomal anomaly. Owing to the high early abortion rate, only case reports that describe the features of complete non-mosaic trisomy 22 after the

second trimester were published, accumulating to no >40 cases worldwide. Prenatal sonographic features were summarized by Stressig et al^[6] in 2005 with 20 patients, delineating the characteristic abnormalities in 9 aspects, including IUGR, bilateral shortening of the femur, neck and skin abnormalities (increased NT and hydrops fetalis), cardiovascular diseases (VSD and atrial septal defect), craniofacial traits (cleft lip, a flat profile, microcephalus, and hypertelorism), cerebellar defects, renal anomalies, and gastrointestinal tract malformations. Sepulveda et al^[7] reviewed 4 reported cases along with 3 new cases, and collectively mentioned IUGR, congenital heart defects, hydrops fetalis, and renal agenesis as the prominent features. In the work of Schwendemann et al,^[8] 9 patients with trisomy 22 with sonographic scans between 10 and 20 weeks were reported to have only oligohydramnios, increased NT, IUGR, and cystic hygroma as main anomalies. However, probably because the sonographic scans were performed too early, many anomalies still remain to be discovered.

In our patient, several malformations were revealed by ultrasonography or autopsy, such as IUGR, VSD, flat facial profile and small kidneys, and membranous imperforate anus, as commonly reported in patients with non-mosaic trisomy 22. However, severe spina bifida occulta with a long split from the lower thoracic vertebrae to the coccygeal vertebrae was a predominant feature of our patient. This feature was only detected by autopsy. To our knowledge, spina bifida occulta has not been reported in fetuses with complete non-mosaic trisomy 22.

Spina bifida is caused by the infusion of the caudal neural tube and results as a cleft from the back vertebrae to the skin. Spina bifida occulta is the mildest form of spina bifida in that normally, only 1 or 2 vertebrae (mostly L5 or S1) are affected and the skin remains intact.^[9] The prevalence of spina bifida occulta is reported to be 15% to 41% in the healthy population.^[10,11] Unlike the mild malformations associated with ordinary spina bifida occulta, a long split from the lower thoracic vertebrae to the coccygeal vertebrae was observed in our patient. We believe this extended, rare lesions are associated with the trisomy 22 anomaly. Of the neurological malformations reported in trisomy 22, cerebellar defects are the most frequent features, followed by ventricle dilatation.^[6] As these defects were not observed in our patient, possibly independent mechanisms were suggested to lead to different neurological malformations.

Without obvious manifestations of open spina bifida, such as a sac with neural elements at the lumbar sites, disarrangements of the vertebrae and cranial features, including a lemon-shaped skull, ventriculomegaly, and Arnold-Chiari II malformation, sonographic detection of spina bifida occulta is difficult. In addition, the pathological lack of movement of the affected fetus further lowered the sensitivity of sonography. For these reasons, the detection of spina bifida occulta prenatally solely by ultrasonography was challenging. As in our patient, standard sectional planes for imaging the spinal cord were impossible to obtain because of the breech position and decreased movement of the fetus, which could partially explain the missed long spina bifida occulta by ultrasonography.

Among the published reports of trisomy 22, postmortem examinations were seldom permitted. The actual incidence of

spina bifida occulta in trisomy 22 is difficult to determine. Keeping the defects in mind when performing a sonographic scan may increase the detection rate. A longer dedicated scan time can also be useful. When necessary, a magnetic resonance imaging scan can be performed to reveal the underlying disease.

In conclusion, complete non-mosaic trisomy 22 embryos mostly ended up with early spontaneous abortion, and only few fetuses continued to grow until the second to third trimester. Rarely did any of the fetuses survived until labor and died in a few months. Identification of trisomy 22 at an early stage is crucial to the decision making for invasive measurements and to genetic counseling. Characteristic sonographic findings involve early IUGR along with multiple structural malformations. We present a case of a fetus with trisomy 22 detected on prenatal ultrasonography and postmortem autopsy to report for the first time the occurrence of long spina bifida occulta in trisomy 22. A more careful, longer sonographic scan, and referral to more experienced radiologists may increase the diagnostic accuracy of this rare anomaly.

Author contributions

Conceptualization: Hua Meng.

Investigation: Yunshu Ouyang.

Resources: Qingwei Qi, Na Hao, Dachun Zhao.

Supervision: Yuxin Jiang.

Writing – original draft: Li Ma.

Writing – review & editing: Hua Meng.

Li Ma orcid: 0000-0001-5380-0499

References

- [1] Menasha J, Levy B, Hirschhorn K, et al. Incidence and spectrum of chromosome abnormalities in spontaneous abortions: new insights from a 12-year study. *Genet Med* 2005;7:251–63.
- [2] Warburton D, Byrne JM, Canki N. *Chromosome Anomalies and Prenatal Development: An Atlas*. 1991;Oxford University Press,
- [3] Huderer-Duric K, Skrablin S, Kuvacic I, et al. The triple-marker test in predicting fetal aneuploidy: a compromise between sensitivity and specificity. *Eur J Obstet Gynecol Reprod Biol* 2000;88:49–55.
- [4] Punnett HH, Kistenmacher ML, Toro-Sola MA, et al. Quinacrine fluorescence and Giemsa banding in trisomy 22. *Theor Appl Genet* 1973;43:134–8.
- [5] Tinkle BT, Walker ME, Blough-Pfau RI, et al. Unexpected survival in a case of prenatally diagnosed non-mosaic trisomy 22: clinical report and review of the natural history. *Am J Med Genet A* 2003; 118A:90–5.
- [6] Stressig R, Kortge-Jung S, Hickmann G, et al. Prenatal sonographic findings in trisomy 22: five case reports and review of the literature. *J Ultrasound Med* 2005;24:1547–53.
- [7] Sepulveda W, Be C, Schnapp C, et al. Second-trimester sonographic findings in trisomy 22: report of 3 cases and review of the literature. *J Ultrasound Med* 2003;22:1271–5.
- [8] Schwendemann WD, Contag SA, Kory PP, et al. Ultrasound findings in trisomy 22. *Am J Perinatol* 2009;26:135–7.
- [9] Mitchell LE, Adzick NS, Melchionne J, et al. Spina bifida. *Lancet* 2004;364:1885–95.
- [10] Wu JW, Xing YR, Wen YB, et al. Prevalence of spina bifida occulta and its relationship with overactive bladder in middle-aged and elderly Chinese people. *Int Neurourol J* 2016;20:151–8.
- [11] Fidas A, MacDonald HL, Elton RA, et al. Prevalence and patterns of spina bifida occulta in 2707 normal adults. *Clin Radiol* 1987;38:537–42.