




ELSEVIER

Contents lists available at [ScienceDirect](https://www.sciencedirect.com)

Trauma Case Reports

journal homepage: www.elsevier.com/locate/tcr

Case Report

Blunt traumatic iliac vein injury without pelvic fracture – A case report

Hiroyuki Takahashi^{a,b,*}, Tomohisa Shoko^a, Hiroyuki Okamoto^b,
Takahumi Shimizu^b, Akiko Oshiro^b, Shinsuke Onishi^b, Yuka Morishita^b,
Satosi Nara^b

^a Department of Emergency and Critical Care Medicine, Tokyo Women's Medical University Medical Center East, 2-1-10 Nishiogu, Arakawa-ku, Tokyo 116-8567, Japan

^b Emergency and Critical Care Medical Center, Teine Keijinkai Hospital, 1-jo 12-chome, Maeda, Teine-ku, Sapporo 006-8555, Japan

ARTICLE INFO

Keywords:

Conservative treatment
Iliac vein
Motor vehicles
Wounds
Nonpenetrating

ABSTRACT

A 48-year-old man fell asleep while driving a 4-t truck, hit an 11-t truck from behind, and was injured. Contrast-enhanced computed tomography revealed retroperitoneal hematoma and extravasation of contrast medium in the left common iliac vein. No obvious pelvic fracture was observed. The patient showed no hemodynamic deterioration, so conservative management was selected. Computed tomography images obtained 2 days after injury showed that the hematoma around the left common iliac vein had shrunk and no clear vein thrombus was observed. No findings suggestive of deep vein thrombosis or pulmonary embolism were seen after the start of gait training. Iliac vein injury without pelvic fracture due to blunt trauma is particularly rare. This rare injury was attributed to sudden extension of the hip and force in the direction of the long axis of the common iliac vein. Conservative management is the recommended first choice for isolated iliac vein injury with stable hemodynamics.

Introduction

We report a case of isolated iliac vein injury without pelvic fracture that was treated conservatively with good results.

Case report

A 48-year-old man (body mass index, 21 kg/m²) fell asleep while driving a 4-t truck, hit an 11-t truck from behind, and was injured. He was wearing his seat belt and the airbag was activated. The driver's seat was severely damaged, his lower limbs were pinched between the driver's seat and the body of the truck, and his lower abdomen was strongly pressed by the steering wheel.

On arrival, vital signs were as follows: Glasgow Coma Scale score, 14 (E3V5M6); blood pressure, 177/147 mmHg; heart rate, 90 beats/min; respiratory rate, 30 breaths/min; peripheral oxygen saturation, 97% with O₂ at 10 L/min; and axillary body temperature, 35.9 °C. Physical examination revealed open fracture in the right thigh and left lower leg. Contrast-enhanced computed tomography

* Corresponding author at: Department of Emergency and Critical Care Medicine, Tokyo Women's Medical University Medical Center East, 2-1-10 Nishiogu, Arakawa-ku, Tokyo 116-8567, Japan.

E-mail address: htakahashi-tmd@umin.ac.jp (H. Takahashi).

<https://doi.org/10.1016/j.tcr.2021.100412>

Accepted 6 February 2021

Available online 10 February 2021

2352-6440/© 2021 The Author(s). Published by Elsevier Ltd. This is an open access article under the CC BY-NC-ND license

(<http://creativecommons.org/licenses/by-nc-nd/4.0/>).

(CT) revealed retroperitoneal hematoma and extravasation of contrast medium in the left common iliac vein (Fig. 1). No obvious pelvic fracture was observed. X-ray examination showed right femoral distal diaphyseal open fracture, right fibula fracture, and left tibial and fibula open fracture.

The main findings from blood examinations were: hemoglobin, 12.0 g/dL; platelet count, $299 \times 10^3/\mu\text{L}$; lactate, 58 mg/dL; international normalized ratio of prothrombin time, 1.17; fibrinogen, 312 mg/dL.

The patient did not exhibit any hemodynamic deterioration, so we decided on conservative management. CT performed again after cleaning and external fixation of the open leg fracture showed no increase in left common iliac vein hematoma. CT images obtained 2 days after the injury showed that the hematoma around the left common iliac vein had shrunk and no vein thrombus was observed (Fig. 2). Although several surgeries were required for the open fractures of the lower limbs, he was able to stand from 25 days after injury. No findings suggestive of deep vein thrombosis or pulmonary embolism were seen after the start of gait training. At 142 days after the injury, he was transferred to another hospital to continue rehabilitation. CT images obtained 6 months after the injury showed no venous stenosis or thrombus.

Discussion

Iliac vascular injuries are relatively uncommon, with an incidence of <2% of all vascular traumas [1]. Penetrating trauma is far more often the cause of iliac vascular injuries than blunt trauma [1]. Most blunt injuries are associated with pelvic fracture, but iliac vascular injuries without pelvic fracture are rare [2], and isolated iliac vein injury due to blunt trauma is particularly rare [Table 1] [1,3–6].

Iliac vascular injuries without pelvic fracture have been considered to involve stretch injury [3] or seat belt injury [7,8]. What was the mechanism of injury in this case? The speed of the truck immediately before the collision was unknown, but the truck that the patient was driving crashed head-on into the back of another truck, and the driver's seat was severely damaged. The steering wheel of the 4-t truck being driven by the patient was horizontal and lower than the position of a normal passenger car steering wheel. After the accident, the steering wheel was pressing strongly on the lower abdomen of the patient. Iliac vein injury in this case might be attributable to the vein being sandwiched between the steering wheel and sacrum. However, no findings suggestive of external forces such as abdominal wall hematoma or increased subcutaneous or abdominal adipose tissue concentrations were seen despite injury due to pinching or bruising. Suliman et al. reported femoral artery and vein injuries resulting from forced hip hyperextension and thigh abduction [9]. They postulated that because the femoral vessels are relatively immobile owing to the branching vessels and periadventitial connective tissue, extreme hyperextension-abduction resulted in traction and external rotation of the femoral head that led to stretching, twisting, and femoral vessel injury. Similarly, the iliac vessels are relatively immobile. In our case, the seat belt and steering wheel compressed the lower abdomen in the sitting position, and external force was thought to be applied to the thighbone. This force resulted in open fracture of the distal diaphysis of the femur, which caused sudden extension of the hip joint and force in the direction of the long axis of the common iliac vein that resulted in injury to the vein.

Repair or ligation has conventionally been discussed as a treatment for iliac vein injury [1], whereas we selected conservative treatment. Conservative treatment has not been studied in detail for this type of injury, but Nancy et al. [3] reported conservative treatment for a case of stable iliac vein injury without pelvic fracture. The patient in that case was discharged home on day 4 after injury, and venous angiography at 6 weeks showed complete healing with no stenosis. Boulanger et al. [4] reported repair for blunt traumatic laceration of the iliac vein without pelvic fracture, the iliac vein was narrowed by an estimated 20–30%, and pulmonary embolism developed. In the present case, no complications such as deep vein thrombosis developed, so conservative treatment may be more effective than surgical treatment for isolated iliac vein injury with stable hemodynamics.

Deep vein thrombosis remains a significant concern in patients with vascular trauma, particularly in venous injury [2]. In this case, we did not administer an anticoagulant because of the risk of rebleeding. In reports of conservative treatment, pharmacological prophylaxis was performed and no bleeding complications were encountered [3]. Although deep vein thrombosis was not observed in

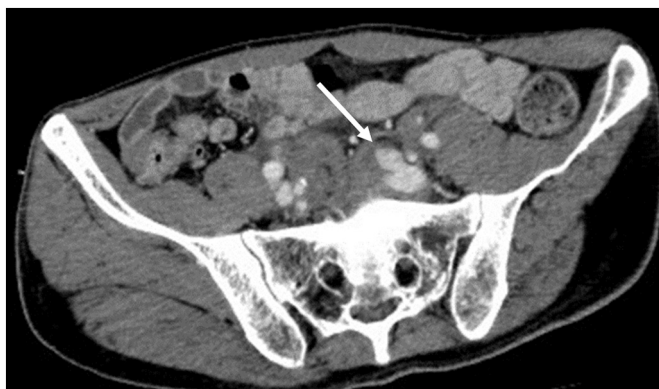

Fig. 1. Contrast-enhanced CT shows presacral hematoma and extravasation of contrast medium in the left common iliac vein (arrow). No obvious pelvic fracture or intraabdominal organ damage is observed.

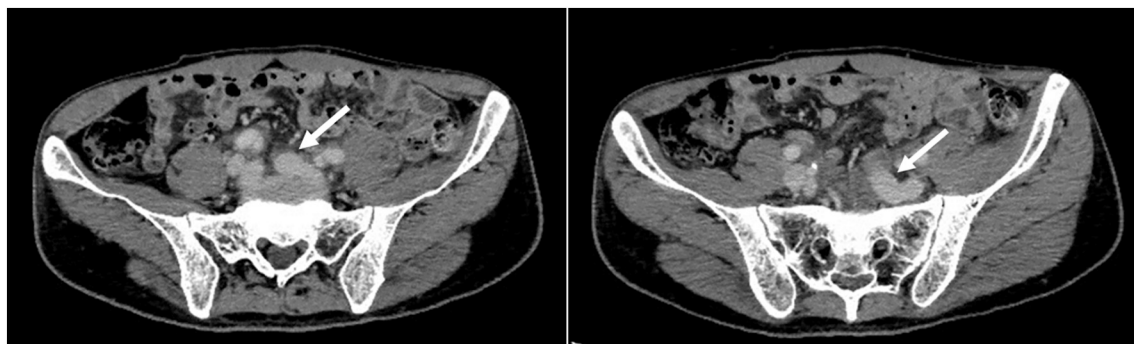


Fig. 2. Contrast-enhanced CT images obtained 2 days after injury show a reduction in hematoma around the left common iliac vein, with no evidence of venous thrombosis or stenosis (*arrow*).

Table 1

Summary of isolated iliac vein injury without pelvic fracture due to blunt mechanisms.

Report	Vessel injury	Mechanism	Age (years)	Hemodynamic status	Treatment
This report (2020)	Left common iliac vein	Motor vehicle collision	48	Stable	Conservative treatment
Helton et al. (2017) [3]	Left common and left external iliac veins	Struck by vehicle	36	Stable	Conservative treatment
Boulanger et al. (1992) [4]	Left iliac vein	Motor vehicle accident	32	Stable	Repair
Buice et al. (1990) [5]	Right external iliac vein	Motorcycle accident	33	Unstable	Repair
Sofue et al. (2012) [6]	Left external iliac vein	Traffic accident	52	Unstable	Stent placement

our case, anticoagulant therapy may be warranted in patients at high risk of deep vein thrombosis, even when conservative treatment is applied.

Conclusion

We encountered a rare case of isolated iliac vein injury without pelvic fracture. This rare injury was attributed to sudden extension of the hip and force in the direction of the long axis of the common iliac vein. Conservative management was considered the first choice for isolated iliac vein injury with stable hemodynamics.

Funding sources

None.

CRedit authorship contribution statement

Hiroyuki Takahashi: investigation, writing- original draft preparation. Tomohisa Shoko: conceptualization, methodology, writing-review and editing. Hiroyuki Okamoto: investigation. Takahumi Shimizu: investigation. Akiko Oshiro: investigation. Shinsuke Onishi: investigation. Yuka Morishita: investigation. Satoshi Nara: supervision.

Declaration of competing interest

None.

Acknowledgements

None.

References

- [1] G.A. Magee, J. Cho, K. Matsushima, et al., Isolated iliac vascular injuries and outcome of repair versus ligation of isolated iliac vein injury, *J. Vasc. Surg.* 67 (1) (2018) 254–261.

- [2] M.H. Lauerman, D. Rybin, G. Doros, et al., Characterization and outcomes of iliac vessel injury in the 21st century: a review of the National Trauma Data Bank, *Vasc. Endovasc. Surg.* 47 (5) (2013) 325–330.
- [3] N. Helton, C. McNeill, W. Witham, Iliac vascular injury in the absence of a pelvic fracture, *J Trauma Nurs.* 24 (5) (2017) 323–325.
- [4] B. Boulanger, J. Green, A. Rodriguez, Blunt traumatic iliac vein laceration without pelvic fracture: a rare entity, *J. Vasc. Surg.* 16 (1) (1992) 87–89.
- [5] W.S. Buice, J.I. Hollenbeck, T. McElwee, Isolated iliac vein injury from blunt trauma, *Surgery.* 107 (3) (1990) 350–352.
- [6] K. Sofue, K. Sugimoto, T. Mori, S. Nakayama, M. Yamaguchi, K. Sugimura, Endovascular uncovered Wallstent placement for life-threatening isolated iliac vein injury caused by blunt pelvic trauma, *Jpn. J. Radiol.* 30 (8) (2012) 680–683.
- [7] N. Gupta, A. Auer, B. Troop, Seat belt-related injury to the common iliac artery: case report and review of the literature, *J. Trauma* 45 (2) (1998) 419–421.
- [8] J.J. Tuech, F. Villapadierna, J.D. Singland, X. Papon, P. Pessaux, M. Vergos, Blunt injury to the common iliac artery, *Eur. J. Vasc. Endovasc. Surg.* 20 (1) (2000) 47–50.
- [9] A. Suliman, M.W. Ali, N. Kansal, N. Tian, N. Angle, R. Coimbra, Complete femoral artery and vein avulsion from a hyperextension injury: a case report and literature review, *Ann Vasc Surg.* 23 (3) (2009) (411.e9-15).