

Severe Ophthalmological Complications of Thyroid Disease are Rare in Ibadan, Southwestern Nigeria: Results of a Pilot Study

Olufunmilola A. Ogun¹ and Jokotade O. Adeleye²

¹Department of Ophthalmology, College of Medicine, University of Ibadan and University College Hospital, Ibadan, Nigeria. ²Department of Medicine, College of Medicine, University of Ibadan and University College Hospital, Ibadan, Nigeria.

ABSTRACT

BACKGROUND: Ocular manifestations of thyroid dysfunction constitute a wide clinical spectrum ranging from minor ocular discomfort, lid retraction, lid lag and ocular injection, to sight threatening eyeball protusion and optic nerve compression. Thyroid-related eye disorders are most commonly associated with Graves' disease, and this most frequently occurs in the setting of hyperthyroidism. However, in 10% of cases, typical eye signs have also been reported in euthyroid and hypothyroid states. The severity of thyroid eye disease has been linked to cigarette smoking. There is very little data specifically reporting the ocular manifestations of thyroid disease among black African patients and there is no known report from Nigeria. This pilot study therefore focused on documenting the ocular signs accompanying thyroid dysfunction in a black African population.

AIM: To evaluate the pattern of ocular complications, among patients treated for thyroid disorders, in a major Nigerian teaching hospital.

RESULTS: A total of 75 patients with thyroid dysfunction, were evaluated, comprising 63 females and 12 males. There was a very low prevalence of smoking among patients (<5%). Graves' disease was the commonest thyroid disorder, representing 70% of cases. Seventy-eight percent of patients were hyperthyroid, 11.8% were euthyroid and only 9.8% of patients were hypothyroid. Commonest systemic symptoms were neck swelling (68.6%), weight loss (63.8%), tremors (60.9%) and palpitations (59.4%). Two-thirds of patients reported ocular symptoms consisting mainly of painless eye swelling (66.7%) and ocular irritation (58%). Conjunctival injection, lid lag and lid retraction were the commonest ocular signs. Chemosis, severe proptosis and ocular motility disorder were very rare. Optic neuropathy was found in 4 patients but was related to pre-existing glaucoma. Majority of patients required only ocular emollients and tear supplements.

CONCLUSION: Severe ocular complications of thyroid disorders were uncommon in this cross-section of Nigerian patients. This may be linked to the very low prevalence of cigarette smoking among Nigerians or genetic and environmental factors linked to their African heritage.

KEYWORDS: graves, thyroid, thyroid eye disease, Nigeria, Africa

CITATION: Ogun and Adeleye. Severe Ophthalmological Complications of Thyroid Disease are Rare in Ibadan, Southwestern Nigeria: Results of a Pilot Study. *Ophthalmology and Eye Diseases* 2016;8:5–9 doi: 10.4137/OED.S32169.

TYPE: Original Research

RECEIVED: November 06, 2015. **RESUBMITTED:** January 20, 2016. **ACCEPTED FOR PUBLICATION:** January 25, 2016.

ACADEMIC EDITOR: Joshua Cameron, Editor in Chief

PEER REVIEW: Three peer reviewers contributed to the peer review report. Reviewers' reports totaled 425 words, excluding any confidential comments to the academic editor.

FUNDING: Authors disclose no external funding sources.

COMPETING INTERESTS: Authors disclose no potential conflicts of interest.

CORRESPONDENCE: olufunmiogun@gmail.com

COPYRIGHT: © the authors, publisher and licensee Libertas Academica Limited. This is an open-access article distributed under the terms of the Creative Commons CC-BY-NC 3.0 License.

Paper subject to independent expert single-blind peer review. All editorial decisions made by independent academic editor. Upon submission manuscript was subject to anti-plagiarism scanning. Prior to publication all authors have given signed confirmation of agreement to article publication and compliance with all applicable ethical and legal requirements, including the accuracy of author and contributor information, disclosure of competing interests and funding sources, compliance with ethical requirements relating to human and animal study participants, and compliance with any copyright requirements of third parties. This journal is a member of the Committee on Publication Ethics (COPE). Provenance: the authors were invited to submit this paper.

Published by Libertas Academica. Learn more about this journal.

Background

Ocular manifestations of thyroid disease constitute a wide clinical spectrum, ranging from ocular irritation, lid retraction, lid lag, and ocular injection to infiltrative ophthalmopathy (thyroid eye disease).^{1–3} Graves' disease is an autoimmune disorder that affects the eyes, the thyroid gland, and rarely the skin and joints.² Thyroid eye disorder is the most common extrathyroidal manifestation of Graves' disease, and it is associated with hyperthyroidism in 90% of cases.² It constitutes the commonest cause of orbital and periorbital inflammation in adults.¹ While thyroid eye disease most commonly occurs in the setting of hyperthyroidism, up to 10% of patients may be euthyroid at the time of onset of the eye disorder¹ and about 3% may be hypothyroid.⁴ The pattern and prevalence of thyroid eye disease vary widely⁵ from a mild disorder characterized by dry eye symptoms and ocular irritation to a severe disfiguring form of orbitopathy.⁵ Cigarette smoking has been implicated in

the pathogenesis of the orbital disease and the attenuation of patients' response to therapy.⁶ Although thyroid disorders are common in Nigeria,^{7,8} less information has been reported on the prevalence or pattern of thyroid eye disease in Nigerians. This study was designed to evaluate the pattern of thyroid-associated eye disease among patients with thyroid disorders, at the University College Hospital, Ibadan, Southwestern Nigeria.

The ancient city of Ibadan is the capital of Oyo state and a major hub in Southwestern Nigeria. It has a population of ~5.6 million inhabitants primarily of Yoruba extraction.⁹ The University College Hospital is an 800-bed hospital and the premier teaching hospital in Nigeria. It is a major referral center for all medical specialties. The endocrine unit runs bimonthly subspecialty thyroid clinics within the medical outpatient (MOP) department. It is believed that this information will provide necessary data for the planning and provision of supportive ophthalmological services to meet the needs of



patients with thyroid disease and also provide a perspective on thyroid eye disorders among Nigerians.

Objective

The purpose was to document the ocular symptoms and signs that accompany thyroid dysfunction in this homogenous Black African population, thereby providing data, which would facilitate the planning and provision of services and resources to meet the needs of this group of patients.

Method

This was a cross-sectional study of consecutive patients presenting with thyroid dysfunction to the Endocrinology unit at the MOP clinic of the University College Hospital, Ibadan. Information obtained from participants at enrollment included age, sex, occupation, smoking history, passive smoking (history of chronic exposure to cigarette/tobacco smoke from a close cohort), systemic and ocular symptoms, and their duration. Identifiers, such as name and hospital number, were collected for the purpose of retrieving relevant hospital records and laboratory investigation results for documentation. Patients were then subjected to a systemic medical and ophthalmological examination. Systemic examination included general physical examination, blood pressure and cardiovascular evaluation, and palpation of the neck. Ocular examination comprised evaluation of the best-corrected visual acuity, exophthalmometry, direct funduscopy, slit-lamp examination of the anterior segment, fluorescein staining of the cornea, applanation tonometry, and evaluation of lid and ocular motility, including cover and alternate cover tests for detection of heterophoria. Patients were characterized upon evaluation by the endocrinologists, placed on individualized treatment plans, and followed up in the MOP clinic. This research adhered to the principles of the Declaration of Helsinki, and patients gave their consent for publication of images and reports of their cases. Ethical approval for the research was granted by the Oyo State Research Ethical Review Committee of the Ministry of Health, Nigeria.

Results

A total of 75 patients presenting to the MOP with thyroid disorders had both medical and ocular assessments. There were 63 women and 12 men, corresponding to a female:male ratio of 5.25:1. Patients were aged between 16 and 75 years with a median age of 42 years (standard deviation = 14.08 years).

Males were significantly younger than females, and 75% of males were below 40 years of age, while majority of women (62.1%) were aged 40 years and above ($P = 0.019$). There were 66 nonsmokers, with 11 individuals who lived in close proximity to a smoker (ie, passive smokers) and 2 ex-smokers who previously smoked on a regular basis but had discontinued the habit. Seven participants gave no response. Smoking and passive smoking were significantly more prevalent among male respondents ($P = 0.005$).

The commonest thyroid disorder was Graves' disease, identified in 42 (70%) of 60 cases. Toxic multinodular goiter was diagnosed in 13 cases (21.7%), hypothyroidism in three cases (5%), and simple goiter in two cases (3.3%), respectively. Fifteen patients did not complete their hormone analysis and thyroid antibody screening to enable characterization. Among those who performed a thyroid function test at presentation ($N = 51$), 78.4% of patients were hyperthyroid, 11.8% of patients were euthyroid, and only 9.8% of patients were hypothyroid.

Patients reported a wide variety of systemic symptoms, but the commonest were neck swelling (68.6%), weight loss (63.8%), tremors (60.9%), and palpitations (59.4%). The pattern of systemic symptoms is shown in Figure 1. There was no correlation with age or gender in the prevalence or pattern of reported symptoms. Fifty-two patients had physical examination of the neck. Of these, more than half had a visible and palpable neck swelling (39/52, 75%).

Ophthalmological symptoms and signs. Majority of patients (63%) presented with ocular symptoms, consisting mainly of tearing, foreign body sensation, ocular injection, blurring of vision, and photophobia. Diplopia was rare. Only four patients (5.3%) reported diplopia, and this was intermittent in nature. A third of patients had no ocular symptoms at all.

Thirty-eight patients (66.7%) reported painless eye swelling, and more than half of the patients (58%) complained of ocular irritation. Blurred vision, diplopia, and pain were uncommon. Ocular symptoms did not interfere with work or self-perception in majority of cases. However, at least one in three patients felt self-conscious of their ocular appearance. Best-corrected visual acuity was good (6/12 or better) in up to 95% of patients. Mean corneocanthal distance, on exophthalmometry, was 18.51 mm (standard deviation [SD] = 3.60 mm) on the right eye and 18.69 mm (SD = 3.40 mm) on the left eye, with a range of 12.00–26.00 mm.

In males, mean corneocanthal distance measured 17.71 mm in the right eye and 17.64 mm in the left eye, while in females, the mean corneocanthal distance measured 18.63 mm and 18.65 mm in the right and left eyes, respectively. The difference in mean corneocanthal distance between males and females was not statistically significant in the right eye ($P = 0.618$) and was only marginally significant in the left eye ($P = 0.049$). There was no significant difference with age.

Focal conjunctival injection over the insertion of the horizontal recti, lid lag, lid retraction, and proptosis were the most common ocular signs. Proptosis was defined as a corneocanthal distance of 21 mm or greater in at least one eye, and this was identified in less than half of the patients. These patients all had Graves' disease. There was no significant age or gender difference in the pattern of ocular presentation. Conjunctival chemosis was very rare, occurring in only three patients. Chemosis in these cases was very mild, and none of these three patients had a history of passive or active smoking. Four patients had optic neuropathy, related to pre-existing glaucoma and unrelated to the thyroid eye disease. All

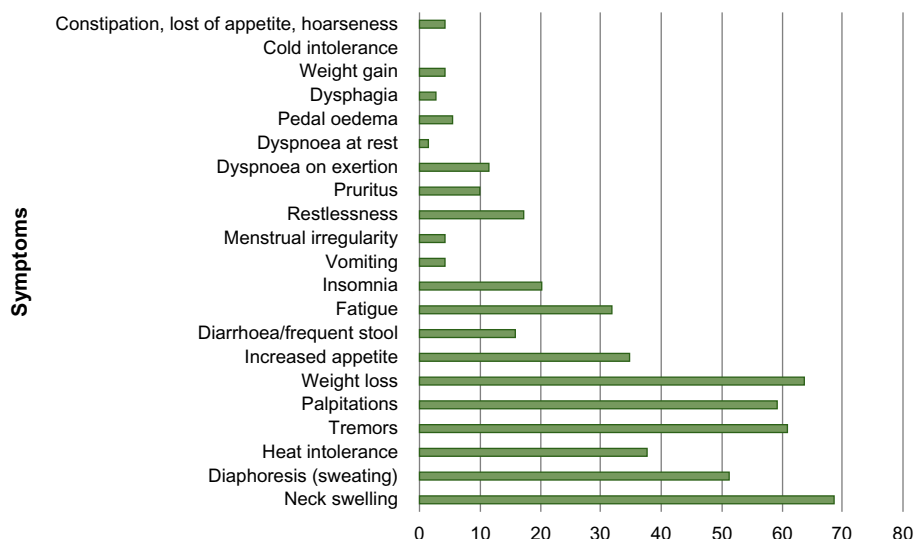


Figure 1. Pattern of systemic symptoms, at presentation, in patients with thyroid disorder in Ibadan.

patients were placed on ocular emollients and artificial tears. No case of severe proptosis, optic nerve compression, or ocular dysmotility was found. Follow-up of cases was very difficult as very few patients returned for follow-up ophthalmic examination after their initial evaluation. Figure 2A–D demonstrates the lack of significant signs of orbital infiltration in patients with Graves' ophthalmopathy.

Discussion

Thyroid-associated orbitopathy, Graves' disease, and hyperthyroidism are closely related clinical syndromes with shared characteristics. Thyroid-associated orbitopathy is an autoimmune process most commonly associated with Graves' disease, which is the commonest autoimmune disorder of the thyroid. More than 50% of patients with Graves' disease manifest the orbital complications characterized as thyroid-associated orbitopathy.⁶ The pattern of thyroid disease, observed in this study, was similar to reports from other parts of the world.^{10,11} Graves' disease was the commonest thyroid disorder in this study, representing more than half of all cases. This is understandable because this was a hospital-based study. The reason for the higher prevalence of Graves' disease among patients recruited in hospital-based studies is most likely related to the hyperthyroidism, which is found in up to 90% of patients with Graves' disease and which is responsible for the numerous ocular and systemic symptoms that cause affected individuals to present to hospital for medical care. This has also been observed in several other hospital-based studies of autoimmune thyroid disorder.^{3,7,11–13} In contrast, a recent review of the literature on the epidemiology of thyroid disorders in Africa, published by Ogbera and Kuku, suggested that simple goiter resulting from iodine deficiency is the commonest thyroid disorder in Africans. However, it is noteworthy that this review did not report on thyroid eye disease,⁸ and the same author (Ogbera⁷) had reported an earlier hospital-based study that showed that Graves' disease/

hyperthyroidism was the most frequently encountered condition in this setting. With respect to gender, there was a significant female preponderance, and female patients were significantly older than males at presentation. Bartley³ recorded similar age disparities between male and female patients with Graves' disorder in Olmsted County. While the female preponderance is well documented in literature, the significance of this gender-based age difference is unclear.

Ocular manifestations of thyroid disease range from mild symptoms of ocular irritation, lid retraction, lid lag, and ocular injection to signs of orbital infiltration such as chemosis, proptosis and restriction of ocular motility, corneal exposure, and optic nerve compression. These infiltrative orbital changes have also been characterized into two main types based on different mechanisms of pathogenesis. Type I orbitopathy is characterized as predominantly fat deposition, while type II orbitopathy involves predominantly extraocular muscle enlargement.¹⁴ These changes are visualized on orbital imaging performed with computerized tomography or magnetic resonance imaging scans. Orbital infiltration is marked by conjunctival injection, chemosis, and protusion of the globe (proptosis or exophthalmos, when bilateral). Proptosis is measured clinically as the corneocanthal distance (horizontal distance from the lateral canthus to the apex of the cornea) taken with an exophthalmometer. In this study, a corneocanthal distance of 21 mm was defined as the limit for the diagnosis of proptosis in accordance with the guidelines of the European Group for the study of Graves' Ophthalmopathy.¹⁵ Using this criterion, only 15 patients (20%) had proptosis. The proptosis was mostly symmetrical and modest (range 21–27 mm). However, conjunctival chemosis and injection were rare. This is similar to reports from Asian populations¹³ in which proptosis was also an infrequent finding. Furthermore, patients in this study tended to manifest more frequent periocular lid swelling (periorbital fullness)

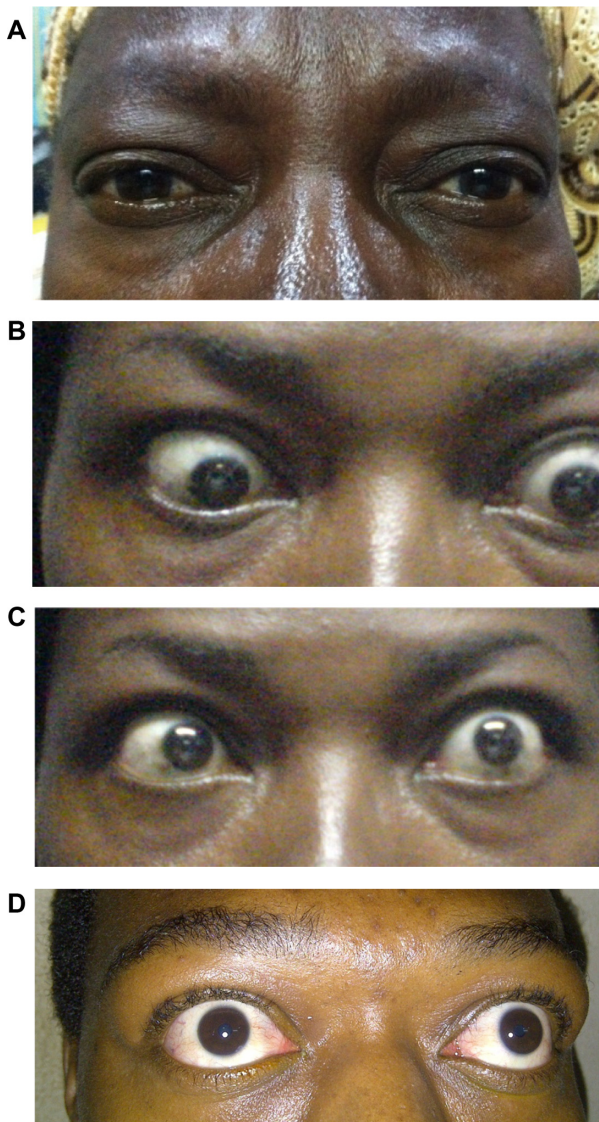


Figure 2. (A) Periorbital swelling was present in the absence of significant chemosis in patients with orbital involvement. (B) Lid retraction and mild conjunctival injection over the insertion of the horizontal recti (no chemosis). (C) Lid lag in the same patient in (B) above. (D) Exophthalmos, lid retraction, and moderate conjunctival injection over the insertion of horizontal recti in the absence of significant chemosis (notice the modest periorbital fullness).

rather than chemosis or proptosis. This striking absence of the typical infiltrative orbitopathy may be related to the low incidence of smoking in this population or may reflect anatomical peculiarities in the size or orbital configuration of African patients when compared with Caucasians. Similar studies in Asian populations also recorded a lower prevalence of proptosis compared with Caucasian figures.^{11,16} On the contrary, Asian studies reported a higher prevalence of thyroid optic neuropathy than similar studies among Caucasians.¹⁷ This has been attributed to differences in the orbital anatomy between the two populations. Asian populations reportedly have deeper orbits with a narrower orbital apex that predisposes to “crowding” at the orbital apex and consequently optic

nerve compression.^{18,19} In this study, the lack of orbital imaging limited the authors’ ability to determine early or subclinical orbital or extraocular muscle involvement or the presence of crowding at the orbital apex. Nevertheless, severe orbital involvement was not seen among these patients. Likewise, the presence of subtle thyroid optic neuropathy could have been overlooked in the absence of objective parameters such as visual evoked potentials (VEP), although all patients had color vision testing with Ishihara plates that are sensitive to red desaturation, an early sign of optic neuropathy. A study of pattern-reversal VEP in 88 patients with normal visual acuities and thyroid-associated ophthalmopathy has shown that VEP was abnormal in 23.8% of cases, asymptomatic for dysthyroid optic neuropathy (DON). Of these cases, less than half had field defects on visual field testing and only one patient demonstrated dyschromatopsia on color vision testing.²⁰ Therefore, it is possible that cases of early DON may have been undiagnosed in this cross-sectional study because electrophysiological testing was unavailable.

In general, the majority of ocular complications observed in this study were mild symptoms and signs of dry eye disease and lid motility changes. Dry eye disease itself has been known to mask underlying thyroid eye disease as observed in a study among Chinese.²¹ The prevalence of dry eye symptoms may have been further exacerbated by the hot tropical climate which occasionally is also dry and dusty. This preliminary study suggests that patients with thyroid disease in Nigeria are more likely to present with symptoms of dry eyes, lid retraction, and lid lag rather than with features of orbital infiltration or ocular dysmotility. Furthermore, compressive optic neuropathy (DON) resulting from thyroid orbital infiltration was also rare. Optic neuropathy in Nigerian patients with thyroid disease is more likely to be related to glaucoma than the thyroid disorder. These may reflect genetic or environmental differences in the manifestation of thyroid eye disease, although the low prevalence of smoking in this population may also play a significant role.

Limitations of this study include the small sample size, the lack of orbital imaging to determine extraocular muscle involvement, and the limited blood investigations (hormonal assays) that were carried out due to financial constraints. It was not possible to correlate the thyroid hormone and thyroid antibody levels with ophthalmological signs because of similar logistic difficulties.

Conclusion

In conclusion, thyroid disease presents with relatively mild ophthalmological symptoms and signs in Ibadan, Southwestern Nigeria, when compared with similar Caucasian studies. It is possible that the relative rarity of severe ophthalmological signs may be related to the extremely low prevalence of smoking in this population or the presence of protective factors in the environment or genes. Further studies are recommended to investigate these apparent ethnic/racial differences in the manifestation of thyroid eye disease.



Author Contributions

Conceived and designed the study: OAO, JOA. Analyzed the data: OAO, JOA. Wrote the first draft of the manuscript: OAO. Contributed to the writing of the manuscript: JOA. Agree with manuscript results and conclusions: OAO, JOA. Jointly developed the structure and arguments for the paper: OAO, JOA. Made critical revisions and approved final version: OAO, JOA. Both authors reviewed and approved of the final manuscript.

REFERENCES

1. Mallika P, Tan A, Aziz S, et al. Thyroid associated ophthalmopathy – a review. *Malays Fam Physician*. 2009;4(1):8–14.
2. Bartalena L, Fatourechi V. Extrathyroidal manifestations of Graves' disease: a 2014 update. *J Endocrinol Invest*. 2014;37(8):691–700.
3. Bartley GB. The epidemiologic characteristics and clinical course of ophthalmopathy associated with autoimmune thyroid disease in Olmsted County, Minnesota. *Trans Am Ophthalmol Soc*. 1994;92:477.
4. Phelps PO, Williams K. Thyroid eye disease for the primary care physician. *Dis Mon*. 2014;60(6):292–8.
5. Bhatt R, Nelson CC, Douglas RS. Thyroid-associated orbitopathy: current insights into the pathophysiology, immunology and management. *Saudi J Ophthalmol*. 2011;25(1):15–20.
6. Naik VM, Naik MN, Goldberg RA, Smith TJ, Douglas RS. Immunopathogenesis of thyroid eye disease: emerging paradigms. *Surv Ophthalmol*. 2010;55(3):215–26.
7. Ogbera A, Fasanmade O, Adediran O. Pattern of thyroid disorders in the South-Western region of Nigeria. *Ethn Dis*. 2007;17:327–30.
8. Ogbera A, Kuku SF. Epidemiology of thyroid diseases in Africa. *Indian J Endocrinol Metab*. 2011;15:S82–8.
9. Nigerian Bureau of Statistics. *Annual Abstract of Statistics*. 2010. Available at: <http://www.nigerianstat.gov.ng/pages/download/712010>.
10. McKeag D, Lane C, Lazarus JH, et al. Clinical features of dysthyroid optic neuropathy: a European Group on Graves' Orbitopathy (EUGOGO) survey. *Br J Ophthalmol*. 2007;91(4):455–8.
11. Lim NC, Sundar G, Amrith S, Lee KO. Thyroid eye disease: a Southeast Asian experience. *Br J Ophthalmol*. 2015;99(4):512–8.
12. Tellez M, Cooper J, Edmonds C. Graves' ophthalmopathy in relation to cigarette smoking and ethnic origin. *Clin Endocrinol (Oxf)*. 1992;36(3):291–4.
13. Tsai CC, Kau HC, Kao SC, Hsu WM. Exophthalmos of patients with Graves' disease in Chinese of Taiwan. *Eye (Lond)*. 2006;20(5):569–73.
14. Kuriyan AE, Woeller CF, O'Loughlin CW, Phipps RP, Feldon SE. Orbital fibroblasts from thyroid eye disease patients differ in proliferative and adipogenic responses depending on disease subtype. *Invest Ophthalmol Vis Sci*. 2013;54:7370–7.
15. European Group on Graves O, Wiersinga WM, Perros P, et al. Clinical assessment of patients with Graves' orbitopathy: the European Group on Graves' Orbitopathy recommendations to generalists, specialists and clinical researchers. *Eur J Endocrinol*. 2006;155(3):387–9.
16. Gupta A, Sadeghi PB, Akpek EK. Occult thyroid eye disease in patients presenting with dry eye symptoms. *Am J Ophthalmol*. 2009;147(5):919–23.
17. Chng CL, Seah LL, Khoo DH. Ethnic differences in the clinical presentation of Graves' ophthalmopathy. *Best Pract Res Clin Endocrinol Metab*. 2012;26(3):249–58.
18. Neigel JM, Rootman J, Belkin RI, et al. Dysthyroid optic neuropathy. The crowded orbital apex syndrome. *Ophthalmology*. 1988;95(11):1515–21.
19. Rootman J. Retrobulbar pressures in dysthyroid optic neuropathy. *Br J Ophthalmol*. 1996;80(12):1034.
20. Salvi M, Spaggiari E, Neri F, et al. The study of visual evoked potentials in patients with thyroid-associated ophthalmopathy identifies asymptomatic optic nerve involvement. *J Clin Endocrinol Metab*. 1997;82(4):1027–30.
21. Lin PY, Tsai SY, Cheng CY, Liu JH, Chou P, Hsu WM. Prevalence of dry eye among an elderly Chinese population in Taiwan. *Ophthalmology*. 2003;110(6):1096–101.