



AKADÉMIAI KIADÓ

White matter microstructural and Compulsive Sexual Behaviors Disorder – Diffusion Tensor Imaging study

Journal of Behavioral Addictions

10 (2021) 1, 55–64

DOI:

[10.1556/2006.2021.00002](https://doi.org/10.1556/2006.2021.00002)

© 2021 The Author(s)

MAŁGORZATA DRAPS^{1*},
NATALIA KOWALCZYK-GRĘBSKA², ARTUR MARCHEWKA³,
FENG SHI⁴ and MATEUSZ GOLA^{1,5}

¹ Institute of Psychology, Polish Academy of Sciences, Warsaw, Poland

² Faculty of Psychology, SWPS University of Social Sciences and Humanities, Warsaw, Poland

³ Laboratory of Brain Imaging, Neurobiology Center, Nencki Institute of Experimental Biology, Polish Academy of Sciences, Warsaw, Poland

⁴ Biomedical Imaging Research Institute, Cedars-Sinai Medical Center, Los Angeles, USA

⁵ Swartz Center for Computational Neuroscience, Institute for Neural Computations, University of California San Diego, San Diego, USA

Received: June 03, 2020 • Revised manuscript received: October 30, 2020; December 04, 2020 • Accepted: December 27, 2020

Published online: February 10, 2021

FULL-LENGTH REPORT



ABSTRACT

Background and aims: Even though the Compulsive Sexual Behavior Disorder (CSBD) was added to the ICD-11 under the impulse control category in 2019, its neural mechanisms are still debated. Researchers have noted its similarity both to addiction and to Obsessive-Compulsive Disorder (OCD). The aim of our study was to address this question by investigating the pattern of anatomical brain abnormalities among CSBD patients. *Methods:* Reviewing 39 publications on Diffusion Tensor Imaging (DTI) we have identified main abnormalities specific for addictions and OCD. Then we have collected DTI data from 36 heterosexual males diagnosed with CSBD and 31 matched healthy controls. These results were then compared to the addiction and OCD patterns. *Results:* Compared to controls, CSBD individuals showed significant fractional anisotropy (FA) reduction in the superior corona radiata tract, the internal capsule tract, cerebellar tracts and occipital gyrus white matter. Interestingly, all these regions were also identified in previous studies as shared DTI correlates in both OCD and addiction. *Discussion and conclusions:* Results of our study suggest that CSBD shares similar pattern of abnormalities with both OCD and addiction. As one of the first DTI study comparing structural brain differences between CSBD, addictions and OCD, although it reveals new aspects of CSBD, it is insufficient to determine whether CSBD resembles more an addiction or OCD. Further research, especially comparing directly individuals with all three disorders may provide more conclusive results.

KEYWORDS

Diffusion Tensor Imaging, white matter microstructure, Compulsive Sexual Behaviors Disorder, hypersexuality, addictions, Obsessive-Compulsive Disorder

INTRODUCTION

The Compulsive Sexual Behaviors Disorder (CSBD) introduced by World Health Organization (WHO) in 11th edition of International Classification of Diseases (ICD-11) is a psychiatric disorder characterized by repeated failure to resist urges for sexual activity. Initially, these activities are rewarding for the patient, but after a while they become harmful and dysfunctional, resulting with high degree of personal distress. To meet CSBD diagnostic criteria, the patient must exhibit above mentioned symptoms for at least 6 months, and

*Corresponding author.

E-mail: mdraps@psych.pan.pl

diagnosis cannot be made if no severe distress in personal life is reported or if the distress is related only to moral judgment and disapproval of sexual behavior, for example, based on religious/moral beliefs (Kraus et al., 2018; WHO, 2019). The criteria of CSBD proposed by WHO in large extent were based on criteria for hypersexual disorder (HD) proposed by Kafka (2010) for consideration in the sexual disorders section of DSM-V. Similarly to HD, CSBD was conceptualized as a compulsive nonparaphilic sexual desire disorder with an impulsivity component, resembling addiction, however unlike HD, CSBD the abandons criterion of stress and emotional regulation (resembling OCD) (for detailed discussion see: Gola et al., 2020).

WHO classified CSBD (in the ICD-11) as an impulse control disorder, but the aspect of compulsiveness is included in the name of the disorder. Unfortunately, the impulse control disorder category is very broad and its boundaries cannot be sharply defined, which makes CSBD's classification the subject of continued debate, centering on the question of whether the symptoms of CSBD are impulsive or compulsive in their nature, or whether CSBD should rather be considered an expression of behavioral addiction (e.g., Bóthe et al., 2019; Gola et al., 2017; Griffiths, 2016; Kraus, Voon, & Potenza, 2016; Kühn & Gallinat, 2016; Potenza, Gola, Voon, Kor, & Kraus, 2017; Young, 2008) or some other type of psychiatric disorder. When arguing for its similarity to addiction, researchers often mention appetitive mechanisms and craving for sexual activity (Gola & Draps, 2018; Gola et al., 2017; Klucken, Wehrum-Osinsky, Schweckendiek, Kruse, & Stark, 2016; Kowalewska et al., 2018; Voon et al., 2014), the growing tolerance and escalation of symptoms, so typical of substance dependence (Reid et al., 2012; Wordecha et al., 2018), and the withdrawal syndrome (Garcia & Thibaut, 2010). On the other hand, CSBD is also compared to Obsessive-Compulsive Disorder (OCD), as it can exhibit cycles of negative, obsessive thoughts accompanied by compulsions, i.e. rituals, repetitive behaviors that reduce tension caused by obsessive thoughts, engaged in to prevent or reduce stress or anxiety (Deacon & Abramowitz, 2005; Fineberg et al. 2014). Sexual behaviors may play a role in coping strategies for emotional regulation (Lew-Starowicz, Lewczuk, Nowakowska, Kraus, & Gola, 2020) According to Coleman and colleagues (2003), CSBD patients experience repetitive thoughts of sexual nature that cause tension (obsession), and engage in compulsive sexual behaviors to reduce this tension (Coleman, Raymond, & McBean, 2003). In this way, sexual behavior can be understood as a manifestation of compulsiveness (Mick & Hollander, 2006) and sexual behavior plays a role of emotional regulation strategy (Kafka, 2010; Miner, Dickenson, & Coleman, 2019; Reid & Kafka, 2014). Currently this coping function is a subject of discussion in the context of CSBD, as it was now included in the WHO's criteria (Gola et al., 2020).

There is growing body of evidences speaking in favor of neurobiological similarities between CSBD and addictions, e.g., erotic-related reactivity of reward system (for review see: Gola & Draps, 2018 or Kowalewska et al., 2018). Among the most interesting effects are: increased ventral striatal reactivity for

preferred erotic pictures (compared with non-preferred pictures) positively correlated with results in the Internet Addiction Test Modified for Cybersex (Brand, Snagowski, Laier, & Maderwald, 2016), or greater activations within: dorsolateral prefrontal cortex, caudate, inferior supramarginal gyrus of the parietal lobe, dorsal anterior cingulate cortex and thalamus, for erotic cues among CSBD individuals when compared to controls (Seok & Sohn, 2015). CSBD individuals also demonstrated increased striatal reactivity (compared to controls) for sexually explicit videos (Voon et al., 2014) or erotic but not monetary cues (Gola et al., 2017) and decreased functional connectivity between the ventral striatum and the prefrontal cortex (Klucken et al., 2016), as well as significant negative correlation between the severity of CSBD symptoms and functional connectivity between the left superior temporal gyrus and the right caudate nucleus (Seok & Sohn, 2018). Regarding structural brain effects related to the CSBD, Kühn and Gallinat (2014) found an inverse relationship between right caudate volumetry and frequency of pornography consumption among non-clinical pornography users. Recent study from our group (Draps et al., 2020) showed that individuals with CSBD, alcohol addiction and gambling disorder share smaller gray matter volume in the left frontal pole (specifically in the orbitofrontal cortex) when compared to healthy subjects. The abovementioned data support the hypothesis on the similarities between CSBD and addictions. Unfortunately, there are no available neurobiological studies comparing CSBD to OCD.

One way of studying potential similarities between CSBD and addiction or OCD is to look at the brain's white matter microstructure. Diffusion Tensor Imaging (DTI) is a magnetic resonance imaging technique sensitive to microstructural tissue properties, allowing the qualitative assessment of white matter tracts (Basser & Jones, 2002; Guevara, Guevara, Román, & Mangin, 2020; Le Bihan, 2003; Le Bihan et al., 2001). There are many DTI techniques, for instance the Tract-Based Spatial Statistics (TBSSs) method widely used to detect white matter abnormalities in humans (Smith et al., 2006), which focuses specifically on differences in fractional anisotropy (FA). In TBSS analysis the nonlinear registration algorithm is used to project individual data onto mean tract representation, called the mean FA skeleton. We have found 39 publications on OCD (31) and addiction (8) using TBSS. In these studies, authors showed FA differences between total 1,050 healthy controls and 1,188 adult patients clinically diagnosed with OCD or addiction disorder. The smallest groups of participants were respectively: 22 in the addiction (Chumin et al., 2019) and eight in the OCD group (Cannistraro et al., 2007). Twenty-eight studies reported significant results with $P < 0.05$ after correction for multiple comparisons and 6 with uncorrected $P < 0.001$, with cluster size of 20 or more voxels. Regional diversity was more highly pronounced in OCD, with results suggesting main FA differences in several tracts such as corpus callosum, cingulum bundle, forceps minor and corona radiata. The results were sparser in addictions, with fewer regions differentiating between patient and control groups. Interestingly, nine regions (viz. superior corona radiata, internal capsule, cerebellum, occipital and frontal white matter, superior fasciculus,

posterior thalamic radiata, corpus callosum and thalamus) were revealed as DTI correlates both, for OCD and addictions (see Fig. 1).

In our study we aimed to (1) identify FA abnormalities specific for OCD and addictions through the literature review, (2) collect DTI data from CSBD patients and healthy controls (using TBSS method to identify differences in FA), and (3) compare our results with previously reported findings on OCD and addictions, to identify similarities or/and differences between OCD, addictions and CSBD.

METHODS

The DTI study

Subjects and recruitment. The sample consisted of 67 heterosexual males divided into two groups: 36 CSBD patients and 31 healthy controls (HCs). Subjects were matched by age and income (see detail information in Table 1). CSBD subjects were recruited among men seeking treatment in clinics in Warsaw, Poland. They were interviewed by psychiatrists and psychologists to confirm the diagnosis according to Kafka’s HD criteria (Kafka, 2010). All of them met four out of five A criteria, and also fulfilled B and C criteria (Kafka, 2014). HC were recruited through online announcements, and exhibited no psychopathological symptoms and were in good health. Exclusion criteria for both groups were a history of other psychiatric disorders, neurological or medical serious issues, and contraindication for magnetic resonance imaging (MRI) procedures. All participants completed questionnaires measuring CSBD symptoms: the Sexual Addiction Screening Test (Polish version: SAST-PL-M: Gola et al., 2016) and the Brief Pornography Screen (Kraus et al., 2020). During recruitment participants were also screened for sexual orientation, history of alcohol abuse and gambling problems. The inclusion

Table 1. Participants characteristic

	CSBD (mean [sd]); n = 36	HC (mean [sd]); n = 31	P-value
Age in years	31.11 [6.018]	31.84 [7.142]	NS
Sexual addiction screening test – revised	11.63 [4.664]	2.67 [1.918]	P < 0.001
Brief pornography screen	6 [2.854]	1.73 [1.929]	P < 0.001
South oaks gambling screen	0.33 [0.816]	0	NS
Alcohol use disorder identification test	7.5 [2.07]	4 [1.414]	P = 0.013
Obsessive-Compulsive Inventory –revised	17.18 [10.825]	13.1 [8.786]	NS
Monetary Choice Questionnaire – overall K value	0.0249 [0.0429]	0.0307 [0.0481]	NS

criteria for both groups were: exclusively or predominantly heterosexual on the Kinsey Scale (Polish adaptation: Wierzbna et al., 2015); scores <10 on the Alcohol Use Disorder Identification Test (Babor, de la Fuente, Saunders, & Grant, 1989); and scores <4 on the South Oaks Gambling Screen (Stinchfield, 2002). Eligible participants were invited to visit the Laboratory of Brain Imaging of Nencki Institute, PAS (Warsaw, Poland) for the data collection.

DTI Scanning protocol. All DTI images were collected on a 3-Tesla MRI scanner (Siemens Magnetom Trio TIM, Erlangen, Germany) equipped with a 12-channel phased array head coil. The Spin-echo diffusion weighted echo planar imaging (DW_EPI) sequence was performed with following parameters: TR = 8,300 ms; TE = 87 ms; GRAPPA; flip angle 90°, voxel size = 2 × 2 × 2 mm³, 64 gradient directions with b-value of 1,000 s/mm², along with two images with no diffusion gradient applied (b-value = 0).

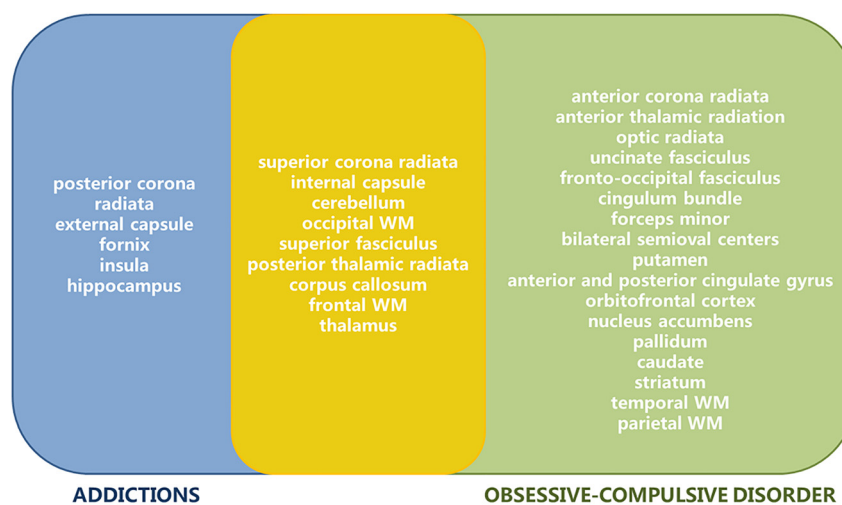


Fig. 1. Results of literature review. Fractional anisotropy (FA) reductions specific for Addiction (blue), FA reductions specific for OCD (green), and regions differentiating both Addiction and OCD patients from healthy controls (yellow)

The DW_EPI sequence was repeated in opposite phase encoding directions anterior-posterior (A-P) and with posterior-anterior (P-A).

DTI image processing. The DTI images were processed with the FSL (3.2.0) package from the FMRIB Software Library (FSL, www.fmrib.ox.ac.uk/fsl) (Smith et al., 2004). First, FSL's `fsroi` command was used to extract the b_0 images. In the next step, data was preprocessed using the corrections for susceptibility (topup) function on the basis of two b_0 images acquired in opposite phase encoding directions. The acquisitions for AP and PA directions were merged into a single four-dimensional file. Using the FSL Brain Extraction Tool (bet), all non-brain voxels and all voxels with only a small partial volume contribution were excluded from the magnitude image. Conventional motion and eddy-current correction was performed with FSL's eddy tool. To fit a diffusion tensor model at each voxel, FA images were calculated with `dtifit`.

The TBSS pipeline consisted of the following standard steps (Smith et al., 2006): (1) DTI-derived FA images were co-registered to a template. The FMRIB58_FA standard-space image was used as target in TBSS. (2) Next, the nonlinear transforms calculated in the previous step were applied to all subjects to bring their data into the 1x1x1 MNI152 standard space. (3) The mean FA and skeleton from the subjects participating in the study were calculated. (4) Thresholding the mean FA skeleton image at the 0.2 level was applied to identify the major white matter pathways.

Statistical Analyses of the DTI data. For TBSS, voxelwise general linear model analysis was performed on whole brain data, using 1,000 random permutations to find the FA skeleton voxels with a significant difference between the healthy controls and the CSBD group. A two-group difference model adjusted for age (mean centered within group) was used. No voxels survived the FDR (false discovery rate) correction for multiple comparisons. Uncorrected analysis was also performed, with threshold values of P ranging from 0.05 to 0.01 and significant cluster size >50 voxels. Calculations of false discovery rate (FDR) correction were carried out using Matlab script from Genovese, Lazar, & Nichols, (2002). Areas of significant difference under uncorrected threshold of $P < 0.02$ with a 50-voxel extent are presented below. The anatomical regions in the skeleton showing significant group differences in the tensor derived parameter (mean FA) were then identified and labeled according to structures defined in the white matter (WM) Atlas (Oishi, Faria, Van Zijl, & Mori, 2010). Those anatomical regions were used to run correlation analysis with symptoms measured by the Sexual Addiction Screening Test (Gola et al., 2016) and the Brief Pornography Screen (Kraus et al., 2020) in the CSBD group.

Ethics

The participants' informed consent was obtained at the beginning of the study. To ensure anonymity, a double-blind procedure was employed, so that members of the research

team responsible for acquiring DTI data had no access to recruitment records and did not know whether any given individual was in the CSBD or the HC group. All the procedures were carried out in accordance with the Declaration of Helsinki. The study was approved by the local ethics committee of Institute of Psychology, PAS.

RESULTS

The participants

Table 1 contains information about the 36 individuals with CSBD and the 31 matched controls, whose DTI data was analyzed in this study. There were no between-group differences in the mean age. CSBD patients obtained significantly higher scores on scales measuring CSBD severity (SAST-R: $t = 9.738$ $P < 0.001$; BPS: $t = 6.623$ $P < 0.001$). For all participants, the scores measuring addiction symptoms were below threshold (AUDIT: $t = 3.012$ $P = 0.013$, SOGS: $t = 0.81$ $P < 0.001$). CSBD patients scored significantly higher than controls in the Alcohol Use Disorder Identification Test (Babor et al., 1989), but none exceeded the alcohol use disorder threshold (16 points). Groups did not differ at the Obsessive-Compulsive Inventory-Revised ($t = 1.580$, $P = 0.12$; OCI-R, Foa et al., 2002) and Monetary Choice Questionnaire ($t = -0.482$, $P = 0.632$; MCQ, Kirby & Markovic, 1996) measuring impulsivity and discounting (Marcowski et al., in press).

DTI results

We found significant group differences in six anatomical clusters (all results are uncorrected, with threshold values for P from 0.05 to 0.01 and size of significant cluster of at least 50 voxels). According to the White Matter Atlas (Oishi et al., 2010), these clusters contain the following regions: three tracts in cerebellum, retrolenticular part of the internal capsule tract, superior part of the corona radiata tract and part of the occipital gyrus white matter (details in Table 2 and Fig. 2). There was no significant correlation between individual mean FA in the six anatomical regions and the severity of CSBD symptoms, as measured by the Sexual Addiction Screening Test (Gola et al., 2016) and Brief Pornography Screen (Kraus et al., 2020). This was unexpected, since, according to the literature on psychiatric disorders such as addiction and OCD, the severity of symptoms is often correlated with differences in FA (for addiction, see: Morales, Jones, Harman, Patching-Bunch, & Nagel, 2020; De Santis et al., 2019; and for OCD: de Salles Andrade et al., 2019; Fitzgerald, Liu, Reamer, Taylor, & Welsh, 2014; Koch et al., 2012; Saito et al., 2008; Wang et al., 2018; Zhou et al., 2018).

DISCUSSION

This is one of the first DTI studies assessing differences between patients with the Compulsive Sexual Behaviors Disorder and healthy controls. Our analysis has uncovered



Table 2. Results from DTI study comparing 36 CSBD patients with 31 matched healthy controls

Index	Cluster size	x	y	z	T-stat value of the peak	P value of the peak	Effect size ^a	Tract-name from Atlas
1	61	30	-45	-28	5.3103	0.000027776	1.290118	ch, cerebellar hemisphere
2	65	-17	-49	-20	5.1651	0.000046134	1.071367	ch, cerebellar hemisphere
3	88	24	-51	-20	5.0823	0.000061393	1.015533	ch, cerebellar hemisphere
4	64	33	-29	6	5.1738	0.000044763	1.125174	rlc, retrolenticular part of internal capsule
5	52	-40	-62	20	4.9949	0.000082731	1.151454	O2-WM, middle or lateral occipital gyrus white matter
6	71	-25	14	28	4.1236	0.0013267	0.829666	scr, superior corona radiata

^a Cohen's *d* effect size were calculated as a mean difference between two groups divided by the pooled standard deviation.

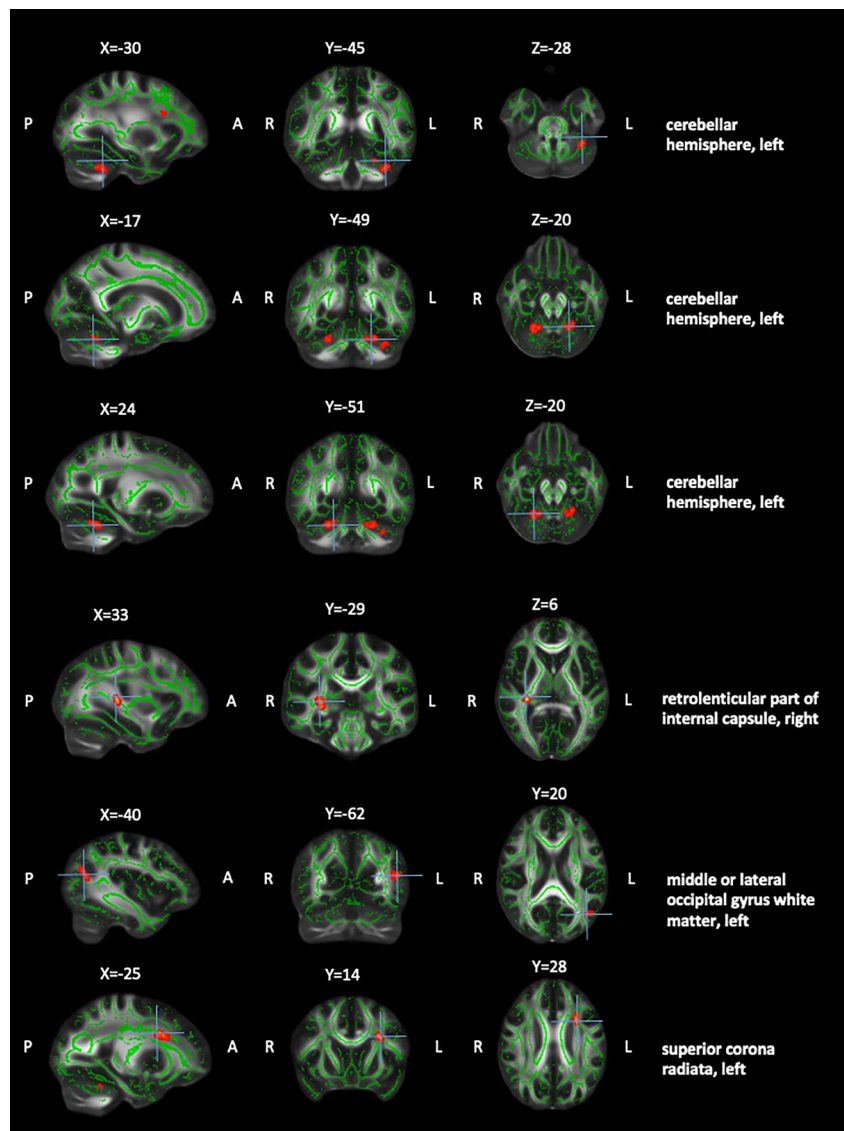


Fig. 2. Differences in fractional anisotropy (FA) between CSBD patients and controls. Mean FA skeleton across all subjects is shown in green over the FMRIB58_FA_1mm template. Results have been thickened for visualization purposes using the standard `tbss_fill` FSL command. Clusters with higher FA values ($P < 0.02$, clusters size > 50) in the control group in comparison to CSBD patients is shown in red. There were no significant results for reverse contrast (CSBD patients $>$ control group)

FA reductions in six regions of the brain in CSBD subjects, compared to controls. The differentiating tracts were found in the cerebellum (there were probably parts of the same tract in the cerebellum), the retrolenticular part of the internal capsule, the superior corona radiata and the middle or lateral occipital gyrus white matter.

To look at these results in the wider context of the entire spectrum of impulsive and compulsive psychiatric disorders, from addiction at one extreme to OCD at the other, we conducted a comprehensive review of literature on DTI in both of the above-mentioned clinical entities. The thirty-nine studies (eight on addiction and 31 on OCD) available in the literature have shown that, as far as DTI is concerned, there is less neuronal diversity in addiction than in OCD. In the OCD literature, the main and frequently reported result concerns a reduction in FA in such regions as the corpus callosum and the cingulum bundle (Benedetti et al., 2013; Bora et al., 2011; Cannistraro et al., 2007; de Salles Andrade et al., 2019; Fan et al., 2016; Gan et al., 2017; Garibotto et al., 2010; Li et al., 2011; Nakamae et al., 2011; Oh et al., 2012; Saito et al., 2008; Spalletta, Piras, Fagioli, Caltagirone, & Piras, 2014; Versace et al., 2019; Yoo et al., 2007; Zhou et al., 2018). In contrast, the addictions literature mentions the posterior corona radiata, external capsule, fornix, insula and hippocampus as the regions that differentiate patients and controls in terms of mean FA (Chumin et al., 2019; De Santis et al., 2019; Pandey et al., 2018; Yip et al., 2017; Zou et al., 2017), as well as other regions found in OCD, i.e., the superior corona radiata, internal capsule, cerebellum, frontal and occipital white matter, superior fasciculus, posterior thalamic radiata, corpus callosum and thalamus (Benedetti et al., 2013; Cannistraro et al., 2007; Chumin et al., 2019; Fan et al., 2012; Fontenelle et al., 2011; Gan et al., 2017; Hartmann, Vandborg, Rosenberg, Sørensen, & Videbeck, 2016; Kim, Jung, Kim, Jang, & Kwon, 2015; Lochner

et al., 2012; Pandey et al., 2018; Segobin et al., 2019; Szeszko et al., 2005; Yip et al., 2017; Yoo et al., 2007; Zhong et al., 2019; Zou et al., 2017). Other regions found in OCD studies are in green area in Figs. 1 and 3 (Glahn, Prell, Grosskreutz, Peschel, & Müller-Vahl, 2015; He et al., 2018; Li, Ji, Li, Li, & Feng, 2014; Menzies et al., 2008; Nakamae et al., 2008; Segobin et al., 2019).

Our DTI data shows that the neural correlates of CSBD overlap with regions previously reported in the literature as related both, to addiction and OCD (see the red area in Fig. 3). Thus, the present study demonstrated an important similarity in shared FA reductions between CSBD and both OCD and addictions. Unfortunately, these results do not indicate which of these two clinical entities is closer to CSBD in terms of DTI correlates.

Limitations

While the present study delivered new data on white matter differences in brain diffusivity in CSBD, its results have some limitations. The main limitation is typical to this kind of correlational study, and concerns the fact that the observed reduction in difference in mean FA between the two samples could be a pre-existing factor or the result of the development of CSBD. This problem affects many other studies of anatomical or functional brain differences using a cross sectional design (Yuan et al., 2010). A longitudinal design is needed to evaluate the role of brain changes as they relate to the development and progression of CSBD symptoms.

Another limitation relates to the recruitment of CSBD participants, which was due to the Hypersexual Disorder (HD; Kafka, 2010), not ICD-11 criteria, as our data were collected before the release of the new WHO's manual. Criteria relating to stress and emotional regulation are present among HD, but not CSBD description (see Gola

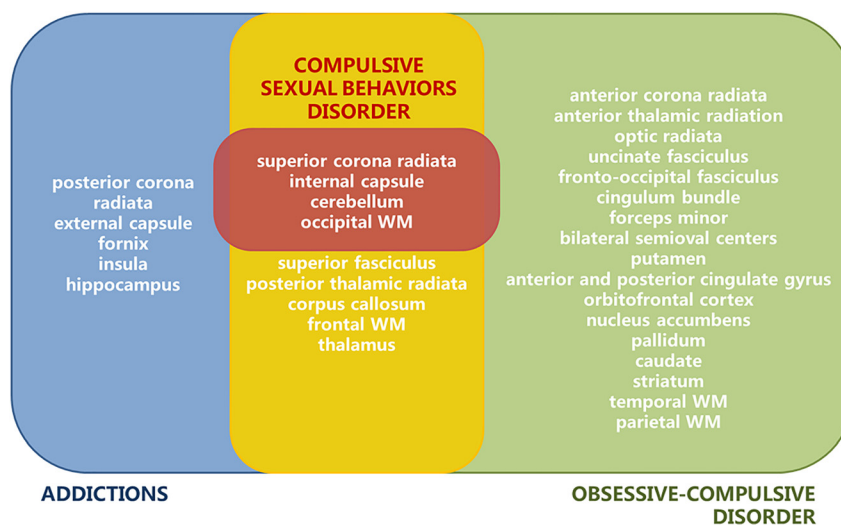


Fig. 3. Overlapping results from literature review on fractional anisotropy (FA) in Addiction and OCD, and results of our DTI study on CSBD patients. FA reductions specific for Addiction (blue), FA reductions specific for OCD (green), regions differentiating both Addiction and OCD patients from healthy controls (yellow), and regions differentiating CSBD patients from healthy controls (red): 3 tracts in cerebellum, retrolenticular part of the internal capsule tract, superior part of the corona radiata tract and part of the occipital gyrus white matter

et al., 2020), therefore our clinical sample might have resemble more an OCD population. More importantly, our sample was relatively small and all the groups consisted of exclusively heterosexual males of similar age, residents of Poland. In future studies of the neurobiological basis of CSBD, larger and more diversified samples need to be recruited. The small sample size could be the reason why our results did not survive the classic FWE correction, and this is yet another limitation of the study. Also, a direct comparison to individuals with addiction and OCD (rather than merely to results reported in the literature) might support stronger conclusions in future studies.

CONCLUSIONS

Results of our study suggest that CSBD shares similar pattern of abnormalities with both OCD and addiction. Compared to controls, CSBD individuals showed significant FA reduction in the superior corona radiata tract, the internal capsule tract, cerebellar tracts and occipital gyrus white matter. As one of the first DTI study comparing structural brain differences between CSBD, addictions and OCD, although it reveals new aspects of CSBD, it is insufficient to determine whether CSBD resembles more an addiction or OCD. Further research, especially comparing directly individuals with all three disorders may provide more conclusive results.

Funding sources: Data collection was supported by the Polish National Science Centre - NCN - grant (2014/15/B/HS6/03792) to MG. MG was supported by gift grant of the Swartz Foundation to the Swartz Center for Computational Neuroscience. NK was supported also by the Foundation of Polish Science (FNP) and Kosciuszko Foundation. MD was supported also by the Polish National Agency for Academic Exchange – NAWA – The Iwanowska Programme (PPN/IWA/2018/1/00018).

Authors' contribution: MD contributed to methods design, subjects recruitment, conducting data collection, data analysis and interpretation, manuscript writing. NK contributed to conducting data analysis and interpretation, manuscript writing. FS contributed to data analysis's consultation, involved in writing manuscript. AM contributed to study and methods design, involved in writing manuscript. MG contributed to study and methods design, data interpretation, manuscript writing, obtaining funding. All authors contributed to and have approved the final manuscript.

Conflict of interest: The authors declare no conflicts of interest with respect to the content of this manuscript.

Acknowledgments: We are grateful to all participants who agreed to be involved in this study.

REFERENCES

- Babor, T. F., de la Fuente, R. J., Saunders, J., & Grant, M. (1989). *AUDIT. The alcohol use disorders identification test. Guidelines for use in primary Health care*. Geneva: World Health Organization.
- Basser, P. J., & Jones, D. K. (2002). Diffusion-tensor MRI: theory, experimental design and data analysis – A technical review. *NMR in Biomedicine*, 15(7), 456–467. <https://doi.org/10.1002/nbm.783>.
- Benedetti, F., Giacosa, C., Radaelli, D., Poletti, S., Pozzi, E., Dal-laspezia, S., et al. (2013). Widespread changes of white matter microstructure in obsessive-compulsive disorder: Effect of drug status. *European Neuropsychopharmacology*, 23(7), 581–593. <https://doi.org/https://doi.org/10.1016/j.euroneuro.2012.07.002>.
- Bora, E., Harrison, B. J., Fornito, A., Cocchi, L., Pujol, J., Fontenelle, L. F., et al. (2011). White matter microstructure in patients with obsessive-compulsive disorder. *Journal of Psychiatry & Neuroscience: JPN*, 36(1), 42–46. <https://doi.org/10.1503/jpn.100082>.
- Brand, M., Snagowski, J., Laier, C., & Maderwald, S. (2016). Ventral striatum activity when watching preferred pornographic pictures is correlated with symptoms of internet pornography addiction. *NeuroImage*, 129, 224–232 <https://doi.org/10.1016/j.neuroimage.2016.01.033>.
- Bóthe, B., Tóth-Király, I., Potenza, M. N., Griffiths, M. D., Orosz, G., & Demetrovics, Z. (2019). Revisiting the role of impulsivity and compulsivity in problematic sexual behaviors. *The Journal of Sex Research*, 56(2), 166–179. <https://doi.org/10.1080/00224499.2018.1480744>.
- Cannistraro, P. A., Makris, N., Howard, J. D., Wedig, M. M., Hodge, S. M., Wilhelm, S., et al. (2007). A diffusion tensor imaging study of white matter in obsessive-compulsive disorder. *Depression and Anxiety*, 24, 440–446. <https://doi.org/10.1002/da.20246>.
- Chumin, E. J., Grecco, G. G., Dziedzic, M., Cheng, H., Finn, P., Sporns, O., et al. (2019). Alterations in white matter microstructure and connectivity in Young adults with alcohol use disorder. *Alcoholism: Clinical and Experimental Research*, 43, 1170–1179. <https://doi.org/10.1111/acer.14048>.
- Coleman, E., Raymond, N., & McBean, A. (2003). Assessment and treatment of compulsive sexual behavior. *Minnesota Medicine*, 86(7), 42–47.
- De Santis, S., Bach, P., Pérez-Cervera, L., Cosa-Linan, A., Weil, G., Vollstädt-Klein, S., et al. (2019). Microstructural white matter alterations in men with alcohol use disorder and rats with excessive alcohol consumption during early abstinence. *JAMA Psychiatry*, 76(7), 749–758. <https://doi.org/10.1001/jamapsychiatry.2019.0318>.
- Deacon, B. J., & Abramowitz, J. S. (2005). The Yale-Brown Obsessive-Compulsive Scale: Factor analysis, construct validity, and suggestions for refinement. *Journal of Anxiety Disorders*, 19, 573–585. <https://doi.org/10.1016/j.janxdis.2004.04.009>.
- Draps, M., Sescousse, G., Potenza, M. N., Marchewka, A., Duda, A., Lew-Starowicz, M., et al. (2020). Gray matter volume differences in impulse control and addictive disorders—an evidence from a sample of heterosexual males. *The Journal of Sexual Medicine*, 17(9), 1761–1769. <https://doi.org/10.1016/j.jsxm.2020.05.007>.

- Fan, S., van den Heuvel, O. A., Cath, D. C., van der Werf, Y. D., de Wit, S. J., de Vries, F. E., et al. (2016). Mild white matter changes in un-medicated obsessive-compulsive disorder patients and their unaffected siblings. *Frontiers in Neuroscience*, 9, 495. <https://doi.org/10.3389/fnins.2015.00495>.
- Fan, Q., Yan, X., Wang, J., Chen, Y., Wang, X., Li, C., et al. (2012). Abnormalities of white matter microstructure in unmedicated obsessive-compulsive disorder and changes after medication. *Plos One*, 7(4), e35889. <https://doi.org/10.1371/journal.pone.0035889>.
- Fineberg, N. A., Chamberlain, S. R., Goudriaan, A. E., Stein, D. J., Vanderschuren, L. J., Gillan, C. M., et al. (2014). New developments in human neurocognition: Clinical, genetic, and brain imaging correlates of impulsivity and compulsivity. *CNS Spectrums*, 19, 69–89. <https://doi.org/10.1017/S1092852913000801>.
- Fitzgerald, K. D., Liu, Y., Reamer, E. N., Taylor, S. F., & Welsh, R. C. (2014). Atypical frontal-striatal-thalamic circuit white matter development in pediatric obsessive-compulsive disorder. *Journal of the American Academy of Child and Adolescent Psychiatry*, 53(11), 1225–1233. <https://doi.org/10.1016/j.jaac.2014.08.010>. e12339.
- Foa, E. B., Huppert, J. D., Leiberg, S., Hajcak, G., Langner, R., & Kichic, R., et al. (2002). The obsessive compulsive inventory: Development and validation of a short version. *Psychological Assessment*, 14, 485–496.
- Fontenelle, L., Bramati, I., Moll, J., Mendlowicz, M., De Oliveira-Souza, R., & Tovar-Moll, F. (2011). White matter changes in OCD revealed by diffusion tensor imaging. *CNS Spectrums*, 16(5), 101–109. <https://doi.org/10.1017/S1092852912000260>.
- Gan, J., Zhong, M., Fan, J., Liu, W., Niu, C., Cai, S., et al. (2017). Abnormal white matter structural connectivity in adults with obsessive-compulsive disorder. *Translational Psychiatry*, 7(3), e1062. <https://doi.org/10.1038/tp.2017.22>.
- Garcia, F. D., & Thibaut, F. (2010). Sexual addictions. *The American Journal of Drug and Alcohol Abuse*, 36, 254–260. <https://doi.org/10.3109/00952990.2010.503823>.
- Garibotto, V., Scifo, P., Gorini, A., Alonso, C. R., Brambati, S., Bellodi, L., et al. (2010). Disorganization of anatomical connectivity in obsessive compulsive disorder: A multi-parameter diffusion tensor imaging study in a subpopulation of patients. *Neurobiology of Disease*, 37(2), 468–476. <https://doi.org/https://doi.org/10.1016/j.nbd.2009.11.003>.
- Genovese, C. R., Lazar, N. A., & Nichols, T. (2002). Thresholding of statistical maps in functional neuroimaging using the false discovery rate. *NeuroImage*, 15(4), 870–878. <https://doi.org/10.1006/nimg.2001.1037>.
- Glahn, A., Prell, T., Grosskreutz, J., Peschel, T., & Müller-Vahl, K. R. (2015). Obsessive-compulsive disorder is a heterogeneous disorder: Evidence from diffusion tensor imaging and magnetization transfer imaging. *BMC Psychiatry*, 15, 135. <https://doi.org/10.1186/s12888-015-0535-5>.
- Gola, M., & Draps, M. (2018). Ventral striatal reactivity in compulsive sexual behaviors. *Frontiers in Psychiatry*, 9, 546.
- Gola, M., Lewczuk, K., Potenza, M. N., Kingston, D. A., Grubbs, J., Stark, R., et al. (2020). What should be included in the criteria for compulsive sexual behaviour disorder? *Journal of Behavioral Addictions*. <https://doi.org/10.1556/2006.2020.00090>.
- Gola, M., Skorko, M., Kowalewska, E., Kołodziej, A., Sikora, M., Wodyk, M., et al. (2016). *Polska adaptacja testu przesiewowego na uzależnienie od zachowań seksualnych (Sexual Addiction Screening Test - Revised)*. SAST-PL-M. Psychiatria Polska. <https://doi.org/10.12740/PP/OnlineFirst/6141>.
- Gola, M., Wordecha, M., Sescousse, G., Lew-Starowicz, M., Kossowski, B., Wypych, M., et al. (2017). Can pornography be addictive? An fMRI study of men seeking treatment for problematic pornography use. *Neuropsychopharmacology*, 42, 2021. <https://doi.org/10.1038/npp.2017.78>.
- Griffiths, M. D. (2016). Compulsive sexual behaviour as a behavioural addiction: The impact of the internet and other issues. *Addiction*, 111, 2107–2108. <https://doi.org/10.1111/add.13315>.
- Guevara, M., Guevara, P., Román, C., & Mangin, J. F. (2020). Superficial white matter: A review on the dMRI analysis methods and applications. *Neuroimage*, 116673. <https://doi.org/10.1016/j.neuroimage.2020.116673>.
- Hartmann, T., Vandborg, S., Rosenberg, R., Sørensen, L., & Videbech, P. (2016). Increased fractional anisotropy in cerebellum in obsessive-compulsive disorder. *Acta Neuropsychiatrica*, 28(3), 141–148. <https://doi.org/10.1017/neu.2015.57>.
- He, X., Steinberg, E., Stefan, M., Fontaine, M., Simpson, H. B., Marsh, R. (2018). Altered frontal interhemispheric and fronto-limbic structural connectivity in unmedicated adults with obsessive-compulsive disorder. *Human Brain Mapping*, 39, 803–810. <https://doi.org/10.1002/hbm.23883>.
- Kafka, M. (2010). Hypersexual disorder: A proposed diagnosis for DSM-V. *Archives of Sexual Behavior*, 39(2), 377–400.
- Kafka, M. P. (2014). What happened to hypersexual disorder? *Archives of Sexual Behavior*, 43(7), 1259–1261. <https://doi.org/10.1007/s10508-014-0326-y>.
- Kim, S. G., Jung, W. H., Kim, S. N., Jang, J. H., & Kwon, J. S. (2015). Alterations of gray and white matter networks in patients with obsessive-compulsive disorder: A multimodal fusion analysis of structural MRI and DTI using mCCA+jICA. *Plos One*, 10(6), e0127118. <https://doi.org/10.1371/journal.pone.0127118>.
- Kirby, K. N., & Marakovic, N. N. (1996). Delay-discounting probabilistic rewards: Rates decrease as amounts increase. *Psychonomic Bulletin & Review*, 3(1), 100–104. <https://doi.org/10.3758/BF03210748>.
- Klucken, T., Wehrum-Osinsky, S., Schweckendiek, J., Kruse, O., & Stark, R. (2016). Altered appetitive conditioning and neural connectivity in subjects with compulsive sexual behavior. *The Journal of Sexual Medicine*, 13(4), 627–636. <https://doi.org/10.1016/j.jsxm.2016.01.013>.
- Koch, K., Wagner, G., Schachtzabel, C., Schultz, C. C., Straube, T., & Güllmar, D., et al. (2012). White matter structure and symptom dimensions in obsessive-compulsive disorder. *Journal of Psychiatric Research*, 46(2), 264–270. <https://doi.org/10.1016/j.jpsychores.2011.10.016>.
- Kowalewska, E., Grubbs, J. B., Potenza, M. N., Gola, M., Draps, M., & Kraus, S. W. (2018). Neurocognitive mechanisms in compulsive sexual behavior disorder. *Current Sexual Health Reports*, 10(4), 255–264.
- Kraus, S. W., Gola, M., Grubbs, J. B., Kowalewska, E., Hoff, R. A., Lew-Starowicz, M., et al. (2020). Validation of a Brief pornography screen across multiple samples, *Journal of Behavioral*



- Addictions*, 9(2), 259–271. Retrieved September 17, 2020 <https://doi.org/10.1556/2006.2020.00038>.
- Kraus, S. W., Krueger, R. B., Briken, P., First, M. B., Stein, D. J., Kaplan, M. S., et al. (2018). Compulsive sexual behaviour disorder in the ICD-11. *World Psychiatry*, 17, 109–110. <https://doi.org/10.1002/wps.20499>.
- Kraus, S. W., Voon, V., & Potenza, M. N. (2016). Should compulsive sexual behavior be considered an addiction? *Addiction*. <https://doi.org/10.1111/add.13297>.
- Kühn, S., & Gallinat, J. (2014). Brain structure and functional connectivity associated with pornography consumption: The brain on porn. *JAMA Psychiatry*, 71(7), 827–834.
- Kühn, S., & Gallinat, J. (2016). Neurobiological basis of hypersexuality. *International Review of Neurobiology*, 1–17. <https://doi.org/10.1016/bs.irn.2016.04.002>.
- Le Bihan, D. (2003). Looking into the functional architecture of the brain with diffusion MRI. *Nature Reviews. Neuroscience*, 4(6), 469–480. <https://doi.org/10.1038/nrn1119>.
- Le Bihan, D., Mangin, J. F., Poupon, C., Clark, C. A., Pappata, S., & Molko, N., et al. (2001). Diffusion tensor imaging: concepts and applications. *Journal of Magnetic Resonance Imaging: JMRI*, 13(4), 534–546. <https://doi.org/10.1002/jmri.1076>.
- Lew-Starowicz, M., Lewczuk, K., Nowakowska, I., Kraus, S., & Gola, M. (2020). Compulsive sexual behavior and dysregulation of emotion. *Sexual Medicine Reviews*, 8(2), 191–205.
- Li, F., Huang, X., Yang, Y., Li, B., Wu, Q., Zhang, T., et al. (2011). Microstructural brain abnormalities in patients with obsessive-compulsive disorder: Diffusion-tensor MR imaging study at 3.0 T. *Radiology*, 260(1), 216–223. <https://doi.org/10.1148/radiol.11101971>.
- Li, Z., Ji, W., Li, D., Li, X., & Feng, W. (2014). Microstructural abnormality in left nucleus accumbens predicts dysfunctional beliefs in treatment-resistant obsessive-compulsive disorder. *Medical Science Monitor : International Medical Journal of Experimental and Clinical Research*, 20, 2275–2282. <https://doi.org/10.12659/MSM.891102>.
- Lochner, C., Fouché, J. P., du Plessis, S., Spottiswoode, B., Seedat, S., Fineberg, N., et al. (2012). Evidence for fractional anisotropy and mean diffusivity white matter abnormalities in the internal capsule and cingulum in patients with obsessive-compulsive disorder. *Journal of Psychiatry & Neuroscience : JPN*, 37(3), 193–199. <https://doi.org/10.1503/jpn.110059>.
- Marcowski, P., Kowalewska, E., Sadowski, J., & Gola, M. (2020). Delay discounting among individuals with compulsive sexual behaviors in 12-Step groups. *Journal of Behavioral Addiction*. (in press).
- Menzies, L., Williams, G. B., Chamberlain, S. R., Ooi, C., Fineberg, N., Suckling, J., et al. (2008). White matter abnormalities in patients with obsessive-compulsive disorder and their first-degree relatives. *American Journal of Psychiatry*, 165(10), 1308–1315. <https://doi.org/10.1176/appi.ajp.2008.07101677>.
- Mick, T. M., & Hollander, E. (2006). Impulsive-compulsive sexual behavior. *CNS Spectrum*, 11(12), 944–955. <https://doi.org/10.1017/s1092852900015133>.
- Miner M. H., Dickenson, J., & Coleman E. (2019). Effects of emotions on sexual behavior in men with and without hypersexuality. *Sexual Addiction & Compulsivity*, 26(1–2), 24–41. <https://doi.org/10.1080/10720162.2018.1564408>.
- Morales, A. M., Jones, S. A., Harman, G., Patching-Bunch, J., & Nagel, B. J. (2020). Associations between nucleus accumbens structural connectivity, brain function, and initiation of binge drinking. *Addiction Biology*, 25(3), e12767. <https://doi.org/10.1111/adb.12767>.
- Nakamae, T., Narumoto, J., Sakai, Y., Nishida, S., Yamada, K., Nishimura, T., et al. (2011). Diffusion tensor imaging and tract-based spatial statistics in obsessive-compulsive disorder. *Journal of Psychiatric Research*, 45(5), 687–690. <https://doi.org/https://doi.org/10.1016/j.jpsychires.2010.09.016>.
- Nakamae, T., Narumoto, J., Shibata, K., Matsumoto, R., Kitabayashi, Y., Yoshida, T., et al. (2008). Alteration of fractional anisotropy and apparent diffusion coefficient in obsessive-compulsive disorder: A diffusion tensor imaging study. *Progress in Neuro-Psychopharmacology and Biological Psychiatry*, 32(5), 1221–1226. <https://doi.org/https://doi.org/10.1016/j.pnpbp.2008.03.010>.
- Oh, J.S., Jang, J.H., Jung, W.H., Kang, D.-H., Choi, J.-S., Choi, C.-H., et al. (2012). Reduced fronto-callosal fiber integrity in unmedicated OCD patients: A diffusion tractography study. *Human Brain Mapping*, 33: 2441–2452. <https://doi.org/10.1002/hbm.21372>.
- Oishi, K., Faria, A. V., Van Zijl, P. C., & Mori, S. (2010). *MRI atlas of human white matter*. Academic Press.
- Pandey, A. K., Ardekani, B. A., Kamarajan, C., Zhang, J., Chorlian, D. B., Byrne, K. N., et al. (2018). Lower prefrontal and hippocampal volume and diffusion tensor imaging differences reflect structural and functional abnormalities in abstinent individuals with alcohol use disorder. *Alcoholism: Clinical and Experimental Research*, 42(10), 1883–1896. <https://doi.org/10.1111/acer.13854>.
- Potenza, M. N., Gola, M., Voon, V., Kor, A., & Kraus, S. W. (2017). Is excessive sexual behaviour an addictive disorder? *The Lancet Psychiatry*, 4(9), 663–664. [https://doi.org/10.1016/S2215-0366\(17\)30316-4](https://doi.org/10.1016/S2215-0366(17)30316-4).
- Reid, R. C., Carpenter, B. N., Hook, J. N., Garos, S., Manning, J. C., et al. (2012). Report of findings in a DSM-5 field trial for hypersexual disorder. *Journal of Sexual Medicine*, 9, 2868–2877. <https://doi.org/10.1111/j.1743-6109.2012.02936.x>.
- Reid, R. C., & Kafka, M. P. (2014). Controversies about hypersexual disorder and the DSM-5. *Current Sexual Health Reports*, 6(4), 259–264. <https://doi.org/10.1007/s11930-014-0031-9>.
- Saito, Y., Nobuhara, K., Okugawa, G., Takase, K., Sugimoto, T., Horiuchi, M., et al. (2008). Corpus callosum in patients with obsessive-compulsive disorder: Diffusion-tensor imaging study. *Radiology*, 246(2), 536–542. <https://doi.org/10.1148/radiol.2462061469>.
- de Salles Andrade, J. B., Ferreira, F. M., Suo, C., Yücel, M., Frydman, I., Monteiro, M., et al. (2019). An MRI study of the metabolic and structural abnormalities in obsessive-compulsive disorder. *Frontiers in Human Neuroscience*, 13, 186. <https://doi.org/10.3389/fnhum.2019.00186>.
- Segobin, S., Laniepe, A., Ritz, L., Lannuzel, C., Boudehent, C., Cabé, N., et al. (2019). Dissociating thalamic alterations in alcohol use disorder defines specificity of Korsakoff's syndrome. *Brain*, 142(5), 1458–1470. <https://doi.org/10.1093/brain/awz056>.
- Seok, J. W., & Sohn, J. H. (2015). Neural substrates of sexual desire in individuals with problematic hypersexual behavior. *Frontiers*

- in *Behavioral Neuroscience*, 9, 321. <https://doi.org/10.3389/fnbeh.2015.00321>.
- Seok, J. W., & Sohn, J. H. (2018). Gray matter deficits and altered resting-state connectivity in the superior temporal gyrus among individuals with problematic hypersexual behavior. *Brain Research*, 1684, 30–39. <https://doi.org/10.1016/j.brainres.2018.01.035>.
- Smith, S. M., Jenkinson, M., Johansen-Berg, H., Rueckert, D., Nichols, T. E., Mackay, C. E., et al. (2006). Tract-based spatial statistics: Voxelwise analysis of multi-subject diffusion data. *NeuroImage*, 31(4), 1487–1505. <https://doi.org/10.1016/j.neuroimage.2006.02.024>.
- Smith, S. M., Jenkinson, M., Woolrich, M. W., Beckmann, C. F., Behrens, T. E. J., Johansen-Berg, H., et al. (2004). Advances in functional and structural MR image analysis and implementation as FSL. *NeuroImage*, 23, 208–219. <https://doi.org/10.1016/j.neuroimage.2004.07.051>.
- Spalletta, G., Piras, F., Fagioli, S., Caltagirone, C., & Piras, F. (2014). Brain microstructural changes and cognitive correlates in patients with pure obsessive compulsive disorder. *Brain and Behavior*, 4(2), 261–277. <https://doi.org/10.1002/brb3.212>.
- Stinchfield, R. (2002). Reliability, validity, and classification accuracy of the South Oaks Gambling screen (SOGS). *Addictive Behaviors*, 27, 1–19. [https://doi.org/10.1016/s0306-4603\(00\)00158-1](https://doi.org/10.1016/s0306-4603(00)00158-1).
- Szeszko, P. R., Ardekani, B. A., Ashtari, M., Malhotra, A. K., Robinson, D. G., Bilder, R. M., et al. (2005). White matter abnormalities in obsessive-compulsive disorder: A diffusion tensor imaging study. *Archives of General Psychiatry*, 62(7), 782–790. <https://doi.org/10.1001/archpsyc.62.7.782>.
- Versace, A., Graur, S., Greenberg, T., Lima Santos, J. P., Chase, H. W., Bonar, L., et al. (2019). Reduced focal fiber collinearity in the cingulum bundle in adults with obsessive-compulsive disorder. *Neuropsychopharmacology: Official Publication of the American College of Neuropsychopharmacology*, 44(7), 1182–1188. <https://doi.org/10.1038/s41386-019-0353-4>.
- Voon, V., Mole, T. B., Banca, P., Porter, L., Morris, L., Mitchell, S., et al. (2014). Neural correlates of sexual cue reactivity in individuals with and without compulsive sexual behaviours. *Plos One*, 9(7), e102419. <https://doi.org/10.1371/journal.pone.0102419>.
- Wang, R., Fan, Q., Zhang, Z., Chen, Y., Zhu, Y., & Li, Y. (2018). Anterior thalamic radiation structural and metabolic changes in obsessive-compulsive disorder: A combined DTI-MRS study. *Psychiatry Research: Neuroimaging*, 277, 39–44. <https://doi.org/10.1016/j.pscychresns.2018.05.004>.
- Wierzba, M., Riegel, M., Pucz, A., Leśniewska, Z., Dragan, W. Ł., Gola, M., et al. (2015). Erotic subset for the Nencki affective picture system (NAPS ERO): Cross-sexual comparison study. *Frontiers in Psychology*, 6, 1336. <https://doi.org/10.3389/fpsyg.2015.01336>.
- Wordecha, M., Wilk, M., Kowalewska, E., Skorko, M., Łapiński, A., & Gola, M. (2018). “Pornographic binges” as a key characteristic of males seeking treatment for compulsive sexual behaviors: Qualitative and quantitative 10-week-long diary assessment. *Journal of Behavioral Addictions*, 7(2), 433–444. <https://doi.org/10.1556/2006.7.2018.33>.
- World Health Organization (2018). *ICD-11 for mortality and morbidity Statistics*. From: <https://icd.who.int/browse11/l-m/en#/http://id.who.int/icd/entity/1630268048>.
- Yip, S. W., Morie, K. P., Xu, J., Constable, R. T., Malison, R. T., Carroll, K. M., et al. (2017). Shared microstructural features of behavioral and substance addictions revealed in areas of crossing fibers. *Biological Psychiatry: Cognitive Neuroscience and Neuroimaging*, 2(2), 188–195. <https://doi.org/10.1016/j.bpsc.2016.03.001>.
- Yoo, S.Y., Jang, J.H., Shin, Y.-W., Kim, D.J., Park, H.-J., Moon, W.-J., et al. (2007). White matter abnormalities in drug-naïve patients with obsessive-compulsive disorder: A diffusion tensor study before and after citalopram treatment. *Acta Psychiatrica Scandinavica*, 116, 211–219. <https://doi.org/10.1111/j.1600-0447.2007.01046.x>.
- Young, K. S. (2008). Internet sex addiction: Risk factors, stages of development, and treatment. *American Behavioral Scientist*, 52(1), 21–37. <https://doi.org/10.1177/0002764208321339>.
- Yuan, K., Qin, W., Dong, M., Liu, J., Sun, J., Liu, P., et al. (2010). Gray matter deficits and resting-state abnormalities in abstinent heroin-dependent individuals. *Neuroscience Letters*, 482, 101–105. <https://doi.org/10.1016/j.neulet.2010.07.005>.
- Zhong, Z., Yang, X., Cao, R., Li, P., Li, Z., Lv, L., et al. (2019). Abnormalities of white matter microstructure in unmedicated patients with obsessive-compulsive disorder: Changes after cognitive behavioral therapy. *Brain and Behavior*, 9(2), e01201. <https://doi.org/10.1002/brb3.1201>.
- Zhou, C., Xu, J., Ping, L., Zhang, F., Chen, W., & Shen, Z., et al. (2018). Cortical thickness and white matter integrity abnormalities in obsessive-compulsive disorder: A combined multi-modal surface-based morphometry and tract-based spatial statistics study. *Depression and Anxiety*, 35, 742–751. <https://doi.org/10.1002/da.22758>.
- Zou, Y., Murray, D. E., Durazzo, T. C., Schmidt, T. P., Murray, T. A., & Meyerhoff, D. J. (2017). Effects of abstinence and chronic cigarette smoking on white matter microstructure in alcohol dependence: Diffusion tensor imaging at 4T. *Drug and Alcohol Dependence*, 175, 42–50. <https://doi.org/10.1016/j.drugalcdep.2017.01.032>.

