

Eruptive lentiginosis in resolving psoriatic plaques



Robert Micieli, BSc,^a and Afsaneh Alavi, MSc, MD, FRCPC^{a,b}
 Toronto, Ontario, Canada

Key words: hyperpigmentation; lentiginosis; macules; plaque psoriasis.

INTRODUCTION

Eruptive lentiginosis confined to areas of resolving psoriatic plaques (ELRP) is a rare occurrence. A number of previous reports have described this phenomenon after the use of different treatment modalities to resolve psoriatic plaques, including topical, ultraviolet light, and biologic therapies. We present a case of ELRP after treatment with secukinumab. A review of the literature synthesizing all available reports describing lentiginous macules at the site of resolving psoriatic plaques was completed to describe the patient population, treatments, and clinical characteristics associated with this entity.

CASE REPORT

A 29-year-old man with Fitzpatrick skin type III-IV presented with a 6-year history of chronic plaque psoriasis. His psoriasis was not previously treated and he was not on any other medications. He had no other significant medical history. On physical examination, the patient had diffuse psoriatic plaques on the trunk and extremities with scalp and nail involvement covering roughly 20% body surface area. Treatment with secukinumab was initiated at a psoriasis-scheduled dose. Resolution of the psoriatic plaques started 3 weeks after initiation of secukinumab with complete clearance after 3 months. However, at 3 months, the patient presented with multiple 2- to 5-mm light to dark brown fairly symmetrical macules located on the upper extremities and trunk that were confined to previous sites of psoriatic plaques (Fig 1). Lentiginosis appeared in all areas of resolution; however, some areas had a higher density of lentiginosis relative to others. The patient did not have a history of lentiginosis, no

Abbreviations used:

ELRP: eruptive lentiginosis in resolving psoriatic plaques
 IL: interleukin
 TNF: tumor necrosis factor

phototherapy was performed, and the patient denied sun exposure on the affected areas during the treatment period. A punch biopsy of a macule found elongation of the rete ridges with mild acanthosis and hyperpigmentation of the basal layer compatible with lentigo (Fig 2). Treatment was continued, and follow-up of 3 months found no change in the macules.

DISCUSSION

Our case report describes ELRP after anti-interleukin (IL)-17 treatment and adds to the growing body of literature describing this phenomenon. A MEDLINE, EMBASE, and PubMed search and review of the references was conducted and found that ELRP has been described in 12 studies (10 case reports, 2 case series) for a total of 18 patients (Table I). Patients with a history of phototherapy were excluded. These lentiginous eruptions have been most commonly reported after treatment with biologics, which was the case for 6 reports representing a total of 7 patients (39%).

Biopsy results of the pigmented macules, when reported, were consistent with a diagnosis of lentigo. Based on the published reports, these lentiginosis appear within the first 6 months of treatment initiation, appearing as early as 3 months in some cases. All patients, with the exception of our patient

From the Faculty of Medicine, University of Toronto^a and the Department of Medicine, Division of Dermatology, Women's College Hospital.^b

Funding sources: None.

Conflicts of interest: None declared.

Correspondence to: Afsaneh Alavi, MSc, MD, FRCPC, Assistant Professor, Division of Dermatology, Women's College Hospital, 76 Grenville Street, 5th floor, Toronto, ON M5S 1B2, Canada. E-mail: afsaneh.alavi@mail.utoronto.ca.

JAAD Case Reports 2018;4:322-6.
 2352-5126

© 2017 by the American Academy of Dermatology, Inc. Published by Elsevier, Inc. This is an open access article under the CC BY-NC-ND license (<http://creativecommons.org/licenses/by-nc-nd/4.0/>).

<https://doi.org/10.1016/j.jdcr.2017.10.009>

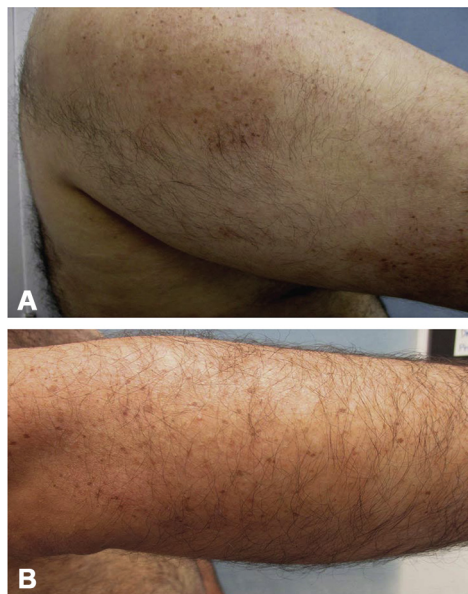


Fig 1. Eruptive lentiginosis in previous sites of psoriatic plaques on the right shoulder (A) and right arm (B).

described above, received prior treatment for their psoriasis that included 1 or a combination of topical and systemic therapies. Although follow-up was only reported for 4 patients, it seems as though the lentiginos persist with little to no improvement for several years after onset. For instance, in 1 case report, minimal improvement was found in the lentiginos over a period of 5 years. However, treatment with a Q-switched ruby laser has led to partial clearance of the pigmented lesions in one patient.¹

The age of the patient population for which ELRP was described ranged from 7 to 74 years with an average age of 48. Two of these patients were younger than 18 years. Gender was reported for only 12 of the patients, of which, 7 were male and 5 were female. Furthermore, patients had a prolonged history of psoriasis ranging from 6 to 40 years before the onset of lentiginos. This phenomenon was described in 2 patients with Fitzpatrick skin type 2 and in 8 patients with skin types 3 or 4. Skin type was not stated for the remaining 8 patients.

The pathophysiology of ELRP is not well understood. Since these pigmented lesions have appeared after a number of different treatment modalities, a common pathway affecting melanocytes is potentially implicated. A previous study by Wang et al² provides some insight into this mechanism. They found high levels of cytokines IL-17 and tumor necrosis factor (TNF) in psoriatic plaques. These cytokines, in addition to others, help stimulate

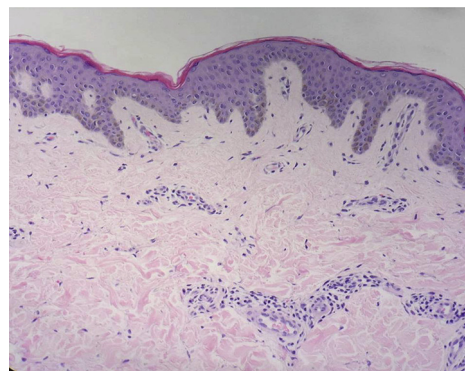


Fig 2. Punch biopsy of a macule found elongation of the rete ridges with mild acanthosis and hyperpigmentation of the basal layer compatible with lentigo.

melanocytic growth such that psoriatic lesions have almost twice as many melanocytes as nonlesional skin. The high levels of these cytokines also contribute to the suppression of those genes responsible for pigment production. Consequently, therapeutic neutralization of TNF and IL-17 with biologics reduced the inhibition of melanogenesis and led to a rapid recovery in pigment production in all patients that were treated with anti-TNF (etanercept) and anti-IL-17 (ixekizumab). The increased number of melanocytes combined with a recovery in pigment production led to an abundant production of melanin in resolving psoriatic plaques, potentially explaining the lentiginos observed in this study. Although Wang et al² only focused on IL-17 and TNF, there may be several other cytokines and factors that help regulate melanogenesis³ and melanocytic growth that are targeted by other biologics and treatments described in this study. Previous reports of eruptive lentiginosis after chemotherapy in cancer patients⁴⁻⁶ provides further support that immune modulation may be responsible for these eruptions.

ELRP has only been reported in a small subset of patients. Perhaps ELRP represents a more exaggerated recovery in pigment production, associated with greater disease severity or greater inhibition of cytokines with treatment. Supporting this is the fact that in some patients, ELRP appeared after the resolution of thick psoriatic plaques and not thin ones. As well, it has been suggested that certain mutations in signaling proteins may predispose certain individuals to lentiginos development, as immune modulation may be greater in these individuals.^{5,7} Overall, it seems that the rapid clearance of psoriatic plaques with new targeted therapies may contribute to the appearance of ELRP.

Table I. Description of all reports on the appearance of eruptive lentiginosis in resolving psoriatic plaques

Treatment class	Reference	Most recent treatment before lesions	Patient details	Lesion details	Time to onset of lesions	Histopathology	Prior psoriatic treatment	Follow-up
Biologics	Santos-Juanes et al., <i>Dermatology</i> . 2008;216(3):279	Adalimumab (40 mg once every 15 d)	55 yo woman, 25-y history of psoriasis	Light and brown regular lentiginosis over the previous sites of the psoriatic plaques	2 mo after treatment	Confirmation of lentiginosis	Topical steroids, tacalcitol, calcipotriol, methotrexate	NS
	Alman-Fernandez and Fernandez-Crehuet, <i>Eur J Dermatol</i> . 2015;25(4):354-356	Etanercept (50 mg twice weekly)	53 yo woman, 30-y history of psoriasis	Multiple small pigmented lesions in areas previously affected by psoriasis. On forearms, legs, and buttocks.	NS	Consistent with lentiginosis. No actinic damage.	Topical treatments, methotrexate, acitretin	NS
			60 yo man, 40-y history of psoriasis	Grouped brown macules over areas previously affected by psoriasis. Non sun-exposed areas involved. Coexistence of macules and psoriasis plaque on elbows.	5 mo after treatment	Consistent with lentiginosis	Topical and systemic therapies	NS
	LaRosa et al., <i>Pediatr Dermatol</i> . 2015;32(3):e114-117	Etanercept (50 mg weekly)	16 yo Hispanic boy, 9-y history of severe plaque psoriasis covering 40% of body surface area, skin type 3	Speckled lentiginous macules within dark-tan hyperpigmented patches, resembling nevus spilus in resolving plaques on chest and back	Appeared before Etanercept treatment and 3 months after treatment	NS	Triamcinolone, calcipotriene, acitretin, methotrexate	28 mo; development of additional macules
	Dogan and Atakan, <i>Cutan Ocul Toxicol</i> . 2015;34(3):262-264	Infliximab (5 mg/kg IV per 8 weeks after 0 and 2 week infusions)	55 yo white woman, 12-year history of psoriasis, skin type 3	Small, 2- to 3-mm light and dark brownish hyperpigmented macules were found on each resolved psoriatic plaque	NS	NS	Topical corticosteroids, emollients, systemic methotrexate, adalimumab	NS
	Micieli and Alavi (current study)	Secukinumab	29 yo, 6-y history of plaque psoriasis, skin type 3-4	Multiple 2- to 5-mm light to dark brown fairly symmetrical macules located on the upper extremities and trunk that were confined to previous sites of psoriatic plaques	3 mo after treatment	Elongation of the rete ridges with mild acanthosis and hyperpigmentation of the basal layer compatible with benign lentigo	None	3 mo; lentiginosis still present without improvement
	Gutierrez-Gonzalez et al., <i>Dermatol Online J</i> . 2014;20(4):22338	Ustekinumab (45 mg every 12 weeks)	40 yo, 15-y history of plaque psoriasis, skin type 4	Multiple grouped but not confluent, brown macules of 2-3 mm over well-defined slightly hyperpigmented areas previously affected by psoriasis on trunk and extremities	6 mo after treatment	Not performed	Topical corticosteroids, calcipotriol, systemic acitretin, methotrexate	NS

Ultraviolet light (\pm other treatments)	Mitra et al ¹	Dithranol + UVB phototherapy (cumulative dose 6.73 J/cm ²)	55 yo man, 28-y history of psoriasis, skin type 2	Light and dark brown macules around the periphery of the cleared psoriasis plaques	6 mo after treatment	Small areas of epidermal basal layer hyperpigmentation	NS	4 y; macules still present without improvement
	Dawn et al., <i>Clin Exp Dermatol.</i> 2001;26(5):459	Coal tar, dithranol, topical steroids, UVB	67 yo man, 20-y history of psoriasis	Dark lentigines on psoriasis plaques on thigh	NS	Confirmed presence of lentigines	NS	NS
Other	Sfecci et al., <i>J Am Acad Dermatol.</i> 2016;75(6):1251-1252	Apremilast (30 mg)	4* of 21 patients (19%) treated had lentigines. Age range, 39-74 y and Fitzpatrick skin type 3 or 4	Lentigines only in areas of resolving psoriatic plaques. Most occurred in sun-protected areas.	0-4 mo after treatment	Not performed	3 patients, methotrexate 1 patient, NS	5 y; lentigines still present
	Marti et al., <i>Dermatol Online J.</i> 2009;15(10):15	Calcipotriol	65 yo man, 30-y history of psoriasis, skin type 2	Small dark brown macules within light brown macules on his trunk, buttocks, and extremities where there was resolution of thick plaque psoriasis. No macules in less thick psoriatic plaques.	3 mo after treatment	Basal cell hyperpigmentation and elongation of the rete ridges with some anastomoses between them. Melanophages present in the upper dermis.	Topical corticosteroids	NS
	Rogers, <i>Clin Exp Dermatol.</i> 1995;20(5):446	Liquor picis carbonis 4% in aqueous cream and a fluorinated topical steroid	7 yo man	Lentigines at sites of very thick resolving plaques. No lentigines at other less thick resolving psoriatic lesions.	NS	NS	No phototherapy	NS
	Dawn et al., <i>Clin Exp Dermatol.</i> 2001;26(5):459	Coal tar, dithranol, topical steroids	74 yo woman, 40-y history of psoriasis mainly on elbows, knees, and hands	Dark irregular lentigines on the hands	NS	Confirmed presence of lentigines	NS	NS
		Topical steroids, crude coal tar	56 yo man, 15-y history of psoriasis limited to hands (including palms)	Dark lentigines that have increased in number but remain limited to areas affected by psoriasis	NS	Confirmed presence of lentigines	NS	NS
		Coal tar, dithranol, topical steroids, calcipotriol	41 yo woman, 25-y history of plaque psoriasis	Dark irregular 3- to 5-mm macular pigmentation limited to psoriasis plaques on the elbows and knuckles of the right hand for 15 years	NS	Features of lentigo	NS	NS

NB-UVB, Narrowband ultraviolet B; NS, not stated; PUVA, psoralen and ultraviolet A; UVB, ultraviolet B; yo, years old.

*One patient who had lentigines was omitted because of a history of phototherapy.

REFERENCES

1. Mitra A, Yeung R, Sheehan-Dare R, Wilson CL. Lentiginous hyperpigmentation confined to resolved psoriatic plaques and treated with a Q-switched ruby laser. *Clin Exp Dermatol*. 2006; 31(2):298-299.
2. Wang CQ, Akalu YT, Suarez-Farinas M, et al. IL-17 and TNF synergistically modulate cytokine expression while suppressing melanogenesis: potential relevance to psoriasis. *J Invest Dermatol*. 2013;133(12):2741-2752.
3. Kotobuki Y, Tanemura A, Yang L, et al. Dysregulation of melanocyte function by Th17-related cytokines: significance of Th17 cell infiltration in autoimmune vitiligo vulgaris. *Pigment Cell Melanoma Res*. 2012;25(2):219-230.
4. De D, Dogra S, Kanwar AJ, Saikia UN. Generalized eruptive lentiginosis induced by chemotherapy. *Clin Exp Dermatol*. 2010;35(4):e113-115.
5. Kong HH, Sibaud V, Chanco Turner ML, Fojo T, Hornyak TJ, Chevreau C. Sorafenib-induced eruptive melanocytic lesions. *Arch Dermatol*. 2008;144(6):820-822.
6. Uhlenhake EE, Watson AC, Aronson P. Sorafenib induced eruptive melanocytic lesions. *Dermatol Online J*. 2013;19(5): 18184.
7. Alaiabac M, Piaserico S, Rossi CR, et al. Eruptive melanocytic nevi in patients with renal allografts: report of 10 cases with dermoscopic findings. *J Am Acad Dermatol*. 2003;49(6): 1020-1022.