

Improvement of peripheral artery disease with Sildenafil and Bosentan combined therapy in a patient with limited cutaneous systemic sclerosis

A case report

Loukman Omarjee, MD, MSc^{a,b,*}, Cedric Fontaine, MD^c, Guillaume Mahe, MD, PhD^a, Vincent Jaquinandi, MD, PhD^a

Abstract

Rationale: Sildenafil, a phosphodiesterase-5-inhibitor and Bosentan, an endothelin-1-receptor antagonist combined therapy could have beneficial effect in systemic sclerosis (SSc) patients with peripheral artery disease.

Patient concerns: We report a case of a 48-year-old Black woman, who developed severe left limb claudication and walking limitation following a left femoropopliteal bypass occlusion in 2014. She was a heavy smoker and had a history of right middle cerebral artery ischemic stroke and bilateral Raynaud phenomenon.

Diagnoses: According to the American College of Rheumatology/European League Against Rheumatism-2013 criteria, diagnosis of limited cutaneous SSc was retained with macrovascular lesions. She was referred for investigation of left limb claudication on treadmill using transcutaneous oxygen pressure measurement during exercise to argue for the vascular origin of the walking impairment. She had a severe left limb ischemia and the maximum walking distance (MWD) she reached was 118 m in March 2015 despite the medical optimal treatment and walking rehabilitation.

Interventions: Sildenafil, 20 mg tid, was introduced due to active digital ulcers. In July 2015, the MWD increased to 288 m, then to 452 m in December 2015. Adding Bosentan to Sildenafil to prevent recurrent digital ulcers resulted in an MWD of 1576 m.

Outcomes: Recently, the patient is treated with the combined therapy. She has no more pain during walking and his quality of life has improved.

Lessons: Sildenafil and Bosentan combined therapy was associated in our case with an improvement of MWD without adverse effect. Further clinical trials are necessary to confirm our original observation.

Abbreviations: cGMP = cyclic guanosine-5-monophosphate, DLCO/VA = diffusing capacity of the lung for carbon monoxide divided by alveolar volume, DROP = decrease from rest of oxygen pressure, DROPmin = the minimal DROP value, ET1 = endothelin-1, MWD = maximal walking distance, NO = nitric oxide, PAD = peripheral artery disease, PDE5i = phosphodiesterase-5-inhibitor, SSc = systemic sclerosis, tcpO₂ = transcutaneous oxygen pressure.

Keywords: Bosentan, exercise tcpO₂, peripheral artery disease, scleroderma, Sildenafil, systemic sclerosis, treadmill walking test

Editor: Raouf Hajji.

Key Message.

Sildenafil, a phosphodiesterase-5-inhibitor and Bosentan, an endothelin-1-receptor antagonist are a highly effective treatment for pulmonary arterial hypertension and digital ulcers in systemic sclerosis. They may represent a new therapeutic option in addition to the conventional optimal medical therapy in patients with macrovascular involvement specifically peripheral artery disease in systemic sclerosis.

Main lessons to learn: Our observation suggests that in this case of macrovascular impairment in systemic sclerosis, the combination of vasoactive drugs characterized by vasodilating property of nitric oxide, enhanced by Sildenafil, and ET1-receptor antagonism, by Bosentan, may provide a synergic effect in peripheral artery disease scleroderma patients (Fig. 2, left panel) without adverse event. Further clinical trials are necessary to confirm this observation.

Data sharing not applicable to this article as no datasets were generated or analyzed during the present study.

Written consent to publication was obtained from the patient.

LO contributed to the management of the patient, treatment strategy, literature search, data collection, data analysis, data interpretation, and writing the report. CF, GM, and VJ contributed to critical review of the concerned article, data interpretation, literature search, and writing the report.

The authors have no funding and conflicts of interest to disclose.

^aUnité de Médecine Vasculaire, INSERM CIC 1414, Pôle Imagerie Médicale et Explorations Fonctionnelles, CHU de Rennes, 35033 Rennes Cedex, France., ^bMitoVasc Institute, UMR CNRS 6015—INSERM U1083, Angers University Hospital, Angers Cedex, ^cUnité de Médecine Vasculaire, Plateau des Consultations Médicales, Cholet Cedex France.

* Correspondence: Dr Loukman Omarjee, Vascular Physician and Clinical Immunologist, Unité de Médecine Vasculaire Pôle imagerie médicale et explorations fonctionnelles. Hôpital Pontchaillou 2 rue Henri Le Guilloux Rennes, F-35033. France (e-mail: loukmano@yahoo.fr).

Copyright © 2017 the Author(s). Published by Wolters Kluwer Health, Inc.

This is an open access article distributed under the terms of the Creative Commons Attribution-Non Commercial-No Derivatives License 4.0 (CCBY-NC-ND), where it is permissible to download and share the work provided it is properly cited. The work cannot be changed in any way or used commercially without permission from the journal. Medicine (2017) 96:25(e6988)

Received: 4 February 2017 / Received in final form: 29 April 2017 / Accepted: 1 May 2017

<http://dx.doi.org/10.1097/MD.0000000000006988>

1. Introduction

Sildenafil, a phosphodiesterase-5-inhibitor (PDE5i) and Bosentan, an endothelin-1 (ET1)-receptor antagonist are a highly effective treatment for pulmonary arterial hypertension and active digital ulcers in systemic sclerosis (SSc). This combined therapy may represent a new therapeutic option in addition to the conventional optimal medical therapy in patients with macrovascular impairment specifically peripheral artery disease (PAD) in SSc patients.

2. Patient and methods

A 48-year-old Black woman, heavy smoker, with a history of right middle cerebral artery ischemic stroke and left femoropopliteal bypass was referred for investigation of severe left limb claudication and bilateral Raynaud phenomenon in March 2015. She was on optimal medical treatment for PAD including a combined regiment of Telmisartan/Amlodipine (80mg/10mg qd), Clopidogrel (75 mg qd), and Atorvastatine (40mg qd). She had also proton pump inhibitor and domperidone therapy for heartburn, regurgitation, and dysphagia. Hand examination revealed skin thickening of fingers distal to metacarpophalangeal joints, puffy fingers, pitting scars on the thumbs, and active digital ulcers on the fourth and the fifth fingers at the hands and feet. The modified Rodnan skin score was 13/51. A nailfold videocapillaroscopy revealed a strong suspicion of SSc in the active stage with enlarged capillaries and capillary loss with pericapillary hemorrhages (Fig. 1). Antinuclear antibodies were positive ($>1/1000$); anti-centromere antibodies were also positive. According to the American College of Rheumatology/European League Against Rheumatism-2013 criteria,^[1] diagnosis of limited cutaneous SSc was retained with macrovascular impairment. Relevant diagnostic procedures were performed following the diagnosis including a high-resolution pulmonary computed tomography that did not find interstitial lung disease. Pulmonary function test showed a low diffusing capacity for carbon monoxide (DLCO/VA=63.6%) and echocardiography did not show pulmonary arterial hypertension. Upper gastrointestinal endoscopy and esophageal manometry revealed dysmotility and chronic gastritis with *Helicobacter pylori* that we treated with Bismuth quadruple therapy (Pylera). Lower limbs Doppler-ultrasonography found an occlusion of her left femoropopliteal bypass. Transcutaneous oxygen pressure (tcpO₂) measurement during exercise was performed to assess the vascular origin of the claudication.^[2] During exercise tcpO₂, chest tcpO₂ change is subtracted from limb tcpO₂ changes and expressed as Decrease from Rest of Oxygen Pressure (DROP; mm Hg). DROP is zero at rest and returns to zero after recovery. The minimal DROP value (DROPmin) is the lowest observed DROP. The treadmill test is performed using a constant load procedure (10% slope and 3.2 km/h speed) up to 15 min and an incremental load thereafter. The standardized and reproducible maximum walking distance (MWD) was measured.

3. Results

During this first test, DROPmin was -35 mm Hg on the left limb. The MWD was 118 m, and walking was stopped because of left limb pain corresponding to the usual symptoms (Fig. 2, right upper panel). Then, tcpO₂ confirmed exercise-induced left limb ischemia. We decided to add a PDE-5i Sildenafil (20mg tid) because of active digital ulcers.^[3] A new tcpO₂ test on treadmill after 17 weeks showed an MWD of 288 m (+144%). DROPmin



Figure 1. Nailfold videocapillaroscopy of the patient: strong suspicion of systemic sclerosis in the active stage with enlarged capillaries and capillary loss with pericapillary hemorrhages.

was -29 mm Hg on the left limb (Fig. 1, right middle panel) and treadmill stopped due to left limb pain. After 44 weeks on treatment and walking rehabilitation, the MWD on treadmill test has improved to 452 m (+63.7%). The digital ulcers healed and we decided to intensify the treatment by combining Sildenafil and Bosentan (62.5 mg bid), an ET1 receptor antagonist approved for prevention of recurrence of digital ulcers. After 59 weeks, a new treadmill tcpO₂ test showed a marked improvement of MWD to 1576 m (+348.7%). DROPmin was -27 mm Hg on the left limb at the end of the effort (Fig. 1, right lower panel) and treadmill stopped due to an inability to follow the incremental workloads. Interestingly, during exercise phase, there was no pain, and values of the DROP were always above -15 mm Hg, which could suggest a recruitment of collateral vessels newly formed from an active angiogenesis. One hypothesis is that last could have been amplified by the synergy of treatment targeting nitric oxide (NO) and ET1 pathways. During the follow-up period, no side effects were reported and the various blood test did not reveal hepatic impairment.

4. Discussion

Prevalence of PAD was found significantly higher in scleroderma patients compared with controls (10%).^[4] Claudication is the most common clinical expression of PAD.^[5] The vasodilating property of NO is due to cyclic guanosine-5-monophosphate (cGMP) as secondary messenger and metabolized by PDE-5. In SSc and atherosclerosis, NO is reduced and Sildenafil increases the levels of cGMP, thus maintaining vasodilatation and blood flow.^[6] Beyond its vasodilator effect, Sildenafil was suggested to have a direct antinociceptor effect via the L-arginine/NO/cGMP pathway^[7] and through spinal adenosine receptors.^[8] In one study, Bosentan inhibits superoxide anion-induced inflammation, pain, cytokine production, and oxidative stress that depend on ET1.^[9] In SSc, ET1 is involved in the genesis of vasculopathy and fibrosis leading to vessel wall occlusion and vascular manifestations.^[10] Recent studies have suggested that ET1 may play an important role in the alteration of endothelial function at the onset of PAD. In a study, 12 weeks of Bosentan significantly improved the MWD and endothelial function. These may suggest that Bosentan could have an anti-atherosclerotic effect in such

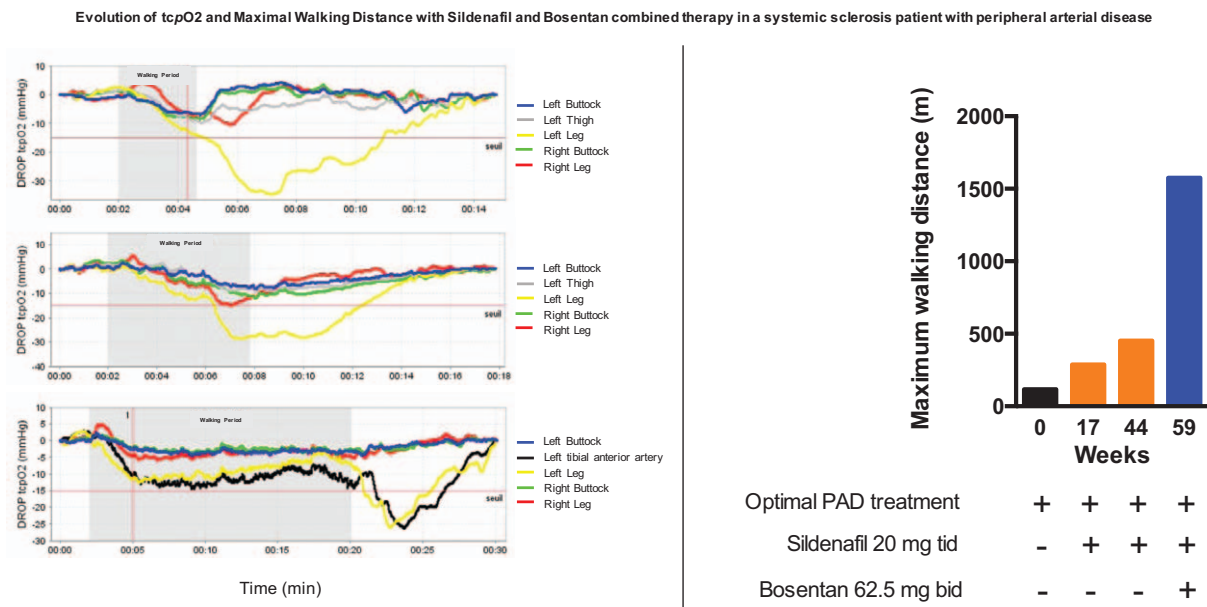


Figure 2. Right panel: Typical example of exercise tcpO₂ recording showing left distal ischemia during the walking period, before (March 2015: upper panel); after a 17-week treatment (July 2015: middle panel) with Sildenafil 20 mg tid and after 1 year of Sildenafil 20 mg tid and 3 months of Bosentan 62.5 mg bid (April 2016: lower panel). Note that from 15 min, speed and slope of the treadmill are progressively increased. Left panel: Evolution of the walking capacity on treadmill as maximal walking distance in a patient with limited cutaneous systemic sclerosis, before, after the introduction of Sildenafil and after the combination therapy Sildenafil and Bosentan.

clinical stage of the disease^[11] and also a synergistic effect between daily exercise and the combination of Sildenafil and Bosentan therapy. In this case report, the MWD is increased by +348% that is high comparing to the mean increase found in a meta-analysis (+122%).^[12] Another finding of this single observation is the synergistic effect of daily walking exercise, Sildenafil and Bosentan combined therapy on angiogenesis. In fact, walking induced vascular endothelial growth factor expression, and the concomitant administration of Sildenafil significantly and dose dependently enhanced this effect.^[13] Previous studies have described the proangiogenic effect of Sildenafil in vitro, in cultured endothelial cells, and in vivo, at both capillary and arteriolar levels in an experimental model of ischemia reperfusion.^[14] Furthermore, Bosentan effectively counteracts the antiangiogenic effects of SSc sera on dermal microvascular endothelial cells and fosters the restoration of a proangiogenic environment.^[15] Finally, we can hypothesize that Sildenafil and Bosentan might have an acute effect on exercise ischemic pain and in the long term, the combined therapy might have synergistic effect on angiogenesis and tissue oxygenation during exercise has shown by exercise tcpO₂ on treadmill test.

Acknowledgment

The authors thank Ms. Isabelle Laporte for technical help.

References

[1] van den Hoogen F, Khanna D, Fransen J, et al. 2013 Classification criteria for systemic sclerosis: an American College of Rheumatology/ European League Against Rheumatism Collaborative Initiative. *Ann Rheum Dis* 2013;72:1747–55.
 [2] Abraham P, Picquet J, Vielle B, et al. Transcutaneous oxygen pressure measurements on the buttocks during exercise to detect proximal arterial ischemia: comparison with arteriography. *Circulation* 2003;107: 1896–900.

[3] Hachulla E, Hatron P-Y, Carpentier P, et al. Efficacy of sildenafil on ischaemic digital ulcer healing in systemic sclerosis: the placebo-controlled SEDUCE study. *Ann Rheum Dis* 2016;75:1009–15.
 [4] Youssef P, Brama T, Englert H, et al. Limited scleroderma is associated with increased prevalence of macrovascular disease. *J Rheumatol* 1995; 22:469–72.
 [5] Olin JW, Sealove BA. Peripheral artery disease: current insight into the disease and its diagnosis and management. *Mayo Clin Proc* 2010; 85:678–92.
 [6] Roustit M, Blaise S, Allanore Y, et al. Phosphodiesterase-5 inhibitors for the treatment of secondary Raynaud’s phenomenon: systematic review and meta-analysis of randomised trials. *Ann Rheum Dis* 2013;72:1696–9.
 [7] Alves DP, da Motta PG, Romero TRL, et al. NO/cGMP production is important for the endogenous peripheral control of hyperalgesia during inflammation. *Nitric Oxide Biol Chem* 2013;28:8–13.
 [8] Lee HG, Kim WM, Choi JI, et al. Roles of adenosine receptor subtypes on the antinociceptive effect of sildenafil in rat spinal cord. *Neurosci Lett* 2010;480:182–5.
 [9] Serafim KGG, Navarro SA, Zarpelon AC, et al. Bosentan, a mixed endothelin receptor antagonist, inhibits superoxide anion-induced pain and inflammation in mice. *Naunyn Schmiedebergs Arch Pharmacol* 2015;388:1211–21.
 [10] Denton CP, Pope JE, Peter H-H, et al. Long-term effects of Bosentan on quality of life, survival, safety and tolerability in pulmonary arterial hypertension related to connective tissue diseases. *Ann Rheum Dis* 2008;67:1222–8.
 [11] De Haro J, Bleda S, Varela C, et al. Effect of Bosentan on claudication distance and endothelium-dependent vasodilation in Hispanic patients with peripheral arterial disease. *Am J Cardiol* 2016;117:295–301.
 [12] Gardner AW, Poehlman ET. Exercise rehabilitation programs for the treatment of claudication pain: a meta-analysis. *JAMA* 1995;274: 975–80.
 [13] Pyriochou A, Zhou Z, Koika V, et al. The phosphodiesterase 5 inhibitor sildenafil stimulates angiogenesis through a protein kinase G/MAPK pathway. *J Cell Physiol* 2007;211:197–204.
 [14] Koneru S, Varma Penumathsa S, Thirunavukkarasu M, et al. Sildenafil-mediated neovascularization and protection against myocardial ischemia reperfusion injury in rats: role of VEGF/angiopoietin-1. *J Cell Mol Med* 2008;12:2651–64.
 [15] Romano E, Bellando-Randone S, Manetti M, et al. Bosentan blocks the antiangiogenic effects of sera from systemic sclerosis patients: an in vitro study. *Clin Exp Rheumatol* 2015;33(suppl 91):S148–52.