



Received: 2014.09.02
Accepted: 2014.10.27
Published: 2015.02.07

Authors' Contribution:

- A** Study Design
- B** Data Collection
- C** Statistical Analysis
- D** Data Interpretation
- E** Manuscript Preparation
- F** Literature Search
- G** Funds Collection

Triaxial System in Re-Embolization for Recanalization of Pulmonary Arteriovenous Malformations

Masashi Shimohira^{ABCDEFF}, Takuya Hashizume^B, Tatsuya Kawai^B, Masahiro Muto^B, Kengo Ohta^B, Kazushi Suzuki^B, Yuta Shibamoto^{AE}

Department of Radiology, Nagoya City University Graduate School of Medical Sciences, Nagoya, Aichi, Japan

Author's address: Masashi Shimohira, Department of Radiology, Nagoya City University Graduate School of Medical Sciences, Nagoya, Aichi, Japan, e-mail: mshimohira@gmail.com

Background:

Recanalization occurs occasionally, following coil embolization of pulmonary arteriovenous malformations (PAVM), and can lead to ischemic stroke; therefore re-embolization is important. A 1.9-Fr. no-taper microcatheter that can be inserted into a 2.7-Fr. microcatheter (named the triaxial system) has recently become available, and contributes to super-selective catheterization for small or tortuous vessels. The aim of this study was to evaluate the usefulness of re-embolization for recanalization of PAVM using the triaxial system.

Material/Methods:

Recanalization was diagnosed in 8 patients with 13 PAVMs between June 2011 and November 2012, and re-embolization was attempted with a conventional microcatheter at first in all 13 PAVMs. However, in three of them it failed with the conventional microcatheter, and then the system was exchanged to the triaxial system. Thus, re-embolization using the triaxial system was performed in 3 PAVMs of 3 female patients, with a median age of 63 years (range, 46–73 years). We assessed technical success, complications, and outcome.

Results:

The disappearance of recanalization was confirmed by angiography in all re-embolization procedures (technical success rate was 100%). Re-embolization was then successfully achieved inside the original coils, and no branch artery of normal lung tissue was embolized. There were no complications related with this procedure. The blood flow of recanalization was decreased in all cases in a follow-up of 27-33 months (median, 31).

Conclusions:

Triaxial system appears to be useful for recanalization of PAVM, especially in difficult cases with a conventional system.

MeSH Keywords:

Catheterization • Embolization, Therapeutic • Pulmonary Artery

PDF file:

<http://www.polradiol.com/abstract/index/idArt/892378>

Background

Recanalization after coil embolization of pulmonary arteriovenous malformations (PAVM) is problematic because it can cause ischemic stroke or brain abscess [1]. The recanalization rate has recently been shown to be relatively high [2–6]. Thus, re-embolization is very important. A 1.9-Fr. no-taper microcatheter that can be inserted into a 2.7-Fr. microcatheter (named the triple co-axial [triaxial] system) was shown to contribute to superselective catheterization [7–10]. The aim of this study was to describe the re-embolization technique for recanalization of PAVM using the triaxial system.

Material and Methods

This retrospective study was approved by the Institutional Review Board, and written informed consent was obtained from each patient before the procedure. Recanalization was found using time-resolved MR angiography (TR-MRA) or pulmonary angiography in 8 patients with 13 PAVMs between June 2011 and November 2012. Recanalization was diagnosed when the venous sac and the draining vein were detected in the pulmonary arterial phase of TR-MRA. In all 13 PAVMs, re-embolization was first attempted with a conventional microcatheter. However, in only 3 PAVMs it was difficult to re-embolize them with the conventional microcatheter because

Table 1. Details of re-embolization and treatment results.

Case	Age	Sex	Location	Size of FA (mm)	No. of coils	Length of coils (mm)	Clinical success	Level of embolization	Patency of normal branch	Outcome	Follow-up (mo)
1	63	F	RLL	3.8	8	200	Yes	Inside of original coils	Yes	Decreased	33
2	46	F	LLL	3.2	10	460	Yes	Inside of original coils	Yes	Decreased	31
3	73	F	LUL	4.1	8	420	Yes	Inside of original coils	Yes	Decreased	27

FA – feeding artery; RLL– right lower lobe; LLL – left lower lobe; LUL – left upper lobe.

of vessel tortuosity or instability of the microcatheter. That is when the system was changed for the triaxial system.

Therefore, re-embolization using the triaxial system was performed in 3 PAVMs of 3 female patients, with a median age of 63 years (range, 46–73 years). In those 3 cases, the initial embolization was performed with a conventional microcatheter using 0.018-inch fibered coils and 0.0135-inch bare coils, and only the feeding artery was embolized. Then, recanalization was diagnosed in TR-MRA within a follow-up of 25–55 months (median, 42).

We assessed technical success, complications related with that procedure, and outcome. Technical success was defined as the disappearance of recanalization on digital subtraction angiography (DSA).

Re-embolization technique with triaxial system

All procedures were approached via the femoral vein with an 8-Fr. sheath. An 8-Fr. balloon catheter (Optimo; Tokai Medical, Kasugai, Japan) was then introduced into the pulmonary artery, followed by a 4-Fr. catheter (MP1; Terumo, Tokyo, Japan) and a conventional microcatheter at first. When it was difficult to perform re-embolization with the conventional microcatheter, it was changed for the triaxial system: it consisted of a 2.7-Fr. microcatheter (Sniper 2 high-flow; Terumo, Tokyo, Japan) and a 1.9-Fr. no-taper microcatheter (MARVEL; Tokai Medical, Kasugai, Japan). The 1.9-Fr. no-taper microcatheter was advanced along with the 0.014-inch microguidewire (BEGIN; ASAHI INTEC, Nagoya, Japan), followed by the 2.7-Fr. microcatheter along with the 1.9-Fr. no-taper microcatheter. The 1.9-Fr. no-taper microcatheter was advanced again, with good support from the 2.7-Fr. microcatheter. When the microcatheter was placed in the aimed position, coil embolization was performed using 0.010-inch coils such as Guglielmi Detachable Coil (GDC; Stryker, Fremont, CA, USA) and Cerecyte coil (Micrus Endovascular, San Jose, CA, USA) with inflation of the balloon in the 8-Fr. balloon catheter to prevent carrying the thrombus to the pulmonary vein, where it may cause cerebral infarction. Saline was dripped during coil embolization to prevent thrombus formation inside the microcatheter. The coils were placed as tight as possible until complete cessation of blood flow was obtained at the end of the re-embolization procedure on DSA. After re-embolization, TR-MRA was planned for follow-up examinations at 1–3 months, 5–7 months, and every 12 months.

Results

Details of re-embolization and the treatment results are summarized in Table 1. The size of the feeding vessel of recanalized PAVM ranged from 3.2 to 4.1 mm (median, 3.8). The number of coils used ranged from 8 to 10 (median, 8), and coil length ranged from 200 to 460 mm (median, 420). All re-embolization procedures were performed successfully, and the disappearance of recanalization was confirmed by DSA (Figure 1). Thus, the technical success rate was 100%. Furthermore, microcatheters could be advanced in all cases into the original coils. Re-embolization was then successfully achieved inside the original coils, and no branch artery of normal lung tissue was embolized. No complications such as chest pain, pleural effusion, or cerebral infarction were observed during or after re-embolization in any case. All patients did well after re-embolization in a follow-up of 27–33 months (median, 31). In all cases, a slight blood flow was found on TR-MRA but it was lesser than before re-embolization, and it was then followed up.

Discussion

Recanalization of the coils used to embolize PAVMs is a well-known phenomenon, with reported rates varying from 4% to 19% [2–6]. Lee et al. [1] reported that 7 of 45 patients (16%) with large PAVMs had reperfusion after transcatheter embolotherapy, and ischemic strokes occurred in 2 of those patients (4%). Thus, the initial embolization should be performed appropriately to prevent recanalization, and careful follow-up after the initial procedure is important to identify recanalization of PAVM as early as possible. Furthermore, re-embolization for recanalization should be performed.

Regarding the initial embolization, embolization using both an Amplatzer vascular plug and coils has recently been reported to prevent recanalization [11]. However, the Amplatzer vascular plug is not covered by health insurance in our country at present. Hayashi et al. [12] demonstrated that coil embolization of not only the feeding artery, but also the venous sac of PAVM contributed to a higher rate of avoided recanalizations than coil embolization of the feeding artery only. For a follow-up examination, CT may be not enough to identify recanalization of PAVM because of metal artifacts that occur after coil embolization. On the other hand, MR angiography has recently been shown useful after coil embolization [13–15]. Kawai et al. [16] have

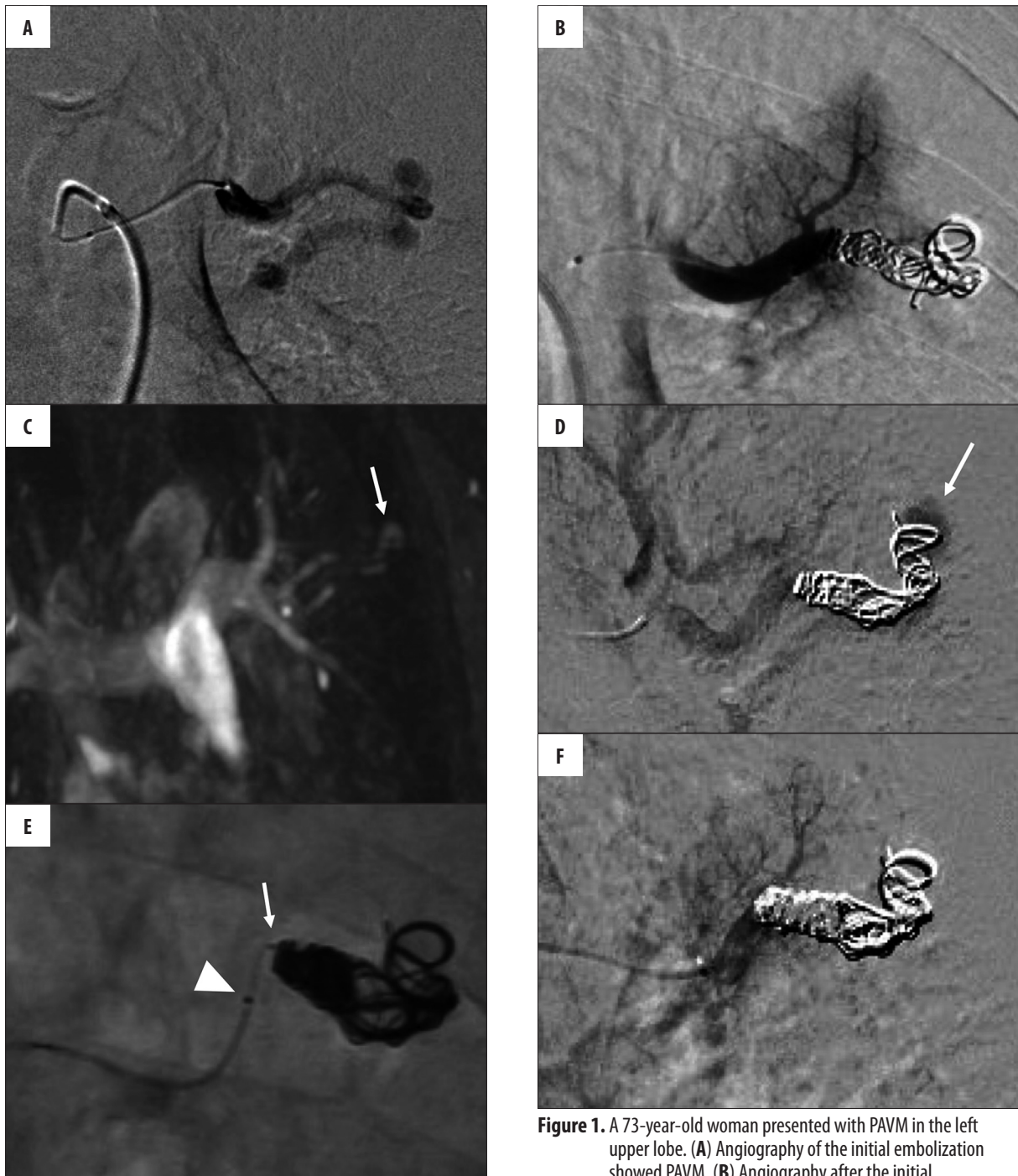

Figure 1. A 73-year-old woman presented with PAVM in the left upper lobe. (A) Angiography of the initial embolization showed PAVM. (B) Angiography after the initial embolization revealed that PAVM was completely embolized using coils. (C) Contrast-enhanced MRI performed 42 months after the initial coil embolization showed recanalization (arrow). (D) Angiography before re-embolization showed recanalization. (E) Coil embolization was performed using the triaxial system. The 1.9-Fr. no-taper microcatheter (arrow) could be inserted into the original coils with good support from the 2.7-Fr. microcatheter (arrow head). (F) Angiography after re-embolization showed a complete cessation of blood flow. The normal branch of the pulmonary artery was saved.

recently reported on the usefulness of TR-MRA in diagnosing reperfusion of PAVM after coil embolization, compared with CT. That is why that technique was used to detect recanalization in our hospital.

In re-embolization of recanalization of PAVMs, coils that had already been placed in the initial procedure, make re-embolization difficult [3]. The tip of the catheter should be placed in the distal end of the original coil to obtain enough space for coil embolization. However it is not easy to go through the original coils. Thus, re-embolization may be performed from inside of the original coils, and

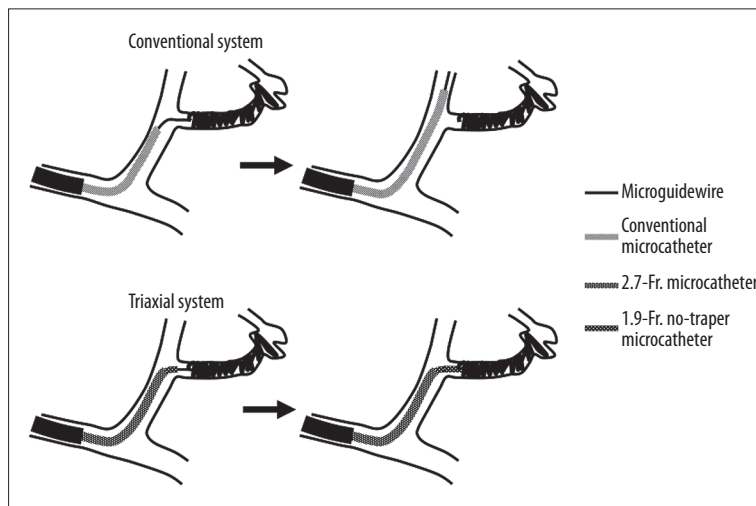


Figure 2. Sketch showing the advantage of the triaxial system. In re-embolization for recanalization of PAVM, the microguidewire cannot be inserted deeply due to the original coils. In such cases, if a conventional system is used, the microcatheter might jump more distally to the ostium of the feeding artery. With the triaxial system, the 2.7-Fr. microcatheter would stabilize and provide good support to the 1.9-Fr. no-taper microcatheter, and it would be easy to insert the 1.9-Fr. no-taper microcatheter into the feeding artery.

the microcatheter should be advanced into interstices of the original coils as deeply as possible. When the feeding artery is straight, a conventional microcatheter may be sufficient. However, when the feeding artery is tortuous, it is difficult to advance the microcatheter into the original coil because it is likely to jump to the parent artery. On the other hand, the microcatheter technique has recently been improved further, and the triaxial system has been shown to be a good method for superselective catheterization in transcatheter arterial chemoembolization for hepatocellular carcinoma, embolization of type II endoleaks following endovascular aneurysm repair, and embolization for lower gastrointestinal bleeding [7–10]. With this new system, the 2.7-Fr. microcatheter can have good stability and provide good support to the 1.9-Fr. no-taper microcatheter. Thus, it is easy to advance the 1.9-Fr. no-taper microcatheter into the original coils even though the microguidewire was not inserted deeply (Figure 2). Furthermore, during coil embolization, the 2.7-Fr. microcatheter can prevent the 1.9-Fr. no-taper microcatheter from kickback, and it should be possible to perform coil embolization tightly.

In this study, however, we observed a slight blood flow in the re-embolized arteries in all 3 cases during a follow-up of 27–33 months (median, 31). We found repeat re-embolization difficult because there was not enough margin to embolize in the feeding artery. Furthermore, with TR-MRA, the blood flow was lesser than before re-embolization, and the risk of paradoxical embolization appeared to be low. Although complete disappearance of the recanalized blood flow was not obtained, it might not have been possible to decrease the blood flow without using the triaxial system, because it was difficult to place a conventional microcatheter inside the original coils in these cases. Therefore, we believe that the triaxial system is a useful technique in cases in which advancing a conventional microcatheter is difficult and it contributes to decreasing the risk of paradoxical embolization.

Conclusions

In conclusion, we consider the triaxial system to be useful for catheterization, as it may contribute to successful re-embolization for recanalization of PAVM.

References:

- Lee DW, White RI Jr, Eglin TK et al: Embolotherapy of large pulmonary arteriovenous malformations: long-term results. *Ann Thorac Surg*, 1997; 64: 930–40
- Prasad V, Chan RP, Faughnan ME: Embolotherapy of pulmonary arteriovenous malformations: efficacy of platinum versus stainless steel coils. *J Vasc Interv Radiol*, 2004; 15: 153–60
- Milic A, Chan RP, Cohen JH, Faughnan ME: Reperfusion of pulmonary arteriovenous malformations after embolotherapy. *J Vasc Interv Radiol*, 2005; 16: 1675–83
- Mager JJ, Overtoom TT, Blauw H et al: Embolotherapy of pulmonary arteriovenous malformations: long-term results in 112 patients. *J Vasc Interv Radiol*, 2004; 15: 451–56
- Mager JJ, Overtoom TT, Blauw H et al: Reperfusion of complex pulmonary arteriovenous malformations after embolization: report of three cases. *Cardiovasc Intervent Radiol*, 2005; 28: 30–35
- Remy-Jardin M, Dumont P, Brillet PY et al: Pulmonary arteriovenous malformations treated with embolotherapy: helical CT evaluation of long-term effectiveness after 2–21-year follow-up. *Radiology*, 2006; 239: 576–85
- Shimohira M, Ogino H, Kawai T et al: Use of the triaxial microcatheter method in super-selective transcatheter arterial chemoembolisation for hepatocellular carcinoma. *Br J Radiol*, 2011; 84: 184–87
- Shimohira M, Ogino H, Kawai T et al: Clinical usefulness of the triaxial system in super-selective transcatheter arterial chemoembolization for hepatocellular carcinoma. *Acta Radiol*, 2012; 53: 857–61
- Shimohira M, Hashizume T, Suzuki Y et al: Triaxial system for embolization of type II endoleak after endovascular aneurysm repair. *J Endovasc Ther*, 2013; 20: 200–4
- Shimohira M, Hashizume T, Ohta K et al: Triaxial transarterial embolization for lower gastrointestinal bleeding: A retrospective case series. *Minim Invasive Ther Allied Technol*, 2014; 20: 1–4
- Trerotola SO, Pyeritz RE: Does use of coils in addition to amplatzer vascular plugs prevent recanalization? *Am J Roentgenol*, 2010; 195: 766–71
- Hayashi S, Baba Y, Senokuchi T et al: Efficacy of venous sac embolization for pulmonary arteriovenous malformations: comparison with feeding artery embolization. *J Vasc Interv Radiol*, 2012; 23: 1566–77

13. Koganemaru M, Abe T, Uchiyama D et al: Detection of neck recanalization with follow-up contrast-enhanced MR angiography after renal artery aneurysm coil embolization. *J Vasc Interv Radiol*, 2010; 21: 298–300
14. Kurosaka K, Kawai T, Shimohira M et al: Time-resolved Magnetic Resonance Angiography for assessment of recanalization after coil embolization of visceral artery aneurysms. *Pol J Radiol*, 2013; 78(1): 64–68
15. Koganemaru M, Abe T, Nonoshita M et al: Follow-up of true visceral artery aneurysm after coil embolization by three-dimensional contrast-enhanced MR angiography. *Diagn Interv Radiol*, 2014; 20: 129–35
16. Kawai T, Shimohira M, Kan H et al: Feasibility of Time-Resolved MR Angiography for Detecting Recanalization of Pulmonary Arteriovenous Malformations Treated with Embolization with Platinum Coils. *J Vasc Interv Radiol*, 2014; 25: 1339–47