



Short Communication

Hydrocortisone relieves the immediate post-operative scrotal edema after inguinal varicocelectomy: A prospective clinical trial



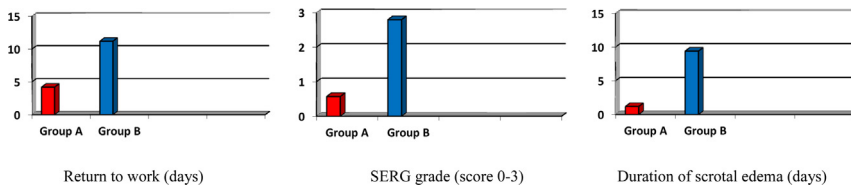
Samir Elhanbly^a, Tamer Youssef^b, Ayman Elkholy^a, Mamdouh Abdel-Gawad^a, Taymour Mostafa^{c,*}

^a Andrology Unit, Faculty of Medicine, Mansoura University, Mansoura, Egypt

^b General Surgery Department, Faculty of Medicine, Mansoura University, Mansoura, Egypt

^c Andrology and Sexology Department, Faculty of Medicine, Cairo University, Cairo, Egypt

GRAPHICAL ABSTRACT



ARTICLE INFO

Article history:

Received 30 December 2016

Revised 17 February 2017

Accepted 5 March 2017

Available online 6 March 2017

Keywords:

Varicocele

Varicocelectomy

Hydrocortisone

Swellings

Edema

Scrotum

ABSTRACT

This study aimed to assess the effect of a single IM injection of hydrocortisone succinate in relieving the immediate post-varicocelectomy scrotal edema. In all, 117 patients with grades II and III varicocele who developed post-varicocelectomy scrotal edema were randomly classified into group A (n = 59) that received a single IM hydrocortisone sodium succinate injection plus ordinary post-operative treatment and Group B (n = 58), which received the post-operative treatment alone. All patients were followed up to assess; changes in scrotal edema, the day of return to work and emergence of complications. Post-operative scrotal edema was assessed using a scrotal edema rating grades (SERG = 0–3) score. In group A, scrotal edema disappeared 1 day after steroid injection in 33 patients (55.9%), and after 2 days in the remaining 26 patients (44.1%), and all patients were returned to work within 5–7 days. In group B, the edema remained large in 36 patients (62.1%), moderate in 22 patients (37.9%), and disappeared after 9–12 days; and those patients returned to work within 11–13 days. It is concluded that a single IM hydrocortisone injection could be effective to reduce the immediate post-operative scrotal edema after inguinal varicocelectomy without obvious side effects.

© 2017 Production and hosting by Elsevier B.V. on behalf of Cairo University. This is an open access article under the CC BY-NC-ND license (<http://creativecommons.org/licenses/by-nc-nd/4.0/>).

Introduction

Varicocele is one of the leading correctable cause of infertility in men attending infertility clinics for evaluation. Varicocele has been shown to cause decreased testicular volume, sperm count, sperm motility, sperm normal forms and Leydig cell function [1–3]. Surgical options for varicocelectomy in infertile men include; Palomo

technique, microsurgical varicocelectomy, laparoscopic varicocelectomy, radiologic embolization and macroscopic inguinal varicocelectomy [4].

Complications of varicocelectomy include hydrocele, scrotal edema, epididymo-orchitis, testicular atrophy and recurrence. Also, scrotal pain, scrotal paresthesia, and intra-scrotal venous ectasies were reported after subinguinal varicocelectomy [5]. Hydrocele was demonstrated to occur more commonly after retroperitoneal approach. Scrotal edema and pain were reported to occur as a complication after different varicocele repairs [6,7].

Peer review under responsibility of Cairo University.

* Corresponding author.

E-mail address: taymour1155@link.net (T. Mostafa).

<http://dx.doi.org/10.1016/j.jare.2017.03.001>

2090-1232/© 2017 Production and hosting by Elsevier B.V. on behalf of Cairo University.

This is an open access article under the CC BY-NC-ND license (<http://creativecommons.org/licenses/by-nc-nd/4.0/>).

Glucocorticoids have anti-inflammatory and immune-suppressive actions that underlie its use in treatment of inflammatory and immune disorders. So, its effects in reducing post-operative edema resulting from tissue injury were studied in different types of operations, e.g., dental, abdominal, cardiac and gynecological surgeries [8].

Different glucocorticoids were used as methylprednisolone and dexamethasone [9,10]. Single-dose IM injection of dexamethasone was shown to reduce post-operative nausea and vomiting after laparoscopic cholecystectomy and to reduce post-operative facial swelling and pain after surgical extraction of impacted lower third molar [11,12].

This study aimed to assess the effect of a single IM hydrocortisone in reducing the immediate post-operative scrotal edema after inguinal varicocelectomy.

Patients and methods

This study was conducted in the period from May 2011 to February 2016 after the IRB approval of Faculty of Medicine, Mansoura University (#R/16.03.43) and informed consent. Cases of varicocele were recruited from 2 University hospitals and 2 private surgical clinics. Cases of bilateral varicocele grades II and III (after clinical examination and scrotal color duplex) underwent standard inguinal varicocelectomy under general anesthesia (n = 572). Only cases that developed immediate (first day after surgery) post-operative scrotal edema (n = 117 cases out of all 572 operated varicocele cases) were included in this study whatever its extent. All patients received the same post-operative treatment regimen including; oral ciprofloxacin 500 mg tablets b.i.d for 5 days. Exclusion criteria were; postoperative scrotal hematoma, scrotal infection, scrotal hydrocele, and all steroid contraindications.

Included subjects (n = 117) were randomly classified (using the every other patient way) into; group A (n = 59) that was given a single Solu-Cortef IM injection (hydrocortisone sodium succinate 100 mg, Pfizer®) in the day they developed post-operative scrotal edema. Group B subjects (n = 58) received only the ordinary post-operative treatment. Both groups were assessed on the second day to record changes in post-operative edema and swelling by blinded observers who did not know the injected patients.

To estimate the degree of post-operative scrotal edema before and after hydrocortisone injection, a measurable method was

created for comparison that can be related to changes in scrotal edema; the scrotal edema rating grades (SERG) score. The SERG score was calculated by estimating the widest scrotal circumference using a numbered measuring tape while the patient is in the standing position. The SERG score was measured before and after surgery plus before and after steroid injection.

The SERG score ranged from 0 to 3 as follows:

- 0 = no edema = the pre-operative scrotal circumference
- 1 = mild edema = <2 folds increase in the widest scrotal circumference
- 2 = moderate edema = 2–3 folds increase in the widest scrotal circumference
- 3 = severe edema = >3 folds increase in the widest scrotal circumference

Patients in group A were observed for the side effects of hydrocortisone. All patients were admitted for 3 days to recruit cases with post-operative scrotal edema and to assess the effect of steroid injection. The patients were followed up for one month after surgery to assess the changes in scrotal edema, to record the day of return to work and to record emergence of any complications.

Statistical analysis

The data was represented as mean and standard deviation (SD). The statistics was carried out using SPSS program version 20.0 (SPSS Inc., Chicago, IL, USA). Comparisons among groups were presented as odds ratios (ORs) with corresponding 95% confidence interval (95% CI). *P* value < 0.05 was set as significant.

Results

The mean age of the two investigated groups was 24.3 ± 2.1 and 25.1 ± 1.9 years, respectively, with nonsignificant difference. The number of unilateral and bilateral varicocele cases in group A was 27 and 32, respectively, compared with 30 and 28 cases in group B. The difference between group A and group B regarding the mean total testicular volume and mean total varicocele grade in the 2 groups was nonsignificant (Table 1).

All investigated parameters (SERG score, duration of edema, and days to return work) yielded a significant decrease in the steroid cases compared with the controls (Table 2).

In group A, scrotal edema disappeared 1 day after steroid injection in 33 patients (55.9%), and after 2 days in the remaining 26 patients (44.1%); all patients returned to work within 5–7 days. Only one case in group A reported gastric hyperacidity. In group B, 36 patients (62.1%) had a SERG score of 3 and 22 patients (37.9%) had a SERG score of 2 on the 2nd day of scrotal edema emergence. In group B, the edema took about 9–12 days to disappear and patients of this group returned to work within 11–13 days.

Table 1
Age, testicular volume, and varicocele grades (mean ± SD).

	Group A (n = 59)	Group B (n = 58)	<i>P</i>
Age (years)	24.8 ± 2.1	25.1 ± 1.9	0.849
Total testicular volume (mL) (right + left)	31.6 ± 1.43	32.4 ± 1.21	0.752
Total varicocele grade (0–6) in duplex (right + left)	4.4 ± 0.71	4.2 ± 0.72	0.872

Table 2
Data of the investigated groups (mean ± SD).

	Group A	Group B	OR (95% CI)	<i>P</i>
n	59	58		
Age (years)	24.8 ± 2.1	25.1 ± 1.9	0.930 (0.441–1.962)	0.849
SERG (score 0–3)	0.57 ± 0.5	2.8 ± 0.4	0.017 (0.012–0.952)	0.045 ^a
Duration of edema (days)	1.2 ± 0.4	9.4 ± 1.5	0.048 (0.010–0.222)	0.001 ^a
Return to work (days)	4.2 ± 1.3	11.2 ± 1.2	0.190 (0.073–0.494)	0.001 ^a

OR: Odds ratio.

CI: Confidence interval.

^a Significant difference.

Discussion

In the current study, post-operative scrotal edema after hydrocortisone injection was significantly less and lasted for a shorter duration compared with the controls. Several studies showed the effect of steroids in different surgical procedures. Klongnoi et al. [12] pointed that dexamethasone was significantly effective in reducing post-operative edema after surgical extraction of lower impacted 3rd molar. Also, intravenous dexamethasone injections 90 min before laparoscopic cholecystectomy showed a significant reduction of post-operative fatigue, pain, nausea and vomiting compared with placebo [13]. In breast surgery, pre-operative dexamethasone showed a significant decrease of post-operative pain, nausea, and vomiting with less need for analgesics and antiemetics compared with placebo [14].

Post-surgical edema was proposed to be a normal consequence and not a complication of tissue injury. Edema occurs due to rise of osmotic pressures, altered capillary permeability and transudation of fluid through the vessels into the area of damage besides obstruction of the local lymphatic system by fibrinogen clots derived from the adjacent injured tissues. Eventually, all these changes make the fluid accumulates in the interstitial spaces [15]. Edema is variable from area to area and accumulates more freely in areas of loose connective tissues, whereas the tightly bound down tissues to underlying structures tend to have less swelling. This immediate edema maximizes within 24–72 h during the post-operative period [16,17].

The mechanisms by which glucocorticoids can decrease post-operative edema include; inhibition of the enzyme phospholipase A2 and reducing the release of arachidonic acid in the cells of the inflamed focus. This will decrease the inflammatory mediators released from the injured tissues; prostaglandins and leukotrienes [12]. In addition, glucocorticoids reduce serotonin, bradykinins, cortisol migratory inhibiting factor and β -endorphins [18]. Steroids are also involved in the synthesis of immunoreactive and regulatory proteins, including vasocortin, angiotensin converting enzyme that degrades bradykinin and lipocortin. Whirlledge and Cidlowksi [19] added that steroids stabilize cellular membranes and have a suppressive effect on lymphocytes, monocytes and eosinophils.

The duration of edema and time needed to return to work was significantly lower in patients that received hydrocortisone injection. This finding went with Bianchin et al. [11] attributing this to the anti-inflammatory effect of the drug and the stress response of the body. Also, post-operative complications of steroid injection were a concern in the current study, however only one patient complained of gastric hyperacidity. In this context, other clinical trials that used higher doses of steroids like dexamethasone in comparable surgeries, did not report significant complications [20].

Conclusions

A single IM injection of hydrocortisone sodium succinate 100 mg could be used to reduce the immediate post-operative scrotal edema after inguinal varicocelelectomy without obvious side effects.

Conflict of interest

The authors have declared no conflict of interest.

References

- [1] Pasqualotto FF, Lucon AM, de Goes PM, Sobreiro BP, Hallak J, Pasqualotto EB, et al. Semen profile, testicular volume, and hormonal levels in infertile patients with varicoceles compared with fertile men with and without varicoceles. *Fertil Steril* 2005;83:74–7.
- [2] Mostafa T, Anis T, El Nashar A, Imam H, Osman I. Seminal plasma reactive oxygen species-antioxidants relationship with varicocele grade. *Andrologia* 2012;44:66–9.
- [3] Mostafa T, Rashed L, Taymour M. Seminal cyclooxygenase relationship with oxidative stress in infertile oligoasthenoteratozoospermic men with varicocele. *Andrologia* 2016;48:137–42.
- [4] Cayan S, Shavakhobov S, Kadioglu A. Treatment of palpable varicocele in infertile men: a meta-analysis to define the best technique. *J Androl* 2009;30:33–40.
- [5] Shiraishi K, Oka S, Matsuyama H. Surgical comparison of subinguinal and high inguinal microsurgical varicocelelectomy for adolescent varicocele. *Int J Urol* 2010;23:338–42.
- [6] Vicari E, Arancio A, Costanzo C, Ingrassia G, Cannizzaro MA. Clinical and sperm follow-up after subinguinal varicocelelectomy. *Arch Ital Urol Androl* 2000;72:65–73.
- [7] Shamsa A, Nademi M, Aqae M, Fard AN, Molaei M. Complications and the effect of varicocelelectomy on semen analysis, fertility, early ejaculation and spontaneous abortion. *Saudi J Kidney Dis Transpl* 2010;21:1100–5.
- [8] Jakobsson J. Preoperative single-dose intravenous dexamethasone during ambulatory surgery: update around the benefit versus risk. *Curr Opin Anaesthesiol* 2010;23:682–6.
- [9] Toft P, Christiansen K, Tønnesen E, Nielsen CH, Lillevang S. Effect of methylprednisolone on the oxidative burst activity, adhesion molecules and clinical outcome following open heart surgery. *Scand Cardiovasc J* 1997;31:283–8.
- [10] Lim SH, Jang EH, Kim MH, Cho K, Lee JH, Lee KM, et al. Analgesic effect of preoperative versus intraoperative dexamethasone after laparoscopic cholecystectomy with multimodal analgesia. *Korean J Anesthesiol* 2011;61:315–9.
- [11] Bianchin A, De Luca A, Caminiti A. Postoperative vomiting reduction after laparoscopic cholecystectomy with single dose of dexamethasone. *Minerva Anesthesiol* 2007;73:343–6.
- [12] Klongnoi B, Kaewpradub P, Boonsirirath K, Wongsirichat N. Effect of single dose preoperative intramuscular dexamethasone injection on lower impacted third molar surgery. *Int J Oral Maxillofac Surg* 2012;41:376–9.
- [13] Bisgaard T, Klarskov B, Kehlet H, Rosenberg J. Preoperative dexamethasone improves surgical outcome after laparoscopic cholecystectomy: a randomized double-blind placebo-controlled trial. *Ann Surg* 2003;238:651–60.
- [14] Gómez-Hernández J, Orozco-Alatorre AL, Domínguez-Contreras M, Ocegüera-Villanueva A, Gómez-Romo S, Alvarez Villaseñor AS, et al. Preoperative dexamethasone reduces postoperative pain, nausea and vomiting following mastectomy for breast cancer. *BMC Cancer* 2010;10:692.
- [15] Alexander RE, Thronson PR. A review of perioperative corticosteroid use in dentoalveolar surgery. *Oral Surg Oral Med Oral Pathol Oral Radiol Endod* 2000;90:406–15.
- [16] Peterson LJ. Postoperative patient management. In: Peterson LJ, Ellis E, Hupp JR, Tucker MR, editors. *Contemporary oral and maxillofacial surgery*. St Louis (USA): Mosby; 1998. p. 251.
- [17] Nadel DM. The use of systemic steroids in otolaryngology. *Ear Nose Throat J* 1996;75:502–5.
- [18] El-Haggag S, El-Ashmawy S, Attia A, Mostafa T, Roaiah MM, Fayed A, et al. Beta-endorphin in serum and seminal plasma in infertile men. *Asian J Androl* 2008;8:709–12.
- [19] Whirlledge S, Cidlowksi JA. A role for glucocorticoids in stress-impaired reproduction: beyond the hypothalamus and pituitary. *Endocrinology* 2013;154:4450–68.
- [20] De Oliveira GS, Almeida MD, Benzon HT, McCarthy RJ. Perioperative single dose systemic dexamethasone for postoperative pain: a meta-analysis of randomized controlled trials. *Anesthesiology* 2011;115:575–88.