

Distinctive clinicopathological features of Von Hippel-Lindau-associated hereditary renal cell carcinoma: A single-institution study

BAOAN HONG^{1-4*}, ZHONGYUAN ZHANG^{1-4*}, JINGCHENG ZHOU¹⁻⁴, KAIFANG MA¹⁻⁴,
JIUFENG ZHANG¹⁻⁴, LIN CAI¹⁻⁴, NING ZHANG⁵ and KAN GONG¹⁻⁴

¹Department of Urology, Peking University First Hospital; ²Hereditary Kidney Cancer Research Center, Peking University First Hospital; ³Institute of Urology, Peking University; ⁴National Urological Cancer Center, Beijing 100034; ⁵Department of Urology, Beijing Cancer Hospital, Beijing 100142, P.R. China

Received August 11, 2018; Accepted February 15, 2019

DOI: 10.3892/ol.2019.10091

Abstract. Von Hippel-Lindau (VHL) disease is a genetic syndrome that involves the development of tumors in numerous organs. The kidney is one of the most frequently affected organs, and patients with VHL and renal tumors require repeated nephrectomy. The present study aimed to further determine the clinicopathological characteristics of patients with VHL-associated renal cell carcinoma (RCC), which may allow more rational clinical treatment decisions. This study included 27 patients with VHL who underwent radical or partial nephrectomy at the Peking University First Hospital between January 2010 and April 2018. The clinicopathological characteristics and prognosis of the patients were retrospectively reviewed. The expression of RCC-associated molecular markers was evaluated by immunohistochemistry. The mean size of the renal tumors was 4.3±2.0 cm (range 1.3-9.5 cm). The pathological type in 26 cases (96.3%) was clear cell RCC (CCRCC), whereas only one patient was diagnosed with CCRCC and clear cell papillary RCC. Renal cysts with a clear cell lining were observed, and RCC cell clusters were scattered in renal cyst cavities. Among the 27 patients, 21 (77.8%) were diagnosed with stage IA/T1N0M0, according to Tumor-Node-Metastasis staging, and 16 (59.3%) had

grade 1 tumors. The mean postoperative follow-up duration was 39.0±24.0 months (range, 1.7-96.5 months). No metastasis or VHL-associated mortality was observed. VHL-associated RCC is a relatively low-risk disease, and a tumor size of 4 cm was determined as a threshold for nephron-sparing surgery. In addition, to prevent tumor cell dispersion, renal cysts should be carefully treated. A comprehensive understanding of the clinicopathological characteristics and underlying mechanisms of RCC associated with VHL syndrome may improve patient prognosis.

Introduction

Von Hippel-Lindau (VHL) disease (Online Mendelian Inheritance in Man no. 193300; <https://www.omim.org/entry/193300>) is an autosomal dominant inherited multi-systemic tumor syndrome, which causes mutations of the tumor suppressor gene *VHL* located on chromosome 3p25-26 (1). The incidence of VHL syndrome is ~1/36,000-52,000 births worldwide, with a penetrance of ~90% at 65 years old in families with a history of VHL (2-4). VHL clinical manifestations include central nervous system hemangioblastoma, retinal hemangioblastoma, renal cell carcinoma (RCC), pheochromocytoma (PHEO), pancreatic cysts or tumors, endolymphatic sac tumors and epididymal or broad ligament cystadenoma (5,6). Based on these clinical symptoms, VHL syndrome is classified as clinical type I (PHEO-free) or clinical type II (PHEO). In addition, type II is subclassified as type IIA (absence of RCC), type IIB (presence of RCC) and type IIC (PHEO only) (7-9). The kidney is one of the numerous organs affected by VHL syndrome, and the incidence of RCC or renal cysts in VHL syndrome is 30-60% (10). The majority of patients with VHL have multiple bilateral kidney lesions and require numerous surgeries across their lifetime. However, repeated surgeries increase the risk of renal dysfunction or uremia, which eventually lead to dialysis treatment or renal transplantation. It is therefore crucial to establish the optimal time point for surgery, in order to minimize the number of procedures, to preserve kidney integrity as long as possible and to improve patient quality of life. Medical advances and a

Correspondence to: Professor Kan Gong, Department of Urology, Peking University First Hospital, 8 Xishiku Street, Xicheng, Beijing 100034, P.R. China
E-mail: gongkan_pku@126.com

Professor Ning Zhang, Department of Urology, Beijing Cancer Hospital, 52 Fucheng Road, Haidian, Beijing 100142, P.R. China
E-mail: niru7429@126.com

*Contributed equally

Key words: Von Hippel-Lindau, clear cell renal cell carcinoma, clear cell papillary renal cell carcinoma, clinicopathological features, prognosis

deeper comprehension of VHL disease have allowed median survival time to increase from 49 to 62 years (3,11). A better understanding of the clinicopathological characteristics and prognosis of VHL-associated hereditary RCC may therefore aid clinicians in making more rational treatment decisions for patients with VHL.

In the present study, 27 patients diagnosed with VHL according to established clinical criteria and genetic tests were included. Clinical characteristics were collected, and pathological features were reevaluated according to the latest diagnostic criteria in order to improve our understanding of VHL syndrome.

Materials and methods

Patients and tumor samples. A total of 27 patients with VHL who underwent radical or partial nephrectomy at Peking University First Hospital (Beijing, China) between January 2010 and April 2018 were included in the present study. Patients were definitively diagnosed with VHL according to clinical criteria and genetic tests performed on peripheral blood prior to surgery. The present study was approved by the Institutional Ethics Committee of Peking University First Hospital (Beijing, China). All patients provided written informed consent.

Patients with VHL with one of the following clinical diagnostic criteria were included: i) >1 hemangioblastoma in the central nervous system (CNS) or retina; ii) a single hemangioblastoma in the CNS or retina combined with a visceral complication, including multiple renal, pancreatic or hepatic cysts, PHEO or renal cancer, with the exception of epididymal and renal cysts; and iii) any of the aforementioned clinical symptom plus a family history of VHL (7,12). A genetic test was performed by direct sequencing of polymerase chain reaction products using multiplex ligation-dependent probe amplification (13). The results were compared with the normal sequence (13).

The clinicopathological characteristics of patients included in the present study comprised sex, age, affected organs, VHL mutation site, nucleotide and protein alterations, surgical procedure, tumor size, pathological type [according to the 2016 World Health Organization (WHO) Kidney Tumor Classification] (14), tumor stage [2010 American Joint Committee on Cancer Kidney Cancer Tumor-Node-Metastasis (TNM) Classification] (15), tumor grade [2016 WHO/International Society of Urological Pathology (ISUP)] (14) and prognosis. The tumor pathological type and grade were reevaluated according to the latest diagnostic pathology criteria.

Hematoxylin and eosin (H&E) staining and immunohistochemistry (IHC). Tissue sections (thickness, 4 μ m) were fixed in 10% formalin-fixed at room temperature for 24-48 h. The paraffin-embedded RCC specimens were subjected to hematoxylin & eosin (H&E) staining at 4°C for 20 h, and examined by light microscopy (BX43; Olympus Corporation, Tokyo, Japan). The expression of RCC-associated molecular markers, including cluster of differentiation 10 (CD10), carbonic anhydrase 9 (CAIX), cytokeratin 7 (CK7) and Ki-67, was evaluated by IHC, as previously described (16). The primary

antibodies against CD10 (cat. no. ZM-0283; 1:150), CAIX (cat. no. ZM-0161; 1:150), CK7 (cat. no. ZM-0071; 1:150) and Ki-67 (cat. no. ZM-0166; 1:150) were purchased from OriGene Technologies, Inc. (Beijing, China). Tissues were subsequently incubated with poly-peroxidase-conjugated anti-rabbit/mouse immunoglobulin G secondary antibody (cat. no., PV-9000; 200 μ l/per slice; OriGene Technologies, Inc.) at room temperature for 1 h. The H&E and IHC stained sections were independently analyzed by two qualified pathologists.

The expression of RCC-associated molecular markers was semi-quantitatively assessed. A total of 10 representative fields of vision were randomly selected under high magnification (x400). The percentage of positive cells was determined as follows: % positive cells = (number of positive cells/number of total cells) x100. The score was defined as negative (-), focally positive (+), moderately positive (++) and strongly positive (+++) for 0-5, 6-10, 11-50 and 51-100% positively stained cells, respectively. The expression levels of RCC-associated molecular markers were divided into two groups according to the aforementioned scores as follows: Low/negative expression (-, +) and high expression (++, +++).

Results

Clinical characteristics. In the present study, 27 patients with VHL from Peking University First Hospital were included (Table I). These patients comprised 13 (48.1%) men and 14 (51.9%) women. The mean age at the time of surgery was 42.0 \pm 14.9 years (range, 23.3-71.6 years). The majority of patients exhibited tumors in multiple organs (Fig. 1). According to the VHL clinical classification, 21 (77.8%) patients were defined as clinical type I, and six (22.2%) patients were defined as clinical type IIB. Additional genetic testing clarified that the number of patients who presented with VHL mutation on exon 1, 2 or 3 and on introns was nine (33.3%), seven (25.9%), 10 (37.0%) and two (7.4%), respectively. The majority of patients (14/27, 51.9%) had missense mutations, six (22.2%) had large deletions, three (11.1%) had nonsense mutations, two (7.4%) had frameshift mutations and two (7.4%) had splicing mutations. In addition, 19 patients underwent partial nephrectomy (open or laparoscopic-assisted in 12 and seven cases, respectively). Nephron-sparing surgery was the conventional therapy for VHL-associated RCC.

Pathological features. In the 27 patients with VHL, the mean size of the renal tumors was 4.3 \pm 2.0 cm (range, 1.3-9.5 cm; Table II). The pathological type of 26 (96.3%) cases was clear cell RCC (CCRCC). Open partial nephrectomy was conducted in one patient, and four renal tumors were resected. The pathological type of three tumors was CCRCC (Fig. 2), whereas the fourth tumor was diagnosed as clear cell papillary RCC (CCPRCC), according to IHC staining that indicated the following: CAIX (+++, goblet cell staining), CK7 (+++), CD10 (-) and P504S (-) (Fig. 2). The number of patients with TNM stages T1aN0M0, T1bN0M0, T2N0M0 and T3N0M0 was 14 (51.9%), seven (25.9%), two (7.4%) and four (14.8%), respectively. According to the 2016 WHO/ISUP guidelines, the number of patients with tumor grades 1, 2 and 3 was 16 (59.3%), eight (29.6%) and three (11.1%), respectively. In addition, renal cyst walls were

Table I. Clinical characteristics of the 27 patients with VHL-associated hereditary renal cell carcinoma.

Clinical characteristics	Value
Sex, n (%)	
Male	13 (48.1)
Female	14 (51.9)
Age, years	
Mean ± SD	42.0±14.9
Range	23.3-71.6
VHL clinical classification, n (%)	
I	21 (77.8)
IIB	6 (22.2)
VHL mutation site, n (%)	
Exon 1	9 (33.3)
Exon 2	7 (25.9)
Exon 3	10 (37.0)
Intron	2 (7.4)
Mutation type, n (%)	
Missense mutation	14 (51.9)
Nonsense mutation	3 (11.1)
Frameshift mutation	2 (7.4)
Splicing mutation	2 (7.4)
Large deletions	6 (22.2)
Surgery approach, n (%)	
Open radical nephrectomy	3 (11.1)
Open partial nephrectomy	12 (44.4)
Laparoscopic radical nephrectomy	5 (18.5)
Laparoscopic partial nephrectomy	7 (25.9)
Postoperative follow-up, months	
Mean	39.0±24.0
Range	1.7-96.5

VHL, Von Hippel-Lindau; SD, standard deviation.

collected during surgery. Pathological analysis of these tissues demonstrated that the renal cyst linings of seven patients were made of CCRCC cells (Fig. 3). A total of four RCC-associated molecular markers, namely CD10, CAIX, CK7 and Ki-67, were detected by IHC (Fig. 4). The expression rates of CD10, CAIX and CK7 were 63, 88.9 and 11.1%, respectively (Table II). All patients presented with low or negative Ki-67 expression levels.

Follow-up. The mean postoperative follow-up duration was 39.0±24.0 months (range, 1.7-96.5 months). No case of VHL-associated mortality was observed. The majority of patients had normal renal functions, with the exception of four patients, who presented with slightly higher creatinine or urea nitrogen levels than the upper normal limit. This mild abnormality however, had no significant effect on the patient's quality of life, as normal levels will be restored with treatment. It is therefore suggested that creatinine and urea nitrogen levels can reflect the renal function.

Table II. Pathological features of the 27 patients with VHL-associated hereditary renal cell carcinoma.

Pathological features	Value
Tumor size, cm	
Mean	4.3±2.0
Range	1.3-9.5
Pathological type, n (%)	
CCRCC	26 (96.3)
CCPRCC	1 (3.7)
RCC in renal cyst wall, n (%)	
Yes	7 (70.0)
No	3 (30.0)
TNM stage, n (%)	
T1aN0M0	14 (51.9)
T1bN0M0	7 (25.9)
T2N0M0	2 (7.4)
T3N0M0	4 (14.8)
WHO/ISUP grade, n (%)	
1	16 (59.3)
2	8 (29.6)
3	3 (11.1)
CD10 expression, n (%)	
High	17 (63.0)
Low/negative	10 (37.0)
CK7 expression, n (%)	
High	3 (11.1)
Low/negative	24 (88.9)
CAIX expression, n (%)	
High	24 (88.9)
Low/negative	3 (11.1)
Ki-67 expression, n (%)	
High	0 (0.0)
Low/negative	27 (100.0)

CAIX, carbonic anhydrase 9; CCRCC, clear cell renal cell carcinoma; CCPRCC, clear cell papillary renal cell carcinoma; CD10, cluster of differentiation; CK7, cytokeratin 7; ISUP, International Society of Urological Pathology; RCC, renal cell, carcinoma; TNM, Tumour-Node-Metastasis; VHL, Von Hippel-Lindau; WHO, World Health Organization.

Discussion

VHL disease is a rare cancer syndrome that affects numerous organs. Multiple bilateral kidney tumors are the most common clinical manifestations of VHL. Previous studies have reported that the clinical characteristics and molecular mechanisms of VHL-associated RCC differ from those of sporadic RCC (17,18). In addition, the onset age of VHL-associated RCC is ~25 years old, which is earlier than that of sporadic RCC. Ning *et al* (19) reported that genetic anticipation is present in families with a VHL history and that telomere length shortening may be associated with this

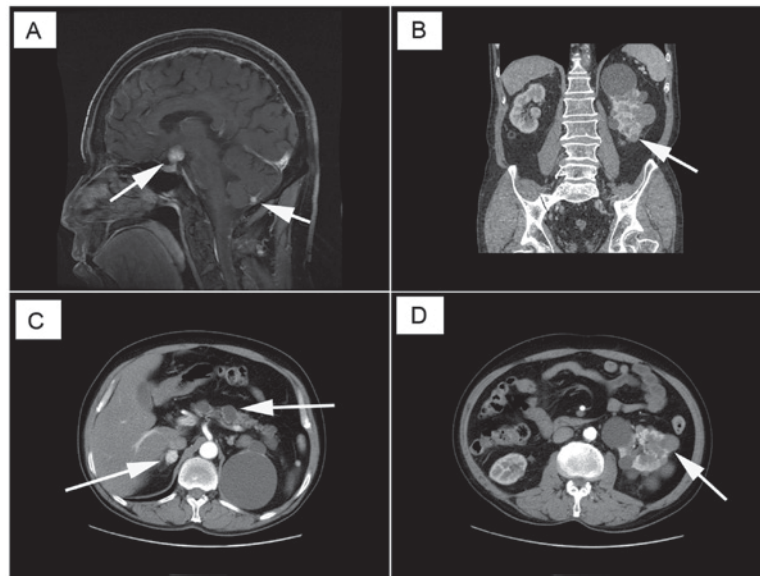


Figure 1. Von-Hippel Lindau disease is a rare tumor syndrome that involves multiple organs. (A) Central nervous system hemangioblastoma. (B) and (D) Multiple renal tumors and cysts. (C) Right adrenal pheochromocytoma and multiple pancreatic cysts or tumors. Arrows indicate cysts or tumors.

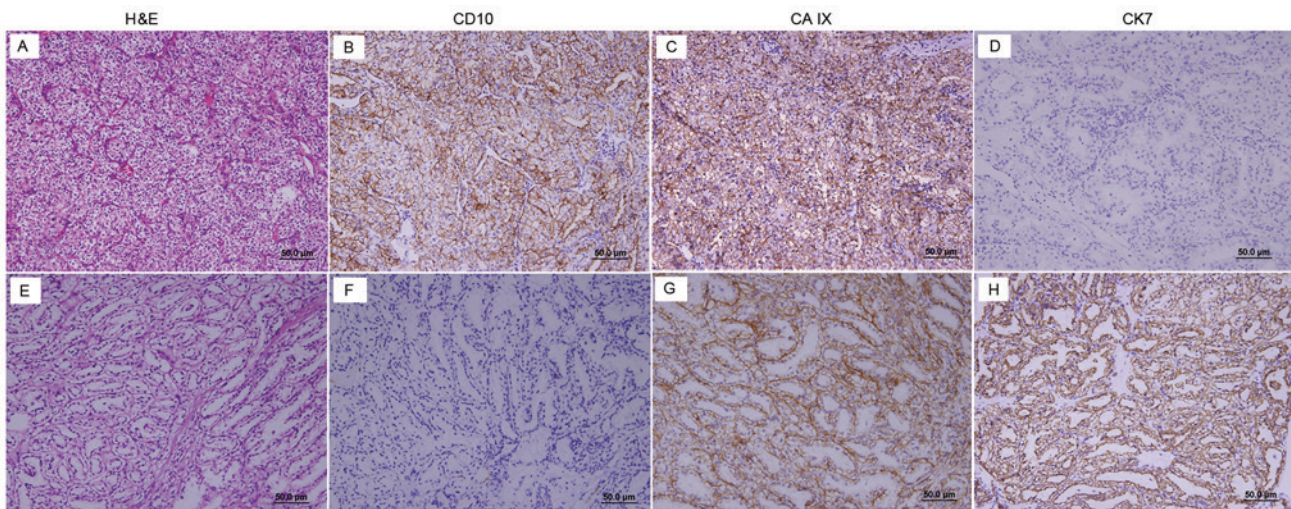


Figure 2. In total, one patient with VHL underwent open partial nephrectomy, and four renal tumors were resected. (A-D) Diagnosis of three tumors was CCRCC, whereas (E-H) the other tumor was diagnosed as a CCPRCC. (A and E) H&E staining of CCRCC and CCPRCC. (B and F) IHC for CD10 was positive in CCRCC and negative in CCPRCC. (C and G) IHC for CAIX was positive in CCRCC and CCPRCC; however, (G) goblet cell staining was observed in CCPRCC. (D and H) IHC for CK7 was negative in CCRCC and positive in CCPRCC. Magnification, x200. Scale bar, 50 μ m. CAIX, carbonic anhydrase 9; CD10, cluster of differentiation; CCRCC, clear cell renal cell carcinoma; CCPRCC, clear cell papillary renal cell carcinoma; CK7, cytokeratin 7; H&E, hematoxylin-eosin; IHC, immunohistochemistry.

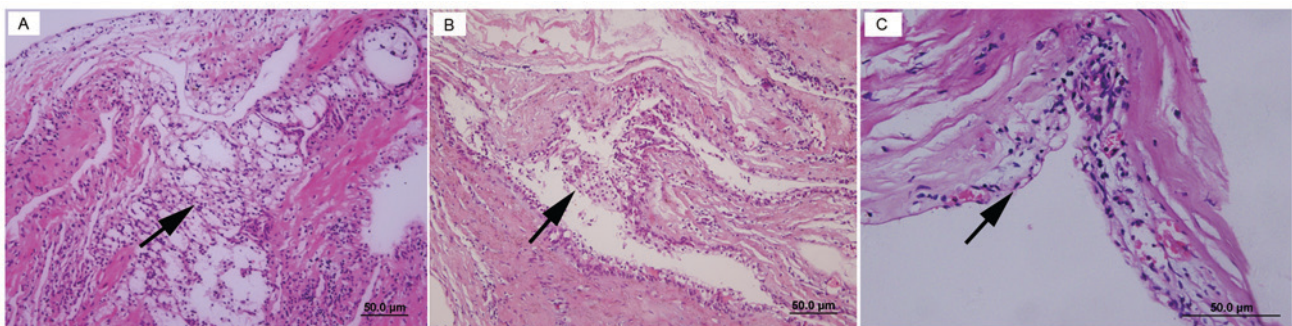


Figure 3. During surgery, renal cyst walls were collected from patients with VHL. Pathological analysis indicated that clear cells clusters were present within (A) renal cyst walls, and that (B) lined renal cyst walls and (C) renal cell carcinoma cell clusters were interspersed in renal cyst cavities (indicated by arrows). (A and B) Magnification, x200. (C) Magnification, x400. Scale bar, 50 μ m.

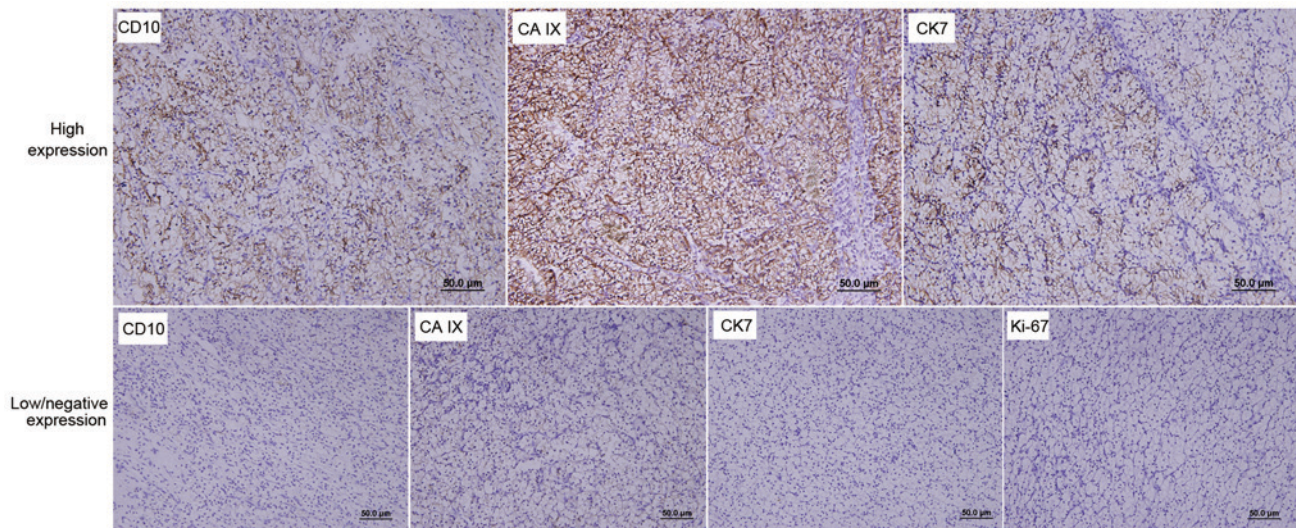


Figure 4. Immunohistochemical staining for RCC-associated molecular markers, including CD10, CAIX, CK7 and Ki-67. Staining in 0-5% cells was considered negative (-), 6-10% cells was focally positive (+), 11-50% cells was moderately positive (++) and 51-100% cells was strongly positive (+++). Two groups of RCC-associated molecular markers were defined according to their expression levels: Low (negative) expression (-, +) and high expression (++, +++). Magnification, x200. Scale bar, 50 μ m. CAIX, carbonic anhydrase 9; CD10, cluster of differentiation; CK7, cytokeratin; RCC, renal cell carcinoma.

phenomenon. VHL-associated RCC is commonly multifocal, occurs in both kidneys and is combined with multiple renal cysts. In addition, simultaneous or metachronous bilateral kidney cancer can be present. Walther *et al* (20) reported that ~1,100 non-malignant cysts have a clear cell lining and that ~600 clear cell neoplasms are observed in the VHL-associated kidney. Furthermore, the pathological type of VHL-associated RCC is low-grade CCRCC. Due to later distant metastasis, VHL-associated RCC prognosis is moderately favorable, compared with that of sporadic RCC (17). Binderup *et al* (21) reported that the estimated mean life expectancy of a man with VHL is 67 years, whereas that for a woman with VHL is 60 years, which is higher than previously reported (49 years) (3). The results from our previous study demonstrated that the estimated median life expectancy is 62 years for Chinese patients with VHL disease (11). A deeper understanding of VHL syndrome, combined with the development of novel technology has therefore significantly improved the prognosis of affected patients.

In the present study, the clinicopathological characteristics of 27 patients with VHL who underwent nephrectomy at Peking University First Hospital were analyzed. The majority of patients maintained adequate renal function following surgery. Among these 27 patients, 19 underwent partial nephrectomy. Patients with VHL commonly undergo numerous renal surgeries across their lifetimes. Nephron-sparing surgery is therefore preferred for these patients. Surgeries are not completely curative, but they can prevent metastasis. However, the tumor size threshold for surgery indication is controversial. Duffey *et al* (22) reported that patients with VHL renal tumors of <3 cm did not present with metastasis. The 3-cm size was therefore proposed as the threshold for nephron-sparing surgery in patients with VHL. However, Gupta *et al* (23) reported that oncological outcomes of patients with hereditary RCC tumors of >4 cm were similar to those of patients with T1b tumors and sporadic RCC treated with partial nephrectomy. In the present study, the mean size

of the largest renal tumors was 4.3 cm (range, 1.3-9.5 cm). No cases of VHL-associated mortality were observed during the mean 39 months of follow-up. Consequently, the 4-cm size may represent an appropriate threshold for nephron-sparing surgery, which may allow renal function preservation in patients with VHL and decrease the number of surgeries required across their lifetimes.

In the present study, renal cyst walls were collected from 10 patients with VHL during surgery. The pathological analyses indicated that seven renal cyst samples presented with a clear cell lining and RCC cell clusters that were scattered in the renal cyst cavities. These findings suggested that during surgery, the cyst fluid, which may contain RCC cells, should be prevented from flowing into the abdominal cavity to avoid RCC dispersion. Furthermore, the pathological characteristics of the renal tumors from patients with VHL were also evaluated according to the most recent diagnostic criteria. As previously reported, VHL-associated RCC is always of the clear cell subtype (24,25). In the present study, renal tumors with overlapping histological features of CCRCC and CCPRCC were observed. CCPRCC is a newly described renal epithelial tumor that was considered a novel RCC subtype in the 2012 ISUP Vancouver Classification of Renal Neoplasia. CCPRCC was initially reported in patients with end-stage renal disease; however, the clinicopathological features of this tumor subtype in VHL disease remain unclear. Rao *et al* (26) reported that CCPRCC represents a unique RCC pathological subtype and should be distinguished from CCRCC due to its different biological potentials. CCPRCC represents a rare subtype, but its prognosis is favorable (27). Conversely, the results from the present study indicated that inter and intra-tumor heterogeneity was present in VHL-associated hereditary RCC. VHL inactivation through genetic mutation is a common and early trigger that is followed by various additional mutations in different renal tumor lesions (28). In clinical practice, multiple site sampling is crucial to allow clinicians to better understand the biological potentials of the tumor.

Actual methods that determine risk stratification rely on tumor stage and grade. According to TNM staging, 21 patients (77.8%) in the present study were classified as T1N0M0 and 16 patients (59.3%) had a grade I tumor. The majority of the VHL-associated RCC cases were therefore considered as low-risk tumors due to their low TNM stage and nuclear grade. In addition, Ki-67 expression was evaluated by IHC. Ki-67 is a non-histone nuclear protein that is highly expressed during the cell cycle. The Ki-67 proliferative index indicates that cell proliferation is a predictive marker for tumor differentiation, invasion, metastasis and prognosis. In the present study, all tumors from patients with VHL exhibited low or negative Ki-67 expression. These findings suggested that when the degree of malignancy of VHL-associated RCC was relatively low, the prognosis was good.

In conclusion, VHL-associated RCC is a low-risk disease, which exhibits inter- and intratumor heterogeneity. A tumor size of ~4 cm may be considered as the threshold for nephron-sparing surgery in patients with VHL in order to reduce surgical frequency. In addition, the results from the present study suggested that, to prevent tumor cell dispersion, renal cysts should be treated with care. The present study does; however, have certain limitations, including the small patient number and its retrospective nature. Since VHL syndrome is a rare hereditary disease, it is hard to include a high number of patients with VHL in a study. In addition, kidneys can present with numerous tumors; however, only large tumors can be resected and not the tumor foci. It is therefore difficult to define recurrence in patients with VHL. Future studies will investigate the clinicopathological and survival data from a larger scale comparative study that includes patients with non-VHL-associated RCC. Understanding the clinicopathological characteristics and molecular mechanisms involved in VHL disease is crucial as it may aid clinicians in making rational treatment decisions.

Acknowledgements

The authors would like to thank Dr Dingfang Bu (Medical Experiment Center, Peking University First Hospital, Beijing, China) for providing technical assistance, Dr Qun He (Department of Urologic Pathology, Peking University First Hospital) for providing assistance with the immunohistochemistry and Dr Yuan Zhao (Department of Pathology, Beijing Chaoyang Hospital, Beijing, China) for providing assistance with immunohistochemistry.

Funding

This study was supported by the National Natural Science Foundation of China (grant no. 81572506) and the Special Health Development Research Project of Capital (grant no. 2016-2-4074).

Availability of data and materials

The datasets used and/or analyzed during the current study are available from the corresponding author on reasonable request.

Authors' contributions

BH, ZZ and KG designed the study. ZZ, JZ, LC and NZ developed the methodology. JCZ, KM and JZ acquired the data. BH, JZ and KM wrote the manuscript. NZ, KG and LC were responsible for funding acquisition and project administration. All authors read and approved the final manuscript.

Ethics approval and consent to participate

The present study was approved by the Institutional Ethics Committee of Peking University First Hospital (Beijing, China). Patients had been informed that important findings of the study would be published in a formal paper. Patients' names, ID numbers or other personally identifiable information will not be included in the paper. All patients provided written informed consent.

Patient consent for publication

All patients provided written informed consent.

Competing interests

The authors declare that they have no competing interests.

References

- Gossage L, Eisen T and Maher ER: VHL, the story of a tumour suppressor gene. *Nat Rev Cancer* 15: 55-64, 2015.
- Neumann HP and Wiestler OD: Clustering of features of von Hippel-Lindau syndrome: Evidence for a complex genetic locus. *Lancet* 337: 1052-1054, 1991.
- Maher ER, Yates JR, Harries R, Benjamin C, Harris R, Moore AT and Ferguson-Smith MA: Clinical features and natural history of von Hippel-Lindau disease. *Q J Med* 77: 1151-1163, 1990.
- Maher ER, Neumann HP and Richard S: von Hippel-Lindau disease: A clinical and scientific review. *Eur J Hum Genet* 19: 617-623, 2011.
- Bader HL and Hsu T: Systemic VHL gene functions and the VHL disease. *FEBS Lett* 586: 1562-1569, 2012.
- Nielsen SM, Rhodes L, Blanco I, Chung WK, Eng C, Maher ER, Richard S and Giles RH: Von Hippel-Lindau disease: Genetics and role of genetic counseling in a multiple neoplasia syndrome. *J Clin Oncol* 34: 2172-2181, 2016.
- Nordstrom-O'Brien M, van der Luijt RB, van Rooijen E, van den Ouweland AM, Majoor-Krakauer DF, Lolkema MP, van Brussel A, Voest EE and Giles RH: Genetic analysis of von Hippel-Lindau disease. *Hum Mutat* 31: 521-537, 2010.
- Chen F, Kishida T, Yao M, Hustad T, Glavac D, Dean M, Gnarr JR, Orcutt ML, Duh FM, Glenn G, *et al*: Germline mutations in the von Hippel-Lindau disease tumor suppressor gene: Correlations with phenotype. *Hum Mutat* 5: 66-75, 1995.
- Hoffman MA, Ohh M, Yang H, Klcio JM, Ivan M and Kaelin WG Jr: von Hippel-Lindau protein mutants linked to type 2C VHL disease preserve the ability to downregulate HIF. *Hum Mol Genet* 10: 1019-1027, 2001.
- Richard S, David P, Marsot-Dupuch K, Giraud S, Bérout C and Resche F: Central nervous system hemangioblastomas, endolymphatic sac tumors, and von Hippel-Lindau disease. *Neurosurg Rev* 23: 1-24, 2000.
- Wang JY, Peng SH, Li T, Ning XH, Liu SJ, Hong BA, Liu JY, Wu PJ, Zhou BW, Zhou JC, *et al*: Risk factors for survival in patients with von Hippel-Lindau disease. *J Med Genet* 55: 322-328, 2018.
- Wu P, Zhang N, Wang X, Ning X, Li T, Bu D and Gong K: Family history of von Hippel-Lindau disease was uncommon in Chinese patients: Suggesting the higher frequency of de novo mutations in VHL gene in these patients. *J Hum Genet* 57: 238-243, 2012.

13. Wang JY, Peng SH, Ning XH, Li T, Liu SJ, Liu JY, Hong BA, Qi NN, Peng X, Zhou BW, *et al*: Shorter telomere length increases age-related tumor risks in von Hippel-Lindau disease patients. *Cancer Med* 6: 2131-2141, 2017.
14. Moch H, Cubilla AL, Humphrey PA, Reuter VE and Ulbright TM: The 2016 WHO classification of tumours of the urinary system and male genital organs-part a: Renal, penile, and testicular tumours. *Eur Urol* 70: 93-105, 2016.
15. Kim SP, Alt AL, Weight CJ, Costello BA, Cheville JC, Lohse C, Allmer C and Leibovich BC: Independent validation of the 2010 American Joint Committee on Cancer TNM classification for renal cell carcinoma: Results from a large, single institution cohort. *J Urol* 185: 2035-2039, 2011.
16. Ning XH, Li T, Gong YQ, He Q, Shen QI, Peng SH, Wang JY, Chen JC, Guo YL and Gong K: Association between FBP1 and hypoxia-related gene expression in clear cell renal cell carcinoma. *Oncol Lett* 11: 4095-4098, 2016.
17. Neumann HP, Bender BU, Berger DP, Laubenberger J, Schultze-Seemann W, Wetterauer U, Ferstl FJ, Herbst EW, Schwarzkopf G, Hes FJ, *et al*: Prevalence, morphology and biology of renal cell carcinoma in von Hippel-Lindau disease compared to sporadic renal cell carcinoma. *J Urol* 160: 1248-1254, 1998.
18. Choyke PL, Glenn GM, Walther MM, Patronas NJ, Linehan WM and Zbar B: Von Hippel-Lindau disease: Genetic, clinical, and imaging features. *Radiology* 194: 629-642, 1995.
19. Ning XH, Zhang N, Li T, Wu PJ, Wang X, Li XY, Peng SH, Wang JY, Chen JC and Gong K: Telomere shortening is associated with genetic anticipation in Chinese Von Hippel-Lindau disease families. *Cancer Res* 74: 3802-3809, 2014.
20. Walther MM, Lubensky IA, Venzon D, Zbar B and Linehan WM: Prevalence of microscopic lesions in grossly normal renal parenchyma from patients with von Hippel-Lindau disease, sporadic renal cell carcinoma and no renal disease: Clinical implications. *J Urol* 154: 2010-2015, 1995.
21. Binderup ML, Jensen AM, Budtz-Jørgensen E and Bisgaard ML: Survival and causes of death in patients with von Hippel-Lindau disease. *J Med Genet* 54: 11-18, 2017.
22. Duffey BG, Choyke PL, Glenn G, Grubb RL, Venzon D, Linehan WM and Walther MM: The relationship between renal tumor size and metastases in patients with von Hippel-Lindau disease. *J Urol* 172: 63-65, 2004.
23. Gupta GN, Peterson J, Thakore KN, Pinto PA, Linehan WM and Bratslavsky G: Oncological outcomes of partial nephrectomy for multifocal renal cell carcinoma greater than 4 cm. *J Urol* 184: 59-63, 2010.
24. Lonser RR, Glenn GM, Walther M, Chew EY, Libutti SK, Linehan WM and Oldfield EH: Von Hippel-Lindau disease. *Lancet* 361: 2059-2067, 2003.
25. Crespigio J, Berbel L, Dias MA, Berbel RF, Pereira SS, Pignatelli D and Mazzucco TL: Von Hippel-Lindau disease: A single gene, several hereditary tumors. *J Endocrinol Invest* 41: 21-31, 2018.
26. Rao P, Monzon F, Jonasch E, Matin SF and Tamboli P: Clear cell papillary renal cell carcinoma in patients with von Hippel-Lindau syndrome-clinicopathological features and comparative genomic analysis of 3 cases. *Hum Pathol* 45: 1966-1972, 2014.
27. DiIombi ML, Cheng L, Argani P and Epstein JI: Do clear cell papillary renal cell carcinomas have malignant potential. *Am J Surg Pathol* 39: 1621-1634, 2015.
28. Kim E and Zschiedrich S: Renal cell carcinoma in von Hippel-Lindau disease-from tumor genetics to novel therapeutic strategies. *Front Pediatr* 6: 16, 2018.



This work is licensed under a Creative Commons Attribution-NonCommercial-NoDerivatives 4.0 International (CC BY-NC-ND 4.0) License.