


Contents lists available at [ScienceDirect](https://www.sciencedirect.com)

North American Spine Society Journal (NASSJ)

journal homepage: www.elsevier.com/locate/xnsj

Clinical Case Studies

Traumatic hangman's fracture after cervical disk arthroplasty with device in-tact: A case report and literature review

Carson Fuller^{a,*}, Kyle Geiger^a, Crystal Gomez^b, Miguel A. Schmitz^{a,b}^a Washington State University, Elson S. Floyd College of Medicine, Spokane, WA, U.S.A^b Alpine Orthopaedic and Spine, Spokane, WA, U.S.A.

ARTICLE INFO

Key Words:

Cervical disk arthroplasty
 anterior cervical discectomy and fusion
 trauma
 artificial disk extrusion
 Prodisc-C

ABSTRACT

Background Context: Cervical disk arthroplasty (CDA) has been demonstrated to be a safe and effective method to treat myelopathy with the added benefit of preserving neck mobility compared to anterior cervical discectomy and fusion (ACDF). Few studies describe complications of trauma after CDA, and to our knowledge this is the only study describing a grossly intact artificial cervical disk (ACD) without extrusion after high energy trauma. Based on our case and a review of literature, we hypothesize that, given adequate osseous integration (OI), CDA may be a safe intervention despite their risk for higher energy trauma.

Purpose: To present a rare case of high-energy trauma after CDA resulting in a Hangman's fracture and grossly in-tact ACD and to engage a biomechanical discussion of trauma after CDA and ACDF utilizing a literature review.

Study Design/Setting: Case-report with literature review and discussion

Patient Sample: Electronic medical record data

Outcome Measures: Computed Tomography, Magnetic Resonance Imaging, and X-Ray physiologic measures

Methods: We report the case of a 44-year-old woman who received a C5-C6 level CDA with a (Synthes Prodisc-C®, Synthes Spine Company, L.P., West Chester, PA) and was subsequently involved in a high-speed motorcycle accident one-and-a-half years later resulting in a Hangman's fracture.

Results: Radiographic evidence after the motorcycle wreck demonstrated a minimally displaced Hangman's fracture at the C2 vertebrae through the pedicles on both sides, partially involving the transverse foramina with approximately 5 mm of displacement. The ACD at C5-C6 was grossly intact and no malalignment was noted. Three years later the patient elected to have an ACDF due to recurrence of facet pain that appeared by way of selective medial branch block injections to originate posteriorly in the facets of C5-6. A literature review revealed reports of trauma induced adjacent disk herniation, metallosis, and implant extrusion after CDA. No accounts of intact hardware, or concomitant Hangman's fracture after CDA were found following high-energy trauma.

Conclusions: Our case reveals the first reported occurrence of a traumatic Hangman's fracture with intact fusion hardware after CDA. We hypothesize that the preserved mobility in the affected spinal level after the CDA exerted a protective effect compared to an ACDF following the high-speed trauma, particularly on the adjacent segments. This case and included literature review, reveal the need for future research efforts to guide decision making in whether ACDF or CDA is superior in younger patients at higher risk for trauma.

Purpose

Cervical Disk Arthroplasty (CDA) has become an increasingly preferred approach for the treatment of cervical radiculopathy (CR).^[1–3] Few studies have demonstrated risks associated with high-energy trauma after CDA (Table 1), and to our knowledge, this is the only

study describing a grossly intact artificial cervical disk (ACD) without extrusion after high-energy trauma.^[6–12] While the risk of ACD implant translation remains, this case-report and literature review investigate the question of whether CDA or anterior discectomy and fusion (ACDF) may be the preferred approach for younger patients at higher risk for trauma.

* Corresponding author: Requests for reprints: Carson Fuller, Address: 212 E Central Ave #365, Spokane, WA 99208, Phone: (509) 385-9863
 E-mail address: carson.fuller@wsu.edu (C. Fuller).

Table 1
Literature Review of Trauma after CDA/ACDF

Source	# of Patients	Surgery/Level	Implant	Trauma Type	Time between initial operation and trauma	Result	Outcome
Our Patient	1	CDA/C5-C6	Synthes Prodisc-C©[1]	High Speed somersault with anterior extension force	18 months	Hangman's fracture at C2, disk grossly intact with no extrusion or malalignment	Revision ACDF years later from soft tissue trauma
Niu, T., et al.[6]	1	CDA/C4-C5	Synthes Prodisc-C©[1]	Paragliding accident resulting in forced flexion	14 months	4 mm anterior protrusion	Removal and Fusion
Brenke C et al.[7]	1	CDA/C5-C6	M6-C©[2]	Unknown, potentially atraumatic	8 years	Core herniation with posterior migration of inferior disk segment	Removal and Fusion
Viezens L et al.[8]	1	CDA/C5-C6, C6-C7	2 CTDR© devices[3]	Unknown, potentially atraumatic	7 months	Posterior disk herniation at C6/C7 with partial paraplegia	Removal and 2-level fusion. Permanent lower extremity weakness with regained upper extremity sensation and strength 38 months post-op
Wagner, S. C., et al.[9]	1	CDA/C5-C6	Bryan Disc©[4]	Low-energy posteriorly forced flexion from a falling book	6 months	2 mm Anterior extrusion	Revision based on CT, no recurrence of radiculopathy
Fan, H., et al.[10]	1	CDA	Bryan Disc©[4]	Unknown, potentially atraumatic	8 years	Broken anterior polyurethane sheath	Revision conversion to ACDF with cage
Lebl DR, et al.[11]	5	CDA	Synthes Prodisc-C©[1]	MVA	23 months	Anterior extrusion and Cervical fracture	Removal, no further data
		1. C5/C6		MVA	23 months	Anterior extrusion and Cervical fracture	Removal, no further data
		2. C6/C7		Unknown trauma	32 months	Posterior dislocation into spinal canal	Removal, no further data
		3. C5/C6		MVA	36 months	Anterior extrusion	Removal, no further data
		4. C5/C6 5. C6/C7		Fall	4 months	Posterior dislocation and cervical fracture	Removal, no further data
Yang, C. C., et al.[12]	1	CDA/C6-C7	Bryan Disc©[4]	Hyperflexion-extension whiplash injury from MVA	8 years	Metallosis and anterior migration of the superior disk aspect	Removal and fusion with resolution of symptoms
Watkins, R. G. t., et al.[15]	3	ACDF/C3-C4, C4-C5, C4-C5	Titanium-coated PEEK (polyetheretherketone) graft filled with iliac crest autograft and plate	Anterior extension from return to sports	1.7-8 years	Adjacent disk disease	ACDF of adjacent disk
Maroon, J. C., et al.[16]	1	ACDF/C4-C5	Anterior plate, no further data	Return to football resulting in flexion trauma	2 years	Adjacent disk disease	ACDF of adjacent disk
Brauge, D., et al.[17]	1	ACDF/C5-C7	Anterior plate, no further data	Forced flexion injury after return to rugby	4 years	C3/C4 complete facet dislocation resulting in tetraplegia	Open reduction and posterior fixation C3-C5
Veli C., et al.[18]	1	ACDF/C4-C6	Anterior plate, no further data	MVA	2 years	Broken Plate	Revision ACDF

Abbreviations: MVA (motor vehicle accident), CDA (Cervical disk arthroplasty), ACDF (Anterior cervical discectomy and fusion)

Device References:

1. Synthes Prodisc-C© (Synthes Spine Company, L.P., West Chester, PA)
2. M6-C CAD (Spinal Kinetics, Sunnyvale, CA, USA)
3. CTDR devices (Osteon ACD Device, ACD 1607; Osteon NV)
4. Bryan Disc; (Medtronic Sofamor Danek, Memphis, TN)

Case Presentation

Initial Operation

A 44-year-old woman with a complex history of cervical pain who previously underwent a rhizotomy at levels C2-C3, C4-C5, and C5-C6 returned to the clinic with worsening radiculopathy symptoms. She was found to have mild degenerative changes and a herniated nucleus pulposus at levels C5-C6 with concordant C6 distribution sensory radiculopathy. She elected to undergo further surgery (Fig. 1). A CDA was advocated due to the patient's age and lack of co-morbidities. She

agreed and underwent a CDA with insertion of an ACD at a median deep designation of 5 mm (Fig. 1, Images B and C). The surgery was uncomplicated, and she was discharged home with a successful postoperative course in the early and extended post-operative period.

Trauma

Unfortunately, one-and-a-half years after her operation, she was involved in a high-energy motorcycle accident involving deceleration into a car with a helmet in place. The patient's recollection of the trauma involved a face-plant onto the windshield of an oncoming car in the oppos-

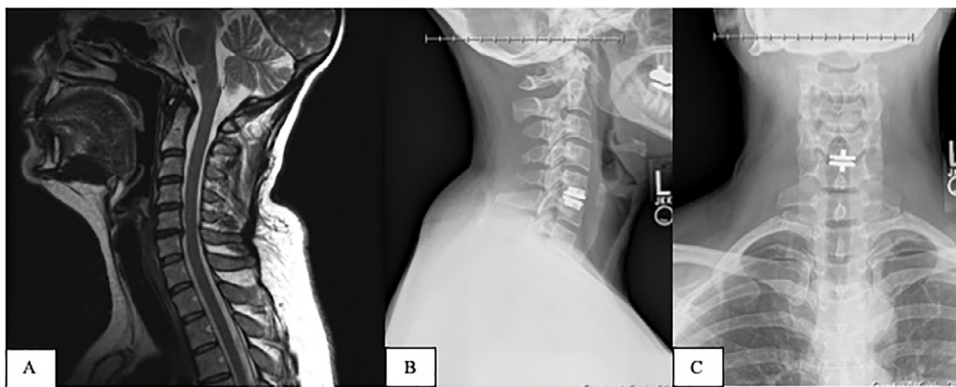
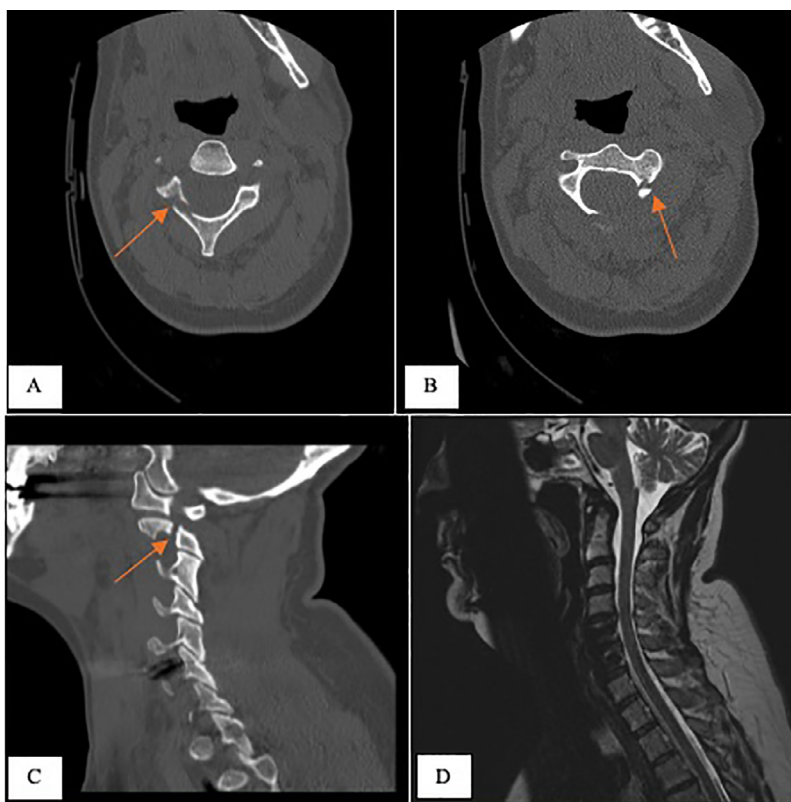


Fig. 1. A T2 weighted MRI of the C5/C6 disk herniation at presentation (Image A) and Lateral/AP X-Ray of Post-Operative CDA (Images B and C).

A T2 weighted MRI of the C5/C6 disk herniation at presentation (Image A) and Lateral/AP X-Ray of Post-Operative CDA (Images B and C)



Day 1 of traumatic motorcycle accident.
 Images A and B: Axial CT Scan demonstrating Hangman's fracture through the pedicles of C2 on both sides
 Image C: Sagittal CT Scan of the Hangman's fracture of C2
 Image D: T2 MRI Showing Herniation at C4/C5 with improved C5/C6 level

Fig. 2. Day 1 of traumatic motorcycle accident. Images A and B: Axial CT Scan demonstrating Hangman's fracture through the pedicles of C2 on both sides. Image C; Sagittal CT Scan of the Hangman's fracture of C2. Image D: T2 MRI Showing Herniation at C4/C5 with improved C5/C6 level.

ing lane, followed by multiple somersaults on the pavement ending up in the sitting position in a conscious state. The initial impact of the accident resulted in a hyperextension force of the neck, which was followed by repeated neck compression and flexional forces during the somersaults. She sustained a compound left humerus fracture, and a Hangman's fracture at C2 (Levine and Edwards Type II)[20] through the pedicles on both sides, partially involving the transverse foramina with approximately 5 mm of displacement (Fig. 2). The ACD at C5-C6 was grossly intact and no malalignment was noted on CT scan (Fig. 3). She underwent

open reduction and internal fixation of her humeral fracture, and her Hangman's fracture was managed non-operatively with a cervical collar.

Reoperation

In time the Hangman's fracture healed, however, three years after the accident she presented with a radiographically inconclusive facet arthropathy at C5-C6, likely due to whiplash trauma during the accident. She subsequently underwent an ACDF at C5-C6 with removal

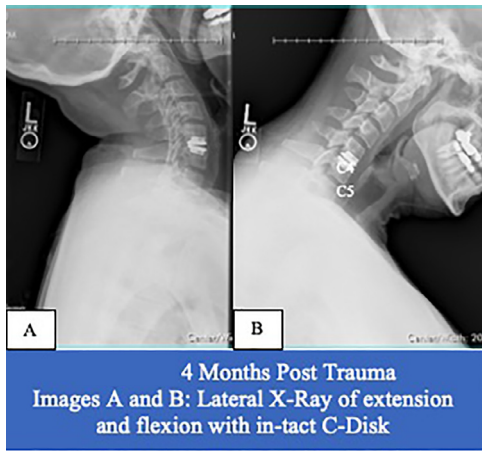


Fig. 3. 4 Months Post Trauma. Image A and B: Lateral X-Ray of extension and flexion with in-tact C-Disk.

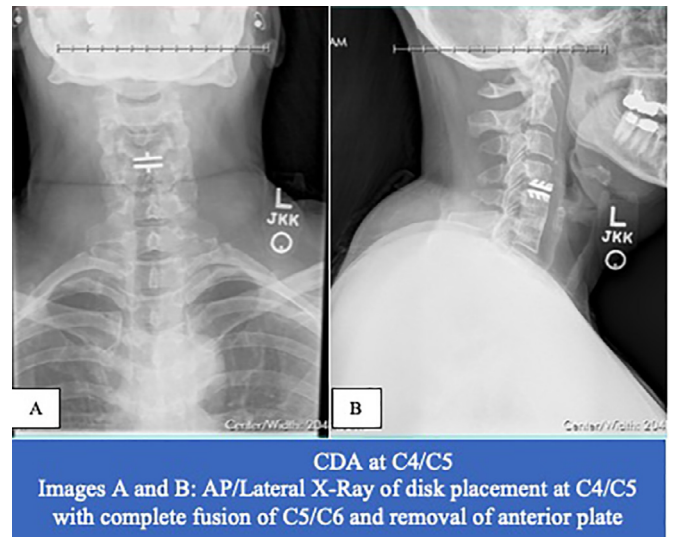


Fig. 5. CDA at C4/C5 Image A and B: AP/Lateral X-Ray of disk placement at C4/C5 with complete fusion of C5/C6 and removal of anterior plate.

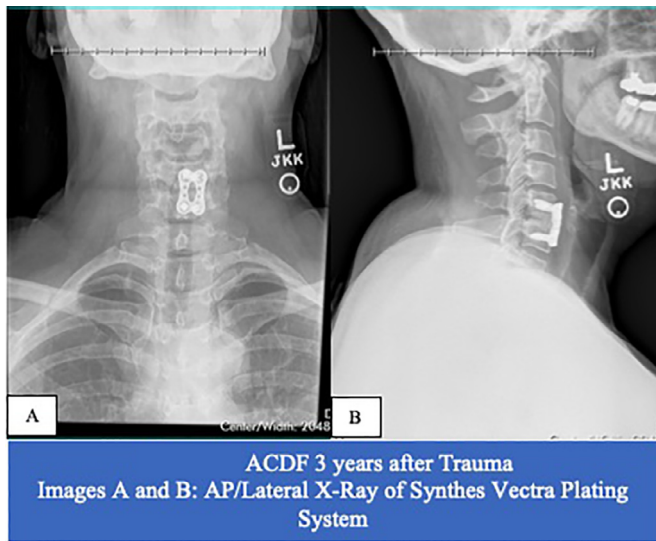


Fig. 4. ACDF 3 years after Trauma. Image A and B: AP/Lateral X-Ray of Synthes Vectra Plating System.

of the artificial disk, allograft fusion into the interspace, and fusion with an anterior plating system (Fig. 4). At her most recent follow-up, approximately 4.5 years after the most recent operation, the patient reports excellent progress with a pain score of 4/10 at its worst.

As demonstrated in Figures 1 and 2, the patient had evidence of C4/C5 disk herniation before her accident. Thus, the progression of C4/C5 disk disease led to a CDA in 2019 (Fig. 5).

Discussion

ACDF is the most common modality of treating cervical radiculopathy associated with cervical disk disease, and complication rates are well known.[14] In recent years, the emergence of CDA has proved to be a safe and effective alternative, with the added advantages of retained mobility in the affected segment, and faster recovery.[1-5] The literature on trauma after both ACDF and CDA is sparse and primarily limited to case reports (Table 1). [6-12,15-18] Furthermore, our patient sustained a high-speed traumatic axial (C2) fracture 1.5 years after an CDA resulting in an intact ACD implant; an incidence that has not been described in any case-report to our knowledge. Our discussion will provide a review of current literature describing complications due to trauma after CDA and ACDF, a biomechanical

discussion of forces required to illicit device migration and Hangman’s fracture, and a hypothesis to guide further research.

Trauma After CDA and ACDF

Accounts of trauma after CDA are elicited in numerous case reports (Table 1). Based on our literature review, the most common implant-related failure after trauma is artificial disk extrusion. [6,8,9,11] These complications are primarily reported within shorter post-operative timeframes, spanning from 6 months to 3 years. Other cases describing more rare complications such as metallosis, artificial disk core herniation, or broken anterior disk sheaths have been associated with much longer post-operative timeframes, at 8 years on average. [7,10,12] Additionally it should be noted that due to a lack of information, these three complications may have occurred in the absence of major trauma. [7,8,10]

Atraumatic complications of ACDF are well-described in literature, and implant-related failure is among the minority of the composition of complications.[22] Case reports of trauma after ACDF are limited and the majority of them describe adjacent disk disease rather than implant-related trauma.[15-18] One case report mentioned an anterior plate fracture from a motor vehicle accident (MVA) two years after a two-level ACDF.[18]

Based on our literature review, major differences in trauma-related complications after CDA compared to ACDF are due to dissimilar points of maximal stress between implant types. Generally speaking, implants fail at the point of maximal stress. In CDA, with the implantation of a prosthetic ball-in-socket artificial disk, physiologic motion is preserved in the affected disk. [4,5] As a result, there is less change in translational force among adjacent cervical disks leading to a reduction in adjacent disk strain relative to ACDF.[2-5] Thus, the point of maximal stress in an artificial disk is located in the bone-to-disk interface, with a strong reliance on osseous integration (OI). On the contrary, in ACDF, the points of maximal stress may be situated in the adjacent disks above and below fixation, the screw-bone interface, within the plate, or within the screw.[22]

It is hypothesized that OI balance plays a vital role in device stability. Too much OI will likely result in heterotopic ossification, a well-defined phenomenon that can lead to hyper-rigidity of the implant.[19] Conversely, Inadequate OI is a risk for device migration. Accounts of disk migration after CDA in shorter post-operative timeframes are likely due to inadequate OI.

Axial Fracture Pathophysiology

Traumatic spondylolisthesis of the axis (Hangman's fracture) account for nearly one-third of cervical spine fractures and are due to a hyperextension-distraction force resulting in a bilateral fracture of the pars interarticularis of C2.[20,21]

The Levine and Edwards classification[20] divides Hangman's fractures into four types:

Type I: fracture without an angular deviation and translational deviation of less than 3.5 mm that occurs due to hyperextension and axial compression;

Type II: fracture with a significant translational or angular deviation that occurs due to hyperextension and axial compression combined with a mechanism of flexion-compression;

Type IIa: fracture with a small translational deviation and wide angulation, with an increase in posterior disc space between C2-C3 upon application of traction that occurs due to a flexion-distraction; and

Type III: fracture with a large translational and angular deviation, which is associated with unilateral or bilateral dislocation of the C2-C3 joint facets and occurs due to a flexion-compression mechanism.

Conclusion

Based on the complex mechanism of injury after our patient's high-speed motorcycle wreck resulting in a somersault on the pavement, it is difficult to assume the primary forces involved on her cervical spine. We hypothesize that the Hangman's fracture was likely due to a hyperextension-distraction force from the initial head impact on the car, and with the subsequent tumble the weight of her helmet exerting a linear force vector away from her body. However, it is likely that she also experienced a hyperextension-flexion (whiplash) force at some point during the wreck.

Some possible explanations for why our patient did not suffer implant extrusion or more severe morbidity after the wreck are as follows:

1. The presence of an ACD allowed for physiologic translation of force along the cervical spine. Had she initially been treated with an ACDF, we believe this would have introduced a weak point in her cervical spine above and below the implant. Brauge, D., et al. presents a case report of a facet dislocation of C3-C4 resulting in quadriplegia after a C5-C7 ACDF.[17]
2. Our patient likely achieved optimal OI. Multiple case reports of disk extrusion after CDA were in the early postoperative period and were hypothesized to be due to inadequate OI. Our patient was relatively young at 44 years, without co-morbid conditions preventing bone healing. Furthermore, the accident occurred 1.5 years postoperatively. The combination of these two details supports a probable hypothesis that she achieved ideal OI to prevent implant extrusion.
3. Lastly, it could be the case that the forces she experienced during her wreck were isolated from the potential traumatic translation of the ACD. The majority of cases in our literature review involving ACD failure were due to flexion or hyperextension forces. However, the sparsity in data and potential confounding variables prevent us from deducing which specific forces could result in ACD translation.

We conclude that the ACD implant may have exerted a protective effect during our patient's high-speed motorcycle wreck relative to an ACDF. This assumption is supported by literature describing retained mobility in the affected segment after CDA, as well as case-reports of trauma after ACDF and CDA.[4–19] However there are drawbacks to this conclusion, as we cannot accurately quantify the forces she experienced during her wreck. Additionally, our patient did eventually have a revision ACDF three years after the motorcycle accident due to the recurrence of a C5-C6 arthropathy at the level of the C5-C6 that was likely due to soft tissue injury or facet trauma rather than micro-extrusion of the ACD. We arrived at this conclusion based on the administration of two medial nerve branch blocks that temporarily

resolved symptoms, as well as a sequential imaging each year post-trauma that failed to provide any evidence of ACD positional change. Literature on the limited role of radiographic evidence after whiplash injury also supports this hypothesis.[23,24]

In summary, this is the first reported case of high-energy trauma following a CDA, resulting in a Hangman's fracture and grossly in-tact ACD. The uniqueness of this case allows for a discussion of previous instances of trauma following CDA and ACDF, as well as the hypothesis of a protective effect of artificial disks compared to ACDF in the event of trauma given adequate OI. We believe this case should be presented in the context of younger patients who engage in higher-risk activities and are deciding between ACDF and CDA in the treatment of cervical myelopathy. As risk of traumatic disk extrusion after CDA remains, further research should focus on which treatment modality may be safer in individuals at higher risk of trauma, as well as how to maximize OI of artificial disks.

Conflicts of Interest and Source of Funding

The authors have no direct financial relationships relevant to this article.

Acknowledgements

None

Supplementary materials

Supplementary material associated with this article can be found, in the online version, at doi:10.1016/j.xnsj.2020.100007.

References

- [1] Malham GM, et al. "Cervical artificial disc replacement with ProDisc-C: clinical and radiographic outcomes with long-term follow-up. *J Clin Neurosci* 2014;21(6):949–53.
- [2] Murrey D, et al. "Results of the prospective, randomized, controlled multicenter Food and Drug Administration investigational device exemption study of the ProDisc-C total disc replacement versus anterior discectomy and fusion for the treatment of 1-level symptomatic cervical disc disease. *Spine J* 2009;9(4):275–86.
- [3] Loumeau TP, et al. "A RCT comparing 7-year clinical outcomes of one level symptomatic cervical disc disease (SCDD) following ProDisc-C total disc arthroplasty (TDA) versus anterior cervical discectomy and fusion (ACDF). *Eur Spine J* 2016;25(7):2263–70.
- [4] Puttlitz CM, et al. Intervertebral disc replacement maintains cervical spine kinetics. *Spine (Phila Pa 1976)* 2004;29(24):2809–14.
- [5] DiAngelo DJ, et al. "In vitro biomechanics of cervical disc arthroplasty with the ProDisc-C total disc implant. *Neurosurg Focus* 2004;17(3):E7.
- [6] Niu T, et al. "Cervical artificial disc extrusion after a paragliding accident. *Surg Neurol Int* 2017;8:138.
- [7] Brenke C, et al. "Core herniation after implantation of a cervical artificial disc: case report. *Eur Spine J* 2015;24(Suppl 4):S536–9.
- [8] Viezens L, et al. "An incomplete paraplegia following the dislocation of an artificial cervical total disc replacement. *J Neurosurg Spine* 2013;18(3):255–9.
- [9] Wagner SC, et al. "Traumatic Migration of the Bryan Cervical Disc Arthroplasty. *Global Spine J* 2016;6(1):e15–20.
- [10] Fan H, et al. Implant Failure of Bryan Cervical Disc due to Broken Polyurethane Sheath. *Spine* 2012;37(13). doi:10.1097/brs.0b013e3182477d85.
- [11] Lebl DR, et al. "The mechanical performance of cervical total disc replacements in vivo: prospective retrieval analysis of prodisc-C devices. *Spine (Phila Pa 1976)* 2012;37(26):2151–60.
- [12] Yang CC, et al. "Metallosis after traumatic loosening of Bryan cervical disc arthroplasty: a case report and literature review. *Eur Spine J* 2018;27(Suppl 3):415–20.
- [13] Ryan MD, Henderson JJ. "The epidemiology of fractures and fracture-dislocations of the cervical spine. *Injury* 1992;23(1):38–40.
- [14] Epstein NE, et al. "A Review of Complication Rates for Anterior Cervical Discectomy and Fusion (ACDF). *Surg Neurol Int* 2019;10:100.
- [15] Watkins RGT, et al. "Return to Play After Anterior Cervical Discectomy and Fusion in Professional Athletes. *Orthop J Sports Med* 2018;6(6):2325967118779672.
- [16] Maroon JC, et al. "Outcomes after anterior cervical discectomy and fusion in professional athletes. *Neurosurgery* 2013;73(1):103–12 discussion 112.
- [17] Brauge D, et al. "Catastrophic Return to Play in Rugby After Double Cervical Arthrodesis. *Clin J Sport Med* 2018.
- [18] Veli C, et al. "Cervical plate fracture: a rare complication. *Pan Afr Med J* 2015;20:266.
- [19] Yi S, et al. "The fate of heterotopic ossification associated with cervical artificial disc replacement. *Spine (Phila Pa 1976)* 2014;39(25):2078–83.

- [20] Levine AM, Edwards CC. "Traumatic lesions of the occipitoatlantoaxial complex. Clin Orthop Relat Res 1989;239:53–68.
- [21] Teo EC, et al. "Experimental investigation of failure load and fracture patterns of C2 (axis). J Biomech 2001;34(8):1005–10.
- [22] Gonugunta V, et al. Anterior cervical plating. Neurol India 2005;53(4):424–32.
- [23] Yadla S, Ratliff JK, Harrop JS. Whiplash: diagnosis, treatment, and associated injuries. Current reviews in musculoskeletal medicine 2008;1(1):65–8. <https://doi.org/10.1007/s12178-007-9008-x>.
- [24] Geothem JW, et al. Whiplash injuries: is there a role for imaging? Eur J Radiol 1996;22:30–7. doi:10.1016/0720-048X(95)00696-N.