

Congenital internal carotid artery hypoplasia

Case report

Dianbin Hou, BS^a, Yu Mei, BS^a, Yongqiang Ji, MD^b, Hongliang Wu, PhD, MD^a, Huilong Zhang, MD^a, Zhongwen Sun, MD^a, Wenjuan Li, MD^c, Bing Li, MD^a, Chao Ren, MD^{a,d,*}, Lina Guan, MD^{e,*}, Chuanyu Liu, MD^{a,*}

Abstract

Rationale: Congenital internal carotid artery hypoplasia (CICAH) is rarely reported. This study aimed to discuss the epidemiological characteristics, clinical manifestation, imaging and treatment of CICAH.

Patient concerns: The case was male who showed barylalia and limited abilities of the left limbs as their main clinical manifestation. This patient was diagnosed CICAH by digital subtraction angiography (DSA) and computed tomography (CT).

Diagnosis: CICAH.

Interventions: The patient underwent anti platelet aggregation, lipid-lowering, improving cerebral circulation.

Outcomes: The patient was in a stable condition after management of cerebrovascular risk.

Lessons: Given the asymptomatic and congenital nature of carotid agenesis, no treatment is necessary or possible to re-establish the internal carotid artery (ICA). However, with the high risk of aneurysm and cerebrovascular insufficiency, management of cerebrovascular risk is important. Urgent radiological assessment is necessary for patients with suspicious neurological symptoms.

Abbreviations: CICAH = congenital internal carotid artery hypoplasia, CT = computed tomography, ICA = internal carotid artery, MRA = magnetic resonance angiography, MRI = magnetic resonance imaging.

Keywords: aneurysm, CT scavenging of the skull base, DSA, hypoplasia, internal carotid artery

Editor: N/A.

DH, YM, and YJ are the authors who contributed equally to this work.

This study was funded by Shandong Provincial Key Research & Development Project (grant number 2017GSF218043), National Natural Science Foundation of China (grant number 81501185) and Yantai Science and Technology Planning Project (grant number 2016WS017).

This study was approved by the ethics committee of Yantai Yuhuangding Hospital Affiliated to Qingdao University. The family members of both patients signed their informed consent.

The authors have not published or submitted this manuscript or its accompanying data elsewhere, and have no conflict of interest to declare.

^a Department of Neurology, ^b Department of Nephrology, ^c Radiology Department, Affiliated Yantai Yuhuangding Hospital of Qingdao University, Yantai,

^d Department of Neurology and Suzhou Clinical Research Center of Neurological Disease, The Second Affiliated Hospital of Soochow University, Suzhou,

^e Neurosurgical Intensive Care Unit, Affiliated Yantai Yuhuangding Hospital of Qingdao University, Yantai, China.

* Correspondence: Chao Ren, Department of Neurology and Suzhou Clinical Research Center of Neurological Disease, The Second Affiliated Hospital of Soochow University, Suzhou 215004, China; Department of Neurology, Affiliated Yantai Yuhuangding Hospital of Qingdao University, Yantai, 264000, China (e-mail: renchaotg@126.com), Lina Guan, Neurosurgical Intensive Care Unit, Affiliated Yantai Yuhuangding Hospital of Qingdao University, Yantai, 264000, China (e-mail: 15688593924@126.com), Chuanyu Liu, Department of Neurology, Yantai Yuhuangding Hospital Affiliated to Qingdao University, 20# the East Road of Yuhuangding, Yantai 264000, Shandong, China (e-mail: lcy32@126.com).

Copyright © 2019 the Author(s). Published by Wolters Kluwer Health, Inc. This is an open access article distributed under the terms of the Creative Commons Attribution-Non Commercial-No Derivatives License 4.0 (CCBY-NC-ND), where it is permissible to download and share the work provided it is properly cited. The work cannot be changed in any way or used commercially without permission from the journal.

Medicine (2019) 98:1(e13986)

Received: 22 August 2018 / Accepted: 10 December 2018

<http://dx.doi.org/10.1097/MD.0000000000013986>

1. Introduction

As one of the most important blood vessels supplying the brain, the internal carotid artery (ICA) rarely mutates during its development. It is important to recognize this rare anomaly, particularly when considering endovascular interventions in the event of cerebrovascular events with revascularization. ICA originates from the third arch artery and the dorsal aorta in normal embryogenesis.^[1] The first case of absence of ICA was discovered by Tode in an autopsy on October 10, 1787.^[2] Later, Verbiest et al reported the first case of congenital internal carotid artery hypoplasia (CICAH) confirmed by angiography.^[3] However, the exact mechanism of CICAH was not clear. Keen et al believed that overbending of the head, excessive pressure and amniotic adhesion caused the absence of ICA.^[4] Other studies suggested CICAH was related to the loss of certain genes such as *FOXI3* and *22q11.2*.^[5–6] We report a case of left internal carotid agenesis in a middle aged male associated with ischemic stroke.

2. Case report

The patient was a 58-year-old male admitted to our hospital on January 5, 2015 due to barylalia with limited abilities of the left limbs. He had a history of hypertension for 5 years. Five hours before his admission he had barylalia, but could understand the language of others, accompanied with limited abilities of the left limbs. His left upper limb was able to hold things but the patient was unable to stand with the left leg. Neurologic examination at the time of admission showed that the patient was sane with no aphasia, slight shallow left nasolabial sulcus, dysarthria, deviation of tongue to the left, level 4 muscle strength on the left upper limb, level 3 muscle strength on the left lower limb, lack

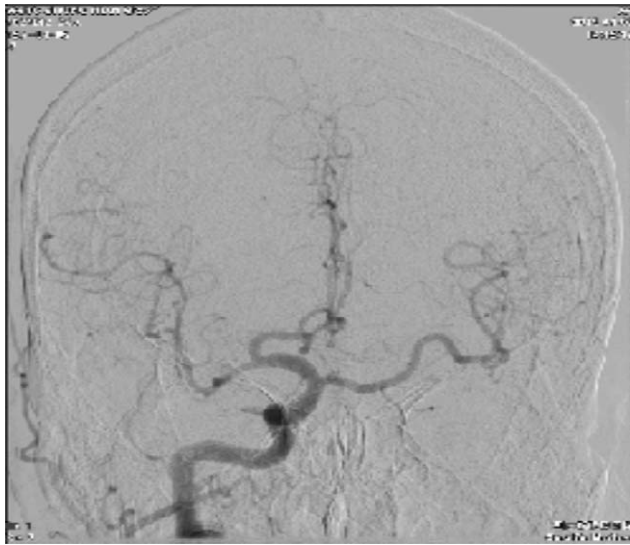

Figure 1. Right carotid artery angiography showed that the left middle cerebral artery originated from the right carotid artery segment of the right carotid artery. The anterior communicating artery was open and bilateral anterior cerebral arteries were visible.

of stability and accuracy in finger-to-nose test with left hand, unable to complete left heel-knee-tibia test, incomppliance in Romberg Sign test and no obvious abnormality in other neurologic tests. Neck vascular ultrasound showed bilateral carotid artery atherosclerosis. Craniocerebral enhanced magnetic resonance imaging (MRI) suggested pontine infarction (fresh focus) and formation of right posterior communicating aneurysm with thrombosis. The patient received cerebral angiography which suggested that the left middle cerebral artery originated from the ophthalmic artery segment of the right carotid artery, collateral patency of the anterior communicating artery, left ICA hypoplasia, poor morphology of the basilar artery and basilar artery aneurysm (Figs. 1–3). The diagnosis was:

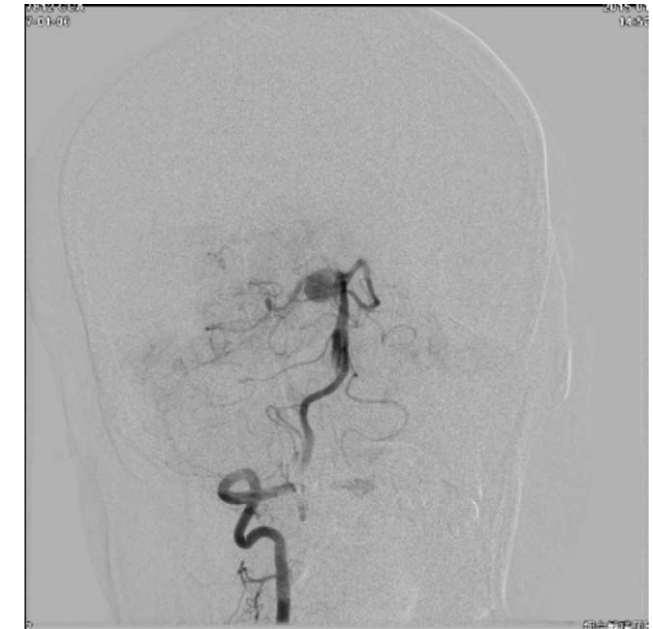

Figure 3. Right vertebroarteriography showed formation of aneurysm at the top of the basilar artery.

- (1) pontine infarction;
- (2) congenital hypoplasia of the left ICA;
- (3) basilar artery aneurysms.

The patient was treated with Clopidogrel against platelet aggregation, with Lipitor to regulate blood lipids and stabilize artery plaques, with Edaravone to remove oxygen free radicals, with Butyphthalide to protect brain mitochondria, and with Urinary Kallidinogenase to improve microcirculation. The patient's condition was improved and left hospital on January 27, 2015.

3. Discussion

3.1. Epidemiological characteristics and clinical manifestations

ICA is one of the most stable arteries in human body, whose hypoplasia is considered very rare. The frequency of CICAH is not very clear. Most cases were identified by ultrasonography, computed tomography (CT) or MRI. It has been reported that the annual incidence of CICAH was about 0.01%.^[2,7] CICAH usually occurs unilaterally. Bilateral CICAH has been reported but is even more rare.^[8] Interestingly, according to the study of Tran-Dinh et al, hypoplasia of the left ICA was more often observed, whose incidence was about 1.5 times that of the hypoplasia of the right ICA.^[11] The case in this report was also left ICA hypoplasia.

Most cases of CICAH can be completely asymptomatic as the patients' collateral circulation, such as the Willis' circle, is well developed.^[9] Lie et al first described the 6 types of compensations of ICA circulation in CICAH patients.^[10] Type A: in case of absence of unilateral ICA, the anterior communicating artery compensates to the ipsilateral anterior cerebral artery and the enlarged posterior communicating artery to the ipsilateral middle cerebral artery. Type B: the ipsilateral anterior cerebral artery and middle cerebral artery are supplied by the anterior communicat-

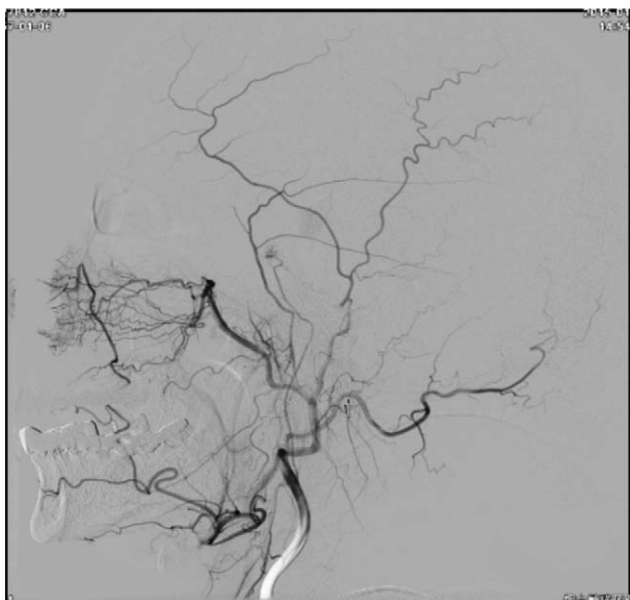

Figure 2. Left carotid artery angiography showed left internal carotid artery hypoplasia.

ing artery. Type C: in case of bilateral hypoplasia of ICA, the anterior circulation of ICA blood supply is compensated by the carotid-vertebrobasilar artery anastomosis of the basilar artery. Type D: in case of unilateral hypoplasia of ICA, blood is supplied to the ipsilateral carotid siphon from the cavernous sinus anastomosis. Type E: the small anterior cerebral artery is supplied by bilateral hypoplasia of ICA and the middle cerebral artery is supplied by an expanded posterior communicating artery. Type F: distal collateral circulation is provided through external carotid artery, internal maxillary artery and skull base anastomosis, that is, the microvascular network of the skull base. In this case, the patient's left middle cerebral artery originated from the right carotid artery segment of the carotid artery, and anterior communicating artery compensated to the left anterior cerebral artery, which was similar to the type D mentioned above. The patient was well compensated and did not have any clinical symptom before this onset.

However, there have been some abnormal symptoms reported to be related to CICAH. In general population, the incidence rate of cerebral vascular aneurism is about 2% to 4%, but Zink et al discovered that among the CICAH population the incidence rate of intracranial aneurysm was about 27.8%.^[11] The pathogeny of aneurysm is not yet understood, but some studies have suggested it might be related to internal carotid agenesis or hypoplasia. Patient with internal carotid hypoplasia is usually companied with other intracranial vascular variation, which increases the intravascular blood flow volume and velocity, causing hemodynamic changes, and thus increases the incidence of intracranial aneurysm. In this case, basilar artery aneurysm was identified by craniocerebral enhanced MRI and brain angiography, confirming that patients with CICAH are susceptible to intracranial aneurysms. For those aneurysm patients with CICAH, surgery or intravascular repair should be performed in time even without clinical symptoms to reduce abnormal hemodynamic pressure, the risk of hemangioma formation and mortality.

In addition, some CICAH patient can present as recurrent headache, blurred vision, recurrent transient ischemic attack, cranial nerve paralysis, paresis, and Horner's syndrome.^[12] However, there are some rare symptoms that have been reported to be related to CICAH, such as posterior fossa malformation, arterial lesions, PHACE Syndrome, Goldenhar syndrome, aortic coarctation, and Klippel-Feil syndrome.^[13-16]

CICAH is more often seen in children. It was suggested CICAH was associated with endocrinic dysplasia, such as hypopituitarism, growth hormone deficiency^[17-19] and congenital urinary dysfunction.^[18] Despite this, currently, there is no general or unified theory that links CICAH with these rare symptoms.

3.2. Imaging

The diagnosis of ICA hypoplasia is mainly based on imaging examination, which includes: magnetic resonance angiography (MRA), digital angiography (DSA), CT angiography (CTA) and skull base thin-layer CT scan. The terms of agenesis and hypoplasia are often used to describe the absence of ICA; however, there are some subtle differences among them. Agenesis refers to complete failure of the artery to develop, hypoplasia is when there is incomplete embryonic development.^[20] Agenesis can be differentiated from hypoplasia by establishing the complete absence of the carotid canal.^[21] This is because the carotid canal requires the presence of the ICA for its development. Therefore agenesis and hypoplasia of the carotid artery can be distinguished by CT examination of the skull base.

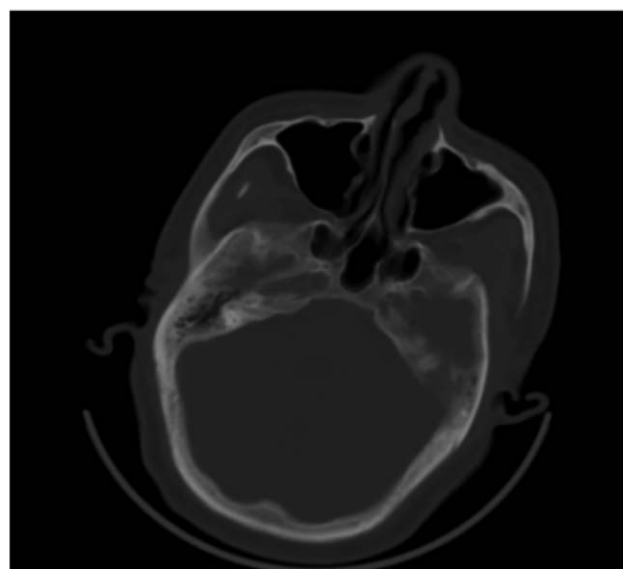


Figure 4. Left osseous carotid artery hypoplasia.

In case of CICAH small osseous carotid canal can be observed on skull base CT. In this report, the patient's skull base CT images showed hypoplasia of the left osseous carotid canal (Fig. 4).

3.3. Treatment

No guidelines currently exist pertaining to the management of CICAH. Given the asymptomatic and congenital nature of carotid agenesis, no treatment is necessary or possible to re-establish the ICA. However, with the high risk of aneurysm and cerebrovascular insufficiency, management of cerebrovascular risk is important. This includes monitoring of blood pressure and using of antihypertensive drugs, reasonable dietary management with close monitoring of cholesterol, consideration of the use of lipid-lowering agents and quitting smoking. Urgent radiological assessment is necessary for patients with suspicious neurological symptoms, including headache.

In summary, CICAH is a rare disease that is usually without clinical manifestations, or with non-specific clinical symptoms. As the incidence of intracranial aneurysm is much higher in CICAH patients than in general population, regular noninvasive imaging examination, such as MRA or CTA, is recommended for these patients to identify potential aneurysm or to take appropriate measures to reduce or avoid the occurrence of cerebrovascular events. Besides, head and neck surgery is a potential fatal risk for patients with CICAH, which should be well understood by surgeons and patients before making any surgical plans.

Author contributions

Authorship: CR and LN G provided technical and material support, helped design the study, drafted the manuscript, and obtained funding. DB H, YM, and QY J participated in patients' medical treatment, analyzed data and drafted the manuscript. HL W, HL Z, and WJ L processed imaging documents and information. CY L, ZW S, and BL provided statistical expertise as well as technical and material support. CY L revised the paper.

Funding acquisition: chao ren.

Project administration: Yu Mei, Yongqiang Ji, Hongliang Wu, Huilong Zhang, Zhongwen Sun, Wenjuan Li, Bing Li, chao ren, Lina Guan, Chuanyu Liu.

Writing – original draft: Dianbin Hou.

References

- [1] Tran-Dinh H, Jayasinghe LS, Merry GM. The absence of the internal carotid artery: report of two cases. *Aust N Z J Surg* 1986;56:85–8.
- [2] Midkiff RB, Boykin MW, McFarland DR, et al. Agenesis of the internal carotid artery with intercavernous anastomosis. *AJNR Am J Neuro-radiol* 1995;16:1356–9.
- [3] Clarós P, Bandos R, Gilea I, et al. Major congenital anomalies of the internal carotid artery: agenesis, aplasia and hypoplasia. *Int J Pediatr Otorhinolaryngol* 1999;49:69–76.
- [4] Keen JA. Absence of both internal carotid arteries. *Clin Proc* 1946; 4:588–94.
- [5] Tassano E, Jagannathan V, Drögemüller C, et al. Congenital aural atresia associated with agenesis of internal carotid artery in a girl with a FOXL3 deletion. *Am J Med Genet A* 2015;167A:537–44.
- [6] Johnson MD, Gentry LR, Rice GM, et al. A case of congenitally absent left internal carotid artery: vascular malformations in 22q11.2 deletion syndrome. *Cleft Palate Craniofac J* 2010;47:314–7.
- [7] Smith KR Jr, Nelson JS, Dooley JM Jr. Bilateral “hypoplasia” of the internal carotid arteries. *Neurology* 1968;18:1149–56.
- [8] Kim MS, Lee SJ, Lee CH, et al. Bilateral segmental absence of the internal carotid artery with rete compensation associated with absence of basilar artery: case report. *Surg Neurol* 2006;65:615–9.
- [9] Ryan FH, Kline LB, Gomez C. Congenital Horner’s syndrome resulting from agenesis of the internal carotid artery. *Ophthalmology* 2000; 107:185–8.
- [10] ALT, Hage J. Congenital anomalies of the carotid arteries. *Plastic and Reconstructive Surgery* 1968;42:283.
- [11] Zink WE, Komotar RJ, Meyers PM. Internal carotid aplasia/hypoplasia and intracranial saccular aneurysms: series of three new cases and systematic review of the literature. *J Neuroimaging* 2007;17:141–7.
- [12] Cohen JE, Gomori JM, Leker RR. Internal carotid artery agenesis: diagnosis, clinical spectrum, associated conditions and its importance in the era of stroke interventions. *Neurol Res* 2010;32:1027–32.
- [13] Weon YC, Chung JI, Kim HJ, et al. Agenesis of bilateral internal carotid arteries and posterior fossa abnormality in a patient with facial capillary hemangioma: presumed incomplete phenotypic expression of PHACE syndrome. *AJNR Am J Neuroradiol* 2005;26:2635–9.
- [14] Ottaviano G, Calzolari F, Martini A. Goldenhar syndrome in association with agenesis of the internal carotid artery. *Int J Pediatr Otorhinolaryngol* 2007;71:509–12.
- [15] Jaeger H, Mehring U, Gissler H, et al. Congenital absence of the internal carotid artery and the basilar artery with persistent trigeminal artery associated with coarctation of the aorta. *Eur Radiol* 2000; 10:1805–9.
- [16] Braga M, Pederzoli M, Beretta S, et al. Agenesis of the right internal carotid artery and Klippel-Feil syndrome: case report. *Spine (Phila Pa 1976)* 2009;34:E740–2.
- [17] Inamo Y, Harada K. Agenesis of the internal carotid artery and congenital pituitary hypoplasia: proposal of a cause of congenital hypopituitarism. *Eur J Pediatr* 2003;162:610–2.
- [18] Moon WJ, Porto L, Lanfermann H, et al. Agenesis of internal carotid artery associated with congenital anterior hypopituitarism. *Neuroradiology* 2002;44:138–42.
- [19] Stagi S, Traficante G, Lapi E, et al. Agenesis of internal carotid artery associated with isolated growth hormone deficiency: a case report and literature review. *BMC Endocr Disord* 2015;15:58.
- [20] Claros P, Bandos R, Gilea I, et al. Major congenital anomalies of the internal carotid artery: agenesis, aplasia and hypoplasia. *Int J Pediatr Otorhinolaryngol* 1999;49:69–76.
- [21] Teal JS, Naheedy MH, Hasso AN. Total agenesis of the internal carotid artery. *AJNR Am J Neuroradiol* 1980;1:435–42.