

# Treatment With Intrastromal and Intracameral Voriconazole in 2 Eyes With *Lasiodiplodia theobromae* Keratitis

## Case Reports

Kaevalin Lekhanont, MD, Manachai Nonpassopon, MD, Nutthida Nimvorapun, MD,  
and Pitak Santanirand, PhD

**Abstract:** To report the clinical presentation and the role of intrastromal and intracameral voriconazole injection in the management of rare cases of fungal keratitis caused by *Lasiodiplodia theobromae*.

Two eyes of 2 patients with *Lasiodiplodia* keratitis unresponsive to topical and oral antifungal medications were included in this study. Diagnosis of *Lasiodiplodia* keratitis was confirmed by microbiological analysis, including culture-based (case 1 and 2) and DNA sequencing techniques (case 2 only).

The first patient presented with multiple satellite lesions and one of these infiltrates spread deeply into the cornea, forming a stromal abscess. Another patient had a large full-thickness corneal infiltrates with several fungal balls in the anterior chamber, requiring a limbus-to-limbus therapeutic penetrating keratoplasty. Despite aggressive topical therapy, the stromal abscess continued to worsen in the first case and recurrent keratitis was observed postoperatively in the second case. Voriconazole 50 µg/0.1 mL was administered intracamerally and intrastromally around the fungal abscess as adjuncts to topical antimycotics in the first case. The second patient who needed therapeutic keratoplasty was treated with an intracameral injection of 50 µg/0.1 mL voriconazole at the end of surgery. Postoperatively, 100 µg/0.1 mL voriconazole was also injected intracamerally after the recurrence of infection was noted in the graft. Reinjections were given 48 hours apart in both cases. After the injections, all corneal and anterior chamber lesions were reduced in size and density and completely resolved within 4 weeks.

Intrastromal and intracameral voriconazole injections may offer safe and effective treatment options for *L theobromae* keratitis.

(*Medicine* 94(6):e541)

**Abbreviations:** BCVA = best-corrected visual acuity, IOP = intraocular pressure, KOH = potassium hydroxide, MIC = minimum inhibitory concentrations, PCR = polymerase chain reaction.

Editor: Mehmet Borazan.

Received: November 21, 2014; revised: January 15, 2015; accepted: January 17, 2015.

From the Department of Ophthalmology (KL, MN, NN); and Department of Pathology (PS), Ramathibodi Hospital, Mahidol University, Bangkok, Thailand.

Correspondence: Kaevalin Lekhanont, Department of Ophthalmology, Ramathibodi Hospital, Mahidol University, Rama VI Rd, Rajathevi, Bangkok 10400, Thailand (e-mail: lekhanont@yahoo.com).

This manuscript was presented as a poster at the 4th Asia Cornea Society Scientific Meeting, December 11–12, 2014, in Taipei, Taiwan.

The authors have no funding and conflicts of interest to disclose.

Copyright © 2015 Wolters Kluwer Health, Inc. All rights reserved.

This is an open access article distributed under the Creative Commons Attribution-NonCommercial-NoDerivatives License 4.0, where it is permissible to download, share and reproduce the work in any medium, provided it is properly cited. The work cannot be changed in any way or used commercially.

ISSN: 0025-7974

DOI: 10.1097/MD.0000000000000541

## INTRODUCTION

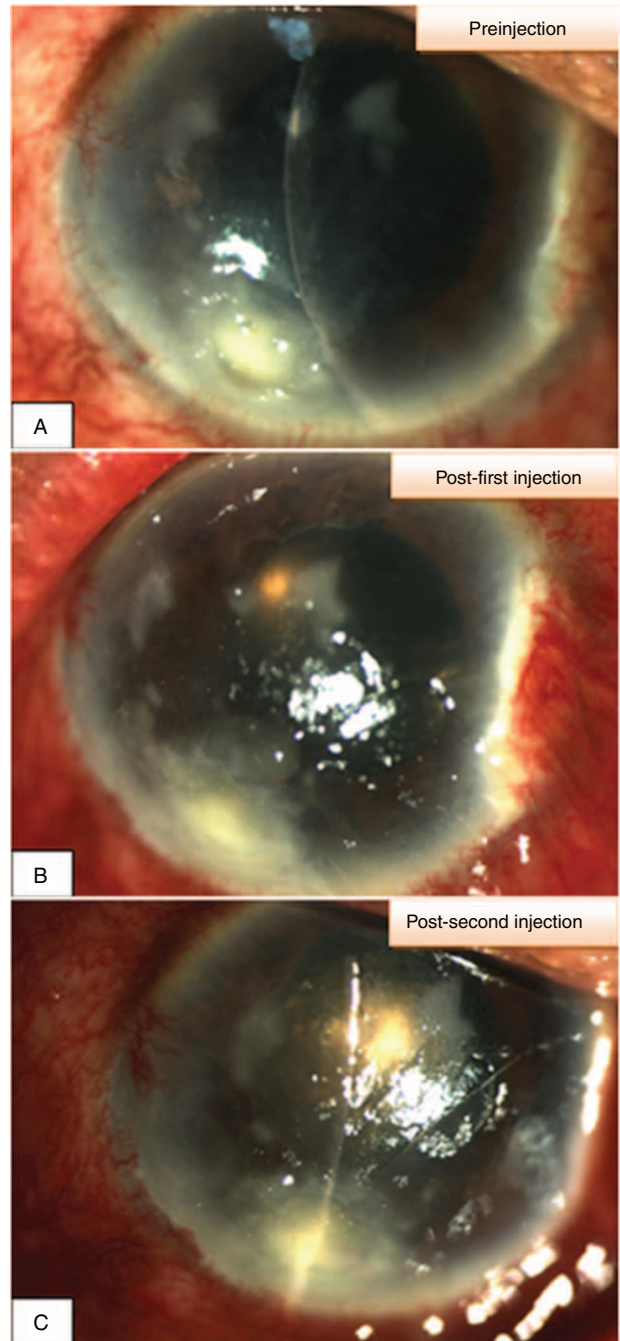
*Lasiodiplodia theobromae*, which is a filamentous fungus from the dematiaceous family, is the anamorph of *Botryosphaeria rhodina* and a member of the subphylum Pezizomycotina of Ascomycota.<sup>1</sup> It is a common plant pathogen in tropical and subtropical countries, causing rot in corn, yams, citrus, bananas, and other fruits.<sup>1</sup> Infections in human are extremely unusual and most frequently involve the eye, primarily the cornea. The first 2 *Lasiodiplodia* keratitis patients were identified in India in 1967.<sup>2</sup> Subsequently, reports from Columbia, the Philippines, Florida, other parts of India, Sri Lanka, and other countries have confirmed that this fungus is pathogenic in the human cornea.<sup>1,3–17</sup> Although *L theobromae* is responsible for 0.5% to 9% of keratomycoses in tropical countries,<sup>11,13,15</sup> it remains an exceptional etiology of fungal keratitis worldwide since only approximately 47 cases have been described in the literature.<sup>18</sup> Additionally, data on treatment options and outcomes are scarce and limited to case reports. Previous studies indicated variable responses to a number of conventional topical and systemic antifungal agents.<sup>1–5,12,16,18–20</sup> Surgical interventions were necessary in several patients.<sup>4–5,12,16,18,20</sup> Also, despite aggressive therapy, the keratitis occasionally progressed to endophthalmitis or panophthalmitis regardless of underlying conditions.<sup>7,12,16,20</sup> Recently, the newer generation triazoles, voriconazole, and posaconazole have been demonstrated to have significantly lower minimum inhibitory concentrations (MIC) against dematiaceous fungi than the older triazoles *in vitro*.<sup>21,22</sup> However, there has been only 1 study evaluating the use of voriconazole to manage a case of infectious keratitis caused by *L theobromae*, in which there was a lack of clinical response to topical voriconazole 1% given alone as first-line therapy, even though *in vitro* drug sensitivity testing showed a good voriconazole susceptibility profile for this organism.<sup>18</sup> Although voriconazole possesses excellent bioavailability and the therapeutic aqueous level can be achieved after topical administration,<sup>23</sup> there might be some difficulties in maintaining effective drug concentrations at the site of lesions.<sup>24</sup> Therefore, targeted drug delivery in the form of intrastromal and intracameral injection may have a role in treating keratomycosis.<sup>24–26</sup> Nonetheless, to the best of our knowledge, these routes of voriconazole therapy have not been previously employed for treatment of *Lasiodiplodia* keratitis. Herein, we report on the clinical presentation and response of 2 rare cases of *Lasiodiplodia* keratitis to a variety of antifungals including the off-label use of intrastromal and intracameral voriconazole. The study was approved by the ethics committee of Mahidol University School of Medicine and was conducted in accordance with the mandates set forth by the Declaration of Helsinki. Written informed consent was obtained from each individual prior to receiving treatments.

## CASE REPORTS

### Case 1

An 85-year-old Thai man presented with progressive pain, redness, tearing, photophobia, and decreased vision of 1-week duration in his right eye after an insect came in contact with the surface of his eye 3 weeks ago. He denied experiencing any other trauma to this eye or having any recent history of ocular infection or surgeries. His review of systems was negative other than the chief complaint. On initial clinical examination, the best-corrected visual acuity (BCVA) was hand motion in the right eye and 20/25 in the left eye. Slit-lamp examination of the right eye revealed conjunctival hyperemia, a peripheral 2- × 3-mm corneal epithelial defect with yellow-white full-thickness stromal infiltration, locating at 6 to 7 o'clock, 1-mm from limbus, multiple paracentral anterior 1/3 stromal infiltrates with feathery edges and satellite lesions, measuring 0.5 to 1.5 mm in diameter, and moderate anterior chamber reaction. There was evidence of brown pigmentation on the peripheral lesion. No corneal foreign body was seen. The left eye examination was normal.

Corneal scrapings were performed for standard microbiological investigations. Potassium hydroxide (KOH) wet mount showed septate broad brown hyphae. Following this, intensive topical treatment was started with 0.3% amphotericin B and 5% natamycin every hour. Itraconazole was given as 100 mg orally twice a day. Epithelial debridement was performed on all lesions with intact epithelium while the patient was on amphotericin B and natamycin eye drops. Five days later, the peripheral lesion became worse, forming a stromal abscess, and the new satellite lesions appeared near the old paracentral ones. A *Lasioidiplodia* species was isolated and subsequently identified by microscopic and morphological features as *L. theobromae* based on Sabouraud glucose neopeptone agar. Polymerase chain reaction (PCR)-based DNA sequencing technique was not used in this case owing to the unavailability of the equipment at that time. Natamycin was then replaced by topical voriconazole 1% eye drops (VFEND; Pfizer, New York, NY). Topical amphotericin B was continued along with topical voriconazole. Two weeks after admission, the superficial paracentral lesions noticeably improved and scarred over, but the peripheral ulcer and stromal abscess remained dense and enlarged, and endothelial plaque was noted (Figure 1A). Oral voriconazole was declined by the patient due to financial constraints. After informed consent was obtained, the patient received intrastromal injection of voriconazole (VFEND) (50 µg/0.1 mL) with a 30-g needle around the active peripheral lesion. The amount of drug injected intrastromally ranged from 0.075 to 0.1 mL. The 0.1 mL of voriconazole (50 µg/0.1 mL) was also administered intracamerally. Preparation and technique of intrastromal and intracameral voriconazole are described elsewhere.<sup>24–25,27</sup> Topical therapy was still continued. Two days postinjection, there was a significant reduction in the size and density of the infiltration. Both injections were repeated every 48 hours, depending on clinical response, until the disease was well controlled. A total of 6 double injections were performed because of slow resolution of the stromal abscess and endothelial plaque (Figure 1B and C). No intraoperative or postoperative complications were observed. The lesion much improved and topical antifungals were tapered off in frequency over the next 4 weeks. The infection resolved completely and his BCVA at 3 months after treatment was limited to 20/200 as a result of corneal scarring.



**FIGURE 1.** Slit-lamp photograph demonstrating superficial paracentral healed ulcers, active peripheral corneal ulcer measuring 2.4 × 3.2 mm, with dense stromal abscess, and endothelial plaque (A). A significant reduction in the size and density of the infiltration and stromal abscess is observed after the first and second injections of intrastromal and intracameral voriconazole respectively (B and C).

### Case 2

A 53-year-old Cambodian woman was referred to our department for a recalcitrant fungal keratitis. The patient reported having sustained injury to her right eye by a wooden particle 2 weeks prior to the onset of symptoms. She first went to

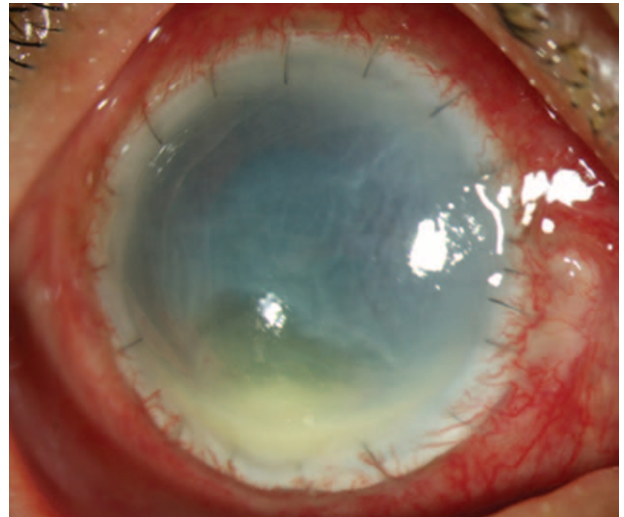
a private eye hospital where an infectious corneal ulcer was diagnosed and the initial microbiological workup was done. The corneal scraping revealed refractile hyphae with septate branching filaments on a 10% KOH smear preparation. The patient was prescribed topical 1% voriconazole and 0.3% amphotericin B hourly around the clock, and oral itraconazole 100 mg twice daily. Blurred vision with eye pain persisted and infection became aggressive despite eyedrop application. The patient was then referred to our department for further evaluation. At presentation, the BCVA of the affected eye was hand motion. Slit-lamp examination showed an extensive, dense, full-thickness infiltration of the cornea from limbus to limbus, a large corneal epithelial defect, and several fungal balls in the anterior chamber with nearly total hypopyon. Intraocular pressure (IOP) estimated with digital palpation was roughly 30 mm Hg. Because the ulcer was very severe and did not respond to treatment, the therapeutic keratoplasty was performed in a limbus-to-limbus fashion using a preserved donor cornea. As there was a shortage of donor corneas in Thailand, a fresh donor cornea was waited for a week and still not available, and the clinical signs rapidly worsened with resultant impending perforation of the cornea during waiting period. Thus, we decided to use the donor tissue for tectonic use for therapeutic keratoplasty. The graft size was  $11 \times 12$  mm. The scleral involvement was fortunately not noticed during surgery. The fungal balls and the fibrinoid membrane on the iris surface and the pupil area were carefully removed. Intracameral voriconazole injection ( $50 \mu\text{g}/0.1 \text{ mL}$ ) was also carried out at the end of surgery. The corneal button was sent for microbiological and histological examinations.

*L. theobromae* was identified based on cultures with Sabouraud glucose neopeptone agar, lactophenol cotton blue mount, and PCR-based DNA sequencing technique using the small subunit region (18S ribosomal DNA). The corneal tissue also revealed numerous, septate, highly bulged fungal filaments involving full corneal thickness in the corresponding histopathology specimens, confirming the diagnosis of *Lasiodiplodia* keratitis.

Postoperatively, hourly application of 1% voriconazole and 0.3% amphotericin B were continued for 1 week and then gradually tapered. The patient was not given any topical or oral corticosteroids following therapeutic keratoplasty. Three weeks after surgery, despite ongoing therapy with 1% voriconazole and 0.3% amphotericin every 2 hours, localized, deep stromal infiltrates in the inferior 1/4 of the corneal graft, endothelial plaques, and a 2-mm hypopyon developed (Figure 2), indicating a recurrent infection. At this point, the doses were increased to 1% voriconazole and 0.3% amphotericin B every hour and intracameral injections of  $100 \mu\text{g}/0.1 \text{ mL}$  voriconazole every other day were added to the regimen. The patient received totally 3 injections. Within 1 week, the hypopyon disappeared and a marked decrease in the size and intensity of the stromal infiltrate and endothelium plaque was appreciated with intense corneal vascularization. The infection finally resolved and her BCVA at 1 month after treatment was limited to counting fingers due to corneal graft edema.

## DISCUSSION

*L. theobromae* is an uncommon cause of infectious keratitis. Although one of the major causes of blindness in Thailand is corneal infection and the prevalence of fungal keratitis is high, no ocular infections caused by this organism have been reported in Thailand. *Lasiodiplodia* keratitis in our patients was



**FIGURE 2.** Slit-lamp photograph showing localized, deep stromal infiltrates in the inferior 1/4 of the corneal graft, endothelial plaques, and a 2-mm hypopyon, indicating a recurrent infection.

associated with agricultural trauma, which was similar to the predisposing factor of injury to the cornea by vegetable material in previous case reports.<sup>16,18</sup> The other specific risk factors, including contact lens wear, chronic ocular surface disease, prior use of topical corticosteroids, ocular surgery, or diabetes mellitus, were not observed in the patients. The clinical features and severity of our 2 patients were different, varying from small to large ulcer, superficial to deep stromal keratitis with corneal abscess, endothelial plaque, or anterior chamber involvement. These are possibly depending on the time interval between trauma and the onset of symptoms, the size of inoculum, and host resistance. The initial presentation of our patients was consistent with the typical features of fungal keratitis, though the onset and clinical course of the disease were not classically slow and relatively indolent. Conversely, *Lasiodiplodia* keratitis seemed to be acute, causing a very severe type of keratitis clinically, similar to the results of a prior report.<sup>28</sup> Additionally, despite being a dematiaceous fungus, clinical pigmentation was only noted in case 1. This was not surprising because a previous large study of dematiaceous keratitis in India found that the characteristic macroscopic pigmentation was seen in only 27% of cases in which pigmented fungi were isolated.<sup>14</sup> All our patients experienced unacceptable outcomes with topical contemporary antifungal agents. Case 1 failed combined topical amphotericin B, natamycin, and oral itraconazole therapy. The patient partially responded to topical voriconazole and amphotericin B eye drops, eventually resolving with a combination of intrastromal and intracameral voriconazole injections. Case 2 failed topical amphotericin B, voriconazole, and oral itraconazole, but was successfully treated with therapeutic penetrating keratoplasty, multiple intracameral voriconazole injections, and topical voriconazole and amphotericin B combination therapy.

Although favorable results have been reported in patients with *Lasiodiplodia* keratitis receiving topical amphotericin B and natamycin,<sup>5</sup> most of previous published studies revealed that therapy for keratitis due to this organism is often challenging.<sup>1,5,12,16,18</sup> Interindividual variations in drug response might be partly related to the virulence factors of this fungus, differences in the severity of initial presentation among patients, and

delay in making the correct diagnosis. Also, owing to the infrequent occurrence of this infection, only limited information concerning the *in vitro* antifungal susceptibility of *L. theobromae* is available. Natamycin, amphotericin B, and voriconazole exhibited good *in vitro* activity against this organism.<sup>1,18</sup> However, *L. theobromae* was resistant to miconazole, ketoconazole, itraconazole, econazole, and fluconazole *in vitro*.<sup>1,18</sup> Nevertheless, the validity of the methods used to derive these data, as well as the relevance of these data to the clinical use of natamycin, amphotericin B, and voriconazole which is given topically, is a controversial issue.<sup>1</sup> The relative *in vivo* resistance to natamycin, amphotericin B, and voriconazole in our patients particularly case 2 is comparable to the results of the previously reported cases and highlights the common lack of correspondence of *in vitro* and clinical sensitivity data for fungi.<sup>5,12,16,18</sup>

Similar to other mycotic keratitis involving deeper corneal layers, *Lasiodiplodia* keratitis appeared to be difficult to treat chiefly because of fungistatic activity, poor corneal penetration, and narrow spectrum of most traditional antifungal drugs. Voriconazole is a new-generation triazole that has demonstrated effectiveness against fungal keratitis caused by a broad range of fungal pathogens.<sup>23,29</sup> With topical administration, voriconazole showed excellent penetration through the cornea into the aqueous humor, without compromising intraocular safety.<sup>29</sup> Superficial keratitis that responded well to topical voriconazole in the first case suggests that voriconazole may overcome *Lasiodiplodia* keratitis. Nonetheless, maintaining sufficient local drug levels in cornea might not be achieved for the deep-seated lesions. Hence, alternate routes including intrastromal and intracameral injections of voriconazole were undertaken in order to have adequate drug concentration at the site of infection. Numerous studies have investigated the effect of targeted drug deliveries using intrastromal or intracameral injections of this potent drug and found that these less invasive surgical modalities were safe, very effective, and well tolerated, and proved to be significant in improving visual prognosis.<sup>24–27</sup> In our series, intrastromal and intracameral injections of 50 µg/0.1 mL voriconazole, and intracameral injections of 100 µg/0.1 mL voriconazole every 48 hours were shown to be efficient in eradicating *L. theobromae* with no adverse events during the follow-up period in case 1 and 2, respectively. We did not try intrastromal injection in case 2 since the cornea was totally infected and there was no normal clear cornea left.

The appropriate dosage and frequency of injection have yet to be determined. The schedules and doses of injections administered in this study were selected based on earlier studies.<sup>24–27</sup> Aqueous humor concentration of voriconazole have been reported to decline rapidly after topical or intracameral injection and elimination of voriconazole after intracameral injection exhibited an exponential decay with a half-life of 22 minutes in rabbit eyes.<sup>30</sup> Despite unknown pharmacodynamics of intrastromal voriconazole, these findings indicate that a sufficient level of voriconazole in the corneal stroma may not last long after injection. Leakage of drug from the stroma to the epithelial side could also reduce the amount of voriconazole after the injection.<sup>31</sup> Consequently, frequent supplementation of intrastromal and intracameral voriconazole may be required in clinical settings. Fortunately, drug elimination seemed to be slower in humans than in rabbits.<sup>30</sup> Elimination of voriconazole from serum has been reported to involve a half-life of 2.5 to 3 hours in rabbits, versus 6.5 hours in humans.<sup>32</sup> Moreover, voriconazole has a low MIC value of 1 µg/mL against *L. theobromae*.<sup>18</sup> Accordingly, the intracorneal or aqueous levels

might exceed the MIC of voriconazole to this organism for more than a few hours. This drug also shows non-concentration-dependent pharmacodynamic characteristics *in vitro*, suggesting that maximizing the exposure duration of a fungus to voriconazole would optimize the fungistatic activity of this medication.<sup>27,33</sup> Furthermore, topically administered voriconazole penetrates well into the anterior chamber through the cornea.<sup>34</sup> Although intrastromal and/or intracameral injections were used, topical voriconazole was not withdrawn in both cases. Therefore, the success in our patients who received injections simply every other day might be attributed to the effects of combined topical and intrastromal/intracameral application which prolonged the therapeutic levels of voriconazole in the corneal stroma and anterior chamber.

On the other hand, some studies found no significant benefit of adding intrastromal voriconazole to topical natamycin for treating refractory fungal keratitis.<sup>31,35</sup> However, in our study, intrastromal and intracameral voriconazole was injected in eyes that did not respond well to the combination of topical voriconazole and amphotericin B. Likewise, the other studies with positive and promising results used intrastromal voriconazole in patients failing to topical voriconazole and natamycin.<sup>24,25,36</sup> The previous negative outcome studies had different treatment conditions in their studies.<sup>31,35</sup> Hence, intrastromal/intracameral injection is probably a worthwhile endeavor for patients with deep mycotic keratitis that are unresponsive to topical antifungal agents before considering a larger more invasive surgery. In addition, the Mycotic Ulcer Treatment Trial Group demonstrated that topical natamycin was superior to topical voriconazole in filamentous keratitis and monotherapy with topical voriconazole could not be recommended for filamentous fungi keratitis, especially *Fusarium* cases.<sup>37,38</sup> These studies included some patients with *Lasiodiplodia* keratitis but did not evaluate subgroup analysis for these patients. To apply their findings to patients with *Lasiodiplodia* keratitis, a combination of topical natamycin and voriconazole could be attempted instead of combined topical amphotericin B and voriconazole.

As for the possible endothelial toxicity of intrastromal and intracameral voriconazole, there were no gross corneal toxicities or changes observed in our patients. Nevertheless, we did not perform any test to analyze morphology and functional integrity of the corneal endothelium. Conflicting views exist regarding the toxicity of voriconazole on corneal endothelial cells. Kernt and Kampik reported that concentrations up to 1000 µg/mL had no influence on human corneal endothelial cell, trabecular meshwork cell, or retinal pigmented epithelium cell proliferation, or on cell viability when administered for 24 hours.<sup>39</sup> Meanwhile, Han et al demonstrated that voriconazole might have a dose-dependent cytotoxic effect on cultured human corneal endothelium. Intracameral voriconazole concentrations of  $\geq 100$  µg/mL could increase the risk of corneal endothelial damage.<sup>40</sup> Nonetheless, the intracameral concentrations of  $\leq 50$  µg/mL were shown to be safe in most previous studies.<sup>40–42</sup> In a rabbit model, no evidence of microstructural damage was found after intracameral injection of concentrations of  $\leq 100$  µg/0.1 mL (0.1%).<sup>43</sup> The difference in types of cell culture, species: human versus animal, exposure time, and environments may, at least in part, account for the different results. Moreover, the results of *in vitro* experiments cannot be directly translated into *in vivo* situations for several reasons.<sup>40</sup> Through many passages, the phenotypic properties of the cultivated human corneal endothelial cells and their sensitivity to toxic agents can change.<sup>40</sup> Natural mechanisms in the

anterior chamber protect the corneal endothelium.<sup>40,43</sup> Because of metabolism in the intracameral space, the voriconazole concentration conceivably decreases gradually; thus, exposure to sustained high drug concentrations for hours is unlikely in vivo conditions.<sup>40</sup> Therefore, the safe concentration in human anterior chamber may be higher than 50 µg/mL. Intracameral voriconazole injection with the dose of 100 µg/0.1 mL in fungal keratitis patients was shown to be effective and did not induce any significant alteration in human cornea.<sup>27</sup> Also, voriconazole was injected safely into the intrastromal layer at a concentration of 50 µg/0.1 mL without obvious evidence of corneal damage.<sup>24–25,44</sup> These support the assumption safety margin of voriconazole could be greater than 50 µg/mL due to the protection mechanisms and drug metabolism.<sup>43</sup> However, in cases of deep fungal keratitis, the corneal endothelium would possibly be damaged by fungi and more vulnerable to toxicity caused by voriconazole than normal endothelium, particularly in the elderly, corneal transplant patients, patients with preexisting endothelial disease or compromised endothelium. Lower doses than those expected to be safe for normal cornea might be needed in such cases.

In summary, *Lasiodiplodia* keratitis could present as superficial keratitis, deep keratitis, corneal abscess, endothelial plaque, and fungal balls, and could be associated with hypopyon. Voriconazole appears to have good efficacy in vivo against *L. theobromae*. Nevertheless, to ensure the optimal drug level for deep keratomycosis, delivery of voriconazole directly to the site of action might be necessary to increase the drug concentration above minimal inhibitory concentration of the organism. Thus, intrastromal and intracameral voriconazole may be advised as a therapeutic adjunctive for the management of deep recalcitrant *Lasiodiplodia* keratitis in combination with topical treatment. Therapeutic keratoplasty is still beneficial in large severe cases.

## REFERENCES

1. Thomas PA. Current perspectives on ophthalmic mycoses. *Clin Microbiol Rev*. 2003;16:730–797.
2. Puttanna ST. Mycotic infections of the cornea. *J All India Ophthalmol Soc*. 1967;15:11–18.
3. Laverde S, Moncada LH, Restrepo A, et al. Mycotic keratitis; 5 cases caused by unusual fungi. *Sabouraudia*. 1973;11:119–123.
4. Valenton MJ, Rinaldi MG, Butler EE. A corneal abscess due to the fungus *Botryodiplodia theobromae*. *Can J Ophthalmol*. 1975;10:416–418.
5. Rebell G, Forster RK. *Lasiodiplodia theobromae* as a cause of keratomycoses. *Sabouraudia*. 1976;14:155–170.
6. Liesegang TJ, Forster RK. Spectrum of microbial keratitis in South Florida. *Am J Ophthalmol*. 1980;90:38–47.
7. Slomovic AR, Forster RK, Gelender H. *Lasiodiplodia theobromae* panophthalmitis. *Can J Ophthalmol*. 1985;20:225–228.
8. Gonawardena SA, Ranasinghe KP, Arsecularatne SN, et al. Survey of mycotic and bacterial keratitis in Sri Lanka. *Mycopathologia*. 1994;127:77–81.
9. Rosa RH Jr, Miller D, Alfonso EC. The changing spectrum of fungal keratitis in south Florida. *Ophthalmology*. 1994;101:1005–1013.
10. Dunlop AA, Wright ED, Howlader SA, et al. Suppurative corneal ulceration in Bangladesh: A study of 142 cases examining the microbiological diagnosis, clinical and epidemiological features of bacterial and fungal keratitis. *Aust N Z J Ophthalmol*. 1994;22:105–110.
11. Hagan M, Wright E, Newman M, et al. Causes of suppurative keratitis in Ghana. *Br J Ophthalmol*. 1995;79:1024–1028.
12. Borderie VM, Bourcier TM, Poirot JL, et al. Endophthalmitis after *Lasiodiplodia theobromae* corneal abscess. *Graefes Arch Clin Exp Ophthalmol*. 1997;235:259–261.
13. Srinivasan M, Gonzales CA, George C, et al. Epidemiology and aetiological diagnosis of corneal ulceration in Madurai, south India. *Br J Ophthalmol*. 1997;81:965–971.
14. Garg P, Gopinathan U, Choudhary K, et al. Keratomycosis: clinical and microbiologic experience with dematiaceous fungi. *Ophthalmology*. 2000;107:574–580.
15. Gopinathan U, Garg P, Fernandes M, et al. The epidemiological features and laboratory results of fungal keratitis: a 10-year review at a referral eye care center in South India. *Cornea*. 2002;21:555–559.
16. Donnio A, Desbois N, Boiron P, et al. Mycotic keratitis and endophthalmitis caused by unusual fungi: *Lasiodiplodia theobromae*. *J Fr Ophthalmol*. 2006;29:e4.
17. Thew MR, Todd B. Fungal keratitis in far north Queensland, Australia. *Clin Experiment Ophthalmol*. 2008;36:721–724.
18. Saha S, Sengupta J, Banerjee D, et al. *Lasiodiplodia theobromae* keratitis: a case report and review of literature. *Mycopathologia*. 2012;174:335–339.
19. Ishibashi Y, Matsumoto Y. Intravenous miconazole in the treatment of keratomycosis. *Am J Ophthalmol*. 1984;97:646–647.
20. Pflugfelder SC, Flynn HW Jr, Zwickey TA, et al. Exogenous fungal endophthalmitis. *Ophthalmology*. 1988;95:19–30.
21. Cuenca-Estrella M, Gomez-Lopez A, Mellado E, et al. Head-to-head comparison of the activities of currently available antifungal agents against 3,378 Spanish clinical isolates of yeasts and filamentous fungi. *Antimicrob Agents Chemother*. 2006;50:917–921.
22. Sabatelli F, Patel R, Mann PA, et al. In vitro activities of posaconazole, fluconazole, itraconazole, voriconazole, and amphotericin B against a large collection of clinically important molds and yeasts. *Antimicrob Agents Chemother*. 2006;50:2009–2015.
23. Hariprasad SM, Mieler WF, Lin TK, et al. Voriconazole in the treatment of fungal eye infections: a review of current literature. *Br J Ophthalmol*. 2008;92:871–878.
24. Prakash G, Sharma N, Goel M, et al. Evaluation of intrastromal injection of voriconazole as a therapeutic adjunctive for the management of deep recalcitrant fungal keratitis. *Am J Ophthalmol*. 2008;146:56–59.
25. Sharma N, Agarwal P, Sinha R, et al. Evaluation of intrastromal voriconazole injection in recalcitrant deep fungal keratitis: case series. *Br J Ophthalmol*. 2011;95:1735–1737.
26. Mittal V, Mittal R. Intracameral and topical voriconazole for fungal corneal endoexudates. *Cornea*. 2012;31:366–370.
27. Shen YC, Wang CY, Tsai HY, et al. Intracameral voriconazole injection in the treatment of fungal endophthalmitis resulting from keratitis. *Am J Ophthalmol*. 2010;149:916–921.
28. Thomas PA, Kalavathy CM, Devanandan P. *Lasiodiplodia theobromae* keratitis—a clinical profile. *J Tamilnadu Ophthalmol Assoc*. 1998;39:31–32.
29. Al-Badriyeh D, Neoh CF, Stewart K, et al. Clinical utility of voriconazole eye drops in ophthalmic fungal keratitis. *Clin Ophthalmol*. 2010;4:391–405.
30. Shen YC, Wang MY, Wang CY, et al. Pharmacokinetics of intracameral voriconazole injection. *Antimicrob Agents Chemother*. 2009;53:2156–2157.
31. Niki M, Eguchi H, Hayashi Y, et al. Ineffectiveness of intrastromal voriconazole for filamentous fungal keratitis. *Clin Ophthalmol*. 2014;8:1075–1079.

32. Purkins L, Wood N, Greenhalgh K, et al. The pharmacokinetics and safety of intravenous voriconazole—a novel wide-spectrum antifungal agent. *Br J Clin Pharmacol*. 2003;56(Suppl 1):2–9.
33. Klepser ME, Malone D, Lewis RE, et al. Evaluation of voriconazole pharmacodynamics using time-kill methodology. *Antimicrob Agents Chemother*. 2000;44:1917–1920.
34. Vemulakonda GA, Hariprasad SM, Mieler WF, et al. Aqueous and vitreous concentrations following topical administration of 1% voriconazole in humans. *Arch Ophthalmol*. 2008;126:18–22.
35. Sharma N, Chacko J, Velpandian T, et al. Comparative evaluation of topical versus intrastromal voriconazole as an adjunct to natamycin in recalcitrant fungal keratitis. *Ophthalmology*. 2013;120:677–681.
36. Kalaiselvi G, Narayana S, Krishnan T, et al. Intrastromal voriconazole for deep recalcitrant fungal keratitis: a case series. *Br J Ophthalmol*. 2015;99:195–198.
37. Sun CQ, Lalitha P, Prajna NV, et al. Association between in vitro susceptibility to natamycin and voriconazole and clinical outcomes in fungal keratitis. *Ophthalmology*. 2014;121:1495–1500.
38. Prajna NV, Krishnan T, Mascarenhas J, et al. The mycotic ulcer treatment trial: a randomized trial comparing natamycin vs voriconazole. *JAMA Ophthalmol*. 2013;131:422–429.
39. Kernt M, Kampik A. Intracameral voriconazole: in vitro safety for human ocular cells. *Toxicology*. 2009;258:84–93.
40. Han SB, Shin YJ, Hyon JY, et al. Cytotoxicity of voriconazole on cultured human corneal endothelial cells. *Antimicrob Agents Chemother*. 2011;55:4519–4523.
41. Lin RC, Sanduja N, Hariprasad SM. Successful treatment of postoperative fungal endophthalmitis using intravitreal and intracameral voriconazole. *J Ocul Pharmacol Ther*. 2008;24:245–248.
42. Reis A, Sundmacher R, Tinteln K, et al. Successful treatment of ocular invasive mould infection (fusariosis) with the new antifungal agent voriconazole. *Br J Ophthalmol*. 2000;84:932–933.
43. Han SB, Yang HK, Hyon JY, et al. Toxicity of voriconazole on corneal endothelial cells in an animal model. *Br J Ophthalmol*. 2012;96:905–908.
44. Park CH, Lee HS, Chung SK. Toxicity of intrastromal voriconazole injection on corneal endothelium in rabbits. *Cornea*. 2014;33:928–934.