



CASE REPORT

Early inappropriate shock in a subcutaneous cardiac defibrillator due to subcutaneous air

Ryo Nishinarita MD  | Jun Kishihara MD, PhD | Gen Matsuura MD | Yuki Arakawa MD |
 Shuhei Kobayashi MD | Yuki Shirakawa MD | Ai Horiguchi MD |
 Hironori Nakamura MD, PhD | Naruya Ishizue MD, PhD | Jun Oikawa MD, PhD |
 Hidehira Fukaya MD, PhD  | Shinichi Niwano MD, PhD | Junya Ako MD, PhD

Department of Cardiovascular Medicine,
 Kitasato University School of Medicine,
 Sagami-hara, Japan

Correspondence

Jun Kishihara, MD, Department of
 Cardiovascular Medicine, Kitasato
 University School of Medicine, 1-15-1
 Kitasato, Minami-ku, Sagami-hara 252-0374,
 Japan.
 Email: j_kishihara@med.kitasato-u.ac.jp

Abstract

A 57-year-old man was admitted to our hospital due to syncopal attack. He was diagnosed with Brugada syndrome due to which a subcutaneous implantable cardiac defibrillator (S-ICD) was inserted using the standard technique. Two hours after the implantation, he experienced inappropriate shock while conscious. Device interrogation revealed a contentious baseline shift and frequent oversensing of low-amplitude signals, which was followed by a shock. Lateral chest X-ray revealed subcutaneous air surrounding the proximal electrode. Another inappropriate shock could be avoided by changing the sensing vector. The subcutaneous air was completely resolved 7 days after implantation.

KEYWORDS

inappropriate shock, subcutaneous air, subcutaneous defibrillator, sudden cardiac death, X-ray

1 | INTRODUCTION

Subcutaneous implantable cardiac defibrillators (S-ICDs) have been reported to exhibit an increasingly important role in the primary and secondary prevention of sudden cardiac death. S-ICDs use an approach to sensing different from that used by conventional transvenous implantable cardiac defibrillators (TV-ICDs). This may cause new sensing issues despite S-ICD usage being a new sensing methodology that incorporates a high-pass filter (SMART Pass), which has reportedly reduced inappropriate shocks due to T-wave oversensing.¹ Here we report a case of inappropriate shock in a patient with a S-ICD because of new, specific sensing issues.

2 | CASE REPORT

A 57-year-old man was admitted to our hospital due to syncopal attack. Electrocardiography revealed coved-type ST segment elevation in lead V1. He had a family history of sudden cardiac death, and ventricular fibrillation was induced by an electrophysiological study. He was diagnosed with Brugada syndrome, and a S-ICD (Boston Scientific; A219 EMBLEM MRI S-ICD, MA, USA) was implanted for the primary prevention of sudden cardiac death. S-ICD surface electrocardiogram screening was performed, and all three leads observed were eligible.

The standard three-incision technique was performed. A left lateral pocket was created for the generator; further, two small

This is an open access article under the terms of the Creative Commons Attribution-NonCommercial License, which permits use, distribution and reproduction in any medium, provided the original work is properly cited and is not used for commercial purposes.

© 2019 The Authors. *Journal of Arrhythmia* published by John Wiley & Sons Australia, Ltd on behalf of the Japanese Heart Rhythm Society.

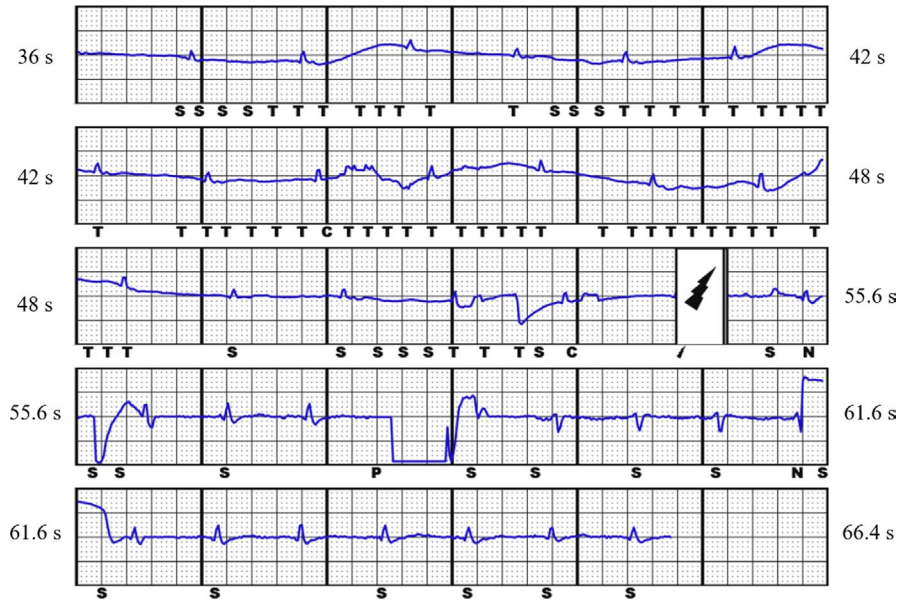


FIGURE 1 Subcutaneous electrocardiogram at the time of inappropriate shock reveals a continuous baseline shift and frequent oversensing of low-amplitude signals, followed by a shock in the primary vector

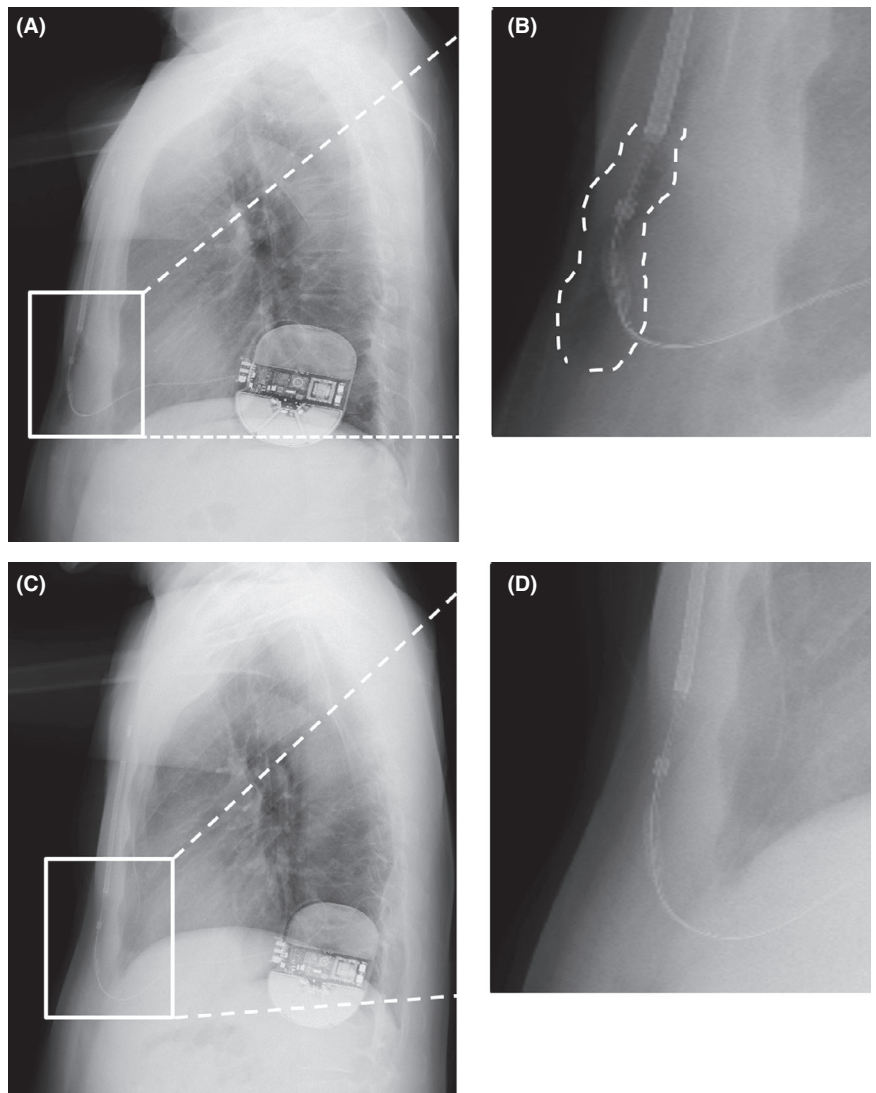


FIGURE 2 Lateral chest X-rays at days 0 (A, B) and 7 (C, D) after implantation. The presence of radiolucent contaminated subcutaneous air surrounding the proximal sensing electrode can be seen (dotted line). The contaminated subcutaneous air was completely resolved 7 d after implantation

incisions were made in the left parasternal area to secure the distal and proximal sensing electrodes of the lead, which had been subcutaneously tunneled. After coils and generators were placed, the air in the subcutaneous tunnels, pockets, and tissues were eliminated by injecting normal saline and performing skin massaging prior to closing the incisions. Ventricular fibrillation was induced and detected in the primary vector, which includes the proximal sensing electrode and the generator. Sinus rhythm was effectively restored via a submaximal 65-J shock. Right after implantation, the device and lead placement were confirmed via a PA chest X-ray.

Two hours after implantation, the patient received an inappropriate shock while conscious. Device interrogation revealed a continuous baseline shift and frequent oversensing of low-amplitude signals, followed by shock in the primary vector (Figure 1). Lateral chest X-ray revealed contaminated subcutaneous air surrounding the proximal electrode (Figure 2A,B). Oversensing of the low-amplitude signals and artifact, which was presumably caused by the contaminated subcutaneous air, was diagnosed. The device was reprogrammed to sense at the secondary vector, and another inappropriate shock could be avoided. The subcutaneous air was completely resolved 7 days after implantation (Figure 2C,D).

3 | DISCUSSION

S-ICDs are a suitable alternative to the conventional TV-ICDs. S-ICDs avoid intravascular lead failures and minimize the operative complications. Several studies have demonstrated the feasibility and safety of S-ICDs in detecting and terminating life threatening ventricular arrhythmias.² S-ICDs are mostly safe and effective; however, the main cause of S-ICD-associated morbidity is inappropriate shock, which is mostly caused by cardiac oversensing, particularly due to T-wave oversensing (TWOS) and low-amplitude signals.³ The rate of inappropriate shocks due to cardiac oversensing is reported as 5.2% to 8.1% on a per-patient basis at the 11 to 12-month follow-up.¹ An initial update in the morphology-based sensing algorithm in S-ICDs reduced inappropriate charges due to TWOS by 40%. Furthermore, a new high-pass filter [SMART Pass (SP), Boston Scientific Corporation, Natick, MA] available within the S-ICD system results in a significant reduction of inappropriate shocks due to cardiac oversensing without a negative effect on appropriate shocks.¹ Despite this morphology-based sensing algorithm and SP filter, inappropriate shocks by cardiac sensing of low-amplitude signals cannot be eliminated. Because the minimum sensibility of S-ICD is 0.08 mV, which is much lower than that of the TV-ICD, S-ICD are prone to oversensing due to their low-amplitude signal compared to TV-ICD.

The present case report describes a case of inappropriate shock caused by S-ICD because of the presence of subcutaneous air. Subcutaneous air insulates the sensing contact ring from surrounding tissues and intermittent lack of contact between ring and tissues, causing inadequate sensing and low-amplitude signals, and thus oversensing from autogain. Good tissue contact with the electrode and pulse generator is important to optimize sensing and therapy delivery.

The following features of inappropriate shock are noteworthy. First, inappropriate shocks often occur within a few hours to a few days after S-ICD implantation. Second, an abrupt baseline shift and low-amplitude signals are observed in the device electrogram just before inappropriate shocks. Third, the air around the sensing electrode, which often disappears in approximately a week, can be observed via lateral chest X-ray. Finally, the sensing failure can be avoided by changing the sensing vector, thereby providing a strategy for excluding the problematic electrode.

In the present case, inappropriate shocks occurred despite keeping the tissue moist via flushing with sterile saline, massaging the skin along the tract, and releasing any residual subcutaneous air out through the incisions prior to closing. Although the incidence of inappropriate shock is relatively rare in the early postimplantation, subcutaneous air is one of the remarkable factors in this period.⁴ Therefore, lateral chest X-ray should be considered right after implantation.

ACKNOWLEDGEMENTS

We sincerely thank the members of the Department of Cardiovascular Medicine, Kitasato University School of Medicine.

CONFLICT OF INTEREST

Authors declare no conflict of interests for this article.

ORCID

Ryo Nishinarita  <https://orcid.org/0000-0003-0329-5476>

Hidehira Fukaya  <https://orcid.org/0000-0002-7588-554X>

REFERENCES

1. Theuns DAMJ, Brouwer TF, Jones PW, Allavattam V, Donnelley S, Auricchio A, et al. Prospective blinded evaluation of a novel sensing methodology designed to reduce inappropriate shocks by the subcutaneous implantable cardioverter-defibrillator. *Heart Rhythm*. 2018;15:1515–22.
2. Burke MC, Gold MR, Knight BP, Barr CS, Theuns DA, Boersma LV, et al. Safety and efficacy of the totally subcutaneous implantable defibrillator. *J Am Coll Cardiol*. 2015;65:1605–15.
3. Olde Nordkamp LR, Brouwer TF, Barr C, Theuns DA, Boersma LV, Johansen JB, et al. Inappropriate shocks in the subcutaneous ICD: incidence, predictors and management. *Int J Cardiol*. 2015;195:126–33.
4. Chinitz JS, Nadraus PA, Darge AL, Cacciabauda JE, Altman EJ. Inappropriate shocks within 24 hours after implantation of a subcutaneous defibrillator with a two-incision technique. *J Innov Cardiac Rhythm Management*. 2016;7:2295–8.

How to cite this article: Nishinarita R, Kishihara J, Matsuura G, et al. Early inappropriate shock in a subcutaneous cardiac defibrillator due to subcutaneous air. *J Arrhythmia*. 2019;35:682–684. <https://doi.org/10.1002/joa3.12210>