

# Microwire navigation and microcatheter positioning by balloon manipulation for the treatment of intracranial aneurysms: A pilot study

Ali Burak Binboga, Mehmet Onay, Cetin Murat Altay

Department of Radiology, Dr. Ersin Arslan Training and Research Hospital, Eyüpoğlu Mahallesi, Hürriyet Cd. No: 40, Şahinbey/Gaziantep, Turkey

**Correspondence:** Dr. Mehmet Onay, Eyüpoğlu Mahallesi, Hürriyet Cd. No: 40, Şahinbey/Gaziantep - 27010, Turkey.  
E-mail: mehmetonay079@hotmail.com

## Abstract

**Background and Objective:** An intracranial aneurysm (IA) is a life-threatening condition and endovascular treatment (EVT) is a demanding procedure, especially in IAs with an unfavorable anatomy. The aim of this study was to investigate the safety and efficacy of balloon-assisted microwire navigation and microcatheter positioning in the EVT of IAs with challenging anatomies. **Materials and Methods:** This retrospective study included patients that underwent balloon-assisted microwire navigation and microcatheter positioning in the EVT of IAs between September 2016 and January 2019. All EVT procedures and data collection were performed by the same two neurointerventional radiologists. Technical success and complication rates, safety, and efficiency of the balloon manipulation method were evaluated. Statistical software was used to analyze the basic descriptive data of the patients and aneurysms. **Results:** This study included 14 patients. The microwire navigation of the target artery with balloon manipulation was used in 4 aneurysms of 4 patients. Microcatheter positioning with balloon manipulation was used in 10 aneurysms of 10 patients. There was no complication caused by the balloon manipulation technique. The technical success rate was 100%. **Conclusion:** In the EVT of IAs with challenging anatomies, the presented technique is a safe and effective option without additional complications, especially in the target artery with an acute angle and in small aneurysms.

**Key words:** Endovascular treatment; intracranial aneurysm; microcatheter positioning; microwire navigation

## Introduction

The incidence of saccular intracranial aneurysms (IAs) varies according to age, sex, ethnicity, and co-morbidities, and their overall prevalence has been reported up to 3.2%.<sup>[1]</sup> IAs can exist in the anterior or posterior cerebral circulation, with the most common site being the middle cerebral artery (MCA), and a less common site being the posterior communicating

artery (Pcom).<sup>[2]</sup> A few decades ago, the surgical clipping of IAs was the primary treatment option, whereas currently, there is an increasing tendency to adopt endovascular strategies in the treatment of both ruptured and unruptured IAs.<sup>[3]</sup> However, there are still some technical difficulties in

This is an open access journal, and articles are distributed under the terms of the Creative Commons Attribution-NonCommercial-ShareAlike 4.0 License, which allows others to remix, tweak, and build upon the work non-commercially, as long as appropriate credit is given and the new creations are licensed under the identical terms.

**For reprints contact:** WKHLRPMedknow\_reprints@wolterskluwer.com

**Cite this article as:** Binboga AB, Onay M, Altay CM. Microwire navigation and microcatheter positioning by balloon manipulation for the treatment of intracranial aneurysms: A pilot study. Indian J Radiol Imaging 2020;30:453-8.

**Received:** 03-Dec-2019

**Revised:** 13-Sep-2020

**Accepted:** 15-Oct-2020

**Published:** 13-Jan-2021

### Access this article online

#### Quick Response Code:



**Website:**  
www.ijri.org

**DOI:**  
10.4103/ijri.IJRI\_482\_19

the endovascular treatment (EVT) of IAs. These technical difficulties are caused by patient- and aneurysm-related factors. Common patient-related technical difficulties include anatomic variations in the aortic arch, stenosis or serious tortuosity of the internal carotid artery (ICA) and vertebral artery that can prevent the advancement of the guiding catheter.<sup>[4-6]</sup> Complex morphological aneurysm features (shape, localization, neck angle, and width) and aneurysm branches located adjacent to the aneurysm neck are considered aneurysm-related technical difficulties. Target artery navigation or microcatheter positioning can be challenging in the EVT of complex IAs, with increased complication rates.<sup>[7,8]</sup> Another important aneurysm-related factor that increases the complication rate is a small aneurysm size.<sup>[9]</sup> Despite these technical difficulties, stent-assisted coil embolization (SACE) and balloon-assisted coil embolization (BACE) are successfully performed to treat IAs.<sup>[10]</sup> In addition, new approaches are being reported to overcome the technical difficulties associated with aneurysm-related factors.

The aim of this study was to investigate the safety and efficacy of balloon-assisted microwire navigation and microcatheter positioning in the EVT of IAs with challenging anatomies.

## Materials and Methods

This manuscript was approved by the local ethics committee/IRB. (Ref 2019/334 on 23/10/2019).

### Patients and aneurysms

Between September 2016 and January 2019, 88 patients with cerebral aneurysms diagnosed by computed tomography (CT) angiography, magnetic resonance (MR) angiography, or digital subtraction angiography (DSA) were analyzed. DSA was performed to determine the features of the aneurysm. The treatment options (open surgery, EVT, or follow-up observation) for all patients were determined by the local neurovascular committee of our hospital, including a neurointerventional radiologist, neurosurgeon, and neurologist. The risks of both treatment options were discussed, and recommendations were given to all patients. Only one of the 88 patients opted for open surgery. Three patients with acute subarachnoid hemorrhage (SAH) and parenchymal hematoma underwent open surgery to evacuate the parenchymal hematoma. One patient with an aneurysm located in the projected MCA bifurcation underwent open surgery. As a result, the decision for open surgery was made by the neurointerventional treatment committee for 5 patients. A total of 94 aneurysms in 83 patients were treated using an endovascular approach. The DSA (including 3D) images of the 94 aneurysms of these 83 patients were analyzed at the workstation by two interventional neuroradiologists involved in the study. The exclusion criteria were as follows: 1) endovascular

treatment without a balloon (simple coiling and flow diversion device, FDD) (27 aneurysms in 25 patients); 2) BACE; and 3) treatment with a balloon for configuring the stent, protecting branches arising from the aneurysm neck, and preventing the coil from prolapsing into the parent artery (53 aneurysms in 44 patients). As a result, this retrospective study included 14 aneurysms of 14 patients treated with balloon-assisted microwire navigation and microcatheter positioning.

### Technical details

#### *Endovascular procedure*

All procedures were performed under general anesthesia, including invasive arterial pressure monitoring. A bolus dose of 5000 IU of heparin was utilized to achieve systemic anticoagulation at the time of groin insertion. A heparin infusion was started to maintain the activated clotting time >2 times the baseline value. In elective cases, 300 mg of aspirin and 75 mg of clopidogrel were used for at least 5 days before the procedure. Diluted clopidogrel (600 mg) was given through the patient's nasogastric tube if stenting was required. A distal access guiding catheter (Fargomax, Balt, Montmorency, France) was placed ipsilaterally into the cervical segment of the target artery. The microcatheter (VASCO 10, Balt, Montmorency, France) and the hypercompliant balloon (Eclipse 2L, Balt, Montmorency, France) were advanced through the guiding catheter.

#### *The microwire navigation problem*

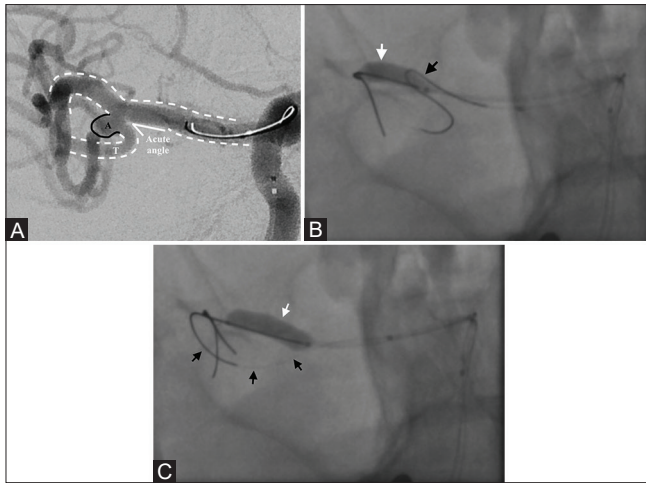
The microwire was advanced under the assistance of road map images. Despite trying multiple manipulations with multiple wires, target artery navigation could not be achieved due to the acute angle of the target artery and herniation of the microwire into a nontarget artery (due to insufficient shoulder support) [Figure 1A]. No over-manipulation was performed to avoid complications that could lead to dissection, thrombosis, and rupture.

#### *Technique for solving the guidewire navigation problem*

The microwire, which was herniated into a nontarget artery, was retracted until flattened. A hypercompliant balloon was placed in the nontarget artery close to the aneurysm neck [Figure 1B] and inflated at a nominal volume to create a wall effect. Then, the microwire was advanced toward the aneurysm neck. The microwire navigation of the acute-angle target artery was achieved safely and effectively using balloon manipulation without microwire herniation [Figure 1C]. The hypercompliant balloon was deflated.

#### *The microcatheter positioning problem*

The microcatheter was advanced over the wire into the small aneurysm sac after reaching the aneurysm sac with the microwire. However, the distal tip of the microcatheter could become stuck at the distal corner of the aneurysm neck, without a suitable position for coiling [Figure 2A].

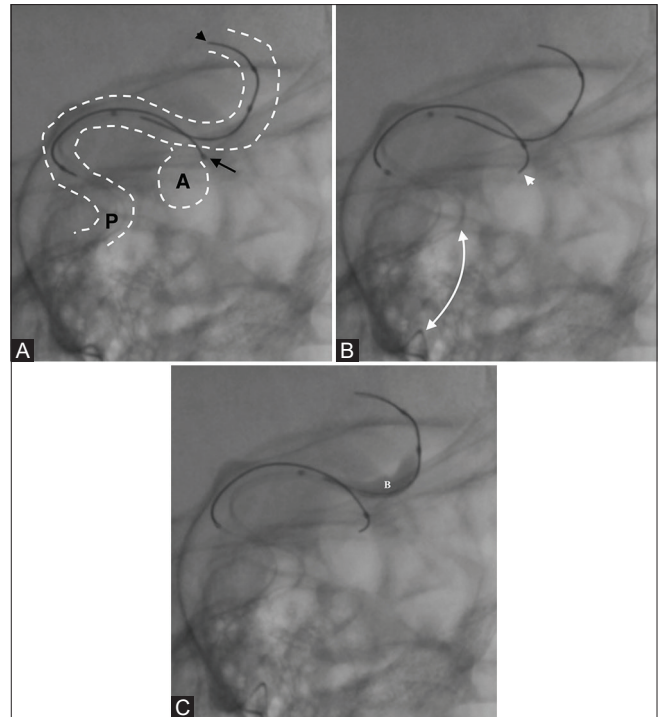


**Figure 1 (A-C):** The anterior-posterior and oblique DSA images of a patient with an aneurysm located on the right MCA. (A) shows the microwire guidewire navigation problem, especially in target arteries with an acute angle and presents a solution (A: Aneurysm, T: Target artery). (B) shows that the microwire is herniating into the non-target artery (black arrow) due to the acute angle of the target artery (white arrow: The balloon catheter and semi-inflated balloon). (C) shows that the nominal inflated balloon in the non-target artery creates an artificial wall effect, which facilitates target artery navigation (white arrow: The balloon catheter and balloon inflated at nominal pressure, black arrow: The microwire)

Another problem was the intrasaccular positioning of the microcatheter due to the narrow neck of very small aneurysms (especially due to vasospasm in patients with acute SAH). Many techniques were tested to achieve the requisite microcatheter position in the aneurysm sac. During the implementation of these techniques, it was clearly observed that the microcatheter was overloaded with force. Using the road map images, it was also observed that the microcatheter was pushing against the opposite wall of the parent artery, with bulging, and although it was advanced at the groin, there was no progress at the distal tip on the DSA images [Figure 2B]. There was a possibility of aneurysm rupture due to the overloaded microcatheter being abruptly thrown into the small aneurysm sac.

#### *Technique for solving the microcatheter positioning problem*

First, the overloaded microcatheter was unloaded until its body flattening was observed throughout the parent artery. The uninflated balloon, which was located proximal to the parent artery for safety purposes, was positioned to cover the neck of the aneurysm. Next, it was inflated to a sufficient volume [Figure 2C]. Inflating the balloon in the parent artery created an artificial wall effect, and the microcatheter was easily advanced into the aneurysm sac without the need for force; then, the balloon was deflated. Finally, the microcatheter was positioned safely and effectively with small push and pull maneuvers in aneurysms with challenging anatomies related to the neck and size. Balloon manipulation was used without any major complication.



**Figure 2 (A-C):** The oblique DSA images of a patient with an aneurysm located on the left MCA. (A) shows the microcatheter positioning problem and a proposed solution (P: Parent artery, A: Aneurysm). Serial images show that the distal tip of the microcatheter becomes stuck at the distal corner of the aneurysm neck, without a suitable position for the coiling. The black arrowhead shows the balloon catheter, the black arrow shows the microcatheter, and the white circle represents the aneurysm. (B) shows that the white dual arrow demonstrates the bulging due to overload force on the microcatheter (white arrowhead: Micro guidewire). (C) shows that the balloon in the non-target artery was inflated to create an artificial wall effect, and the microcatheter falls into the aneurysm without additional force (B: Balloon)

SPSS v. 18 was used to analyze the basic descriptive data of the patients and aneurysms.

## Results

The results of the study are shown in Table 1.

#### **Patients and aneurysms**

This study included a total of 14 patients. The microwire navigation of the target artery with balloon manipulation was used in 4 aneurysms of 4 patients. Microcatheter positioning into the aneurysm sac with balloon manipulation was used in 10 aneurysms of 10 patients.

In the microwire navigation group, the mean diameter of aneurysms was 3.87 mm (min-max: 3-4.5 mm), and the mean diameter of aneurysm necks was 1.77 mm (1.2-2.2 mm). In this group of patients, all the target arteries had an acute angle of less than 40 degrees (min-max: 23-40 degrees). In the microcatheter positioning group, the mean diameter of aneurysms was 4.21 mm (min-max: 2.2-6.5 mm), and the mean diameter of aneurysm necks was 1.97 mm (1.1-3.5 mm).

**Table 1: Patients' demographics and aneurysm features**

Age (years)/Sex	Aneurysm Features			Etiology	Aim of Balloon Use	Balloon Size (mm)
	Localization	Size (mm)	Neck (mm)			
22/M	Basilar artery	6.5×4.1	3.5	A. SAH	Positioning	6×15
76/F	MCA-Bif.	3.1×2.9	1.5	A.SAH	Positioning	6×15
69/M	Acom	2.9×2	1.1	A. SAH	Positioning	6×15
57/F	Acom	5.5×2.4	2.3	A. SAH	Positioning	6×12
62/F	Acom	4.6×3.4	2.9	A. SAH	Positioning	6×9
42/M	Acom	5.6×3.4	2.6	A. SAH	Positioning	6×15
44/F	ICA-Pcom	3.9×2.5	1.5	A.SAH	Positioning	6×20
45/F	ICA-Pcom	4.5×3.5	1.2	A.SAH	Positioning	6×20
74/M	ICA-Pcom	2.2×2	1.1	A. SAH	Positioning	6×20
41/F	ICA-Pcom	3.3×2.2	2	A. SAH	Positioning	6×15
63/F	MCA-Bif.	3.6×2.3	1.8	A. SAH	Navigation	6×15
33/F	MCA-Bif.	3×2.7	1.2	None SAH	Navigation	6×12
70/F	MCA	4.4×2.8	1.9	Old SAH	Navigation	6×15
39/F	ICA	4.5×4	2.2	Old SAH	Navigation	6×12

M: Male, F: Female, Bif.: Bifurcation, A. SAH: Acute subarachnoid hemorrhage, Acom: Anterior communicating artery, Pcom: Posterior communicating artery, MCA: Middle cerebral artery, ICA: Internal carotid artery

Among the patients in the microwire navigation group ( $n=4$ , cases 11-14), 1 patient had acute aneurysmal SAH (ruptured MCA bifurcation aneurysm), and 2 had previously undergone EVT (6 and 12 months earlier, respectively). The cause of retreatment in these 2 cases was the remnant aneurysm neck and increasing aneurysm size observed on follow-up angiography. The remaining 1 patient had an unruptured IA treated with SACE 15 months earlier. In this case, the follow-up angiography revealed a remnant aneurysm neck and coil prolapse into the A1 segment of the anterior cerebral artery (ACA), which is why retreatment was performed electively. Among all patients in the microcatheter positioning group ( $n=10$ , cases 1-10), including those with acute aneurysmal SAH, EVT was performed within the first 24 hours of presentation to the hospital.

Among all patients with ruptured aneurysms in both groups, the aneurysms were located in the ICA in 5 cases (45.5%), the anterior communicating artery (Acom) in 4 cases (36.3%), MCA in 1 case (7.1%), and the basilar artery in 1 case (7.1%).

### Complications

There were no cases of mortality or persistent neurological deficits due to EVT. A complication was observed in only 3 patients. In only 1 patient, balloon manipulation for microwire navigation caused temporary intraprocedural stent occlusion (case 12). In this case, the patient had been treated with primary coiling 6 months earlier, and coil migration toward the dome of the aneurysm had been detected. The stent (LEO Baby, Balt, Montmorency, France) was deployed from the inferior trunk of the MCA to the M1 segment, and an in-stent thrombus was immediately observed. Tirofiban (4 cc) was diluted in 20 cc of saline and

selectively injected via the microcatheter. The thrombus completely resolved angiographically. There was no branch loss, and no additional neurological deficit was observed after the procedure.

Coil prolapse into the parent artery was observed in 2 patients (cases 1 and 7). In case 1, a coil loop in the basilar aneurysm extended to the distal part of the P1 segment of the left posterior cerebral artery (PCA) during the deployment of the last coil. A "J"-shaped microwire was hooked up the protruded coil tip and withdrawn into the aneurysm sac without complications. In case 7, at mid-coiling, the tail tip of the coil in the ICA-posterior communicating artery (Pcom) aneurysm sac prolapsed toward the lumen of the Pcom. The coiling process was continued. No thrombosis due to coil prolapse was observed during the first control angiography examination (after 24 hours). Endothelialization over the tip of the prolapsed coil loop was seen on DSA at the 6<sup>th</sup>-month follow-up examination. There was no branch loss or any additional neurological deficit related to the balloon manipulation procedure in either patient. There was also no increase in the complication rates with the balloon manipulation method.

### Discussion

In our study, it was found that a hypercompliant balloon could be used for manipulating microcatheter or microwire to avoid microwire herniation into the nontarget artery in acute-angled target arteries and to prevent iatrogenic aneurysm ruptures caused by microcatheter overloading in narrow-necked small aneurysms.

Ordinary and extraordinary utilizations of balloons in the EVT of IAs are available. Ordinary utilizations of

balloons are performed typically to obtain dense-packed aneurysm coiling and to prevent coil loop prolapse into the parent artery in the treatment of wide-necked aneurysms.<sup>[11,12]</sup> Another benefit of hypercompliant balloon ordinary utilization has been reported as the protection of branches located close to the aneurysm neck.<sup>[13,11]</sup> Balloon-assisted coiling is used safely in the EVT of IAs with different localizations and morphological features.<sup>[11,13-16]</sup> Although some reports suggest that the use of balloons in the treatment of IAs increases the number of intraprocedural complications (thromboembolic events and aneurysm rupture), there are also comprehensive publications comparing treatments with and without the use of a balloon, indicating that the rate of intraprocedural complications does not increase.<sup>[14,16]</sup>

It has even been reported that balloons can be used intraprocedurally to resolve complications in EVT.<sup>[17,18]</sup> One of the interesting solutions proposed involves the utilization of a balloon to prevent an FDD from slipping proximally into the aneurysm sac.<sup>[18]</sup> During this process, access to the FDD from its proximal tip was regained by creating a leverage effect with an inflated balloon in the aneurysm sac.<sup>[18]</sup> Another extraordinary use of balloons is to resolve problems in gaining access using the guiding catheter resulting from aortic arch variations, ICA tortuosity, or vascular irregularities. Peeling *et al.*<sup>[6]</sup> suggested that problems related to challenging access could be solved by using the balloon as an anchor in the petrous segment of ICA. Another extraordinary application of the balloon is to create a barrier to prevent the herniation of the microwire into a non-target artery (MCA M1 segment) during the navigation of the A1 segment of ACA with an acute angle.<sup>[19]</sup>

This study shows that balloons can be used safely and effectively to avoid microwire herniation in acute-angle target artery navigation, as demonstrated in 4 patients. The major feature of this study is that it is one of the first to describe balloon manipulation for microcatheter positioning. In our neurointerventional radiology unit, a very high proportion of patients (12%) required treatment with the microcatheter positioning technique, which was successfully applied. The average aneurysm diameter in the patients who underwent treatment with the microcatheter positioning technique with balloon manipulation was 4.2 mm, placing these aneurysms in the small category. Schuette *et al.*<sup>[9]</sup> demonstrated that the intraprocedural rupture rate increased by 4.6-fold for aneurysms smaller than 4 mm because there is little space for microcatheter navigation and positioning in small aneurysm sacs. Forward pressure to advance the microcatheter may cause aneurysm rupture, which has mortal consequences.

Microcatheter shaping is a well-known technique to access an aneurysm sac in the presence of challenging anatomies<sup>[20-22]</sup>; however, this technique has certain

handicaps. The first is that some microcatheters cannot be easily shaped. The structural materials of the microcatheter affect shaping capacity. Yamaguchi *et al.*<sup>[21]</sup> analyzed four different types of microcatheters to investigate the shaping capacity and found that only one straight microcatheter had superiority for effective shaping. The problem of low accessibility of microcatheters with high shaping capacity in medical markets can adversely affect the adoption of this technique. In contrast, there is no need for a special microcatheter type for the utilization of the balloon manipulation method. In a typical shaping technique, the direction of the formed tip of the microcatheter is unclear; therefore, the optimal 3D position and stabilization of microcatheter may not be easy to achieve. Some authors have also used a 3D printer when performing microcatheter shaping to obtain an accurate 3D position *in vivo*.<sup>[21,23]</sup> Despite using a 3D printer, Namba *et al.*<sup>[24]</sup> reported the microcatheter instability rate as 10% in 10 consecutive cases. In addition to instability rates, the difficulty of accessing 3D printers is an important disadvantage of the shaping technique. Furthermore, the shaping technique is only related to the microcatheter and does not provide any convenience about microwire navigation. On the other hand, our technique is more practical because it can be performed both in microwire navigation and microcatheter positioning. Some authors have mentioned the failure rates of pre-shaped microcatheter insertion up to 13%.<sup>[21]</sup> In our study, the balloon-assisted technique was performed with an excellent technical success rate (100%). Our technique provided promising results in the EVT of small IAs and presents as a feasible alternative that does not require microcatheters with high shaping capacity or 3D printers.

One of the important limitations of this study is the small sample size. This was due to only a small number of patients requiring the extraordinary use of balloons, as defined in this study. Another limitation is the retrospective nature and single-center design of the study. However, considering that our study is one of the first publications about the balloon manipulation technique, we believe that these limitations are acceptable and do not diminish the significance of the results. Multicenter, prospective studies with larger samples are needed to further test the safety and efficacy of balloon manipulation techniques.

## Conclusion

Balloon-assisted microwire navigation and microcatheter positioning is a safe and effective method without additional complications, especially in target arteries with an acute angle and in small aneurysms in the EVT of IAs with challenging anatomies. This technique presents as a favorable alternative to prevent the failure of EVT.

## Financial support and sponsorship

Nil.

**Conflicts of interest**

There are no conflicts of interest.

**References**

1. Vlak MH, Algra A, Brandenburg R, Rinkel GJ. Prevalence of unruptured intracranial aneurysms, with emphasis on sex, age, comorbidity, country, and time period: A systematic review and meta-analysis. *Lancet Neurol* 2011;10:626-36.
2. Caranci F, Briganti F, Cirillo L, Leonardi M, Muto M. Epidemiology and genetics of intracranial aneurysms. *Eur J Radiol* 2013;82:1598-605.
3. Lin N, Cahill KS, Frerichs KU, Friedlander RM, Claus EB. Treatment of ruptured and unruptured cerebral aneurysms in the USA: A paradigm shift. *J Neurointerv Surg* 2018;10(Suppl 1):i69-i76.
4. Gao B-L, Li Z-S, Li T-X, Xue J-Y, Feng G, Wang Z-L, *et al.* Endovascular treatment of intracranial aneurysms concomitant with severe adjacent atherosclerotic stenosis. *World Neurosurg* 2018;111:e927-32.
5. Patel M, Iwananga J, Bentley J, Wang BH, Patel A, Tubbs RS, *et al.* Incidentally found double aortic arch while treating posterior inferior cerebellar artery aneurysm: Conversion from femoral to radial artery access. *World Neurosurg* 2018;116:1-4
6. Peeling L, Fiorella D. Balloon-assisted guide catheter positioning to overcome extreme cervical carotid tortuosity: Technique and case experience. *J Neuro Inter Surg* 2014;6:129-33.
7. Connolly Jr ES, Rabinstein AA, Carhuapoma JR, Derdeyn CP, Dion J, Higashida RT, *et al.* Guidelines for the management of aneurysmal subarachnoid hemorrhage. *Stroke* 2012;43:1711-37.
8. Kawabata S, Imamura H, Adachi H, Tani S, Tokunaga S, Funatsu T, *et al.* Risk factors for and outcomes of intraprocedural rupture during endovascular treatment of unruptured intracranial aneurysms. *J Neurointerv Surg* 2018;10:362-6.
9. Schuette AJ, Hui FK, Spiotta AM, Obuchowski NA, Gupta R, Moskowitz SI, *et al.* Endovascular therapy of very small aneurysms of the anterior communicating artery: Five-fold increased incidence of rupture. *Neurosurgery* 2011;68:731-7.
10. White AC, Khattar NK, Aljuboori ZS, Obiora JC, James RF. Basic Endovascular Techniques: Direct, Balloon-Assisted, and Stent-Assisted Coil Embolization. In: Andrew J. Ringer, editor. *Intracranial Aneurysms*, 1<sup>st</sup> ed. Cambridge: Academic Press; 2018. p. 329-56.
11. Cekirge HS, Yavuz K, Geyik S, Saatci I. HyperForm balloon remodeling in the endovascular treatment of anterior cerebral, middle cerebral, and anterior communicating artery aneurysms: Clinical and angiographic follow-up results in 800 consecutive patients. *J Neurosurg* 2011;114:944-53.
12. Pierot L, Cognard C, Anxionnat R, Ricolfi F, CLARITY Investigators. Remodeling technique for endovascular treatment of ruptured intracranial aneurysms had a higher rate of adequate postoperative occlusion than did conventional coil embolization with comparable safety. *Radiology* 2011;258:546-53.
13. Baldi S, Mounayer C, Piotin M, Spelle L, Moret J. Balloon-assisted coil placement in wide-neck bifurcation aneurysms by use of a new, compliant balloon microcatheter. *Am J Neuroradiol* 2003;24:1222-5.
14. Layton KF, Cloft HJ, Gray LA, Lewis DA, Kallmes DF. Balloon-assisted coiling of intracranial aneurysms: Evaluation of local thrombus formation and symptomatic thromboembolic complications. *AJNR Am J Neuroradiol* 2007;28:1172-5.
15. Ross IB, Dhillon GS. Balloon assistance as a routine adjunct to the endovascular treatment of cerebral aneurysms. *Surg Neurol* 2006;66:593-601.
16. Santillan A, Gobin YP, Mazura JC, Meausoone V, Leng LZ, Greenberg E, *et al.* Balloon-assisted coil embolization of intracranial aneurysms is not associated with increased periprocedural complications. *J Neurointerv Surg* 2013;5(Suppl 3):iii56-61.
17. Jagadeesan BD, Sandhu D, Hong KJ, Khanipour SR, Grande AW, Tummala RP. Salvage of herniated flow diverters using stent and balloon anchoring techniques: A technical note. *Interv Neurol* 2017;6:31-5.
18. Martínez-Galdámez M, Ortega-Quintanilla J, Hermosín A, Crespo-Vallejo E, José Ailagás J, Pérez S. Novel balloon application for rescue and realignment of a proximal end migrated pipeline flex embolization device into the aneurysmal sac: Complication management. *J Neurointerv Surg* 2017;9:e4-e4.
19. Naragum V, AbdalKader M, Nguyen TN, Norbash A. Balloon-assisted cannulation for difficult anterior cerebral artery access. *Interv Neurol* 2018;7:48-52.
20. Kwon BJ, Im S-H, Park JC, Cho YD, Kang H-S, Kim J-E, *et al.* Shaping and navigating methods of microcatheters for endovascular treatment of paraclinoid aneurysms. *Neurosurgery* 2010;67:34-40; discussion 40.
21. Yamaguchi S, Ito O, Koyanagi Y, Iwaki K, Matsukado K. Microcatheter shaping using intravascular placement during intracranial aneurysm coiling. *Interv Neuroradiol* 2017;23:249-54.
22. Xu Y, Tian W, Wei Z, Li Y, Gao X, Li W, *et al.* Microcatheter shaping using three-dimensional printed models for intracranial aneurysm coiling. *J Neurointerv Surg* 2020;12:308-10.
23. Ishibashi T, Takao H, Suzuki T, Yuki I, Kaku S, Kan I, *et al.* Tailor-made shaping of microcatheters using three-dimensional printed vessel models for endovascular coil embolization. *Comput Biol Med* 2016;77:59-63.
24. Namba K, Higaki A, Kaneko N, Mashiko T, Nemoto S, Watanabe E. Microcatheter shaping for intracranial aneurysm coiling using the 3-dimensional printing rapid prototyping technology: Preliminary result in the first 10 consecutive cases. *World Neurosurg* 2015;84:178-86.