



# Outcome of Transforaminal Endoscopic Discectomy in Rural India in a Single-Level Lumbar Disc Prolapse Under Local Anesthesia

Vishnu Vikraman Nair<sup>1</sup> Sarabjeet Kohli<sup>1</sup> Nilesh Vishwakarma<sup>1</sup> Juilee Mhatre<sup>1</sup>

<sup>1</sup>Department of Orthopaedics, MGM Institute of Health Sciences, Navi Mumbai, Maharashtra, India

Address for correspondence Vishnu Vikraman Nair, MBBS, MS, Kaleekal House, Nedumkunnam PO, Kottayam, Kerala, 686542, India (e-mail: vishnunair212@gmail.com).

AJNS 2023;18:312–320.

## Abstract

**Aim** The aim of this study was to undertake a clinical study to evaluate the outcomes of transforaminal endoscopic discectomy under local anesthesia and to study the complication rate.

**Study Design** It is a prospective study.

**Methods** We prospectively analyzed outcomes of 60 patients with a single-level lumbar disc prolapse in rural India from December 2018 to April 2020 who underwent endoscopic discectomy under local anesthesia. Follow-up was done using the visual analogue score (VAS) and Oswestry Disability Index (ODI) scoring systems with a minimum follow-up up to 1 year postoperatively.

**Results** In our study of 60 patients, there was 38 cases of L4-L5 disc pathology, 13 L5-S1 discs, and 9 L3-L4 discs. Our study showed a significant clinical reduction in mean VAS score that was 7.07/10 preoperatively and reduced to 3.88/10 at the third month and 3.64/10 at 1 year of follow-up ( $p$ -value  $< 0.05$ ) showing clinical significance. The ODI scoring done preoperatively was an average mean of 57.37% pointing to how crippled the patients were with lumbar disc prolapse and showed a significant reduction to 29.32% postoperatively at 1 year ( $p$ -value  $< 0.05$ ) showing clinical significance. This reduction in ODI directly correlates to how almost all patients returned to normal life coping to all activities and were completely pain free at 1 year of follow-up.

**Conclusion** Endoscopic spine surgery in lumbar disc prolapse is highly effective and can deliver a good functional outcome if done with correct preoperative planning and approach.

## Keywords

- ▶ lumbar disc prolapse
- ▶ endoscopic spine surgery
- ▶ low back pain
- ▶ local anesthesia
- ▶ discectomy

## Introduction

Back pain is one of the most common problems facing this rapidly progressive world. Statistical data are such that approximately two-thirds of the world population will experience low back pain at some point in their life.<sup>1</sup> According

to statistical data, approximately 40% of adults have low back pain during any given year and approximately 75% have low back pain at some point of time in their lives.<sup>2</sup>

The intervertebral discs are a part of this deep tissue that are fibrocartilaginous structures transmitting compressive weight load to the opposing end surfaces of the bodies of

article published online  
June 16, 2023

DOI <https://doi.org/10.1055/s-0043-1769756>.  
ISSN 2248-9614.

© 2023. Asian Congress of Neurological Surgeons. All rights reserved.

This is an open access article published by Thieme under the terms of the Creative Commons Attribution-NonDerivative-NonCommercial-License, permitting copying and reproduction so long as the original work is given appropriate credit. Contents may not be used for commercial purposes, or adapted, remixed, transformed or built upon. (<https://creativecommons.org/licenses/by-nc-nd/4.0/>)

Thieme Medical and Scientific Publishers Pvt. Ltd., A-12, 2nd Floor, Sector 2, Noida-201301 UP, India

vertebrae functioning as principal shock absorbers. The human intervertebral disc has shown to undergo most dramatic degeneration than any other musculoskeletal tissue.<sup>3</sup> This degeneration is described to be a complex interaction of biologic, genetic, and biomechanical factors.

Kirkaldy-Willis and Farfan described disc degeneration into three stages: temporary dysfunction, instability, and stabilization. Lumbar disc herniation is a major cause of back pain and radiating pain to the lower limb. Lumbar disc herniation is a complication of disc degeneration during its first- and second-stage of degeneration.<sup>4</sup> Disc degeneration and its pathologic progression is a combination of clinical correlation of history, physical examination, and imaging that yields a specific diagnosis that seems till today the greatest challenge.

The nucleus of the disc elicits an immune response leading to inflammatory reaction around the disc and the adjacent nerve root.<sup>5,6</sup> The immune response is also said to play a role in the resolution of the herniated disc.<sup>7</sup> Back pain with radicular pain was studied by Kellegren where he instituted hypertonic saline into the deeper tissues of the spine and regenerated the pain the patient experienced and pain in superficial tissue was only local and vanished after needle removal.<sup>8</sup>

Nonanatomic problems like psychosocial issues and depression must be considered when evaluating these patients. In addition, the number of anatomic causes for these symptoms, whether real or perceived, has increased, as understanding and diagnostic capabilities have increased.<sup>9</sup>

The highest prevalence is among people aged between 30 and 50 years, with a male to female ratio of 2:1. In people aged between 25 and 55 years, approximately 95% of herniated discs occur at the lower lumbar spine (L4/5 and L5/S1 level) with L5/S1 being the most common; disc herniation above this level is more common in people aged over 55 years.<sup>10</sup>

### Treatment Options

A comprehensive approach should be adopted for the management of lumbar disc disease. Initial management for all symptomatic disc disease should include rest followed by physiotherapy, and appropriate use of pain medication. In most instances, radicular symptoms will abate or resolve within 6 weeks.<sup>11,12</sup>

According to Deyo et al, 2 days of bed rest was better than a longer period of immobilization.<sup>13</sup>

Nonsteroidal anti-inflammatory drugs along with muscle relaxants are effective for short-term relief. Tricyclic antidepressants and opioids like tramadol help reduce pain significantly.<sup>9</sup>

McKenzie therapy, core muscle strengthening, is part of the physiotherapy that should be done under supervision in the nonpainful phase of the disease.<sup>9</sup>

Malmivaara et al compared the efficacy of bed rest alone, back extension exercises, and continuation of ordinary activity as tolerated in the treatment of back pain and concluded that continuation of ordinary activity within the limits permitted by pain led to a quicker recovery.<sup>14</sup>

Selective nerve root block with a combination of local anesthetic drug and long-acting steroid may also relieve pain in acute cases.<sup>9</sup> Other traditional treatment options include traction, transcutaneous electric nerve stimulation, and nontraditional treatments options like massage herbs that do not have any definitive evidence.<sup>9</sup>

### Surgical Treatment

Surgical treatment of lumbar disc disease has evolved over the years. Currently, we have minimal invasive surgeries like microdiscectomy and endoscopic spine surgeries. Open lumbar discectomy was implemented as a standard surgery for lumbar disc disease, first described by Dandy and Peltier.<sup>15</sup>

New technological advancements in magnetic resonance imaging (MRI) and computed tomography scan along with clinical correlation have helped us to precisely diagnose the cause of pain generation and manage such patients endoscopically.<sup>16</sup>

The overall success rate of conventional microdiscectomy ranged from 75 to 100%<sup>17</sup> and that of transforaminal percutaneous endoscopic lumbar discectomy (PELD) was 69 to 90%.<sup>18-21</sup> Therefore, transforaminal PELD might be an important alternative to conventional open microdiscectomy, and their clinical outcomes were reported to be comparable.<sup>22-24</sup> Moreover, transforaminal PELD can be operated under local anesthesia. No Foley catheterization was done in any of the patients as only local anesthesia was administered. Hence, this procedure is possible for elderly patients with poor general conditions and provides better feedback to avoid potential nerve root damage from manipulation during operation.<sup>25</sup>

Advantages of endoscopic spine surgeries are lower muscular trauma and stripping, minimal to no blood loss, lowered chances of epidural vessel damage, and it is also a day care procedure providing immediate and effective reduction in pain.

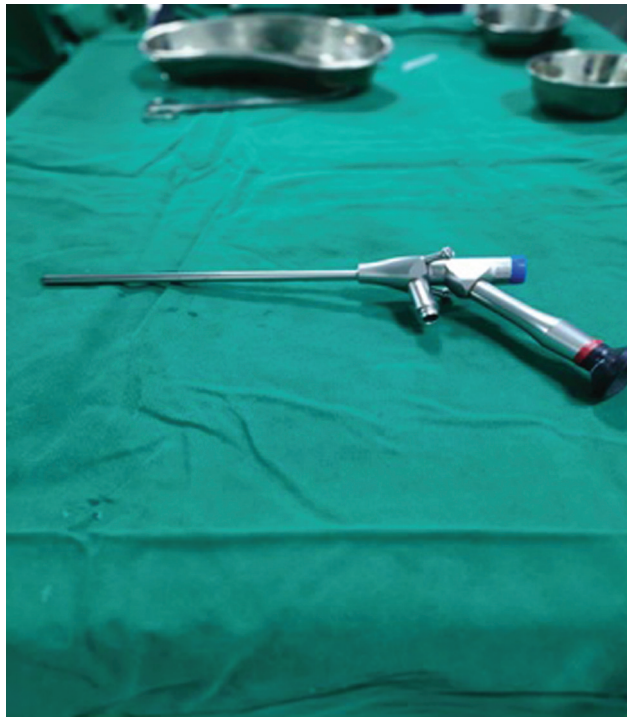Athletes and sports personnel would have an early functional recovery and less tissue trauma when operated endoscopically.<sup>16</sup>

In this study, we report the outcomes and complications of 60 patients who will undergo endoscopic discectomy under local anesthesia and how the pain scale varies postoperatively that will help us pave a way to the future of spine surgeries.

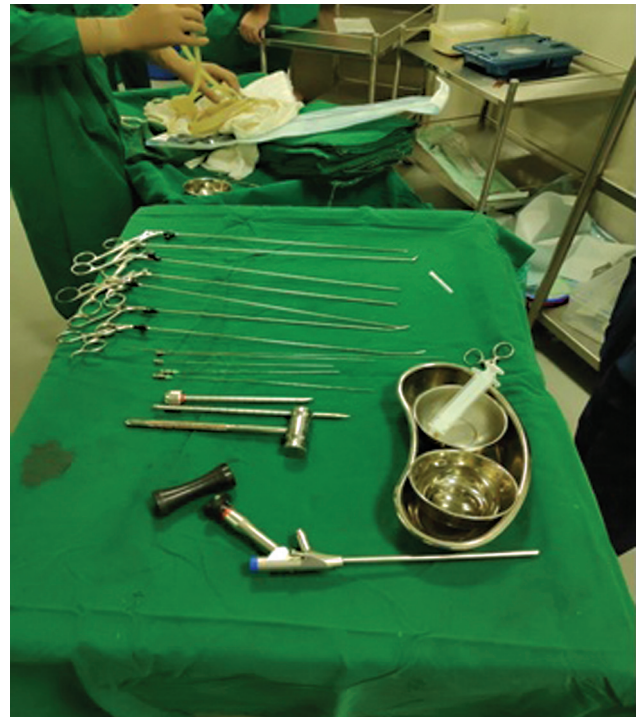
### Subjects and Methods

Sixty patients with a single-level lumbar disc prolapse prospectively analyzed and operated during December 2018 to April 2020. These patients were evaluated postoperatively at 24 hours, 3 months, and 1 year using visual analogue scoring (VAS) and Oswestry Disability Index (ODI). We conducted this study in compliance with the principles of the Declaration of Helsinki. The study's protocol was reviewed and approved by the Institutional Ethics Committee of MGM Medical college, Navi Mumbai, with approval number: N-EC/2019/SC/03/56

Inclusion criteria were as follows: (1) Patients (both males and females) were included if they suffered back pain and



**Fig. 1** 25-degree endoscope.



**Fig. 2** Instruments.

combinations of referred pain in buttock, groin, thigh, and below the knee that were treated conservatively for at least 6 weeks and on MRI had single-level prolapse of disc; aged above 18 years; and had positive straight leg raise test.

The exclusion criteria were as follows: (1) Patients with bilateral radiculopathy; (2) cauda equina syndrome, established lumbar canal stenosis, facet joint cysts, tumors, and discitis; and (3) instability on X-ray films.

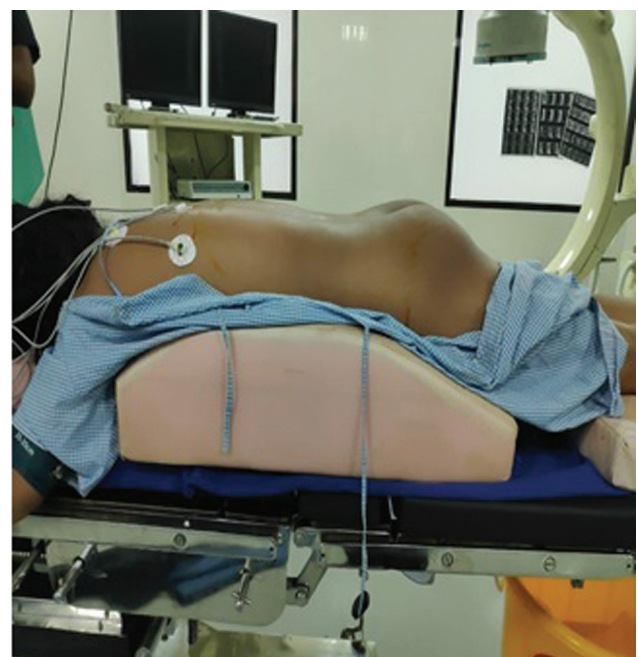### Surgical Technique

All surgeries were performed using KARL STORZ 25-degree scope (►Fig. 1) and an operating working sheath, dilation sleeve, puncture needle, guidewire, metal mallet, punch sleeve, grasping forceps, and bendable grasping forceps (►Fig. 2). Prone positioning of the patient on an adjustable radiolucent frame was most desirable for endoscopic transforaminal discectomy (►Fig. 3). After prone positioning, the level was identified and scrubbing and painting were done. Markings were done using a scale under C-arm guidance (►Fig. 4).

The skin, subcutaneous tissue, fascia, and muscle layers are infiltrated with local anesthesia (lignocaine + bupivacaine) (►Fig. 5). A lateral entry point is made using the marking as a guide, in a range of 10 to 14 cm lateral to the posterior midline. Now we use a transforaminal spinal needle to reach the foramen with the needle tip positioned at the medial pedicular line in the anteroposterior projection and on the posterior vertebral borderline in the lateral projection. The needle was then advanced to the midline in the anteroposterior projection (►Fig. 6).


We now pass a guidewire after removing the stylet and take the needle out. Skin incision is then taken, and serial

dilators are used over the guidewire up to the disc space. Once we have reached the desired level the guidewire is removed, and operating sheath is inserted into the disc space (►Fig. 7). The dilator is removed, and endoscope is inserted. The disc is directly visualized (►Fig. 8) and removed. Bleeding is controlled by increasing the pressure of fluid or by bipolar cautery.

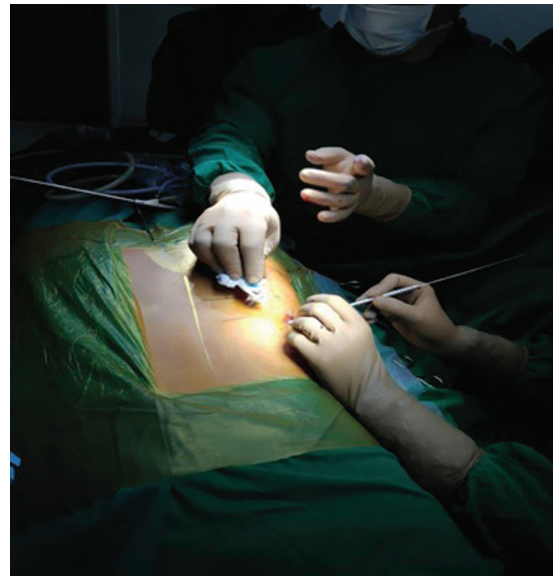

**Fig. 3** Prone positioning.

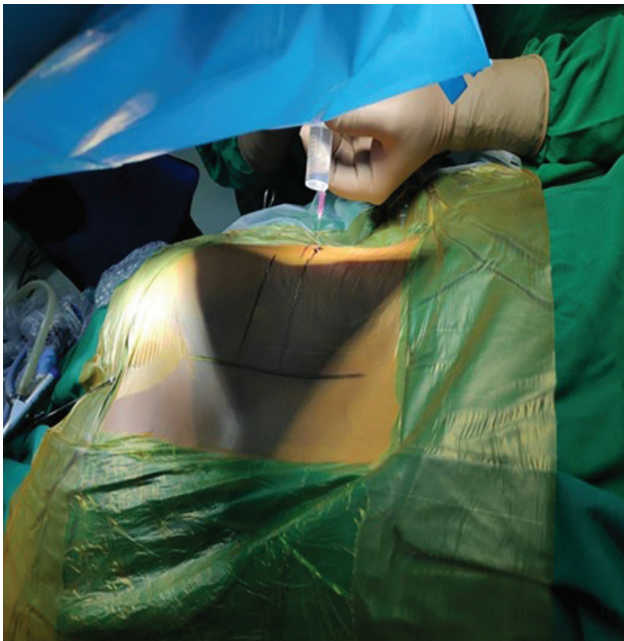




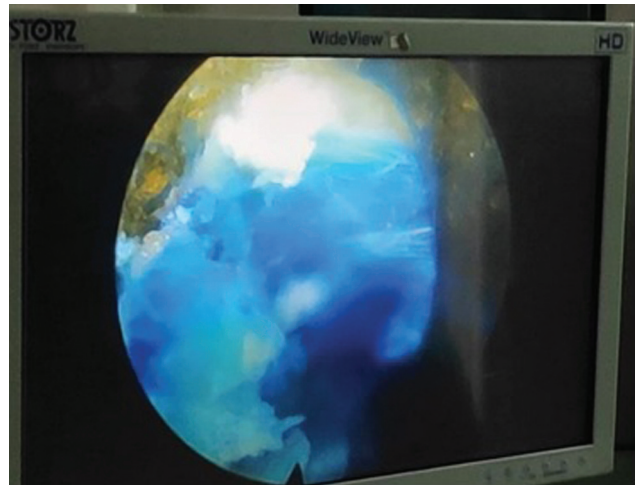
**Fig. 4** Level marking.



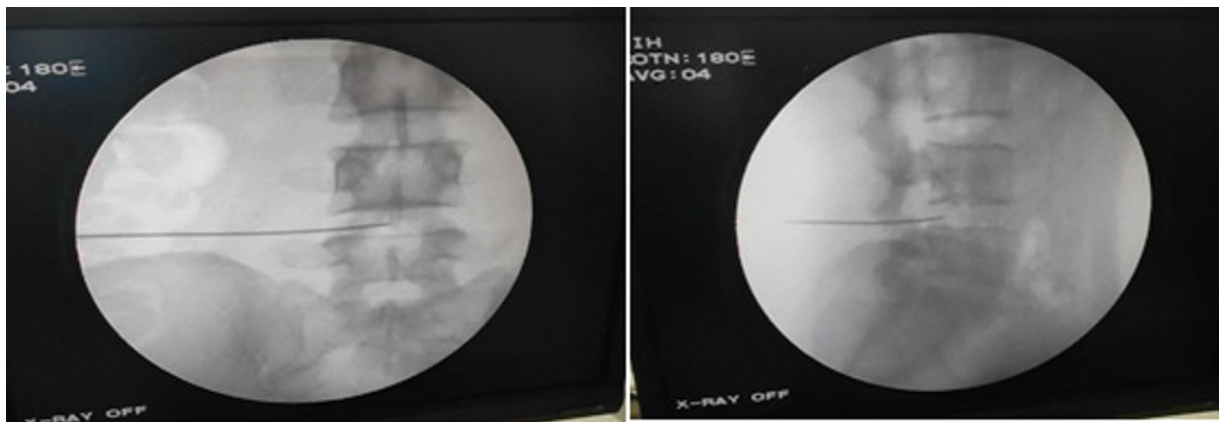
**Fig. 7** Serial dilators on guidewire.



**Fig. 5** Local anesthesia infiltration.



**Fig. 8** Stained disc material.



**Fig. 6** Needle insertion.

**Table 1** Test of normality in ODI

Tests of normality						
Difference	Kolmogorov–Smirnov test <sup>a</sup>			Shapiro–Wilk test		
	Statistic	df	Sig.	Statistic	df	Sig.
Pre–postoperative day 1	0.190	59	0.000	0.903	59	0.000
Pre–postoperative 3 months	0.226	59	0.000	0.900	59	0.000
Pre–postoperative 1 year	0.162	59	0.001	0.943	59	0.008

<sup>a</sup>Lilliefors significance correction.

**Table 2** Mean, median, and SD (ODI)

	Median	Mean	Standard deviation
ODI pre	60.00	57.37	14.00
Postoperative day 1	30.00	30.85	11.53
Postoperative month 3	30.00	30.34	9.55
ODI postoperative year 1	30.00	29.32	9.80

Abbreviation: ODI, Oswestry Disability Index.

**Table 3** Mean rank (ODI)

Ranks	
	Mean rank
ODI pre	3.96
Postoperative day 1	2.10
Postoperative month 3	2.03
ODI postoperative year 1	1.92

Abbreviation: ODI, Oswestry Disability Index.

Removal of multiple disc fragments is done and visualization of epidural fat or nerve root and decompression around the root is done with protective measures to not damage the root. Intraoperative relief of leg pain can be seen once adequate decompression is done. After discectomy, endoscope is withdrawn and skin incision is closed with a single tag suture.

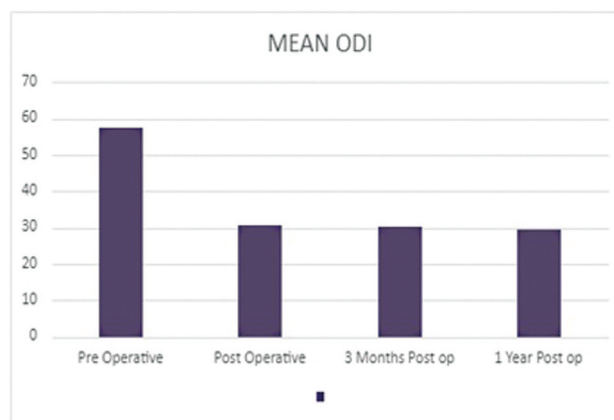
## Results and Statistical Analysis

In our study, we successfully operated 60 patients, out of which we had 23 females and 37 males. The age distribution consisted of 46% patients in the age bracket of 35 to 55 years, 22% below 35 years, and 36% above 55 years of age.

### Comparison of ODI

#### Tests of Normality

*Interpretation:* Since *p*-value for K-S and S-W test of normality is less than that of 0.05, it indicates that data are not distributed normally and therefore we use Friedman’s test and Wilcoxon signed rank test to test the significance (→ Tables 1, 4).



**Fig. 9** Mean comparison of pre- and postoperative Oswestry Disability Index (ODI) scoring.

**Table 4** Friedman’s test

Test statistics	
<i>n</i>	59
Chi-square test	116.053
df	3
<i>p</i> -Value	0.000

### Descriptive Statistics

#### Mean Rank Table

The mean ODI (→ Fig. 9) in the preoperative period was 57% that then fell to 30% in the postoperative period and remained in the same range in follow-up on 3 months and 1 year (→ Table 3).

#### Friedman’s Test Result

*Interpretation:* Since *p*-value for the Friedman’s test is less than that of 0.05, it indicates that the average score of ODI significantly changes over the time. The pairwise comparison is done to find which of these pair is significant (→ Table 5).

#### Wilcoxon Signed Rank Test (Pairwise Comparison)

##### Interpretation

- *p*-Value less than that of 0.05 for postoperative day 1–ODI pre-comparison indicates that the postoperative day 1 score is significantly less than the ODI pre-score.

**Table 5** Comparison of ODI at all visits

	z	p-Value
Postoperative day 1—ODI pre	-6.584	0.000
Postoperative month 3—ODI pre	-6.637	0.000
ODI postoperative year 1—ODI pre	-6.582	0.000
Postoperative month 3—postoperative day 1	-0.825	0.410
ODI postoperative year 1—postoperative day 1	-1.497	0.134
ODI postoperative year 1—postoperative month 3	-1.228	0.220

Abbreviation: ODI, Oswestry Disability Index.

**Table 6** Mean, median, SD (VAS)

	Median	Mean	Standard deviation
VAS pre	7.00	7.07	1.16
VAS postoperative day 1	4.00	4.41	1.19
VAS month 3	4.00	3.88	1.12
VAS year 3	3.00	3.64	1.21

Abbreviation: VAS, visual analog scale.

**Table 7** Mean rank (VAS)

Ranks	Mean rank
Preoperative	3.99
Postoperative day 1	2.53
Postoperative month 3	1.88
Postoperative year 1	1.60

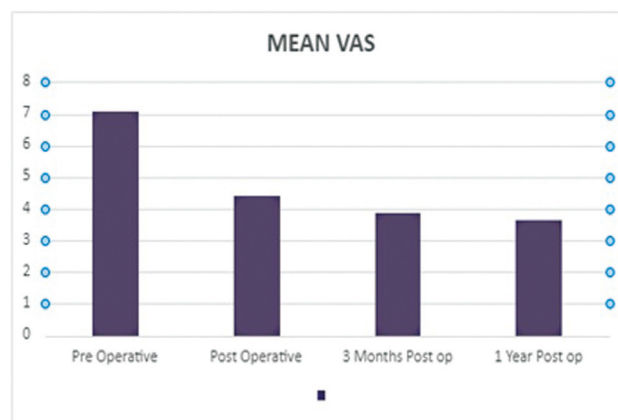
- p-Value less than that of 0.05 for postoperative month 3—ODI pre-comparison indicates that the postoperative month 3 is significantly less than the ODI pre-score.
- p-Value less than that of 0.05 for postoperative 1 year—ODI pre-comparison indicates that the postoperative 1 year is significantly less than the ODI pre-score.
- Since p-value for postoperative month 3—postoperative day 1, ODI postoperative 1 year—postoperative day 1, ODI post 1 year—postoperative month 3 is greater than that of 0.05 indicates that the average ODI score is almost same on postoperatively (→ Tables 6, 7).

### Comparison of VAS Score

#### Descriptive Statistics

##### Mean Rank Table

The mean visual analog score (→ Fig. 10) preoperatively was 7/10 significantly reduced to 4/10 post operatively and 3/10 in 3rd month and 1 year follow-up (→ Table 8).



**Fig. 10** Mean comparison of pre- and postoperative Visual Analog Scale (VAS) scoring.

**Table 8** Friedman’s test

Test statistics	
n	59
Chi-square test	147.977
df	3
p-Value	0.000

**Table 9** Comparison of VAS at all visits

	z	p-Value
Postoperative day 1—pre	-6.680	0.000
Postoperative month 3—pre	-6.729	0.000
Postoperative year 1—pre	-6.720	0.000
Postoperative month 3—postoperative day 1	-4.238	0.000
Postoperative year 1—postoperative day 1	-5.011	0.000
Postoperative year 1—postoperative month 3	-2.854	0.004

#### Friedman’s Test Result

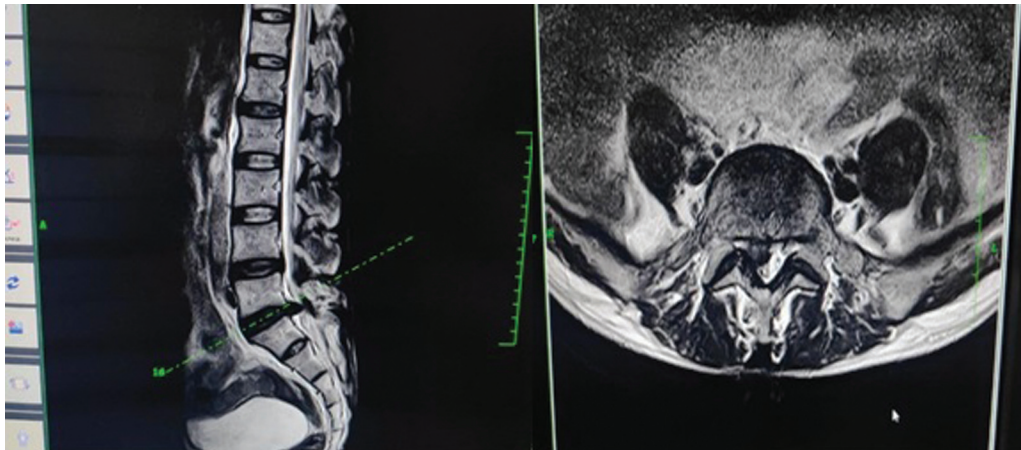
**Interpretation:** Since p-value for the Friedman’s test is less than that of 0.05, it indicates that the average score of VAS significantly changes over the time. The pairwise comparison is done to find which of these pair is significant (→ Table 9).

#### Wilcoxon Signed Rank Test (Pairwise Comparison)

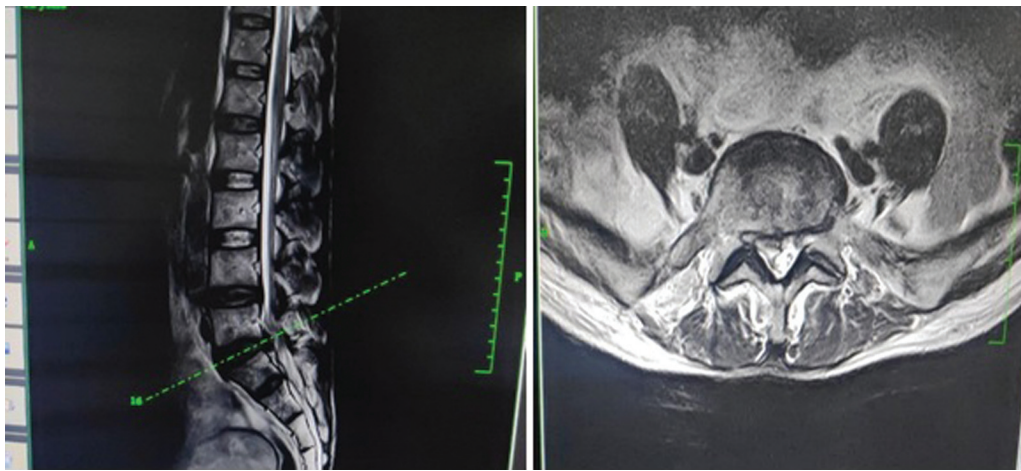
##### Interpretation

- p-Value less than that of 0.05 for postoperative day 1—pre-comparison indicates that the postoperative day 1 score is significantly less than the pre-score.
- p-Value less than that of 0.05 for postoperative month 3—pre-comparison indicates that the postoperative month 3 is significantly less than the pre-score.





**Fig. 11** Preoperative magnetic resonance imaging (MRI) case pre-operative MRI.



**Fig. 12** Postoperative magnetic resonance imaging case.

- *p*-Value less than that of 0.05 for postoperative 1 year—pre-comparison indicates that the post-operative 1 year is significantly less than the pre-score.
- *p*-Value less than that of 0.05 for postoperative month 3—postoperative day 1 comparison indicates that the postoperative month 3 is significantly less than the postoperative day 1 score.
- *p*-Value less than that of 0.05 for postoperative 1 year—postoperative day 1 comparison indicates that the postoperative 1 year is significantly less than the postoperative day 1 score.
- *p*-Value less than that of 0.05 for postoperative 1 year—postoperative month 3 comparison indicates that the postoperative 1 year is significantly less than the postoperative month 3 score.

## Discussion

In this progressive world, we are always aiming for excellence and for years, open discectomy has been the standard treatment for lumbar disc herniations. Endoscopic and microdiscectomy procedures have now decreased the need for long incisions.<sup>26</sup> Open lumbar discectomies have been the gold standard for the management of lactate dehydrogenase for the

last few decades due to the success rates ranging from 76 to 93% in long-term follow-up studies.<sup>27</sup>

In our study, there was 60 patients out of which we had 23 females and 37 males. Studies show a similarity in increased incidence of disc disease in male patients.<sup>28</sup>

We had 38 cases of L4–L5 disc pathology, 13 L5–S1 discs, and 9 L3–L4 discs.

Our study showed a significant clinical reduction in VAS postoperatively and a consistent pattern up to 1 year of follow-up, suggesting a low level of pain score after endoscopic discectomy. The ODI scoring done preoperatively was an average of 57% pointing to how crippled the patients were with lumbar disc disease and showed a significant reduction to 30% postoperatively to 1 year. This reduction in ODI directly correlates to how almost all patients returned to normal life coping to all activities with/without mild pain according to the ODI. On comparison of the pre-operative MRI (→**Fig. 11**) and post operative MRI (→**Fig. 12**) the effectiveness of the discectomy can be visualised.

Gibson et al compared the outcomes of results of transforaminal endoscopic disc surgery versus microdiscectomy and concluded that results were similar in terms of outcomes clinically in endoscopic spine and microdiscectomy showing

the real potential of endoscopic spine surgery in the years to come.<sup>29</sup>

Yeung and Tsou reported satisfactory result rate in 89.7% in posterolateral disc excision and poor results in only 10.3 patients attributing to the complications like deep infection in two, thrombophlebitis in two, dysesthesia in six, and dural tear in one patient.<sup>22</sup>

Chae et al performed 153 endoscopic discectomies and reported 94.77% satisfactory results on patients with lumbar disc herniations.<sup>30</sup>

Our study had few or less complications, four in total. We did not observe any late infection, thrombosis, or hemorrhage. One patient had developed discitis on the fifth postoperative day that was resolved with 7 days of intravenous antibiotics. Nerve root injury was seen in two patients one of which had developed power loss in flexor hallucis longus/flexor digitorum longus (FHL/FDL) and the other had a sensory loss in anterolateral aspect of thigh (L4). Two other patients developed reherniation causing similar symptoms present preoperatively. Comparing our study to literature, we had an exceptionally low complication rate, and it was mostly associated with the learning curve and experience needed in this surgery.

In a large retrospective study, the cause for a failed endoscopic procedure in lumbar disc disease is inadequate removal of disc material.<sup>31</sup> Another research group gave a rate of 4.5% recurrent disc herniations in a postoperative endoscopic discectomy patient.<sup>17</sup> Incomplete decompression can be a major cause of persistent symptoms even after surgery. The end-point of decompression is a subjective topic and varies among surgeons. In our study, we had multiple trained endoscopic spine surgeons who helped in targeted disc fragment removal in each patient. A steep learning curve in endoscopic spine along with poor decision making in a surgeon only beginning to do endoscopic spine could lead to an incomplete discectomy. We had no cases in our study that required an immediate conversion to a mini open or open decompression. But for a spine surgeon only just starting out to do endoscopic spine, it would always be good to be well versed with open or mini open decompression if targeted discectomy becomes a harder task.

Kulkarni et al reported the complications of microendoscopic discectomy in 188 patients, reporting 5% dural tear, 2.1% residual disc herniation, 1.5% recurrence, wrong level 0.5%, and 0.5% infection rate.<sup>32</sup>

Advances in instrumentation and the use of a working sheath have given endoscopic spine a promising future in minimally invasive spine procedures as the requirement for removal of bone, long incisions, and increased blood loss are eliminated in this procedure.

Another major advantage in endoscopic spine surgery is the use of only local anesthesia that keeps the patient always awake during surgery and the patient himself can guide us away from the root to avoid any root injury. Studies also show a high rate of anxiety in patients undergoing spine surgery under general anesthesia.<sup>33</sup>

The prospective collection of data and limited loss to follow-up was the biggest strength in our study. Even though

we had no control group to compare it to, our aim was to show how effective endoscopic spine surgery is in lumbar disc disease.

## Conclusion

We can finally conclude to the fact that endoscopic spine surgery in lumbar disc disease is highly effective and can deliver a good functional outcome if done with correct preoperative planning and approach. We also had an exceptionally low complication rate, corresponding to further implementation of endoscopic spine surgery all around the world. The only disadvantage is the steep learning curve. Endoscopic spine surgery under local anesthesia can be considered the gold standard in the treatment of lumbar disc disease.

### Note

The paper was presented at IOA – CON 2021, organized by the Indian Orthopaedics Association, held in Goa, India, between December 21 and 25, 2021.

### Conflict of Interest

None declared.

## References

- Deyo RA, Weinstein JN. Low back pain. *N Engl J Med* 2001;344(05):363–370
- Reisbord LS, Greenland S. Factors associated with self-reported back-pain prevalence: a population-based study. *J Chronic Dis* 1985;38(08):691–702
- Buckwalter JA. Aging and degeneration of the human intervertebral disc. *Spine* 1995;20(11):1307–1314
- Kirkaldy-Willis WH, Farfan HF. Instability of the lumbar spine. *Clin Orthop Relat Res* 1982;(165):110–123
- Spiliopoulou I, Korovessis P, Konstantinou D, Dimitracopoulos G. IgG and IgM concentration in the prolapsed human intervertebral disc and sciatica etiology. *Spine* 1994;19(12):1320–1323
- Arai Y, Yasuma T, Shitoto K, Yamauchi Y, Suzuki F. Immunohistological study of intervertebral disc herniation of lumbar spine. *J Orthop Sci* 2000;5(03):229–231
- Hatano E, Fujita T, Ueda Y, et al. Expression of ADAMTS-4 (aggrecanase-1) and possible involvement in regression of lumbar disc herniation. *Spine* 2006;31(13):1426–1432
- Kellgren JH. Referred pains from muscle. *BMJ* 1938;1(4023):325–327
- Weinstein SL, Buckwalter JA. *Turek's Orthopaedics: Principles and Their Application*. Philadelphia: Lippincott Williams & Wilkins; 2005
- Jordan J, Konstantinou K, O'Dowd J. Herniated lumbar disc. *Clin Evid* 2009;2009:1118
- Bono CM, Wisneski R, Garfin SR. Lumbar disc herniations. In: Herkowitz HN, Garfin SR, Eismont FJ, Bell GR, Balderston RA, eds. *The Spine*. 5th ed. Philadelphia, PA: Saunders; 2006
- Carragee E. Surgical treatment of lumbar disk disorders. *JAMA* 2006;296(20):2485–2487
- Deyo RA, Diehl AK, Rosenthal M. How many days of bed rest for acute low back pain? A randomized clinical trial. *N Engl J Med* 1986;315(17):1064–1070
- Malmivaara A, Häkkinen U, Aro T, et al. The treatment of acute low back pain—bed rest, exercises, or ordinary activity? *N Engl J Med* 1995;332(06):351–355
- Dandy WE, Peltier LF. Loose cartilage from intervertebral disk simulating tumor of the spinal cord. By Walter E. Dandy, 1929. *Clin Orthop Relat Res* 1989;238(238):4–8



- 16 Choi G, Pophale CS, Patel B, Uniyal P. Endoscopic Spine Surgery. [published correction appears in J Korean Neurosurg Soc. 2019 May;62(3):366] Korean Neurosurg Soc 2017;60(05):485–497
- 17 Sencer A, Yorukoglu AG, Akcakaya MO, et al. Fully endoscopic interlaminar and transforaminal lumbar discectomy: short-term clinical results of 163 surgically treated patients. World Neurosurg 2014;82(05):884–890
- 18 Nellensteijn J, Ostelo R, Bartels R, Peul W, van Royen B, van Tulder M. Transforaminal endoscopic surgery for lumbar stenosis: a systematic review. Eur Spine J 2010;19(06):879–886
- 19 Li Z, Hou S, Shang W, Song K, Zhao H. New instrument for percutaneous posterolateral lumbar foraminoplasty: case series of 134 with instrument design, surgical technique and outcomes. Int J Clin Exp Med 2015;8(09):14672–14679
- 20 Morgenstern R, Morgenstern C, Yeung AT. The learning curve in foraminal endoscopic discectomy: experience needed to achieve a 90% success rate. SAS J 2007;1(03):100–107
- 21 Li ZZ, Hou SX, Shang WL, Cao Z, Zhao HL. Percutaneous lumbar foraminoplasty and percutaneous endoscopic lumbar decompression for lateral recess stenosis through transforaminal approach: technique notes and 2 years follow-up. Clin Neurol Neurosurg 2016;143:90–94
- 22 Yeung AT, Tsou PM. Posterolateral endoscopic excision for lumbar disc herniation: Surgical technique, outcome, and complications in 307 consecutive cases. Spine 2002;27(07):722–731
- 23 Kondo M, Oshima Y, Inoue H, Takano Y, Inanami H, Koga H. Significance and pitfalls of percutaneous endoscopic lumbar discectomy for large central lumbar disc herniation. J Spine Surg 2018;4(01):79–85
- 24 Li X, Han Y, Di Z, et al. Percutaneous endoscopic lumbar discectomy for lumbar disc herniation. J Clin Neurosci 2016;33:19–27
- 25 Sairyo K, Chikawa T, Nagamachi A. State-of-the-art transforaminal percutaneous endoscopic lumbar surgery under local anesthesia: discectomy, foraminoplasty, and ventral facetectomy. J Orthop Sci 2018;23(02):229–236
- 26 Kraemer R, Wild A, Haak H, Herdmann J, Krauspe R, Kraemer J. Classification and management of early complications in open lumbar microdiscectomy. Eur Spine J 2003;12(03):239–246
- 27 Davis RA. A long-term outcome analysis of 984 surgically treated herniated lumbar discs. J Neurosurg 1994;80(03):415–421
- 28 Ahn Y, Lee SH, Park WM, Lee HY, Shin SW, Kang HY. Percutaneous endoscopic lumbar discectomy for recurrent disc herniation: surgical technique, outcome, and prognostic factors of 43 consecutive cases. Spine 2004;29(16):E326–E332
- 29 Gibson JN, Cowie JG, Ipreburg M. Transforaminal endoscopic spinal surgery: the future 'gold standard' for discectomy? - a review. Surgeon 2012;10(05):290–296
- 30 Chae KH, Ju CI, Lee SM, Kim BW, Kim SY, Kim HS. Strategies for noncontained lumbar disc herniation by an endoscopic approach: transforaminal suprapedicular approach, semi-rigid flexible curved probe, and 3-dimensional reconstruction CT with discogram. J Korean Neurosurg Soc 2009;46(04):312–316
- 31 Choi KC, Lee JH, Kim JS, et al. Unsuccessful percutaneous endoscopic lumbar discectomy: a single-center experience of 10,228 cases. Neurosurgery 2015;76(04):372–380, discussion 380–381, quiz 381
- 32 Kulkarni AG, Bassi A, Dhruv A. Microendoscopic lumbar discectomy: technique and results of 188 cases. Indian J Orthop 2014;48(01):81–87
- 33 Lee JS, Park YM, Ha KY, Cho SW, Bak GH, Kim KW. Preoperative anxiety about spinal surgery under general anesthesia. Eur Spine J 2016;25(03):698–707. Doi: 10.1007/s00586-015-3788-2. Epub 2015 Feb 11. PMID: 25670066