

Received: 2018.02.14

Accepted: 2018.04.03

Published: 2018.08.04

## Monoamine Oxidase B in Renal Cell Carcinoma

Authors' Contribution:  
Study Design A  
Data Collection B  
Statistical Analysis C  
Data Interpretation D  
Manuscript Preparation E  
Literature Search F  
Funds Collection G

ABCG 1 **Ingrid Hodorová**  
ABDG 1 **Silvia Rybárová**  
ADG 2 **Peter Solár**  
CD 3 **Marián Benický**  
BDF 4 **Dušan Rybár**  
BD 1 **Zuzana Kováčová**  
CEF 1 **Jozef Mihalik**

1 Department of Anatomy, P.J. Šafárik University, Faculty of Medicine, Košice, Slovak Republic  
2 Department of Medical Biology, P.J. Šafárik University, Faculty of Medicine, Košice, Slovak Republic  
3 Department of Pathology, P.J. Šafárik University, Faculty of Medicine, Košice, Slovak Republic  
4 Department of Anesthesiology and Intensive Medicine, P.J. Šafárik University, Faculty of Medicine and VUSCH a.s., Košice, Slovak Republic

**Corresponding Author:** Jozef Mihalik, e-mail: [jozef.mihalik@upjs.sk](mailto:jozef.mihalik@upjs.sk)

**Source of support:** This work was supported by following grants: VEGA 1/0204/16, VEGA 1/0394/15 and KEGA 019 UPIŠ-4/2017

**Background:** Studies on monoamine oxidase B (MAO-B) expression in renal cell carcinoma (RCC) are lacking. This study focused on the immunohistochemical evaluation of MAO-B in RCC.


**Material/Methods:** Sixty-three RCC samples were compared on basic clinical and histopathological parameters, including histopathological type and tumor grade. RCC samples were divided according to the histopathological type into 2 groups: conventional type (51 samples) and other types (12 samples). For MAO-B detection, a standard immunohistochemical procedure was employed.

**Results:** In healthy kidney samples, MAO-B was detected predominantly in tubules. Fifty-two cancer tissue samples were MAO-B negative and 11 tissue samples were MAO-B low positive. Enzymes were detected only in the cytoplasm. We did not find any significant correlation between the percentage of positive MAO-B specimens and nuclear grade. Additionally, Fisher's test did not reveal any difference in numbers of positive and negative MAO-B samples between the 2 RCC types ( $P>0.05$ ).

**Conclusions:** From our results, it was clear that MAO-B expression played no significant role in stimulation of renal cancer development. We found that MAO-B occurred only in 19% of kidney tumors and that the positivity of protein expression was low. Moreover, it seems that the disappearance of this enzyme in RCC is a consequence of replacement of healthy tissue by cancer cells. On the other hand, one can assume that the loss of MAO-B expression could be associated with severe pathological processes in the kidney.

**MeSH Keywords:** **Carcinoma, Renal Cell • Immunohistochemistry • Monoamine Oxidase**

**Full-text PDF:** <https://www.medscimonit.com/abstract/index/idArt/909507>



1599



2



4



29



## Background

Many factors, such as intracellular signaling molecules and extracellular components, including cytokines, extracellular matrix and neurotransmitters, may affect cancer [1,2]. Monoamine oxidases (MAOs) are enzymes that catalyze the degradation of different monoamines by oxidative deamination. During this process, hydrogen peroxide, a major source of reactive oxygen species (ROS), is formed as a side-product [3]. ROS can predispose cellular DNA to damage and cause tumor initiation and progression [4]. Two isoenzymes, MAO-A and MAO-B, have been identified in mammals. Both are present on the outer mitochondrial membrane, but each isoenzyme has different substrate and inhibitor sensitivities. For example, MAO-A is involved in degradation of neurotransmitters such as serotonin and noradrenaline, while MAO-B predominantly catalyzes degradation of  $\beta$ -phenylethylamine. Dopamine is a common substrate for both isoenzymes [5].

In the human brain, isoenzyme A is found in catecholaminergic neurons while isoenzyme B is preferentially placed in glia and astrocytes [6]. These different localizations suggest that the 2 isoforms have different physiological functions. MAOs are related to psychiatric and neurological disorders, such as depression and Parkinson disease, respectively [7]. Among other roles, both MAO-A and MAO-B are major enzyme systems involved in the oxidative metabolism of xenobiotics, dietary amines, and drugs [8].

Recent evidence suggests a correlation between elevated MAO-A expression and high-grade renal cell carcinoma (RCC). The percentage of MAO-A positive samples progressively increases from 9% in grade 2 to 45% in grade 3. Moreover, high levels of MAO-A immunoreactivity in epithelial cells of proximal tubules in normal renal tissue has also been noted [9]. Thus, MAO-A inhibitors, which have served as antidepressants for many years, could have a new therapeutic role in reducing tumor growth [10] and/or protecting an organism from metastatic dissemination [11].

On the other hand, studies on MAO-B have focused mostly on its role in the central nervous system and in the development of neurodegenerative diseases [12]. Although MAO-B is also known to be expressed in renal tissues [13], its function in kidneys or the clinical implication of its expression in renal cancer have not been determined. To fill this gap, we decided to conduct research in this area; thus, the present study focused on immunohistochemical evaluation of the MAO-B in renal cancer.

**Table 1.** Characteristic of 63 patients with renal cell carcinoma.

No. of patients	(n=63)		
Sex	Female	26	(41%)
	Male	37	(59%)
Age	≤50	12	(19%)
	≥51	51	(81%)
Histopathological type	RCC – clear-cell type	51	(81%)
	RCC – papillary type	5	(8%)
	RCC – chromophobe type	3	(5%)
	RCC – multiloc. cystic type	1	(1.50%)
	RCC – sarcomatoid type	1	(1.50%)
	RCC – unclassified type	2	(3%)
Grade	1	20	(32%)
	2	32	(51%)
	3	11	(17%)
MAO-B expression	Positive	9	(14.20%)
	Negative	54	(85.80%)

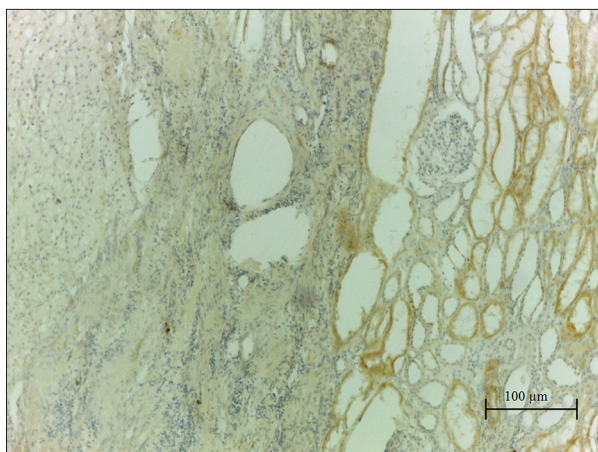
## Material and Methods

### Patients

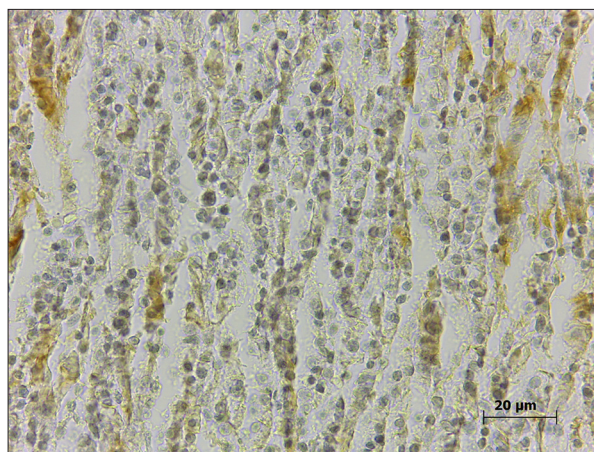
The Ethics Committee at the Šafárik University approved this research project, which conforms to the provision of the Declaration of Helsinki. In our work, we used 63 samples of different human RCC. Our results were compared to basic clinical and histopathological parameters such as histopathological type and tumor grade. We also compared MAO-B expression between normal and tumor tissue samples. Formalin-fixed and paraffin-embedded tissues were retrieved with informed consent from archive sources at the Department of Pathology, Pasteur Faculty Hospital, Košice, Slovak Republic. Patient and tumor characteristics are summarized in Table 1. RCC samples were divided according to the histopathological type into 2 groups: conventional type RCC (clear cell type) group, n=51 samples; and a group of other RCC types (5 papillary types, 3 chromophobe, 1 sarcomatoid, 1 multilocular cystic, and 2 unclassified), n=12 samples.

### Immunohistochemical detection of MAO-B

For MAO-B immunohistochemical detection, goat polyclonal primary antibody (B, LS-B2871, Biosciences) was used. After



**Figure 1.** Chromophobe type of renal cell carcinoma. The picture shows border between pathologically changed tissue without any MAO-B expression (left portion of specimen) and healthy kidney tissue, where MAO-B is detected predominantly in tubules (right part of specimen).



**Figure 2.** Papillary type of renal cell carcinoma. Low positivity of MAO-B protein is detected.

**Table 2.** MAO-B expression in samples of renal cell carcinoma (RCC). Fisher's test did not reveal any significant difference in numbers of positive and negative MAO-B samples from different RCC types.

	Negative	Low positive	Positive	High positive	Fisher's test
RCC – clear-cell type, n=51	41 (80.40%)	10 (19.60%)	0 (0%)	0 (0%)	p>0.05
RCC – other types, n=12	10 (83.33%)	2 (16.67%)	0 (0%)	0 (0%)	

dewaxing, 3-mm sections were washed in phosphate-buffered saline containing 0.05% Tween-20 (PBS-Tw, pH 7.6). Subsequently, the sections were treated by 0.3% H<sub>2</sub>O<sub>2</sub> in methanol for 10 minutes at room temperature (RT) to reduce endogenous peroxidase activity. The process continued with blocking nonspecific staining with normal blocking serum (1.5% blocking serum in PBS) for 30 minutes at RT, and primary antibody was applied overnight in humidified chamber at 4°C. After rinsing in PBS-Tw, the sections were subsequently incubated with the secondary antibody (ABC Staining System, Santa Cruz Biotechnology, Inc.) for 30 minutes at RT. The slides were washed with PBS-Tw, and the enzyme was visualized with 3,3'-diaminobenzidine tetrahydrochloride (DAB). Slides were counterstained with hematoxylin, washed in tap water, dried, mounted, and cover slipped. The immunohistochemical procedure was controlled by replacing primary antibody with PBS-Tw.

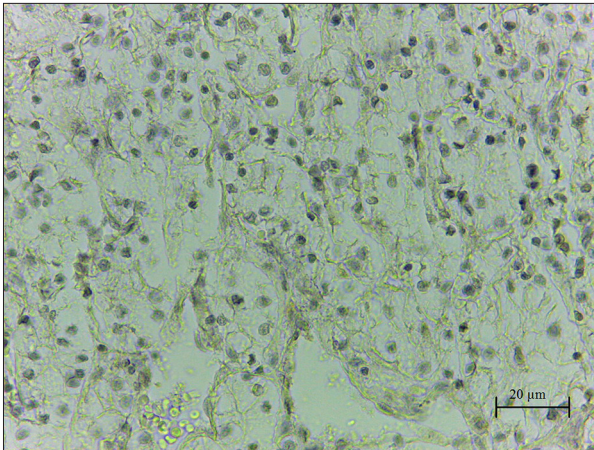
The results of the immunohistochemical staining were evaluated using light microscopy, as was described previously [14]. Briefly, the quantitative analysis of MAO-B in kidney cancer tissues was performed using ImageJ software accompanied by IHC profiler plugin developed by Varghese et al. [15]. Images from random fields were captured at 40× magnification using

a camera (Leica ICC50 HD) attached to a light microscope (Leica DM500), and software determined the score semi-quantitatively as negative, low positive, positive, or high positive.

## Results

MAO-B was detected in glomeruli of a healthy kidneys, predominantly in tubules (Figure 1). Details describing MAO-B expression in RCC are illustrated in Table 2. Twelve tissue samples (19.05%) were MAO-B positive (Figure 2) and 51 tissue samples (80.95%) were MAO-B negative (Figure 3). MAO-B was detected only in cytoplasm of cells, and no nuclear reaction for MAO-B protein was observed in any of analyzed specimens.

We did not find any significant correlation between the percentage of MAO-B positive tumor samples and nuclear grade in RCC. Linear regression formula describing such relation is  $y=1.59x+13.09$ ,  $r^2=0.89$ . Overall, 15.60% of samples were MAO-B positive in grade 2 while 18.18% of samples were MAO-B positive in grade 3. From this equation, only a nonsignificant moderate increment in the number of MAO-B positive samples was detected. The value of MAO-B reactive samples was kept at approximately the same level, regardless of



**Figure 3.** Conventional type of renal cell carcinoma without any MAO-B expression.

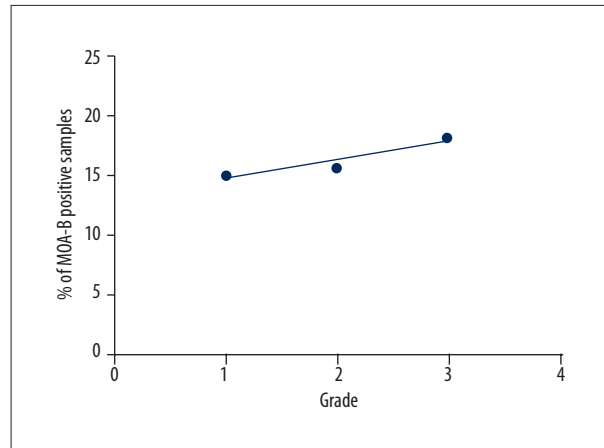
nuclear grade of RCC (Figure 4). Additionally, Fisher's test did not reveal any significant difference in the numbers of positive and negative MAO-B samples between RCC clear cell type and other RCC types of renal cancers ( $P>0.05$ ,  $P=1$ ).

## Discussion

The primary finding of our study was that MAO-B occurred only in 19% of kidney tumors and that the positivity of protein expression was low. We did not find any significant correlation between percentage of MAO-B positive tumor samples and nuclear grade in both RCC clear type and other RCC types. Moreover, our study did not reveal a significant difference in the number of positive and negative MAO-B samples in different types of renal cancers.

MAO activity in the kidney is among the highest [16,17]. In humans, both MAO-A and MAO-B have been detected in the renal cortex and medulla [18]. Proximal tubule cells are the main source of dopamine that are synthesized from circulating and/or filtered L-DOPA, a direct precursor of dopamine [19]. It is known that dopamine is one of the major factors regulating sodium re-absorption in the renal proximal tubule [20,21], and MAO-A, not MAO-B, has been detected as the predominant enzyme involved in the deamination of this natriuretic neurotransmitter in the kidney [22].

In addition to their role in the control of substrate availability, MAOs may participate in the regulation of renal cell functions through the generation of hydrogen peroxide. It has been shown that in intact rat renal proximal tubule cells, hydrogen peroxide produced by MAO-B during dopamine and tyramine degradation induces sequential extracellular signal-regulated kinase ERK activation and cell proliferation [23]. These data suggest that monoamine oxidases may play a critical role in



**Figure 4.** Linear regression between% of MAO-B positive samples and nuclear grade in renal cell carcinoma specimens.

the regulation of cell growth and repair processes, and they may also be involved in proliferative diseases in the kidney.

The relationship between MAO-B and cancers has rarely been mentioned. For example, in oral cancer tissue, unlike adjacent noncancerous tissue, the protein expression of the MAO-B gene exhibits downregulation, and this performance is consistent with decreased MAO-B mRNA levels [24]. On the other hand, the mRNA and protein expressions of MAO-B are higher in non-small cell lung cancer (NSCLC) cells than in normal lung cells. MAO-B further increases dose-dependently by ionizing radiation, and it is responsible for increased radioresistance of lung cancer cells. From this perspective, application of MAO-B inhibitors could be a new promising treatment for radioresistant lung cancer [25]. Similarly, the levels of MAO-B are, on average, 8 times higher in gliomas than in control tissue [26] and MAO-B levels correlate with glioma tumor grade [27]. Human gliomas exhibit significant and selective increases in MAO-B activity compared to other types of common brain tumors, such as meningiomas or non-tumor-bearing brain tissues [28]. This characteristic presents a distinct opportunity for rational drug design, using MAO-B as a catalyst for converting a non-toxic pro-drug into a mature chemotherapeutic [27].

In general, MAO-B generates hydrogen peroxide. High basal rates of ROS generation, mostly hydrogen peroxide, were also found in gliomas. MAO-B increases peroxide levels, peroxide facilitates the repression of transcription factor Sp3 and Sp1 upregulation, and these events ultimately increase MAO-B expression. A very similar function of MAO-A in prostate cancer has been recently suggested. It was found that MAO-A generated  $H_2O_2$  to induce proliferation, invasiveness, and metastasis of prostate cancer cells [29]. Subsequent experiments should try to examine whether there is a correlation between MAO-B expression and levels of ROS in renal cancer.

## Conclusions

Data suggest that MAO-B expression decreased in several cancer types while in other specific types, MAO-B expression increased, which has possible therapeutic implications in MAO-B inhibitors administration. From our results, it was clear that renal cancers belong to the first group, where elevated MAO-B expression plays no significant role in pathogenesis of this disease, probably because in the kidney, MAO-A is the more active enzyme that probably plays a more important role in physiological conditions compared to MAO-B. A significant correlation between elevated MAO-A expression and high-grade tumors of RCC confirms this finding [9]. On the other hand, no

such correlation exists between renal cancers and MAO-B, as was demonstrated in our study. To our knowledge, this is the first study on MAO-B expression and renal cell cancer.

## Acknowledgements

Authors thank Diana Gagyiová and Ivana Čigašová-Perúnska for their excellent technical help.

## Conflict of interest

None.

## References:

- Zender L, Vilaneuva A, Towar V et al: Cancer gene discovery in hepatocellular carcinoma. *J Hepatol*, 2010; 52: 921–29
- Minquez B, Hoshida Y, Vilaneuva A et al: Gene-expression signature of vascular invasion in hepatocellular carcinoma. *J Hepatol*, 2011; 55: 1325–31
- Shih JC, Wu JB, Chen K: Transcriptional regulation and multiple functions of MAO genes. *J Neural Transm (Vienna)*, 2011; 118: 979–86
- Trachootham D, Alexandre J, Huang P: Targeting cancer cells by ROS-mediated mechanisms: a radical therapeutic approach? *Nat Rev Drug Discov*, 2009; 8: 579–91
- Westlund KN, Denney RM, Rose RM, Abell CW: Localization of distinct monoamine oxidase A and monoamine oxidase B cell populations in human brainstem. *Neuroscience*, 1988; 25: 439–56
- Riederer P, Konradi C, Schay V et al: Localization of MAO-A and MAO-B in human brain: A step in understanding the therapeutic action of L-doprenyl. *Adv Neurol*, 1987; 45: 111–18
- Mallajosyula JK, Kaur D, Chinta SJ et al: MAO-B elevation in mouse brain astrocytes results in Parkinson's pathology. *PLoS One*, 2008; 20: e1616
- Strolin Benedetti M, Tipton KF, Whomsley R: Amine oxidases and monoxygenases in the *in vivo* metabolism of xenobiotic amines in humans: Has the involvement of amine oxidases been neglected? *Fundam Clin Pharmacol*, 2007; 21: 467–80
- Hodorová I, Rybářová S, Vecanová J et al: Comparison of expression pattern of monoamine oxidase A with histopathologic subtypes and tumour grade of renal cell carcinoma. *Med Sci Monit*, 2012; 18: BR482–86
- Wu JB, Lin TP, Gallagher JD et al: Monoamine oxidase A inhibitor-near-infrared dye conjugate reduces prostate tumor growth. *J Am Chem Soc*, 2015; 137: 2366–74
- Ferrarelli LK: Antidepressants protect bones from metastatic prostate cancer. *Sci Signal*, 2017; 10: eaan2866
- Naoi M, Maruyama W, Inaba-Hasegawa K: Type A and B monoamine oxidase in age-related neurodegenerative disorders: Their distinct roles in neuronal death and survival. *Curr Top Med Chem*, 2012; 12: 2177–88
- Sivasubramaniam SD, Finch CC, Rodriguez MJ et al: A comparative study of the expression of monoamine oxidase-A and -B mRNA and protein in non-CNS human tissues. *Cell Tissue Res*, 2003; 313: 291–300
- Mohammed AT, Mohamed AA, Ali H: Pulmonary apoptotic and oxidative damaging effects of Triclosan alone or in combination with Fluoride in Sprague Dawley rats. *Acta Histochem*, 2017; 119: 357–63
- Varghese F, Bukhari AB, Malhotra R, De A: IHC Profiler: An open source plugin for the quantitative evaluation and automated scoring of immunohistochemistry images of human tissue samples. *PLoS One*, 2014; 9: e96801
- Saura J, Kettler R, Da Prada M, Richards JG: Quantitative enzyme radioautography with 3H-Ro 41-1049 and 3H-Ro 19-6327 *in vitro*: Localization and abundance of MAO-A and MAO-B in rat CNS, peripheral organs, and human brain. *J Neurosci*, 1992; 12: 1977–99
- Fowler JS, Logan J, Wang GJ et al: PET imaging of monoamine oxidase B in peripheral organs in humans. *J Nucl Med*, 2002; 43: 1331–38
- Saura J, Nadal E, van den Berg B et al: Localization of monoamine oxidases in human peripheral tissues. *Life Sci*, 1996; 59: 1341–49
- Vindis C, Séguélas MH, Lanier S et al: Dopamine induces ERK activation in renal epithelial cells through H<sub>2</sub>O<sub>2</sub> produced by monoamine oxidase. *Kidney Int*, 2001; 59: 76–86
- Hubbard PC, Henderson IW: Renal dopamine and the tubular handling of sodium. *J Mol Endocrinol*, 1995; 14: 139–55
- Aperia AC: Intrarenal dopamine: A key signal in the interactive regulation of sodium metabolism. *Annu Rev Physiol*, 2000; 62: 621–47
- Guimarães JT, Soares-da-Silva P: The activity of MAO A and B in rat renal cells and tubules. *Life Sci*, 1998; 62: 727–37
- Vindis C, Séguélas MH, Bianchi P et al: Monoamine oxidase B induces ERK-dependent cell mitogenesis by hydrogen peroxide generation. *Biochem Biophys Res Commun*, 2000; 271: 181–85
- Chen PH, Huang B, Shieh TY et al: The influence of monoamine oxidase variants on the risk of betel quid-associated oral and pharyngeal cancer. *Scientific World Journal*, 2014; 2014: 183548
- Son B, Jun SY, Seo H et al: Inhibitory effect of traditional oriental medicine-derived monoamine oxidase B inhibitor on radioresistance of non-small cell lung cancer. *Sci Rep*, 2016; 6: 21986
- Sharpe MA, Baskin DS: Monoamine oxidase B levels are highly expressed in human gliomas and are correlated with the expression of HIF-1 $\alpha$  and with transcription factors Sp1 and Sp3. *Oncotarget*, 2016; 7: 3379–93
- Sharpe MA, Livingston AD, Gist TL et al: Successful treatment of intracranial glioblastoma xenografts with a monoamine oxidase B-activated prodrug. *EBioMedicine*, 2015; 2: 1122–32
- Gabilondo AM, Hostalot C, Garibi JM et al: Monoamine oxidase B activity is increased in human gliomas. *Neurochem Int*, 2008; 52: 230–34
- Wu JB, Shao C, Li X et al: Monoamine oxidase A mediates prostate tumorigenesis and cancer metastasis. *J Clin Invest*, 2014; 124: 2891–908