

Analysis of Sacrococcygeal Morphology in Koreans Using Computed Tomography

Min Geun Yoon, MD, Myung-Sang Moon, MD, Bong Keun Park, MD,
Hohyoung Lee, MD, Dong-Hyeon Kim, MD

Department of Orthopedic Surgery and Traumatology, Cheju Halla General Hospital, Jeju, Korea

Background: The sacrococcygeal morphology of Arabs and Europeans has been studied using computed tomography (CT) or magnetic resonance imaging to determine the cause of coccydynia. Studies have suggested differences in sacrococcygeal morphology among ethnic groups. However, there are no data on the sacrococcygeal anatomy of Koreans.

Methods: We conducted a retrospective analysis of 606 pelvic CT scans that were taken at Cheju Halla General Hospital between 2008 and 2014. Fractures of the sacrum or coccyx were excluded. Differences in the sacrococcygeal morphology among age groups stratified by decade of life and between genders were analyzed using sagittal plane pelvic CT scans. The morphological parameters studied were the sacral and coccygeal curved indexes, sacrococcygeal angle, intercoccygeal angle, coccygeal type, coccygeal segmental number, and sacrococcygeal fusion.

Results: The average sacral and coccygeal curved indexes were 6.15 and 7.41, respectively. The average sacrococcygeal and intercoccygeal angles were 110° and 49°, respectively. Type II coccyx was most common, and the rate of sacrococcygeal fusion was 34%. There was a moderate positive correlation between age and the sacral curved index ($r = 0.493$, $p = 0.000$) and a weak negative correlation between age and the coccyx curved index ($r = -0.257$, $p = 0.000$). There was a weak negative correlation between age and the intercoccygeal angle ($r = -0.187$, $p = 0.000$). The average intercoccygeal angle in males and females was 53.9° and 44.7°, respectively.

Conclusions: The sacrum tended to be more curved and the coccyx straighter with age. The coccyx was straighter in females than males. Knowledge of the sacrococcygeal anatomy of Koreans will promote better understanding of anatomical differences among ethnicities and future studies on coccydynia.

Keywords: Coccyx, Sacrum, Morphology, Koreans, Computed X-ray tomography

The coccyx, or tailbone, is the most distal segment of the spine. Although the coccyx is a rudimentary structure, the levator ani, iliococcygeus muscle, and several ligaments are attached to the structure. These muscle and ligament structures support the pelvic floor and contribute to voluntary movement.

Pain can develop around the coccyx, which is referred to as coccydynia or coccygodynia. Numerous studies have suggested the causes of the pain.¹⁻¹²⁾ Coccydynia can result from external trauma; repetitive minor trauma such as prolonged sitting on hard, uncomfortable surfaces; and internal trauma during childbirth.¹⁻¹²⁾ Other causes such as local tumor, inflammation, disc degeneration, and idiopathy, have also been proposed. It is well known that females have a 4 to 5 times higher incidences of coccydynia than men.¹⁰⁾ Although the cause of the higher incidences of coccydynia in females has not been elucidated, most authors attributed it to differences in the morphology and mobility of the sacrococcygeal segments between males

Received June 27, 2016; Accepted August 8, 2016

Correspondence to: Hohyoung Lee, MD

Department of Orthopedic Surgery and Traumatology, Cheju Halla General Hospital, 65 Doryeong, Jeju 63127, Korea

Tel: +82-64-740-5410, Fax: +82-64-743-3110

E-mail: mingy9879@gmail.com

Copyright © 2016 by The Korean Orthopaedic Association

This is an Open Access article distributed under the terms of the Creative Commons Attribution Non-Commercial License (<http://creativecommons.org/licenses/by-nc/4.0>) which permits unrestricted non-commercial use, distribution, and reproduction in any medium, provided the original work is properly cited.

Clinics in Orthopedic Surgery • pISSN 2005-291X eISSN 2005-4408

and females.^{6,13-16)}

Postacchini and Massobrio⁵⁾ suggested a radiologic classification of the coccyx and described the relationship between the coccygeal type and pain. There have been several articles on the morphology and morphometry of the sacrococcygeal region in Arabs and Europeans using computed tomography (CT) or magnetic resonance imaging (MRI).¹³⁻¹⁵⁾ However, to the best of our knowledge, there has been no previous study on the coccygeal morphology in Asian ethnicities. In this study, we investigated the morphology and morphometry of sacrococcygeal anatomy of Koreans using CT and compared morphologic differences among ethnic groups.

METHODS

This study was conducted on patients who had a pelvic or sacral CT in a single hospital between 2008 and 2014. Patients with a sacral fracture, a coccyx fracture, or a deformed sacrum due to tumor or infection were excluded. A total of 606 CT scans were available for the analysis. A 128-slice multidetector CT scanner (iCT 128 scanner; Philips, Cleveland, OH, USA) was used for the study. Digital images of the lumbosacral junction and the whole coccyx were obtained with the PACS system (STARPACS5081; INFINTT Healthcare, Seoul, Korea). CT was taken with all patients in the supine position.

The qualitative and quantitative parameters of the sacrococcygeal anatomy were assessed. The definitions of these parameters are presented in Table 1.¹³⁻¹⁵⁾ The type of coccyx was determined based on the classification proposed by Postacchini and Massobrio.⁵⁾ Their classification was modified on the basis of the angle between a line drawn from the first coccygeal segment to the tip of the last coccygeal segment and a vertical line on the CT scan referring to the horizontal line of the supine position. If the angle was larger than 30°, the coccyx type was type II; if it was less than 30°, the coccyx type was type I. The morphological parameters were sacrococcygeal fusion, the coccygeal segmental number, and the coccygeal type (Fig. 1). The morphometric parameters were the sacral and coccygeal curved indexes and the sacrococcygeal and intercoccygeal angles (Table 1 and Fig. 2). The age- and gender-matched differences of these parameters were analyzed. Cases with sacrococcygeal fusion cases, those parameters were not assessed to avoid confusing the sacrococcygeal junction's location. Sacrococcygeal fusion was defined as continuation of the anterior and posterior cortices between the sacrum and the coccyx. However, there could be the possibility of sacralization of the first coccygeal segment. Since it was not feasible to differentiate sacrococcygeal fusion from sacralization of the first coccygeal segment, sacralization cases were also considered as sacrococcygeal fusion cases.

Two orthopedic surgeons measured the parameters

Table 1. Parameters of Sacrococcygeal Anatomy and Definition of Each Parameter

Parameter	Definition of parameter
Morphology	
1. No. of coccygeal segment	Unfused segment(s) of the coccyx
2. Type of coccyx*	Type 1: slightly curved coccyx pointing downwards
	Type 2: more curved coccyx pointing forwards
	Type 3: sharply angulated at intercoccygeal joint
	Type 4: subluxation at the sacrococcygeal or first intercoccygeal joint
	Type 5: retroversion of the coccyx
3. Fusion of sacrococcygeal joint*	Continuation of the anterior and posterior cortices between the sacrum and the coccyx
Morphometry	
1. Curved index of coccyx and sacrum*	100 – (straight length divided by curved length × 100)
2. The sacrococcygeal angle*	The angle between a line from the midpoint of the S1 upper endplate to the midpoint of the S5 lower endplate and a line from the midpoint of the S5 lower endplate to the tip of the last coccygeal segment
3. The intercoccygeal angle*	The angle between an intersecting line of the first coccygeal segment and an intersecting line of the last two coccygeal segments

*The parameters and definitions are derived from previous reports.¹³⁻¹⁵⁾

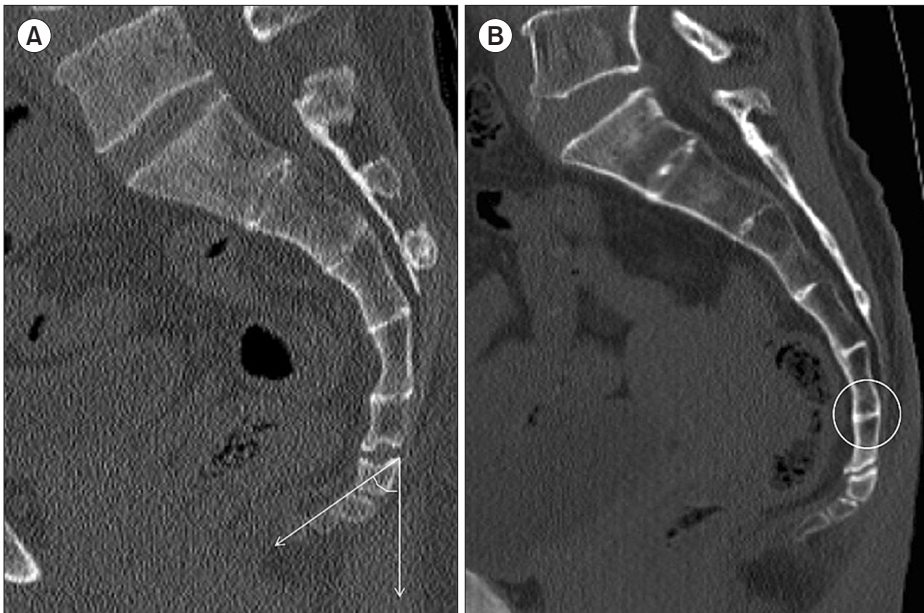


Fig. 1. Computed tomography images showing morphology of the sacrococcygeal region. (A) The coccygeal type is classified according to the angle between a line from the center of the first coccygeal segment to the tip of the last coccygeal segment and a vertical line. (B) Sacrococcygeal fusion (circle) is noted.

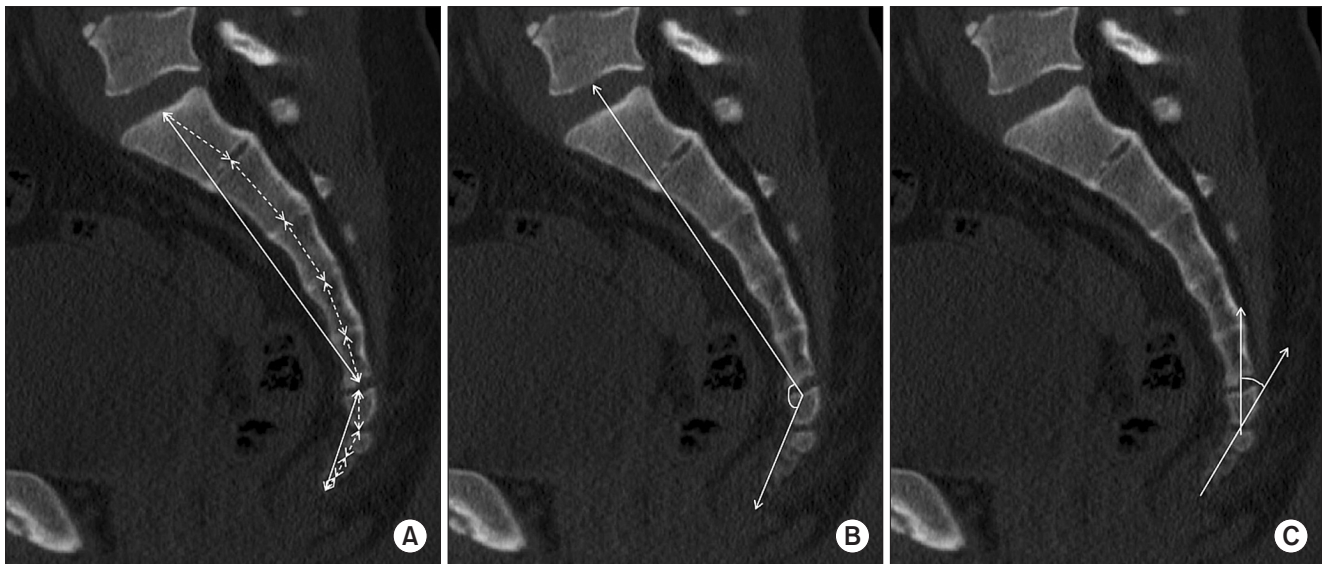


Fig. 2. Computed tomography images for morphometry of the sacrococcygeal region. (A) Straight (solid line) and curved (dotted line) lengths of each sacrum and coccyx. (B) Sacrococcygeal angle. (C) Intercoccygeal angle.

twice, with a 2-week interval between measurements. Averages of the parameters were used for statistical analysis.

Statistical Analysis

Data analysis was performed using SPSS ver. 19 (IBM Co., Armonk, NY, USA). The most common type of coccyx, the number of coccygeal segments, the average of the sacral and coccygeal curved indexes, and the sacrococcygeal and intercoccygeal angles of Koreans were assessed.

The correlation between the sacral curved index and age (stratified by decade) was analyzed using Spearman correlation. The correlations of the coccygeal curved index, sacrococcygeal angle, and intercoccygeal angle among patients in each decade of life were analyzed using the same method. Spearman correlation coefficient (r) was interpreted as poor if < 0.30 , fair if $0.31-0.50$, moderate if $0.51-0.60$, moderately strong if $0.61-0.80$, and very strong if > 0.80 . The differences in the sacrococcygeal morphom-

etry between males and females were analyzed using an independent *t*-test. The sacrococcygeal fusion rate, the number of coccygeal segments, and coccygeal type according to the decade of age were analyzed using linear-by-linear association. The difference in the sacrococcygeal fusion rate between males and females was analyzed using a chi-square test.

An intraclass correlation coefficient (ICC) was calculated to assess the intraobserver and interobserver reliability. The reliability was determined by repeating the measurements in 30 subjects two weeks after the initial measurement, using CT scans. A *p*-value less than 0.05 was considered statistically significant.

This study was approved by the Institutional Review Board of the Cheju Halla General Hospital.

RESULTS

A total of 248 males (40.9%) and 358 females (59.1%) were included in this study. The average age of the subjects was 55.5 years (range, 16 to 97 years). The number of subjects in each age group stratified by decade of life was 27 in the second, 74 in the third, 77 in the fourth, 64 in the fifth, 98 in the sixth, 79 in the seventh, 107 in the eighth, and 80 in the ninth and tenth decades of life (Table 2).

Coccygeal Morphology

The most common type of coccyx among Korean patients was type II (51%), followed by type I (27.4%). Types III, IV, and V were 14.7%, 4.5%, and 0.2%, respectively. There was no significant difference in the coccygeal type between males and females (*p* = 0.126). However, the rate of

type II compared with other types was significantly higher in females than males (54.7% vs. 45.6%, *p* = 0.032) (Table 3). The coccygeal type was significantly different among the age groups (*p* = 0.015): the type I ratio increased in the eighth-decade (29.9%) and ninth and tenth decades (40%) compared with the averages in the other decades (27.4%) (Table 4). The numbers of coccygeal segments were not significantly different between gender (*p* = 0.231) (Table 3). However, there was a weak negative correlation between the number of coccygeal segments and the age (*r* = -0.112, *p* = 0.007) (Table 4). Four coccygeal segments were the most common and present in 379 of individuals (64.8%), followed by three segments in 169 (28.9%).

The sacrococcygeal fusion rate significantly increased in the eighth (38.3%) and ninth and tenth (46.3%) decades compared with the other decades (average, 33.4%; *p* = 0.02) (Table 4). The sacrococcygeal fusion rate was not significantly different between genders, except in the ninth and tenth decades (*p* = 0.283) (Tables 3 and 4). These subjects were excluded from the analysis due to the very small number of males (8) compared with females (71).

Coccygeal Morphometry

The mean straight lengths of the coccyx and sacrum were 34.7 mm and 108.3 mm, respectively, while the mean curved lengths were 37.6 mm and 115.3 mm, respectively.

Table 2. The Number of Subjects at Each Decade for This Study

Decade	Male	Female	Total
2nd	17 (63)	10 (37)	27
3rd	37 (50)	37 (50)	74
4th	47 (61)	30 (39)	77
5th	33 (52)	31 (48)	64
6th	50 (51)	48 (49)	98
7th	32 (41)	47 (59)	79
8th	24 (22)	83 (78)	107
9th–10th	8 (10)	72 (90)	80
Total	248 (41)	358 (59)	606

Values are presented as number (%).

Table 3. Morphologic Differences between Male and Female

Variable	Male	Female	<i>p</i> -value
No. of coccygeal segment(s)			0.231
5	12 (5)	7 (2)	
4	158 (66.1)*	221 (63.9)*	
3	63 (26.4)	106 (30.6)	
2	5 (2.1)	11 (3.2)	
1	1 (0.4)	1 (0.3)	
Coccyx type			0.126
I	67 (27)	99 (27.7)	
II	113 (45.6)*	196 (54.7)*	
III	46 (18.5)	43 (12)	
IV	14 (5.6)	13 (3.6)	
V	1 (0.4)	0	
Sacrococcygeal fusion	66 (27.5)	97 (33.9)	0.283

*Four coccygeal segments and type II coccyx were most common in Koreans.

Table 4. Morphologic Differences among Decades

Variable	Decade								p-value
	2nd	3rd	4th	5th	6th	7th	8th	9th–10th	
No. of coccygeal segments									0.007
4	21 (84.0)	50 (68.5)	39 (52.0)	45 (77.6)	59 (62.1)	53 (68.8)	63 (61.2)*	49 (62.0)*	
3	3 (12.0)	21 (28.8)	29 (38.7)	9 (15.5)	28 (29.5)	23 (29.9)	38 (36.9)	18 (22.8)	
Type									0.015
II	14 (51.9)	34 (45.9)	38 (49.4)	29 (45.3)	51 (52.0)	48 (60.8)	57 (53.3)	38 (47.5)	
I	6 (22.2)	14 (18.9)	16 (20.8)	16 (25.0)	29 (29.6)	21 (26.6)	32 (29.9)*	32 (40.0)*	
Sacrococcygeal fusion	2 (7.4)	22 (29.7)	28 (36.4)	17 (26.6)	31 (31.6)	22 (27.8)	41 (38.3)*	37 (46.3)*	0.02

Values are presented as number (%).

*Over 8th decade, rate of four coccygeal segments decreased and rate of type I and sacrococcygeal fusion increased.

Table 5. Morphometric Differences between Genders and among Decades

Variable	Between genders			Among decades	
	Male	Female	p-value	p-value	Pearson correlation (r)
Curved index of coccyx	8.89 ± 6.05*	6.26 ± 4.99	0.000	0.000	-0.257
Curved index of sacrum	5.28 ± 2.65	6.83 ± 3.8*	0.000	0.000	0.493
Sacrococcygeal angle (°)	110.5 ± 11.8	108.9 ± 12.5	0.201	0.000	0.210
Intercoccygeal angle (°)	53.9 ± 20	44.7 ± 21.6*	0.000	0.000	-0.187

*The coccyx was more curved and the sacrum was straighter in males than females.

The mean curved indexes of the coccyx and sacrum were 7.41 and 6.15, respectively. The average sacrococcygeal and intercoccygeal angles were 110° and 49°, respectively. The curved index of the sacrum increased with age, showing a fair positive correlation ($r = 0.493$, $p = 0.000$), while the curved index of the coccyx decreased with age, showing a weak negative correlation ($r = -0.257$, $p = 0.000$). As the age increased, the sacrococcygeal angle increased, showing a weak positive correlation ($r = 0.21$, $p = 0.000$), while the intercoccygeal angle decreased, showing a weak negative correlation ($r = -1.87$, $p = 0.000$). As the age increased, the sacral curved index became larger and the sacrococcygeal angle increased, while the coccygeal curved index and intercoccygeal angle decreased (Table 5 and Fig. 3). There were significant differences in the curved indexes of the coccyx and sacrum between genders. The mean coccygeal curved index was larger in males (8.89) than females (6.26, $p = 0.000$), while the mean sacral curved index was smaller in males (5.28) than females (6.83, $p = 0.000$). The mean sacrococcygeal angle was not significantly different be-

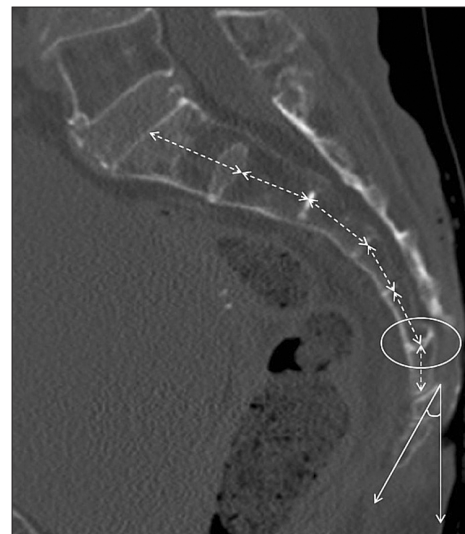


Fig. 3. In a 92-year-old female patient, the sacrum is curved (dotted line) and the coccyx is straight. Type I coccyx (angle) and sacrococcygeal fusion (circle) are noted.

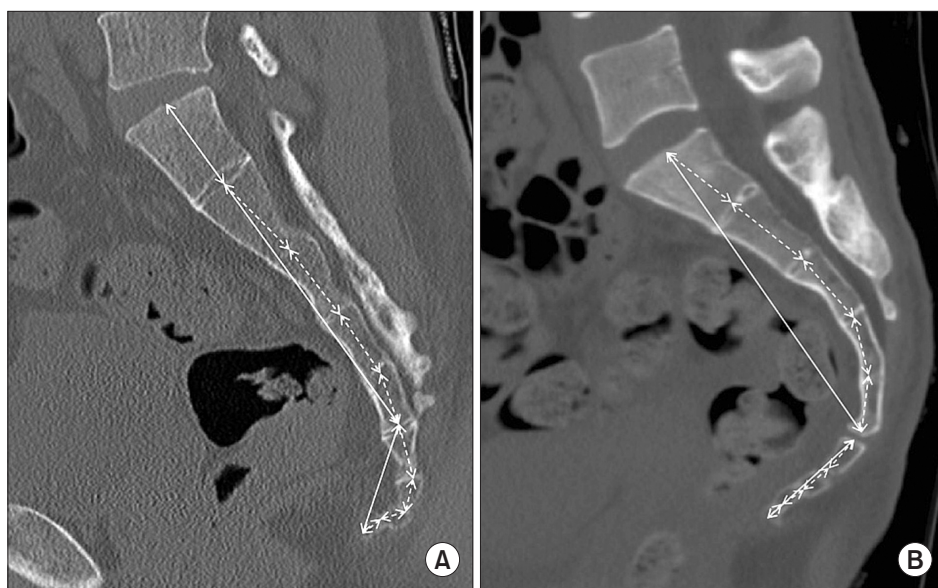


Fig. 4. Differences in sacrococcygeal anatomy between a male (A) and a female (B). In the female, the sacrum is more curved and the coccyx is straighter than in the male.

tween genders ($p = 0.201$), while the mean intercoccygeal angle was significantly larger in males than females (53.9° vs. 44.7° , $p = 0.000$). These results indicate that the coccyx was more curved and the sacrum was straighter in males than females (Table 5 and Fig. 4).

Reliability

Intra- and interobserver reliability were calculated with ICCs. The ICCs for intra- and interobserver reliability were 0.918 and 0.872, respectively, for all quantitative measurements. These results had almost perfect repeatability and reproducibility.

DISCUSSION

To the best of our knowledge, this study is the first to investigate the morphology and morphometry of the sacrococcygeal anatomy of Koreans and other Asians using CT. The most frequent number of coccygeal segments of Arabs was three¹³⁾ while that of Europeans was four.^{14,15)} In our study, four coccygeal segments were most common (64.8%). This difference in the number of coccygeal segments among ethnicities might be due to intercoccygeal or sacrococcygeal fusion. In this study, although sacrococcygeal fusion cases were excluded from the analysis, fusion of the third and fourth segments of the coccyx might have caused reduction in the number of segments. Occasional fusion of the second and third segments of the coccyx was also noted. The number of coccygeal segments might have been decreased due to the aging-related fusion of the intercoccygeal segment. The most common type of coccyx in this study was type II (51%) followed by type I (27.4%). In

Arabs and Europeans, except for one study,¹⁷⁾ type I coccyx was most common, followed by type II. This might be due to the fact that there are some ambiguous features in the classification of Postacchini and Massobrio,⁵⁾ especially between types I and II. For classification, we measured the angle created by a line drawn from the first coccygeal segment to the tip of the last coccygeal segment and a vertical line. The tip of the type I coccyx directed more downward. According to previous literature, types III and IV were more common in males, whereas there was no significant difference in the coccygeal type between genders in our study. However, type II was more common in females, and the tip of the coccyx directed more ventrally than in males as in other studies.¹³⁻¹⁵⁾ There was a significant difference in the coccygeal type among age groups in this study. Older patients (those in the eighth, ninth, or tenth decades) were more likely to have type I coccyxes, indicating a more downward position of the coccyx, than those in the seventh decade. Korean patients had similar coccyxes as those of Arabs.¹³⁾

The average fusion rate of the sacrococcygeal joint was 33.4%, similar to that of other studies.^{13-15,18)} Fusion of the sacrococcygeal joint was more common in older patients, especially those in the eighth, ninth or tenth decades, while there was no significant difference between males and females. For comparative study with regard to gender, the patients in the ninth and tenth decades were excluded due to the very small number of males. Some authors claimed that fusions are observed more frequently in elderly females^{19,20)} or occur later in women.²¹⁾ Some authors, however, insisted that the incidence of sacrococcygeal fusion is not simply a reflection of age or sex.²²⁾ In

our study, although gender was not an influencing factor, but age appeared to affect fusion rates. Older patients had sacrococcygeal fusion more frequently.

The straight and curved lengths of the sacrum and coccyx in males were larger than those in females. These results are similar to data in the literature.¹³⁻¹⁵⁾ However, the curved indexes of the sacrum and coccyx between males and females are controversial. In this study, females had straighter coccyxes and more curved sacra than males. These findings are similar to those in Europeans,^{14,15,23)} but different from those in Arabs.¹³⁾ There was no significant difference in the sacrococcygeal angle between genders, while the intercoccygeal angle was larger in males. The difference of the intercoccygeal angle between genders was also similar to Europeans, but different from Arabs. The coccyx of Arabs was more curved, with a larger intercoccygeal angle in females, suggesting that the anatomical features of females might predispose them to a higher risk of developing coccydynia.¹³⁾ Some authors reported that the intercoccygeal angle was a useful radiological measurement to evaluate the forwardly angulated deformity of the coccyx, and the intercoccygeal angle of the idiopathic coccygodynia group was greater.⁷⁾ Arabic females had more curved coccyxes and this feature was correlated with the prevalence of coccydynia, whereas in our study and European studies, females had straighter coccyxes and type II (more forwardly directed coccyx) was more common in females (Fig. 3). We could not determine the relationship between the coccygeal morphology (curvature or type) of females and coccygodynia. Several studies have disclosed that hypermobility of the coccygeal segment or a rigid coccyx with a predominant tip might be a possible cause of painful coccyx rather than the morphology.^{1,14,24)} Thus, the controversy on the relationship between coccygeal morphology and coccydynia remains unresolved.

In this study, as age increased, the sacral curved index and the sacrococcygeal angle also increased, while the coccygeal curved index and intercoccygeal angle decreased. The sacrum was more curved and the coccyx was straighter in older patients. Similar results were also found in Arabic coccygeal morphometry; however, this morphologic change was observed among those aged 50 years or older in Arabic subjects,¹³⁾ whereas it was seen in patients over 70 years of age in Korean subjects.

Although our patient cohort was reasonably large and the methodology was reliable, there are some limitations to this study. The first limitation is that we could not determine the relationship between the anatomical morphology of the sacrococcygeal region and coccydynia. In this study, the subjects were not divided by the presence or

absence of coccydynia, and we, therefore, could not assess the prevalence of coccydynia in these subjects. The second limitation was that the CT image was obtained with the patient placed in the supine position. A different coccygeal type may be observed when the patient stands due to a change in the pelvic tilt. However, we studied only the static sacrococcygeal morphology and previous reports also assessed the coccygeal type based on the images obtained in the supine position, which allowed for the comparison with previous studies on the coccygeal type. The third limitation was that CT scans could only show static sacrococcygeal morphology, and thus the mobility of the coccyx could not be evaluated.

The other anatomical features that can lead to coccygeal pain, spicule, subluxation, and ventral curve of the last segment of the sacrum were not analyzed in this study. Other factors, such as body mass index and obesity, could not be included to analyze other anatomical differences that could affect morphology.

In conclusion, we studied the morphology and morphometry of the sacrococcygeal anatomy in 606 Korean patients. Our patients had similarities and differences with other ethnic groups. The most common type of coccyx was type II and the average number of coccygeal segments was four. There were some differences in coccygeal anatomy between genders; females had a more curved sacrum and straighter coccyx than males. Females had type II coccyxes (ventrally forward coccyx) more frequently than males. However, it could not be determined whether the differences in sacrococcygeal anatomy would affect coccydynia that occurs more often in females.

The sacrococcygeal morphology changed with the aging process. When subjects were older, the sacrum tended to be more curved and the coccyx straighter, especially in patients over 70 years of age. In addition, the sacrococcygeal fusion rate increased in patients over 70 years of age. Knowledge of the sacrococcygeal anatomy of Koreans will improve understanding of the anatomical differences between ethnicities and facilitate future studies on coccydynia.

CONFLICT OF INTEREST

No potential conflict of interest relevant to this article was reported.

REFERENCES

- Maigne JY, Doursounian L, Chatellier G. Causes and mechanisms of common coccydynia: role of body mass index and coccygeal trauma. *Spine (Phila Pa 1976)*. 2000;25(23):3072-9.
- Lirette LS, Chaiban G, Tolba R, Eissa H. Coccydynia: an overview of the anatomy, etiology, and treatment of coccyx pain. *Ochsner J*. 2014;14(1):84-7.
- Patijn J, Janssen M, Hayek S, Mekhail N, Van Zundert J, van Kleef M. Coccygodynia. *Pain Pract*. 2010;10(6):554-9.
- Fogel GR, Cunningham PY 3rd, Esses SI. Coccygodynia: evaluation and management. *J Am Acad Orthop Surg*. 2004;12(1):49-54.
- Postacchini F, Massobrio M. Idiopathic coccygodynia: analysis of fifty-one operative cases and a radiographic study of the normal coccyx. *J Bone Joint Surg Am*. 1983;65(8):1116-24.
- Maigne JY, Pigeau I, Roger B. Magnetic resonance imaging findings in the painful adult coccyx. *Eur Spine J*. 2012;21(10):2097-104.
- Kim NH, Suk KS. Clinical and radiological differences between traumatic and idiopathic coccygodynia. *Yonsei Med J*. 1999;40(3):215-20.
- Nathan ST, Fisher BE, Roberts CS. Coccydynia: a review of pathoanatomy, aetiology, treatment and outcome. *J Bone Joint Surg Br*. 2010;92(12):1622-7.
- Woon JT, Stringer MD. Clinical anatomy of the coccyx: a systematic review. *Clin Anat*. 2012;25(2):158-67.
- Karadimas EJ, Trypsiannis G, Giannoudis PV. Surgical treatment of coccygodynia: an analytic review of the literature. *Eur Spine J*. 2011;20(5):698-705.
- Maigne JY, Lagauche D, Doursounian L. Instability of the coccyx in coccydynia. *J Bone Joint Surg Br*. 2000;82(7):1038-41.
- Mouhsine E, Garofalo R, Chevalley F, et al. Posttraumatic coccygeal instability. *Spine J*. 2006;6(5):544-9.
- Marwan YA, Al-Saeed OM, Esmaeel AA, Kombar OR, Bendaray AM, Azeem ME. Computed tomography-based morphologic and morphometric features of the coccyx among Arab adults. *Spine (Phila Pa 1976)*. 2014;39(20):E1210-9.
- Woon JT, Maigne JY, Perumal V, Stringer MD. Magnetic resonance imaging morphology and morphometry of the coccyx in coccydynia. *Spine (Phila Pa 1976)*. 2013;38(23):E1437-45.
- Woon JT, Perumal V, Maigne JY, Stringer MD. CT morphology and morphometry of the normal adult coccyx. *Eur Spine J*. 2013;22(4):863-70.
- Maigne JY, Tamalet B. Standardized radiologic protocol for the study of common coccygodynia and characteristics of the lesions observed in the sitting position: clinical elements differentiating luxation, hypermobility, and normal mobility. *Spine (Phila Pa 1976)*. 1996;21(22):2588-93.
- Przybylski P, Pankowicz M, Bockowska A, et al. Evaluation of coccygeal bone variability, intercoccygeal and lumbosacral angles in asymptomatic patients in multislice computed tomography. *Anat Sci Int*. 2013;88(4):204-11.
- Tague RG. Fusion of coccyx to sacrum in humans: prevalence, correlates, and effect on pelvic size, with obstetrical and evolutionary implications. *Am J Phys Anthropol*. 2011;145(3):426-37.
- Moore KL. Clinically oriented anatomy. 2nd ed. Baltimore, MD: Williams & Wilkins; 1985.
- Gray H, Williams PL, Warwick R. Gray's anatomy. 36th ed. Edinburgh: Churchill-Livingstone; 1980.
- Breathnach AS. Frazer's anatomy of the human skeleton. 6th ed. London: J & A Churchill; 1965.
- Saluja PG. The incidence of ossification of the sacrococcygeal joint. *J Anat*. 1988;156:11-5.
- Kerimoglu U, Dagoglu MG, Ergen FB. Intercoccygeal angle and type of coccyx in asymptomatic patients. *Surg Radiol Anat*. 2007;29(8):683-7.
- Balain B, Eisenstein SM, Alo GO, et al. Coccygectomy for coccydynia: case series and review of literature. *Spine (Phila Pa 1976)*. 2006;31(13):E414-20.