






COVID-19 in Renal Transplant Patient Presenting With Active Typical Symptoms and Resolved Atypical Symptoms

Journal of Investigative Medicine High
Impact Case Reports
Volume 8: 1–7
© 2020 American Federation for
Medical Research
DOI: 10.1177/2324709620949307
journals.sagepub.com/home/hic


Sreedhar Adapa, MD, FACP, FASN¹ ,
Venu Madhav Konala, MD, FACP, CACP² ,
Srikanth Naramala, MD, FACR, CCD¹ ,
Subba Rao Daggubati, MD³,
Narayana Murty Koduri, MD, MRCPsych⁴,
Vijay Gayam, MD⁵ ,
and Avantika Chenna, MD, FASN^{6,7}

Abstract

The novel coronavirus disease has brought the world to standstill with high infectivity and rapid transmission. The disease caused by novel coronavirus is termed as coronavirus disease 2019 (COVID-19). We present the case of a renal transplant patient who was infected with COVID-19 through community spread and presented with fever and gastrointestinal symptoms. Transplant recipients are particularly vulnerable because of the immunosuppressed state. These patients can shed a virus for a prolonged period and can have a higher load of the virus. There have been no COVID-19 cases transmitted through organ donation. Preinfection immunological impairment can aggravate the severity of the infection. The transplant team plays a crucial role in donor and recipient evaluation and guiding the timing of the transplant. Although specific published data are lacking with regard to transplant recipients, they should follow the same precautions as the general population, like avoiding nonessential travel and practice social distancing.

Keywords

coronavirus, COVID-19, acute respiratory distress syndrome, renal transplant

Introduction

The severe acute distress syndrome caused by severe acute respiratory syndrome coronavirus 2 (SARS-CoV-2) is a public health concern and has infected more than 7 million people worldwide as of June 8, 2020.¹ The disease caused by SARS-CoV-2 is termed as coronavirus disease 2019 (COVID-19). The SARS-CoV-2 is highly contagious and frequently involves patients with preexisting conditions. Transplant recipients are particularly vulnerable because of the immunosuppressed state and can develop opportunistic infections. COVID-19 is rapidly evolving, causing outbreaks and case clusters, and it has affected transplantation globally. We present a renal transplant patient who was infected with COVID-19 through community spread and presented with fever and gastrointestinal symptoms.

disease, s/p living-related kidney transplant in 2004 at an outside hospital, presented to the emergency room with fever for 5 days. She also had diarrhea and nausea, which had resolved by the time of presentation. The patient had nausea and diarrhea for 5 days. The diarrhea was nonbloody and watery, occurring about 4 to 5 times daily. The patient

¹Adventist Medical Center, Hanford, CA, USA

²Ashland Bellefonte Cancer Center, Ashland, KY, USA

³Wise Health System, Decatur, TX, USA

⁴Great Plains Health, North Platte, NE, USA

⁵Interfaith Medical Center, Brooklyn, NY, USA

⁶Phoebe Putney Memorial Hospital, Albany, GA, USA

⁷Medical College of Georgia, Augusta, GA, USA

Received June 8, 2020. Revised July 18, 2020. Accepted July 19, 2020.

Corresponding Author:

Srikanth Naramala, MD, FACR, CCD, Department of Internal Medicine, Division of Rheumatology, Adventist Medical Center, 470 North Greenfield Avenue, Suite 305, Hanford, CA 93230, USA.
Email: dr.srikanth83@gmail.com

Case Report

A 61-year-old African American female with a history of end-stage renal disease due to adult polycystic kidney



Table 1. Summary of Laboratory Findings.

Parameters	Reference range	At admission	At discharge
Hemoglobin	11-15 (g/dL)	13.3	12.4
WBC	4.5-11 ($10^3/\mu\text{L}$)	4.7	6.1
Lymphocytes	22-48 (%)	24.4	N/A
Neutrophils	40-70 (%)	67	N/A
Sodium	136-145 (mmol/L)	135	136
Potassium	3.5-5.1 (mmol/L)	4.1	4.1
Bicarbonate	23-31 (mEq)	21	23
BUN	9.8-20.1 (mg/dL)	13	14
Creatinine	0.57-1.11 (mg/dL)	1.3	1.41
Magnesium	1.6-2.6 (mg/dL)	1.6	N/A
Creatine kinase	29-168 (U/L)	83	N/A
Ferritin	30-400 (ng/mL)	734.4	1492.7
C-reactive protein	0-10 (mg/L)	5.3	6.5
Tacrolimus trough level	5-20 ($\mu\text{g/L}$)	7	N/A
Covid-19	NAA/PCR	Positive	N/A

Abbreviations: BUN, blood urea nitrogen; N/A, not available; NAA, nucleic acid amplification; PCR, polymerase chain reaction; WBC, white blood cells.

attended a funeral 10 days before her admission. She denied any history of cough, shortness of breath, chest pain, abdominal pain, vomiting, fatigue, myalgia, or headache. Symptoms started after attending a funeral in the city where several people had tested positive for COVID-19. Past medical history includes hypertension, gout, and histoplasmosis. Her home medications include tacrolimus 0.5 mg twice a day, mycophenolate mofetil (MMF) 250 mg twice a day, prednisone 5 mg daily, itraconazole 100 mg twice a day, allopurinol 100 mg daily, labetalol 100 mg twice a day, and hydralazine 100 mg 3 times a day.

On presentation, the patient was febrile with 103 °F, pulse rate 87 beats per minute, blood pressure 151/85 mm Hg, respiratory rate 24 breaths per minute, and oxygen saturation 92% to 97% on room air. Physical examination revealed that the patient was in respiratory distress with decreased breath sounds on the left side of the chest. The rest of the physical examination was unremarkable. The laboratory findings are summarized in Table 1. The patient's baseline creatinine was 1.4 g/dL in the laboratory tests done in 2019. The urinalysis revealed 2+ protein, which was new, negative for blood and red blood cells. The chest X-ray revealed mild mid to lower lung infiltrate bilaterally, more significant on the left (Figure 1). The computed tomography (CT) scan of the chest with contrast revealed few scattered rounded ground glass and consolidative opacities seen within the lingula of the left lung and middle lobe right lung and segmental lung consolidation seen within the dependent portion of both lower lobes (Figure 2).

The patient was started on treatment with ceftriaxone and azithromycin for possible community-acquired pneumonia. The patient was started on intravenous fluids and antipyretics for fever. The patient's MMF was held, tacrolimus and prednisone were continued. The COVID-19 testing done

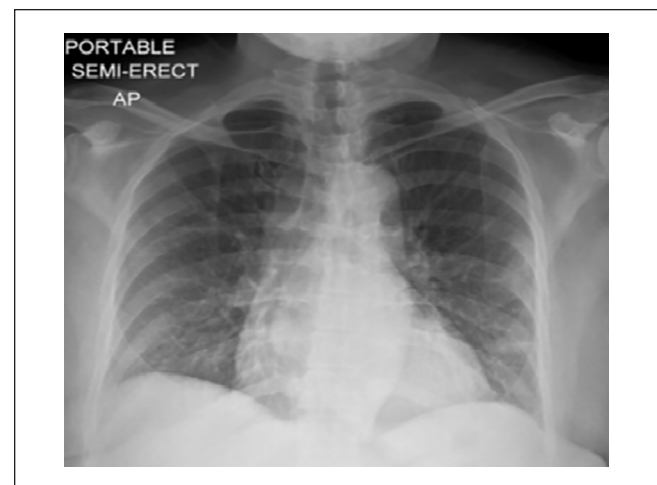


Figure 1. Chest X-ray portable revealed mid to lower lung infiltrates bilaterally left greater than right.

using polymerase chain reaction at the time of admission came positive. The patient needed only 2 to -3 L of oxygen for the first 2 days and no oxygen requirements after that. Her fever resolved. The patient was discharged after 5 days from the hospital. MMF was restarted and continued the same immunosuppressive regimen, before the hospital admission. The patient continues to do well after 2 weeks of discharge from the hospital.

Discussion

Coronavirus disease 2019 (COVID-19) has become a global threat and is spreading at an alarming rate. The ailment from COVID-19 in transplant patients can be mild to severe. This group of patients can shed virus for longer period and can

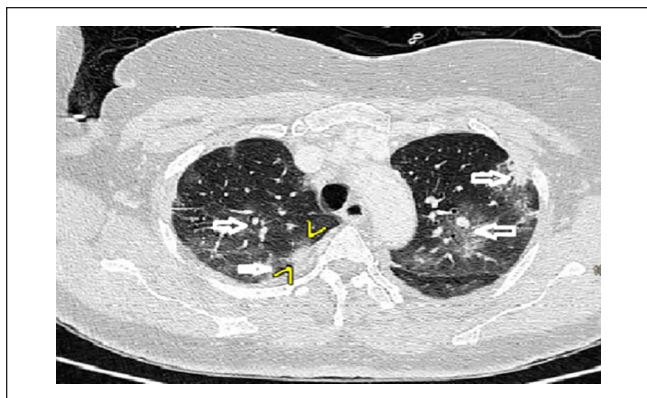


Figure 2. Computed tomography of the chest with contrast revealed few scattered rounded ground glass and consolidative opacities in the lingula of the left lung and middle lobe of the right lung along with segmental lung consolidation seen within the dependent portion of both lower lobes.

have increased viral load.² Preinfection immunological impairment can aggravate the severity of the infection. These patients can also develop coinfections with bacteria, fungus, and opportunistic pathogens. The presentation in our patient was atypical with gastrointestinal symptoms, which is not a common presentation in COVID-19.

Transplantation is a life-saving procedure for any end-stage organ damage, and in the event of COVID-19, the recipient and the transplant program faces many challenges that need individualized decisions. Review of literature did not report any COVID-19 transmission through organ donation.³ The SARS-CoV was detected in the liver and kidney on the autopsy reports, which, along with detection of SARS-CoV-2 in the blood of 15% cases, infers that virus can affect the organs.⁴ The clinical and laboratory screening of the donors should be done as COVID-19 has compelling community spread.³ SARS-CoV-2 real-time nucleic acid testing nasopharyngeal swab was included in the donor screening algorithms in many countries.³ Universal nucleic acid testing should be done in deceased and living donors.³ Prior studies have shown that the tissue viral loads and mortality were higher in patients with transplants who had severe acute respiratory syndrome (SARS) and Middle East respiratory syndrome (MERS) compared with immunocompetent individuals.³ In the setting of the pandemic, we should consider many factors like local health care utilization, weighing the risks and benefits of proceeding with the transplant, and exposing the patients to immunosuppression.

The chronic transplant recipients should limit their exposure by minimizing clinic visits and communicating with the transplant team either by telephone or through telemedicine visits. The members of the transplant care team should be educated on symptoms of COVID-19 and should report to the team if they experience any symptoms or self-isolate if they experience symptoms or had exposure. The members of the transplant team can be of increased risk of exposure when

they travel to endemic areas to procure the organs, performing bronchoscopies on diseased donors, which are of exceptionally high risk, and getting exposed to asymptomatic patients who shed viruses.³ Appropriate personal protection equipment should be used to alleviate this risk.³

Management is challenging when a vaccine is not available. Prevention is the key by avoiding exposure, practicing social distancing, and controlling the transmission. The patients should be advised not to change their immunosuppressive medications without consulting with the transplant team to prevent rejection. Graft rejection will need hospital admission for the management that can result in an increased risk of exposure to COVID-19. The patients who are exposed to COVID-19 should seek guidance from the transplant team, quarantine themselves, and should be directed appropriately for testing if they develop symptoms. There is no evidence for prophylaxis for COVID-19 in transplant patients. Hydroxychloroquine is associated with side effects like visual disturbances, bone marrow depression, gastrointestinal symptoms, and QT interval prolongation, which can result in fatal arrhythmias.⁵ The transplant recipient who develops COVID-19 should be managed by the transplant team and might involve the temporary cessation of MMF or azathioprine on the background of calcineurin inhibitors (CNIs).⁶ In a study by Carbajo-Lozoya et al,⁷ tacrolimus inhibited the growth of human coronaviruses, including SARS-CoV.

The British Thoracic Society has issued guidance for transplant patients with symptoms compatible with COVID-19. All the patients should stop antiproliferative drugs like MMF or azathioprine and consider the reduction of CNIs. In the patients who do not require hospital admission, the patients should self-isolate, remotely monitored for any change of symptoms, and should not use high-dose steroids. In patients needing hospital admission or needing ventilator support, stopping CNIs and increasing steroid dose should be considered.⁸ The decision to increase the steroids should be a collaborative decision of intensivists and the transplant team. Other management issues like fluid administration, ventilator support, antibiotics, and antivirals should be in line with local and national guidance.⁸

There are many medications under trial for COVID-19, such as hydroxychloroquine, remdesivir, tocilizumab, and colchicine. Drug interactions should require very close attention. Information on adjusting immunosuppression and patient outcomes from prior case reports and series published on renal transplant patients with COVID-19 is discussed below and summarized in Table 2, which will help physicians in decision making in similar case scenarios.

Bartiromo et al²⁴ has described the case of a 36-year-old renal transplant recipient who developed COVID-19 and was treated with hydroxychloroquine, ritonavir/lopinavir, along with a reduction of tacrolimus level. The patient developed abdominal pain, nausea, and vomiting, and tacrolimus trough levels were extremely high, 90.5 ng/mL, tacrolimus

Table 2. Summary of Case Reports Published on Renal Transplant Patients With COVID-19.

Case report	Age in years/sex	Home immunosuppression	Age of transplant	Immunosuppression modification	Other treatments	AKI (yes/no)	Care in ICU (yes/no)	Outcome
Zhu et al ⁹	52/Male	Tacrolimus, MMF, prednisone	12 years	Discontinued all home immunosuppressive agents Methyl prednisone 40 mg oral daily	Intravenous immunoglobulin (IVIg), interferon- α , biapenem	No	No	Discharged
Guillen et al ¹⁰	50/Male	Tacrolimus, everolimus, prednisone	4 years	Discontinued tacrolimus, everolimus	Lopinavir + ritonavir, ceftriaxone, meropenem, hydroxychloroquine, interferon- β	Yes	Yes	Unknown
Gandolfini et al ¹¹	75/Male	Tacrolimus, MMF, steroid	10 years	Discontinued tacrolimus, MMF Continued steroids	Lopinavir + ritonavir, antibiotics Hydroxychloroquine	No	No	Deceased
Gandolfini et al ¹¹	52/Male	Tacrolimus, MMF, steroid	8 months	Discontinued tacrolimus, MMF Continued steroids	Darunavir/cobicistat, antibiotics Hydroxychloroquine, colchicine	Yes	No	Alive
Huang et al ¹²	58/Male	MMF, steroids	12 years	Discontinued MMF Methyl prednisone 80 mg oral daily started	Osetamivir Moxifloxacin Lopinavir + ritonavir	NA	Yes	Deceased
Ning et al ¹³	29/Male	MMF, cyclosporine, methyl prednisone	15 months	Continued immunosuppression	Moxifloxacin Trimethoprim-sulfamethoxazole, lopinavir + ritonavir	No	No	Discharged
Chen et al ¹⁴	49/Male	Tacrolimus, MMF, prednisone	7 years	Discontinued MMF, tacrolimus Started on methyl prednisone 20 mg oral daily	Umifenovir, ribavirin, IVIG, moxifloxacin	No	Yes	Discharged
Seminari et al ¹⁵	50/Male	Tacrolimus, MMF	4 years	Continued immunosuppression	Ceftriaxone	No	No	Discharged
Marx et al ¹⁶	58/Male	Belatacept, MMF, prednisone	3 years	Belatacept, MMF discontinued Low-dose cyclosporine started Prednisone continued	No treatment	Yes	No	Discharged
Arpali et al ¹⁷	28/Female	Tacrolimus, MMF, prednisone	6 months	Continued immunosuppression	Osetamivir	No	No	Discharged
Hsu et al ¹⁸	39/Male	Tacrolimus, MMF, prednisone	3 years	Discontinued MMF, tacrolimus and prednisone continued	Hydroxychloroquine Remdesivir	No	Yes	Discharged

(continued)

Table 2. (continued)

Case report	Age in years/sex	Home immunosuppression	Age of transplant	Immunosuppression modification	Other treatments	AKI (yes/no)	Care in ICU (yes/no)	Outcome
Cheng et al ¹⁹	48/Male	Tacrolimus, MMF, prednisone	11 years	Discontinued MMF and tacrolimus. Low-dose methyl prednisone started	No treatment	No	No	Discharged
Cheng et al ¹⁹	65/Female	Tacrolimus, MMF, prednisone	9 years	Discontinued MMF and tacrolimus. prednisone continued, later changed to methyl prednisone	Moxifloxacin IVIg Umifenovir	No	No	Discharged
Kim et al ²⁰	36/Male	Tacrolimus, MMF, prednisone	4 years	Discontinued MMF and tacrolimus. Started on methyl prednisone	Lopinavir + ritonavir Hydroxychloroquine	Yes	No	Discharged
Kim et al ²⁰	56/Male	Tacrolimus, MMF, prednisone	9 years	Discontinued MMF. tacrolimus and prednisone continued	Azithromycin + hydroxychloroquine	Yes	No	Discharged
Fontana et al ²¹	61/Male	Cyclosporine, prednisone	15 years	Discontinued cyclosporine. methyl prednisone started	Hydroxychloroquine + azithromycin Tocilizumab IVIg	Yes	No	Discharged
Bussalino et al ²²	32/Male	Tacrolimus, MMF, prednisone	2.5 years	Continued on Tacrolimus, MMF with increase in dose of prednisone	Meropenem Hydroxychloroquine Osetamivir	Yes	No	Discharged
Wang et al ²³	49/Male	Cyclosporine MMF Prednisone	2 year	Continued cyclosporine, MMF, prednisone	Cefatrolone Lopinavir + ritonavir Interferon α -2b Ribavirin	Yes	No	Discharged

Abbreviations: MMF, mycophenolate mofetil; ICU, intensive care unit.

was discontinued and was managed only on steroids and discharged home.²⁴

In a case series of 5 renal transplant patient with COVID-19, described by Zhang et al,²⁵ all patients were on MMF, CNI, and prednisolone. MMF was stopped, and steroids, as well as CNI doses, were reduced in all patients. Four patients developed new-onset proteinuria. All patients had lung infiltrates and received antiretroviral therapy; none of them developed severe disease, needed intensive care unit (ICU) care, or needed intubation.²⁵ Banerjee et al⁶ described 7 renal transplant patients with COVID-19 from London, all presenting with fever and respiratory symptoms. Two patients presented within 3 months of renal transplant, and 2 patients were managed on an outpatient basis. Four out of 5 needed ICU admission. One patient died, and 6 patients had immunosuppression modified. Alberici et al²⁶ analyzed data from 20 renal transplant recipients with COVID-19. Most (95%) of these patients were on CNIs, 70% on MMF, 65% on glucocorticoids, and 10% on mammalian target of rapamycin (mTOR) inhibitor. All the immunosuppression was withdrawn. All patients have been treated with methylprednisolone 16 mg daily, 19 were treated with hydroxychloroquine and antivirals, and 6 patients received tocilizumab. Four patients needed ICU care, 6 developed acute kidney injury, and 1 among them needed dialysis. Unfortunately, 5 out of 20 patients died.²⁶

In a single-center study by Akalin et al²⁷ in New York, 36 adult kidney transplant recipients tested positive for COVID-19. The median age was 60 years, and the majority of them were male (26 patients, 72%). Most of them were African Americans and Hispanics at 39% and 42%, respectively. Ninety-four percent of the patients have hypertension, and 69% have diabetes. Thirty-five patients (97%) were receiving tacrolimus, 34 patients were receiving prednisone (94%), and 31 patients (86%) were receiving MMF. The presenting symptoms were fever (58%), cough (53%), dyspnea (44%), myalgias (36%), and diarrhea (22%). The hospital admission was needed in 28 patients out of which 27 patients' radiographic findings were consistent with pneumonia. Antimetabolite was withdrawn in 86%, and tacrolimus was withdrawn in 21% of the patients. Hydroxychloroquine, azithromycin, leronlimab, tocilizumab, and high-dose glucocorticoids were used in 86%, 46%, 21%, 7%, and 7%, respectively. A total of 10 patients died (28%), 11 patients needed intubation (39%), renal replacement was needed in 6 patients (21%), and 10 patients were discharged.²⁷

In a case series of 6 kidney transplant patients infected with COVID-19 pneumonia that were treated with tocilizumab, 4 patients died. All patients developed acute respiratory distress syndrome, and 2 of them needed continuous renal replacement therapy. Three of the 4 patients who died developed septic shock. The 2 patients who improved after tocilizumab treatment showed significant improvement in the lymphocyte count.²⁸

In an experience from Spain evaluating the outcomes of COVID-19 in elderly (age >65 years) kidney transplant recipients, 4.9% (16 out of 324) were infected. One third of the patients developed renal dysfunction. mTOR inhibitors or MMF were discontinued on admission in all patients, and tacrolimus was withdrawn in 70% of the patients. The patients were primarily treated with a combination of azithromycin and hydroxychloroquine. Tocilizumab and antiretrovirals were given in a subset of patients. Short-term mortality in this study was 50% and is more pronounced in patients who had underlying cardiac disease, frail, and obese.²⁹

Nair et al³⁰ reported the clinical characteristics and outcomes of 10 kidney transplant recipients infected with COVID-19. Nine patients were hospitalized, and 1 patient was discharged home from the emergency room with no change in immunosuppression. Antimetabolites were stopped in all hospitalized patients. All hospitalized patients were treated with hydroxychloroquine and azithromycin. Five patients require ICU stay and developed acute kidney injury with one needing continuous renal replacement therapy. Mortality was 30% (3 patients) in this study.³⁰

Husain et al³¹ discussed the early outcomes of outpatient management of 41 kidney transplant recipients with COVID-19. COVID-19 was confirmed in 22 (54%) patients and suspected in 19 patients. Thirteen (32%) patients were hospitalized with a median time of 8 days from symptom onset. The majority of the patients were male, and the median age was 49 years. The main symptoms were fever (80%), cough (56%), and shortness of breath (36%). However, dyspnea was more significant in hospitalized patients (77%) than those treated as an outpatient. The median baseline creatinine was higher in hospitalized patients. Maintenance immunosuppression was similar in these patients, with 76% on CNIs and antimetabolites. The immunosuppressive regimen was reduced in 26 (63%) patients, with 82% in confirmed cases. Of the patients managed on an outpatient basis only, the improvement of the symptoms was seen at 12 days. There was no acute rejection noted during this limited follow-up (24 days) period in the patients with reduced immunosuppression.³¹

Conclusion

The kidney transplant recipients are at increased risk of developing infections secondary to their immunosuppressed state. Although specific published data are lacking, they should follow the same precautions as the general population, like avoiding nonessential travel and practice social distancing.

Declaration of Conflicting Interests

The author(s) declared no potential conflicts of interest with respect to the research, authorship, and/or publication of this article.

Funding

The author(s) received no financial support for the research, authorship, and/or publication of this article.

Ethics Approval

Our institution does not require ethical approval for reporting individual cases or case series.


Informed Consent

Verbal informed consent was obtained from the patient for their anonymized information to be published in this article.

ORCID iDs

Sreedhar Adapa  <https://orcid.org/0000-0001-5608-5654>

Venu Madhav Konala  <https://orcid.org/0000-0003-1953-8815>

Srikanth Naramala  <https://orcid.org/0000-0003-1238-856X>

Vijay Gayam  <https://orcid.org/0000-0001-5194-9134>

References

1. John Hopkins University and Medicine. Coronavirus Resource Center. Accessed June 8, 2020. <https://coronavirus.jhu.edu/map.html>
2. Fishman JA, Grossi PA. Novel coronavirus-19 (COVID-19) in the immunocompromised transplant recipient: #Flatteningthecurve. *Am J Transplant.* 2020;20:1765-1767.
3. Kumar D, Manuel O, Natori Y, et al. COVID-19: a global transplant perspective on successfully navigating a pandemic. *Am J Transplant.* 2020;20:1773-1779.
4. Kaul DR, Mehta AK, Wolfe CR, Blumberg E, Green M. Ebola virus disease: implications for solid organ transplantation. *Am J Transplant.* 2015;15:5-6.
5. Eljaaly K, Alireza KH, Alshehri S, Al-Tawfiq JA. Hydroxychloroquine safety: a meta-analysis of randomized controlled trials. *Travel Med Infect Dis.* 2020;36:101812.
6. Banerjee D, Popoola J, Shah S, Ster IC, Quan V, Phanish M. COVID-19 infection in kidney transplant recipients. *Kidney Int.* 2020;97:1076-1082.
7. Carbajo-Lozoya J, Müller MA, Kallies S, Thiel V, Drosten C, von Brunn A. Replication of human coronaviruses SARS-CoV, HCoV-NL63 and HCoV-229E is inhibited by the drug FK506. *Virus Res.* 2012;165:112-117.
8. British Transplantation Society. Guidance on the management of transplant recipients diagnosed with or suspected of having COVID19. Updated April 1, 2020. Accessed June 8, 2020. <https://bts.org.uk/wp-content/uploads/2020/04/Clinical-management-of-transplants-and-immunosuppression-Updated-1st-April-2020.pdf>
9. Zhu L, Xu X, Ma K, et al. Successful recovery of COVID-19 pneumonia in a renal transplant recipient with long-term immunosuppression. *Am J Transplant.* 2020;20:1859-1863.
10. Guillen E, Pineiro GJ, Revuelta I, et al. Case report of COVID-19 in a kidney transplant recipient: does immunosuppression alter the clinical presentation? *Am J Transplant.* 2020;20:1875-18784.
11. Gandolfini I, Delsante M, Fiaccadori E, et al. COVID-19 in kidney transplant recipients. *Am J Transplant.* 2020;20:1941-1943.
12. Huang J, Lin H, Wu Y, et al. COVID-19 in post-transplantation patients—report of two cases. *Am J Transplant.* 2020;20:1879-1881.
13. Ning L, Liu L, Li W, et al. Novel coronavirus (SARS-CoV-2) infection in a renal transplant recipient: case report. *Am J Transplant.* 2020;20:1864-1868.
14. Chen S, Yin Q, Shi H, et al. A familial cluster, including a kidney transplant recipient, of Coronavirus Disease 2019 (COVID-19) in Wuhan, China. *Am J Transplant.* 2020;20:1869-1874.
15. Seminari E, Colaneri M, Sambo M, et al. SARS Cov2 infection in a renal transplanted patients: a case report. *Am J Transplant.* 2020;20:1882-1884.
16. Marx D, Moulin B, Fafi-Kremer S, et al. First case of COVID-19 in a kidney transplant recipient treated with belatacept. *Am J Transplant.* 2020;20:1944-1946.
17. Arpali E, Akyollu B, Yelken B, Tekin S, Turkmen A, Kocak B. Case report: a kidney transplant patient with mild COVID-19. *Transpl Infect Dis.* Published online April 16, 2020. doi:10.1111/tid.13296
18. Hsu JJ, Gaynor P, Kamath M, et al. COVID-19 in a high-risk dual heart and kidney transplant recipient. *Am J Transplant.* 2020;20:1911-1915.
19. Cheng DR, Wen JQ, Liu ZZ, Lv TF, Chen JS. Coronavirus disease 2019 in renal transplant recipients: report of two. *Transpl Infect Dis.* Published online May 16, 2020. doi:10.1111/tid.13329
20. Kim Y, Kwon O, Paek JH, et al. Two distinct cases with COVID-19 in kidney transplant recipients. *Am J Transplant.* Published online April 26, 2020. doi:10.1111/ajt.15947
21. Fontana F, Alfano G, Mori G, et al. COVID-19 pneumonia in a kidney transplant recipient successfully treated with tocilizumab and hydroxychloroquine. *Am J Transplant.* 2020;20:1902-1906.
22. Bussalino E, De Maria A, Russo R, Paoletti E. Immunosuppressive therapy maintenance in a kidney transplant recipient with SARS-CoV-2 pneumonia: a case report. *Am J Transplant.* 2020;20:1922-1924.
23. Wang J, Li X, Cao G, Wu X, Wang Z, Yan T. COVID-19 in a kidney transplant patient. *Eur Urol.* 2020;77:769-770.
24. Bartiromo M, Borchini B, Botta A, et al. Threatening drug-drug interaction in a kidney transplant patient with coronavirus disease 2019 (COVID-19). *Transpl Infect Dis.* Published online April 12, 2020. doi:10.1111/tid.13286
25. Zhang H, Chen Y, Yuan Q, et al. Identification of kidney transplant recipients with coronavirus disease 2019. *Eur Urol.* 2020;77:742-747.
26. Alberici F, Delbarba E, Manenti C, et al. A single center observational study of the clinical characteristics and short-term outcome of 20 kidney transplant patients admitted for SARS-CoV2 pneumonia. *Kidney Int.* 2020;97:1083-1088.
27. Akalin E, Azzi Y, Bartash R, et al. Covid-19 and kidney transplantation. *N Engl J Med.* 2020;382:2475-2477.
28. Mella A, Mingozzi S, Gallo E, et al. Case series of six kidney transplanted patients with COVID-19 pneumonia treated with tocilizumab. *Transpl Infect Dis.* Published online June 5, 2020. doi:10.1111/tid.13348
29. Crespo M, Pérez-Sáez MJ, Redondo-Pachón D, et al. COVID-19 in elderly kidney transplant recipients. *Am J Transplant.* Published online May 29, 2020. doi:10.1111/ajt.16096
30. Nair V, Jandovitz N, Hirsch JS, et al. COVID-19 in kidney transplant recipients. *Am J Transplant.* 2020;20:1819-1825.
31. Husain SA, Dube G, Morris H, et al. Early outcomes of outpatient management of kidney transplant recipients with coronavirus disease 2019. *Clin J Am Soc Nephrol.* Published online May 18, 2020. doi:10.2215/CJN.05170420