

Ginsenoside Rg1 attenuates liver injury induced by D-galactose in mice

MING-HE XIAO^{1*}, JIE-YU XIA^{1,2*}, ZI-LING WANG¹, WEN-XU HU¹, YAN-LING FAN¹,
DAO-YONG JIA¹, JING LI¹, PENG-WEI JING¹, LU WANG¹ and YA-PING WANG¹

¹Laboratory of Stem Cells and Tissue Engineering, Department of Histology and Embryology, Chongqing Medical University, Chongqing 400016; ²Key Laboratory for Biorheological Science and Technology of Ministry of Education, Chongqing University Cancer Hospital and Chongqing Cancer Institute and Chongqing Cancer Hospital, Chongqing 400044, P.R. China

Received November 9, 2017; Accepted August 2, 2018

DOI: 10.3892/etm.2018.6727

Abstract. The present study investigated the effect and underlying mechanisms of ginsenoside Rg1 (Rg1) in attenuating subacute liver injury induced by D-galactose (D-gal) in mice. Specific Pathogen Free (SPF) male C57BL/6J mice were randomly divided into 3 groups: i) D-gal-administration group (D-gal group), where the mice were intraperitoneally administrated with D-gal (120 mg/kg/day for 42 days); ii) D-gal + Rg1 group where the mice were treated with 120 mg/kg/day D-gal for 42 days and with Rg1 at a dose of 20 mg/kg/day for 35 days. The first dose of Rg1 was administered on the 8th day of treatment with D-gal; and iii) the normal control group, where the mice were injected with an equal volume of saline for 42 days. The day following the final injections in all groups, peripheral blood was collected and serum was prepared to measure the contents of aspartate aminotransferase (AST), alanine aminotransferase (ALT), total bilirubin (TbIL), advanced glycation end products (AGEs) and 8-hydroxy-2 deoxyguanosine (8-OH-dG). Liver tissue homogenates were prepared to measure the contents of malondialdehyde (MDA) and glutathione (GSH), and the activities of glutathione peroxidase (GSH-Px) and superoxide dismutase (SOD). Paraffin section were prepared to observe the microscopic structure of the liver. Transmission electron microscopy was used to observe the ultrastructure of hepatocytes. Frozen section were prepared and stained with senescence-associated β -galactosidase to detect the relative optical density value of

senescence-associated markers. Compared with the D-gal group, the contents of AST, ALT, TbIL, AGEs and MDA significantly decreased in the D-gal + Rg1 group, while the activities of SOD and GSH-Px markedly increased, and liver injury and degenerative alterations of hepatocytes were reduced. Administration of Rg1 induced a protective effect on D-gal-induced liver injury in mice by inhibiting the oxidative stress, reducing DNA damage and decreasing the AGE content.

Introduction

Liver serves a crucial role in the metabolism of xenobiotics which may cause numerous hepatic diseases (1). A previous study has indicated that oxidative stress is a key element to the pathophysiology of various types of liver damage, including alcoholic and nonalcoholic liver disease (2). Previous studies have also confirmed that the reactive oxygen species (ROS) is a crucially important factor for the initiation of oxidative stress and that advanced glycation end products (AGEs) are associated with enhanced oxidative stress (3,4). D-galactose is a common oxidative stress model inducer and the tissues of animals with chronic D-gal administration induce oxidative damage and AGE formation (5). Oxidative stress causes the increase of liver cell membrane permeability, releasing ALT and AST into the blood, making these parameters suitable biochemical markers of liver damage (6). Furthermore, other biomarkers including superoxide dismutase (SOD), 8-hydroxy-2 deoxyguanosine (8-OH-dG), malondialdehyde (MDA), glutathione (GSH), glutathione peroxidase (GSH-Px), may be used to assess oxidative stress in liver disease (7).

Traditional treatment methods usually include administration of nucleoside analogues, interferon and antiviral drugs (8). Synthetic drugs for the treatment of liver diseases can lead to severe side-effects (9), and, therefore, herbal medication may be an alternative treatment method. There is a long history of using traditional Chinese medicines in treatment of liver diseases (10). Ginsenoside Rg1 (Rg 1) is one of the most active ingredients of ginseng which induces antiaging and antioxidant effects, as well as improves immunity and memory (11,12). Previous studies have investigated the effect of Rg1 on liver

Correspondence to: Professor Ya-Ping Wang, Laboratory of Stem Cells and Tissue Engineering, Department of Histology and Embryology, Chongqing Medical University, 1 Medical School Road, Chongqing 400016, P.R. China
E-mail: ypwangcq@aliyun.com

*Contributed equally

Key words: ginsenoside Rg1, D-galactose, liver injury, underlying mechanism

damage and demonstrated that this compound reduces apoptosis, and inflammatory response to protect the liver from ischemia reperfusion injury and type 2 diabetes (13,14). Rg1 also enhanced the antioxidative defense system to ameliorate carbon tetrachloride-induced liver injury in rats (15). The present study used a mouse model of D-gal-induced liver injury to elucidate the function and the underlying mechanism of Rg1.

Materials and methods

Animals. SPF male C57BL/6J mice (weight, 16±2 g; n=30; age, 6-8 weeks) were purchased from the Medical and Laboratory Animal Center of Chongqing University (Chongqing, China) and housed at a temperature of 22-24°C, a humidity of 40-70% and a 12 h light/dark cycle, with free access to water and food. All animal experiments were performed in accordance with the institutional and national guidelines and regulations, and approved by the Chongqing Medical University Animal Care and Use Committee.

Reagents. Rg1 (purity >95%) was purchased from Hongjiu Biotech Co., Ltd., (Tonghua, China). D-galactose (D-gal; purity >99%) was obtained from Sangon Biotech Co., Ltd. (Shanghai, China). The senescence-associated β-galactosidase (SA-β-gal) Staining kit was purchased from Cell Signaling Technology, Inc. (Danvers, MA, USA), whereas the SOD, GSH-Px, GSH and MDA detection kits were purchased from Nanjing Jiancheng Bioengineering Institute (Nanjing, China). The AGEs (cat. no. abx512406) and 8-OH-dG (cat. no. SKT-120-480) kits were purchased from Shanghai Yuanye Biological Technology Co., Ltd. (Shanghai, China).

Mouse D-gal aging model and treatment groups. A total of 30 mice were randomly divided into three groups: Control group, D-gal-administration group (D-gal group) and D-gal-administration plus Rg1 treatment group (D-gal + Rg1 group). In the D-gal group, D-gal (120 mg/kg body weight/day) was injected intraperitoneally into mice for 42 days. In the D-gal + Rg1 group, 120 mg/kg body weight/day D-gal was also administered to mice intraperitoneally and Rg1 (20 mg/kg body weight/day) was concomitantly injected for 35 days from the 8th day of the D-gal injection. All control animals were given an equal volume of saline intraperitoneally. On the 43rd day of the experiment, the animals were weighted (27.20±1.37 g) and anesthetized by intraperitoneal injection of sodium pentobarbital at a dose of 40 mg/kg. The blood was collected from the retro-orbital plexus (0.3 ml per mice) and liver samples were dissected and weighted immediately. The anesthetized mice were sacrificed by blood loss from heart puncture (0.6±0.1 ml per mice) until the mice succumbed to mortality confirmed by muscle relaxation and no respiratory circulation. The blood and animal carcass were collected and returned to Medical and Laboratory Animal Center of Chongqing for safe disposal.

Detection of hepatic index. The hepatic indices of each group were calculated using the following equation: Hepatic index=liver weight (mg)/body weight (g).

Biochemical determination. The collected blood was allowed to clot and serum was separated by centrifugation at a speed

of 1,200 x g for 15 min at 4°C. Serum biochemical parameters of liver function including alanine aminotransferase (ALT), aminotransferase (AST), albumin (Alb) and total bilirubin (TbIL) were analyzed by the Department of Laboratory Medicine of the First Affiliated Hospital Group of Chongqing Medical University (Chongqing, China).

Histological examination. For histological studies, the liver tissues were fixed with 4% paraformaldehyde at room temperature for 24 h, dehydrated in graded (50-100%) alcohol series and embedded in paraffin. Thin sections (5 μm) were cut and placed into a glass dish with hematoxylin. Following agitation for 30 sec at room temperature, slides were washed using water for 1 min. Slides were then stained with 1% eosin for 30 sec at room temperature. Sections were then dehydrated using alcohol and washed with xylene. One or two drops of mounting medium was then placed onto samples and covered with a coverslip. Samples were observed using bright field microscopy (magnification, x200) to observe sections. The initial examination was qualitative, with the purpose of determining histopathological lesions of the liver tissue. For transmission electron microscopy (TEM) liver tissues were fixed with 2.5% buffered glutaraldehyde for 4 h at 4°C. Tissues were subsequently washed three times for 15 min with PBS. Tissues were then fixed with 1% osmium for 1 h at 4°C and dehydrated with different concentrations of alcohol (50, 70, 80, 90 and 95%) for 15 min each, then infiltration and embedding tissues at 70°C overnight. Tissues were then sliced into 100 nm sections and stained with 0.5% toluidine blue for 30 min at 60°C. Samples were observed using TEM.

SA-β-gal cytochemical staining. The SA-β-gal staining was carried out according to the manufacturer's protocol of the SA-β-gal Staining kit. The preparation of liver tissue paraffin sections (5 μm) was performed as aforementioned. Briefly, slides were washed twice for >5 min using PBS, fixed with the Fixative Solution for 15 min at room temperature and stained by X-Gal Staining Solution (100 mM sodium phosphate, 2 mM MgCl₂, 150 mM sodium chloride, 0.01% sodium deoxycholate, 0.02% NP-40, 5 mM potassium ferricyanide, 5 mM potassium ferrocyanide and 1 mg/ml X-gal; pH 6) for 24 h at 37°C without CO₂. After the incubation, sections were washed in PBS, stained with eosin for 30 sec at room temperature and viewed using bright field microscopy (magnification, x200). Quantitative image analysis included at least 3 random fields of view per slide and was performed in a blinded manner. The intensity of SA-β-gal-positive staining was evaluated using the relative optical density (ROD) value. ROD of SA-β-gal-positive cells in the liver was obtained following transformation of mean gray values into ROD using the following formula: ROD=log (256/mean gray value) (16). Images were captured from five randomly selected fields of view using Image Pro Plus software 6.0 (Media Cybernetics, Inc., Rockville, MD, USA).

Detection of oxidation-associated biomarkers. The liver was collected and lysed in a -4°C ice bath for 30 min. The supernatant was collected after centrifugation at 12,000 r/min and 4°C for 15 min. GSH-Px and SOD activity, and GSH and MDA

Table I. Effect of Rg1 on hepatic indices.

Groups	Body weight (g)	Liver weight (g)	Hepatic indices (mg/g)
Normal control	20.00±1.22	1.21±0.45	62.43±8.49
D-gal model	23.85±2.35	2.01±0.36	83.32±6.32 ^a
Rg1 + D-gal model	26.54±2.71	1.82±0.23	71.99±5.40 ^b

Data are presented as the mean ± standard deviation, n=10. ^aP<0.05 vs. the control group. ^bP<0.05 vs. the D-gal group. D-gal, D-galactose; Rg1, ginsenoside Rg1.

Table II. Effect of Rg1 on liver damage indexes.

Groups	Alb (g/l)	ALT (U/l)	AST (U/l)	TBiL (μ mol/l)
Normal control	31.01±3.67	17.9±2.80	75.61±2.97	0.57±0.12
D-gal model	24.27±4.70 ^a	27.73±2.15 ^a	97.63±3.56 ^a	1.19±0.17 ^a
Rg1 + D-gal model	28.94±2.05 ^b	21.65±1.91 ^b	76.09±5.32 ^b	1.04±0.17 ^b

Data are presented as the mean ± standard deviation, n=10. ^aP<0.05 vs. the normal control. ^bP<0.05 vs. the D-gal group. AST, aminotransferase; ALT, alanine aminotransferase; TBiL, total bilirubin; Alb, albumin; D-gal, D-galactose; Rg1, ginsenoside Rg1.

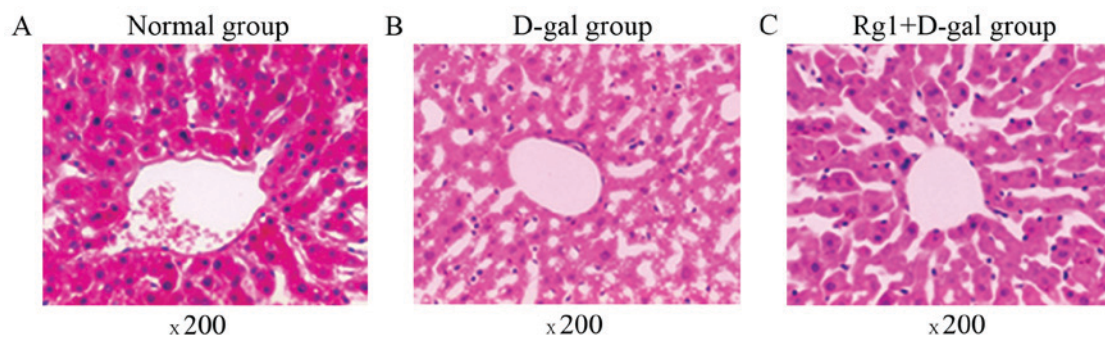


Figure 1. Effect of Rg1 on the liver structure. (A) Normal group. (B) D-gal group. (C) Rg1 + D-gal group. Hematoxylin and eosin staining; magnification, x200. D-gal, D-galactose; Rg1, ginsenoside Rg1.

contents were detected by colorimetric analysis according to the manufacturer's protocol.

Detection of AGEs and 8-OH-dG in the liver homogenate by ELISA. The supernatant was collected as described above, and the levels of AGEs and 8-OH-dG in the liver in each group were measured by ELISA kits according to the manufacturer's protocol.

Statistical analysis. Data were analyzed using one-way analysis of variance followed by a post-hoc Tukey's test for multiple comparisons. SPSS software (version 17.0; SPSS, Inc., Chicago, IL, USA) was used to analyze data, which are presented as the mean ± standard deviation. P<0.05 was considered to indicate a statistically significant difference.

Results

Effect of Rg1 on the hepatic index in a mouse model of hepatic injury. Hepatic indices in the D-gal group were significantly

higher compared with the control and the D-gal + Rg1 groups (P<0.05; Table I).

Effect of Rg1 on the liver damage indexes. Administration of D-gal significantly altered the biochemical parameters compared with the control group (all P<0.05; Table II). Treatment with Rg1 significantly decreased the serum levels of AST, ALT and TBiL (all P<0.05) and elevated the serum level of Alb (P<0.05) compared with the D-gal group.

Effect of Rg1 on liver histopathology. The liver tissue structure in the three groups was assessed by optical microscopy (Fig. 1). The mice in the control group exhibited normal and intact lobular architecture and structure of hepatocytes. Histological examination of livers exposed to D-gal indicated severe liver damage, including dilated liver sinusoids, disordered arrangement of hepatocytes, multiple and extensive areas of portal inflammation and hepatocellular necrosis, as well as an increasing number of adipose cell. However, these pathological alterations were attenuated in animals treated with Rg1. TEM

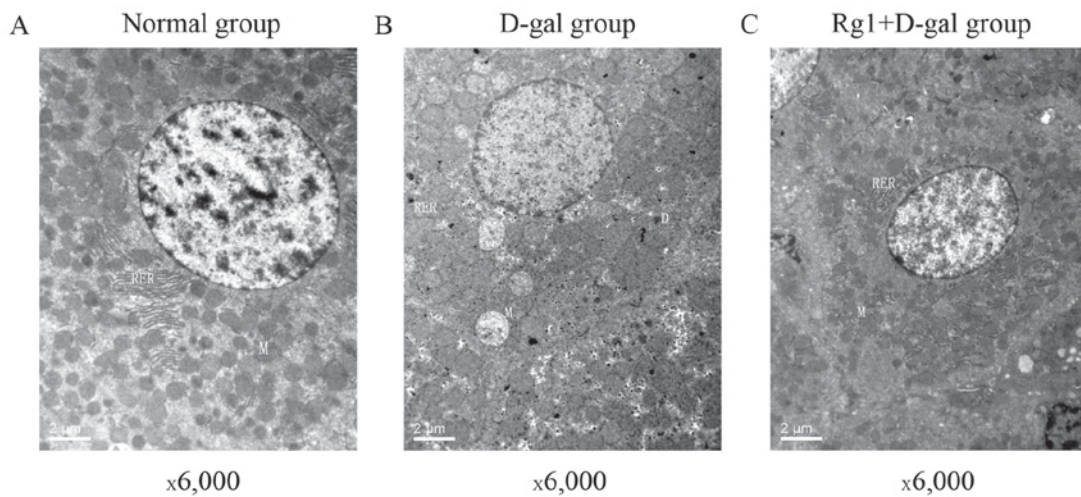


Figure 2. Effect of Rg1 on the ultrastructure of hepatocytes. (A) Normal group. (B) D-gal group. (C) Rg1 + D-gal group. Magnification, x6,000. D-gal, D-galactose; M, mitochondrion; RER, rough endoplasmic reticulum; D, dense deposit; Rg1, ginsenoside Rg1.

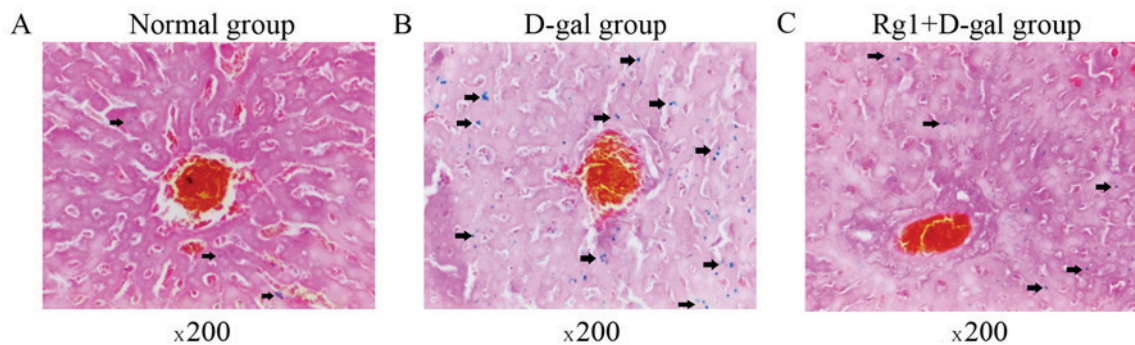


Figure 3. Effect of Rg1 on hepatocyte senescence. (A) Normal group. (B) D-gal group. (C) Rg1 + D-gal group. Senescence-associated β -galactosidase staining; magnification, x200. Arrows indicate ageing cells. D-gal, D-galactose; Rg1, ginsenoside Rg1.

was also used to compare the three groups (Fig. 2). Numerous free ribosomes were identified in the cytoplasm of the control group hepatocytes and the cytoplasmic organelles included mitochondria, rough endoplasmic reticulum (RER) and normal and activated lysosomes. Following administration with D-gal for 42 days, dense deposits in the cytoplasm of hepatocytes were observed. An increased number of vacuoles, mitochondrial swelling and shortened, disrupted RER were observed in the cytoplasm. Clumping of nuclear chromatin was observed. However, the damage of hepatocytes was attenuated following treatment with Rg1.

Antioxidative effect of Rg1 in the mouse model of hepatic injury.

Oxidative stress caused by ROS is one of the main causes of cell injury (17). SOD and GSH-Px are enzymes that participate in the removal of ROS from the cellular environment (18,19). MDA is an end-product of ROS-induced peroxidation and it is widely used as an oxidative stress biomarker (20); while GSH is the substrate of GSH-Px. Compared with the control group, SOD and GSH-Px activities, and GSH content decreased significantly in the D-group liver while the MDA content increased (all $P < 0.05$; Table III). By contrast, Rg1 rescued the SOD and GSH-Px activities, lowered the GSH consumption significantly, and partially reversed the increase in MDA compared with the D-gal group (Table III).

Rg1 reduced the SA- β -gal staining in the liver. Asymmetric ROS are molecules containing unpaired, highly reactive electrons, leading to cell injury and aging (21). SA- β -gal is one of commonly used biomarkers of cell senescence (22), and, therefore, in the present study the cytoplasm of ageing cells stained blue (Fig. 3; arrows). Few SA- β -gal-positive cells were observed in the control group (Fig. 3A). The intensity of SA- β -gal staining was evaluated using the ROD value. D-gal administration induced a significant increase in the ROD value of the SA- β -gal staining, compared with the control group (Figs. 3 and 4). However, in the D-gal + Rg1 group, the ROD value significantly decreased compared with the D-gal group (Figs. 3 and 4).

Effect of Rg1 on the DNA damage of hepatocytes. The oxidation of guanine to form 8-OH-dG is a marker of oxidative DNA damage (23). Based on the levels of 8-OH-dG, oxidative DNA damage was elevated in the D-gal group compared with the control group. The level of 8-OH-dG in mice treated with Rg1 remained stable at a level of 44.49 ± 4.20 ng/ml, and was significantly reduced compared with the D-gal group (Table IV).

Treatment with Rg1 decreased the levels of AGEs in hepatocytes from the mouse model of liver injury. AGEs are a group of modified molecular species formed by non-enzymatic

Table III. Effect of Rg1 on expression levels of SOD, MDA, GSH-Px and GSH.

Groups	SOD (U/mg prot)	MDA (nmol/mg prot)	GSH-Px (U/ml)	GSH (μ mol/mg)
Normal control	178.47 \pm 13.32	4.24 \pm 1.29	49.68 \pm 7.91	7.80 \pm 0.62
D-gal model	136.32 \pm 21.59 ^a	8.72 \pm 2.04 ^a	33.22 \pm 5.44 ^a	6.63 \pm 0.81 ^a
Rg1 + D-gal model	155.43 \pm 13.80 ^b	6.02 \pm 1.15 ^b	43.22 \pm 5.41 ^b	7.52 \pm 0.75 ^b

Data are presented as the mean \pm standard deviation, n=10. ^aP<0.05 vs. the control group. ^bP<0.05 vs. the D-gal group. D-gal, D-galactose; Rg1, ginsenoside Rg1; SOD, superoxide dismutase; MDA, malondialdehyde; GSH-Px, glutathione peroxidase; GSH, glutathione.

Table IV. Effect of Rg1 on 8-OH-dG and AGEs in the liver of injured model mice.

Groups	8-OH-dG (ng/ml)	AGEs (ng/ml)
Normal control	35.52 \pm 4.15	92.82 \pm 19.70
D-gal model	56.44 \pm 3.36 ^a	140.99 \pm 15.95 ^a
Rg1 + D-gal model	44.49 \pm 4.20 ^b	117.15 \pm 12.3

Data are presented as the mean \pm standard deviation, n=10. ^aP<0.05 vs. the control group. ^bP<0.05 vs. the D-gal group. AGEs, advanced glycation end products; 8-OH-dG, 8-hydroxy-2 deoxy-guanosine; D-gal, D-galactose; Rg1, ginsenoside Rg1.

reactions of reducing sugars and proteins, lipids or nucleic acids (24). The accumulation of AGEs is associated with hepatocyte damage and the process of aging (25). The administration of D-gal increased the liver accumulation of AGEs. However, treatment with Rg1 decreased the levels of AGEs compared with the D-gal model (Table IV).

Discussion

D-gal has been previously used to establish an experimental model of aging (26). A previous study has demonstrated that the primary advantage of long-term D-gal administration to mice is that it mimics the natural aging effect of the liver (27). The underlying mechanism of D-gal-induced injury is a decrease in the cellular UTP concentration leading to the inhibition of RNA and protein synthesis (28,29). Furthermore, oxidative damage and inflammation have also been hypothesized to serve roles in age-associated alterations in the liver (30). Hepatic aging and necrosis induced by the excessive levels of D-gal are associated with increased expression levels of oxygen-derived free radicals in mouse hepatocytes (31). Based on the results of previous studies, the present study established a D-gal-induced model to further investigate hepatic injury. In the present study, liver injury was induced by administration of D-gal and confirmed by alterations in liver damage indices, oxidative stress, histopathology, DNA damage, and levels of AGEs. All D-gal-induced alteration in the liver were significantly attenuated by administration of Rg1.

Liver damage induced by D-gal disrupts liver cell metabolism which leads to characteristic alterations in serum enzyme activity (32). Alterations in the membrane permeability of liver cells indicate the severity of hepatocellular damage

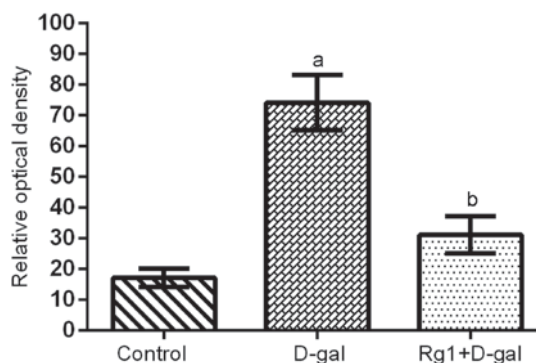


Figure 4. Quantitative analysis of the effect of Rg1 on hepatocyte senescence. Senescence-associated β -galactosidase staining results were quantified. Data are presented as the mean \pm standard deviation, n=10. ^aP<0.05 vs. the control group. ^bP<0.05 vs. the D-gal group. D-gal, D-galactose; Rg1, ginsenoside Rg1.

induced by D-gal (6). In the present study, serum ALT, AST and TBI_L activities increased following treatment with D-gal and significantly decreased following administration of Rg1. Administration of Rg1 increased the level of Alb in serum which decreased following treatment with D-gal. Furthermore, hepatic indices in the D-gal + Rg1 group were reduced compared with the D-gal group. The above results indicate that Rg1 may attenuate liver injury induced by D-gal in mice and therefore serve a protective role in liver damage.

Histological examination is necessary for determination of drug-induced liver protection. Tissues and cells are subjected to oxidative injury when large quantities of free radicals are generated or the activity of the antioxidant system deteriorates. The normal lobular architecture and structure of hepatic cells in the control group was altered in the D-gal group as indicated by hepatocellular necrosis and cytoplasm vacuolar degeneration. An improved architecture of the liver tissue was observed following administration of Rg1. TEM results revealed large numbers of free ribosomes in hepatocytes of the control group; cytoplasmic organelles were present and included mitochondria, RER and normal lysosomes. Following the administration of D-gal, there were numerous electron-dense deposits throughout hepatocyte cytoplasm and cytoplasmic organelles exhibited degenerative signs, including mitochondrial edema, shortened and disrupted RER, or vacuolation. Clumping of nuclear chromatin was observed. The D-gal-induced hepatic injury was attenuated by the administration of Rg1. Therefore, in the present study, administration of Rg1 served a protective role against the development of hepatic necrosis.

D-gal contributes to increased oxidative stress and formation of reactive oxygen species, which may result in hepatocyte damage or death (33). Free radicals may damage a number of cellular components including DNA, proteins and lipids (34,35). Antioxidation serves a protective role against D-gal-induced liver injury. SOD, which reduces the levels of superoxide anions and aids in the synthesis of hydrogen peroxide, is widely distributed in cells and protects from oxidative damage (36). GSH-Px catalyzes the reduction of hydrogen peroxide and lipid peroxide to non-toxic products and scavenges highly reactive lipid peroxides in the aqueous phase of the cell membrane (37). SOD and GSH-Px are important enzymes that participate in the removal of ROS from the cellular environment. GSH, an endogenous antioxidant, exhibits a particularly high concentration in the liver and is known for its key function as an electron donor during ROS metabolism and scavenge (38). Furthermore, GSH, GSH-Px and SOD decrease the levels of ROS to prevent the oxidation of proteins, lipids and DNA (39). MDA is an end-product of ROS-induced peroxidation, and it is commonly used as an oxidative stress biomarker (40). 8-OH-dG, a product of DNA oxidation, is a marker of oxidative DNA damage (41). The activity of SOD and GSH-Px, and the contents of GSH, MDA and 8-OH-dG may be used to measure the level of oxidative stress in cells (42), and to evaluate the protective effect of Rg1. In the present study, Rg1 increased the activity of SOD and GSH-Px and the contents of GSH compared with the D-gal group (43). Furthermore, treatment with Rg1 reduced the increase in the expression levels of MDA and 8-OH-dG caused by injury (44). These results indicated that Rg1 may act by enhancing the activity of endogenous antioxidative enzymes in cells and reducing the levels of peroxidation products.

Cell senescence is due to cellular damage caused by ROS (45). It has been reported that D-gal causes hepatocyte damage, induces cellular senescence and results in hepatic injury (46,47). Lysosomal dysfunction results in accumulation of SA- β -gal in aging cells, and, therefore, SA- β -gal is one of the most widely used biomarkers of aging (22). Furthermore, determination of cellular accumulation of AGEs may also be used to detect cellular aging (48). Both SA- β -gal and AGEs are common biomarkers used to evaluate senescence (49,50). The present study indicated that Rg1 inhibited cellular aging, which supports the results of a previous study where Rg1 alleviated senescence of hematopoietic stem/progenitor cells (51). Treatment with D-gal markedly increased the ROD value of SA- β -gal-positive cells and increased the accumulation of AGEs compared with the control group. D-gal-induced alterations were attenuated following treatment with Rg1. These results of the present suggest that Rg1 may alleviate the effects of D-gal on liver aging, and the underlying mechanism may be associated with the reduction of oxidative stress injury in cells.

In conclusion, the present study indicated that Rg1 improved the resistance of hepatic cells to D-gal-induced subacute liver injury in an *in vivo* mouse model. The results indicated that Rg1 exerted protective effects through its antioxidative properties, alleviation of DNA damage induced by chronic oxidative stress and enhanced activity of endogenous antioxidative defense enzymes. The present study may provide a theoretical and experimental basis for the application of Rg1 in the treatment of liver injury.

Acknowledgements

Not applicable.

Funding

The present study was supported by the National Natural Science Foundation of China (grant no. 81673748).

Availability of data and materials

The datasets used and/or analyzed during the current study are available from the corresponding author on reasonable request.

Authors' contributions

MHX, JYX and YPW conceived and designed the experiments of the current study. Performed the experiments: JYX, MHX, ZWL, WXH, YLF, DYJ, JL, PWJ and LW performed the experiments. JYX, MHX, JL and LW analyzed the data. WL, WXH and YLF provided reagents, materials and analysis tools. MHX and JX wrote the manuscript.

Ethics approval and consent to participate

All animal experiments were performed in accordance with the institutional and national guidelines and regulations, and approved by the Chongqing Medical University Animal Care and Use Committee.

Patient consent for publication

Not applicable.

Competing interests

The authors declare that they have no competing interests.

References

1. Kashaw V, Kumar AN and Agarwal A: Hepatoprotective prospective of herbal drugs and their vesicular carriers-a review. *Int J Res Pharmaceutical Biomedical Sci* 2: 360-374, 2011.
2. Lieber CS: Role of oxidative stress and antioxidant therapy in alcoholic and nonalcoholic liver diseases. *Adv Pharmacol* 38: 601-628, 1997.
3. Plumel MI, Benhaim-Delarbre M, Rompais M, Thiersé D, Sorci G, van Dorsselaer A, Criscuolo F and Bertile F: Differential proteomics reveals age-dependent liver oxidative costs of innate immune activation in mice. *J Proteomics* 135: 181-190, 2016.
4. Yan HD, Li XZ, Xie JM and Li M: Effects of advanced glycation end products on renal fibrosis and oxidative stress in cultured NRK-49F cells. *Chin Med J (Engl)* 120: 787-793, 2007.
5. Cui X, Zuo P, Zhang Q, Li X, Hu Y, Long J, Packer L and Liu J: Chronic systemic D-galactose exposure induces memory loss, neurodegeneration, and oxidative damage in mice: Protective effects of R-alpha-lipoic acid. *J Neurosci Res* 83: 1584-1590, 2006.
6. Ktari N, Nasri R, Mnafigui K, Hamden K, Belguith O, Boudaouara T, El Feki A and Nasri M: Antioxidative and ACE inhibitory activities of protein hydrolysates from zebra blenny (*Salaria basilisca*) in alloxan-induced diabetic rats. *Process Biochemistry* 49: 890-897, 2014.
7. Arauz J, Ramos-Tovar E and Muriel P: Redox state and methods to evaluate oxidative stress in liver damage: From bench to bedside. *Ann Hepatol* 15: 160-173, 2016.

8. Cordoba J: New assessment of hepatic encephalopathy. *J Hepatol* 54: 1030-1040, 2011.
9. Triantafyllou K, Vlachogiannakos J and Ladas SD: Gastrointestinal and liver side effects of drugs in elderly patients. *Best Pract Res Clin Gastroenterol* 24: 203-215, 2010.
10. Xue XL, Wu XY, Xing JM, Li L, Zhao Y, Wang JJ, Zhang YJ, Wang QB, Tang Y, Li GR, *et al*: Xiaopi-yishen herbal extract granule improves the quality of life among people with fatigue-predominant Subhealth and liver-qi stagnation and spleen-qi deficiency syndrome. *Evid Based Complement Alternat Med* 2012: 509705, 2012.
11. Cheng Y, Shen LH and Zhang JT: Anti-amnestic and anti-aging effects of ginsenoside Rg1 and Rb1 and its mechanism of action. *Acta Pharmacol Sin* 26: 143-149, 2005.
12. Chen X, Zhang J, Fang Y, Zhao C and Zhu Y: Ginsenoside Rg1 delays tert-butyl hydroperoxide-induced premature senescence in human WI-38 diploid fibroblast cells. *J Gerontol A Biol Sci Med Sci* 63: 253-264, 2008.
13. Tao T, Chen F, Bo L, Xie Q, Yi W, Zou Y, Hu B, Li J and Deng X: Ginsenoside Rg1 protects mouse liver against ischemia-reperfusion injury through anti-inflammatory and anti-apoptosis properties. *J Surg Res* 191: 231-238, 2014.
14. Tian W, Chen L, Zhang L, Wang B, Li XB, Fan KR, Ai CH, Xia X, Li SD and Li Y: Effects of ginsenoside Rg1 on glucose metabolism and liver injury in streptozotocin-induced type 2 diabetic rats. *Genet Mol Res* 16, 2017.
15. Qi B, Zhang S, Guo D, Guo S, Jiang X and Zhu X: Protective effect and mechanism of ginsenoside Rg1 on carbon tetrachloride-induced acute liver injury. *Mol Med Rep* 16: 2814-2822, 2017.
16. Garcia G, Tagliaferro P, Ferri A, Evangelista de Duffard AM, Duffard R and Brusco A: Study of tyrosine hydroxylase immunoreactive neurons in neonate rats lactationally exposed to 2,4-dichlorophenoxyacetic acid. *Neurotoxicology* 25: 951-957, 2004.
17. Chandra K, Salman AS, Mohd A, Sweetey R and Ali KN: Protection against FCA induced oxidative stress induced DNA damage as a model of arthritis and In vitro anti-arthritis potential of *Costus speciosus* Rhizome extract. *Int J Pharmacognosy Phytochemical Res* 7: 383-389, 2015.
18. Schlieve CR, Lieven CJ and Levin LA: Biochemical activity of reactive oxygen species scavengers do not predict retinal ganglion cell survival. *Invest Ophthalmol Vis Sci* 47: 3878-3886, 2006.
19. Yu J, Chen Y, Zhai L, Zhang L, Xu Y, Wang S and Hu S: Antioxidative effect of ginseng stem-leaf saponins on oxidative stress induced by cyclophosphamide in chickens. *Poult Sci* 94: 927-933, 2015.
20. Chang YT, Chang WN, Tsai NW, Huang CC, Kung CT, Su YJ, Lin WC, Cheng BC, Su CM, Chiang YF and Lu CH: The roles of biomarkers of oxidative stress and antioxidant in Alzheimer's disease: A systematic review. *Biomed Res Int* 2014: 182303, 2014.
21. Sigler K, Chaloupka J, Brozmanová J, Stadler N and Höfer M: Oxidative stress in microorganisms-I. Microbial vs. higher cells-damage and defenses in relation to cell aging and death. *Folia Microbiologica* 44: 587-624, 1999.
22. Dimri GP, Lee X, Basile G, Acosta M, Scott G, Roskelley C, Medrano EE, Linskens M, Rubelj I, Pereira-Smith O, *et al*: A biomarker that identifies senescent human cells in culture and in aging skin in vivo. *Proc Natl Acad Sci USA* 92: 9363-9367, 1995.
23. Kregel KC and Zhang HJ: An integrated view of oxidative stress in aging: Basic mechanisms, functional effects, and pathological considerations. *Am J Physiol Regulatory Integrative Comp Physiol* 292: R18-R36, 2007.
24. Goldin A, Beckman JA, Schmidt AM and Creager MA: Advanced glycation end products: Sparking the development of diabetic vascular injury. *Circulation* 114: 597-605, 2006.
25. Park S, Kim CS, Lee J, Suk Kim J and Kim J: Effect of regular exercise on the histochemical changes of d-galactose-induced oxidative renal injury in high-fat diet-fed rats. *Acta Histochem Cytochem* 46: 111-119, 2013.
26. Kaviani E, Rahmani M, Kaeidi A, Shamsizadeh A, Allahtavakoli M, Mozafari N and Fatemi I: Protective effect of atorvastatin on d-galactose-induced aging model in mice. *Behav Brain Res* 334: 55-60, 2017.
27. Ho SC, Liu JH and Wu RY: Establishment of the mimetic aging effect in mice caused by D-galactose. *Biogerontology* 4: 15-18, 2003.
28. Keppler D, Lesch R, Reutter W and Decker K: Experimental hepatitis induced by D-galactosamine. *Exp Mol Pathol* 9: 279-290, 1968.
29. El-Mofty SK, Scrutton MC, Serroni A, Nicolini C and Farber JL: Early, reversible plasma membrane injury in galactosamine-induced liver cell death. *Am J Pathol* 79: 579-596, 1975.
30. Wei H, Li L, Song Q, Ai H, Chu J and Li W: Behavioural study of the D-galactose induced aging model in C57BL/6J mice. *Behav Brain Res* 157: 245-251, 2005.
31. Guerrieri F, Pellicchia G and Papa S: Reactive oxygen species (ROS) and alteration of F0F1-ATP synthase in aging and liver regeneration. *Free Radicals Oxidative Stress and Antioxidants* 296: 109-1191, 1998.
32. Wu YH, Hao BJ, Cao HC, Xu W, Li YJ and Li LJ: Anti-Hepatitis B virus effect and possible mechanism of action of 3,4-O-Dicaffeoylquinic acid in vitro and in vivo. *Evid Based Complement Alternat Med* 2012: 1-9, 2012.
33. Liu LM, Zhang JX, Luo J, Guo HX, Deng H, Chen JY and Sun SL: A role of cell apoptosis in lipopolysaccharide (LPS)-induced nonlethal liver injury in D-galactosamine (D-GalN)-sensitized rats. *Dig Dis Sci* 53: 1316-1324, 2008.
34. Das SK and Vasudevan DM: Alcohol-induced oxidative stress. *Life Sci* 81: 177-187, 2007.
35. Lieber CS: Pathogenesis and treatment of alcoholic liver disease: Progress over the last 50 years. *Rocz Akad Med Białymst* 50: 7-20, 2005.
36. Muller FL, Song W, Liu Y, Chaudhuri A, Pieke-Dahl S, Strong R, Huang TT, Epstein CJ, Roberts LJ II, Csete M, *et al*: Absence of CuZn superoxide dismutase leads to elevated oxidative stress and acceleration of age-dependent skeletal muscle atrophy. *Free Radic Biol Med* 40: 1993-2004, 2006.
37. Halliwell B and Gutteridge JMC: Free radicals in biology and medicine. *J Free Radicals Biol Med* 1: 331-332, 2007.
38. Townsend DM, Tew KD and Tapiero H: The importance of glutathione in human disease. *Biomed Pharmacother* 57: 145-155, 2003.
39. Yuan L and Kaplowiyz N: Glutathione in liver diseases and hepatotoxicity. *Mol Aspects Med* 30: 29-41, 2009.
40. Dahake H, Warade J, Kansara G, Pawade Y and Ghangle S: Study of malondialdehyde as an oxidative stress marker in schizophrenia. *Int J Res Med Sci* 4: 730-4734, 2016.
41. Mizoue T, Tokunaga S, Kasai H, Kawai K, Sato M and Kubo T: Body mass index and oxidative DNA damage: A longitudinal study. *Cancer Sci* 98: 1254-1258, 2007.
42. Sharma JB, Sharma A, Bahadur A, Vimala N, Satyam A and Mittal S: Oxidative stress marker and antioxidant levels in normal pregnancy and preeclampsia. *Int J Gynecol Obstet* 94: 23-27, 2006.
43. Hailiqian T, Kang JS and Sun L: Effects of aqueous extract of *Hedysarum austrosibiricum* on metabolism of oxygen free radicals in subacute aging mice caused by D-galactose. *Zhongguo Zhong Yao Za Zhi* 32: 729-731, 2007 (In Chinese).
44. Fan Y, Xia J, Jia D, Zhang M, Zhang Y, Huang G and Wang Y: Mechanism of ginsenoside Rg1 renal protection in a mouse model of d-galactose-induced subacute damage. *Pharm Biol* 54: 1815-1821, 2016.
45. Davalli P, Mitic T, Caporali A, Lauriola A and D'Arca D: ROS, cell senescence, and novel molecular mechanisms in aging and age-related diseases. *Oxid Med Cell Longev* 2016: 3565127, 2016.
46. Wang Y, Schulte BA, LaRue AC, Ogawa M and Zhou D: Total body irradiation selectively induces murine hematopoietic stem cell senescence. *Blood* 107: 358-366, 2006.
47. Wang Y, Liu L, Pazhanisamy SK, Li H, Meng A and Zhou D: Total body irradiation causes residual bone marrow injury by induction of persistent oxidative stress in murine hematopoietic stem cells. *Free Radic Biol Med* 48: 348-356, 2010.
48. Zhu XF and Zou HD: PEDF in diabetic retinopathy: A protective effect of oxidative stress. *J Biomed Biotechnol* 2012: 580687, 2012.
49. Gruber HE, Ingram JA, Norton HJ and Hanley EN Jr: Senescence in cells of the aging and degenerating intervertebral disc: Immunolocalization of senescence-associated beta-galactosidase in human and sand rat discs. *Spine (Phila Pa 1976)* 32: 321-327, 2007.
50. Park CH and Kim JW: Effect of advanced glycation end products on oxidative stress and senescence of trabecular meshwork cells. *Korean J Ophthalmol* 26: 123-131, 2012.
51. Chen C, Mu XY, Zhou Y, Shun K, Geng S, Liu J, Wang JW, Chen J, Li TY and Wang YP: Ginsenoside Rg1 enhances the resistance of hematopoietic stem/progenitor cells to radiation-induced aging in mice. *Acta Pharmacol Sin* 35: 143-150, 2014.

