

A practical continuous curvilinear capsulorhexis self-training system

Jing Dong*, Xiaogang Wang^{1*}, Xiaoliang Wang², Junhong Li¹

Purpose: To describe a practical, self-assembled continuous curvilinear capsulorhexis (CCC) self-training system to facilitate resident self-training and shorten the CCC learning curve. **Methods:** This was a prospective experimental study that included a total of 600 capsulorhexis cases. A device for CCC practice was self-assembled and used for training and testing. Based on capsulorhexis manipulation experience, three main groups of residents (A, capsulorhexis experience with <50 cases; B, capsulorhexis experience with 400–500 cases; and C, capsulorhexis experience with >1000 cases) were created. Furthermore, based on different capsulorhexis conditions, each main group was divided into four subgroups (1, CCC without an anterior chamber cover and capsulorhexis marker; 2, CCC with an anterior chamber cover without a capsulorhexis marker; 3, CCC with an anterior chamber cover and a capsulorhexis marker; and 4, CCC with an anterior chamber cover and a capsulorhexis marker under 2.5 times magnification). Three CCC-related parameters, including acircularity index (AI), axis ratio (AR), and capsulorhexis time, were statistically evaluated. **Results:** We compared the differences in study parameters among 50 consecutively completed capsulorhexis cases by one trainee with different capsulorhexis experience in each subgroup. The CCC-related parameter values in subgroups 1 and 4 were significantly different among the three groups ($P < 0.001$). The capsulorhexis time in subgroup 2 was significantly different among the three groups ($P < 0.001$). The capsulorhexis time and AI in subgroup 3 were significantly different among the three groups ($P < 0.001$). Moreover, with increasing manipulation experience (from group A–C), the capsulorhexis time, the AI, and AR tended to decrease. With the help of the CCC marker, in subgroups 3 and 4, the AI and AR were closer to 1.0. **Conclusion:** This self-assembled CCC self-training system is practical. The CCC marker seems helpful for size specification and centration during self-training.

Key words: Acircularity index, axis ratio, cataract residents surgical training, continuous curvilinear capsulorhexis

Continuous curvilinear capsulorhexis (CCC), an extremely important step during cataract surgical procedure, has enhanced the efficiency and safety of phacoemulsification and extracapsular extraction techniques.^[1] Furthermore, the surgical step has contributed to the development of technologies related to phacoemulsification, such as hydrodissection, hydrodelineation, nucleus rotation, phaco-chop, and intraocular lens (IOL) implantation. In addition to the anterior capsule, the CCC technique can be used for the posterior capsule to manage potential posterior capsule opacification due to implanted diffractive multifocal IOL or pediatric cataract surgery with IOL optic capture.^[2–4] In the current era of refractive cataract surgeries, parameters such as CCC size and centration with uniform IOL optic coverage will affect the effective lens position, IOL stability, and toric IOL rotation, eventually affecting postoperative refractive outcomes. Therefore, these factors are directly correlated with patient satisfaction.^[5–8] Various methods and technologies have been developed to improve the precision of CCC, such as the

corneal capsulorhexis marker, digital image guidance system, femtosecond laser capsulotomy, diathermic high-frequency capsulorhexis, and thermal capsulotomy.^[9–15] However, due to costs, time, and lack of significant advances, a large proportion of cataract surgery still uses manual CCC.^[16]

Based on current disharmonious doctor–patient relationships, training residents to improve cataract surgical skills in real cases has many challenges.^[17] Reports have indicated that repeated practice using animal eyes or simulators can improve surgical performance in actual clinical settings.^[18,19] Moreover, surgical complications associated with residents can be prevented by adequate preclinical training using animal eyes (eyes of pigs and rabbits) and virtual reality-based surgical simulation systems.^[20–22] However, most residency training systems cannot provide enough facilities for all residents' training.^[23–26] Moreover, currently, there is no economic and practical self-training model to practice all key factors of CCC, such as pivot skills and different incision sizes.^[27,28] Therefore, in this study, we introduce a practical, self-assembled, and self-designed training model to support CCC training and have evaluated its feasibility in training residents.

The First Hospital of Shanxi Medical University, Taiyuan, Shanxi, ¹Shanxi Eye Hospital Affiliated to Shanxi Medical University, Taiyuan, Shanxi, ²School of Aeronautics and Astronautics, Shanghai Jiao Tong University, Shanghai, P.R. China

*These two authors contributed equally to this work.

Correspondence to: Dr. Junhong Li, Department of Ophthalmology, Shanxi Eye Hospital Affiliated to Shanxi Medical University, No. 100 Fudong St, Xinghualing District, Taiyuan 030002, Shanxi, P.R. China. E-mail: 107504056@qq.com

Received: 25-Jan-2021

Revision: 07-Jun-2021

Accepted: 30-Jun-2021

Published: 25-Sep-2021

Video Available on:

www.ijo.in

Access this article online

Website:

www.ijo.in

DOI:

10.4103/ijo.IJO_210_21

Quick Response Code:



This is an open access journal, and articles are distributed under the terms of the Creative Commons Attribution-NonCommercial-ShareAlike 4.0 License, which allows others to remix, tweak, and build upon the work non-commercially, as long as appropriate credit is given and the new creations are licensed under the identical terms.

For reprints contact: WKHLRPMedknow_reprints@wolterskluwer.com

Cite this article as: Dong J, Wang X, Wang X, Li J. A practical continuous curvilinear capsulorhexis self-training system. Indian J Ophthalmol 2021;69:2678–86.

Methods

This prospective experimental study was conducted at xxxx. The research protocol was approved by the institutional review board of xxxx and performed according to the tenets of the Declaration of Helsinki.

Group information

Based on the total capsulorhexis manipulation experience on virtual eyes and human eyes of three residents, three main groups (A group, B group, C group) were divided. A group comprised of a resident with capsulorhexis experience <50 cases; B group comprised of a resident with capsulorhexis experience about 400–500 cases; and C group comprised of a resident with capsulorhexis experience >1000 cases. Furthermore, based on different capsulorhexis conditions, each main group was divided into four subgroups [Fig. 1].

Device description

As shown in Fig. 2, this self-designed CCC device mainly consists of the following four parts: (1) an anterior chamber cover consisting of a transparent corneal and pigmented iris. The device has an anterior chamber structure similar to the real ocular structure (corneal diameter, approximately 12 mm; anterior chamber depth, approximately 3.0 mm; pupil size, approximately 7.0 mm); (2) an inlet for the capsulorhexis forceps or cystotome: this rectangle inlet (width, 1.8–3.2 mm [depending on the main incision width required in an actual surgery]; height, approximately 2.0 mm); (3) an anterior capsule replacement: commercial tinfoil paper (10 μm) with or without a 5.5-mm colorful ring; and (4) a subplate: an approximately 2-cm-thick foamed plastic material which simulates the cortex under the anterior capsule and provide the same consistency experienced during capsule puncture and raising the capsule.

Manipulation procedure

CCC manipulation was done using smartphone screen magnification, 2.5 times mimicking the microscope function (unexpected small CCC profile enlargement to a regular size CCC). The following steps were used for the CCC procedure: (1) A cystotome (a bent, 27-gauge needle) or an appropriately sized capsulorhexis forceps (1.8, 2.2, 3.0 mm) with parallel needle tip to the enter anterior chamber cover through the specific inlet is used for the procedure; (2) turn the cystotome or capsulorhexis forceps clockwise and punch the center of target CCC to raise the flap; (3) seize or control the capsule flap for a clockwise or counterclockwise CCC using a pivot, with or without the CCC marker [Fig. 3]. The CCC time was defined as the time period from the beginning of raising the flap to successful removal of whole flap from the anterior chamber.

Image data extraction and evaluation

The tinfoil paper used for CCC training was scanned to acquire a digital image. After image acquisition, the acircularity index (AI) and axis ratio (AR) of the CCC profile were analyzed using MATLAB R2009a (the MathWorks, Inc., Natick, Massachusetts, USA) with version 7.8.0.347 [Fig. 4].

The AI was defined as the ratio of the perimeter of the CCC to the perimeter of a circle with an equivalent area.^[29] The AI is 1 for a perfectly circular CCC; the values become higher with a corresponding increase in the irregularity of CCC. The AR was defined as the ratio of the major and minor axes of an ellipse and is calculated using MATLAB's region props function using the second-order moments.^[30,31] The AR is 1 for a perfectly circular CCC; AR becomes higher with greater eccentricity and elongated CCC. To validate the MATLAB algorithm used, we used foveal avascular zone figures by Krawitz *et al.*^[31] The final result of testing was similar to their published data, which demonstrated that MATLAB

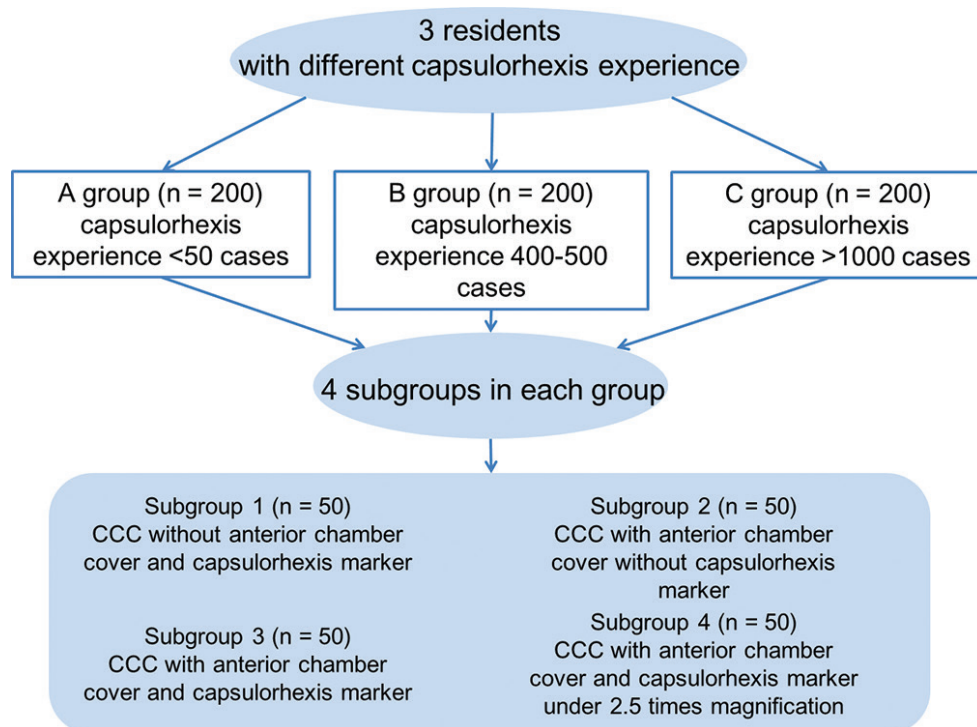


Figure 1: The flow diagram of this study

Table 1: The capsulorhexis-related complications during the successful completion of consecutive 50 cases in each group

	A group				B group				C group			
	1	2	3	4	1	2	3	4	1	2	3	4
Tearing	5 (10%)	14 (28%)	16 (32%)	49 (98%)	5 (10%)	5 (10%)	5 (10%)	6 (12%)	4 (8%)	3 (6%)	3 (6%)	0 (0%)
Residual flap	11 (22%)	18 (36%)	17 (34%)	30 (60%)	7 (14%)	7 (14%)	2 (4%)	3 (6%)	1 (2%)	0 (0%)	0 (0%)	0 (0%)
Tearing plus residual flap	0 (0%)	4 (8%)	2 (4%)	6 (12%)	0 (0%)	0 (0%)	0 (0%)	0 (0%)	0 (0%)	0 (0%)	0 (0%)	0 (0%)
Raising flap failure	1 (2%)	2 (4%)	0 (0%)	2 (4%)	0 (0%)	1 (2%)	0 (0%)	0 (0%)	0 (0%)	0 (0%)	0 (0%)	0 (0%)
Laceration of surrounding capsule	0 (0%)	0 (0%)	0 (0%)	2 (4%)	0 (0%)	2 (4%)	0 (0%)	1 (2%)	0 (0%)	0 (0%)	0 (0%)	0 (0%)

A group=capsulorhexis experience with <50 cases; B group=capsulorhexis experience with 400-500 cases; C group=capsulorhexis experience with >1000 cases; 1=subgroup without the anterior chamber cover and the CCC marker; 2=subgroup with the anterior chamber cover but without the CCC marker; 3=subgroup with the anterior chamber cover and the CCC marker; 4=subgroup under 2.5 times magnification with the anterior chamber cover and the CCC marker

Table 2: The mean capsulorhexis parameters and corresponding data range in each group

	A group (n=200)				B group (n=200)				C group (n=200)			
	1	2	3	4	1	2	3	4	1	2	3	4
Time (seconds)	44±11 (28-83)	50±16 (25-103)	41±13 (22-92)	60±26 (31-180)	24±9 (12-61)	33±8 (16-49)	34±11 (21-75)	39±11 (23-72)	12±3 (7-22)	21±8 (10-42)	23±6 (13-46)	29±9 (16-50)
AI	1.07±0.01 (1.04-1.10)	1.06±0.01 (1.04-1.11)	1.06±0.01 (1.04-1.09)	1.06±0.01 (1.04-1.09)	1.06±0.01 (1.05-1.09)	1.06±0.01 (1.05-1.09)	1.06±0.01 (1.05-1.08)	1.05±0.01 (1.04-1.07)	1.06±0.01 (1.03-1.07)	1.06±0.01 (1.04-1.08)	1.05±0.01 (1.04-1.06)	1.05±0.01 (1.04-1.06)
AR	1.15±0.09 (1.00-1.44)	1.15±0.10 (1.02-1.27)	1.11±0.10 (1.02-1.40)	1.15±0.09 (1.02-1.40)	1.12±0.06 (1.02-1.30)	1.14±0.08 (1.02-1.36)	1.10±0.05 (1.01-1.23)	1.11±0.05 (1.04-1.29)	1.10±0.05 (1.01-1.22)	1.13±0.05 (1.03-1.24)	1.10±0.04 (1.01-1.20)	1.08±0.04 (1.02-1.20)

A group=capsulorhexis experience with <50 cases; B group=capsulorhexis experience with 400-500 cases; C group=capsulorhexis experience with >1000 cases; 1=subgroup without the anterior chamber cover and the CCC marker; 2=subgroup with the anterior chamber cover but without the CCC marker; 3=subgroup with the anterior chamber cover and the CCC marker; 4=subgroup under 2.5 times magnification with the anterior chamber cover and the CCC marker; AI=acircularity index; AR=axis ratio

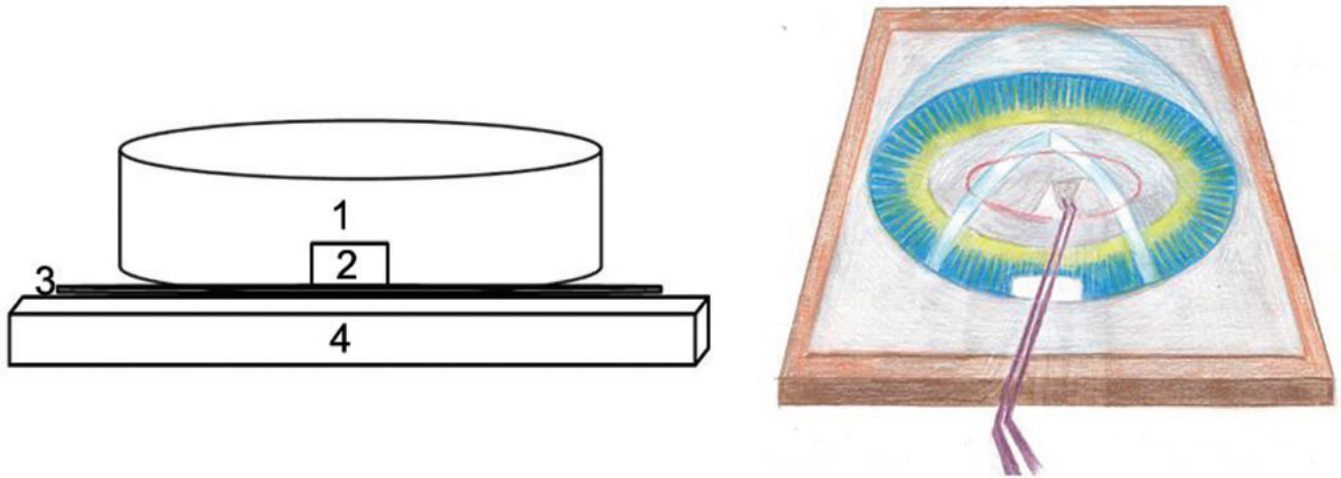


Figure 2: The schematic diagram (left side) and corresponding freehand stereogram (right side) of the self-designed continuous curvilinear capsulorhexis training device (anterior view). 1, an anterior chamber cover; 2, the inlet of capsulorhexis or cystotome; 3, anterior capsule replacement (tin foil paper in the current study); and 4, a subplate




Figure 3: The complete set of our CCC device and demonstration of several real-life cases. Panel A: the complete set of this device, including the anterior chamber cover, cystotome, capsulorhexis forceps, red ink, CCC marker, and ruler; Panel B: the part of the tinfoil paper with finished CCC; Panel C: CCC without the anterior chamber cover and the CCC marker; Panel D: CCC with the anterior chamber cover (red circle) and cystotome; Panel E: CCC with the anterior chamber cover and capsulorhexis forceps; Panel F: CCC with the anterior chamber cover and the CCC marker (red circle with 5-5 mm diameter) made using a capsulorhexis forceps; Panel G: finished capsulorhexis flaps. CCC, continuous curvilinear capsulorhexis

code used in this study is acceptable for CCC parameters analysis [Fig. 5].

Statistical analyses

All statistical analyses were performed with a commercially available software (SPSS ver. 13.0; SPSS Inc.). Kruskal–Wallis H test, a subtype of nonparametric tests, was used to compare the CCC

time, AI, and AR data among the study groups and subgroups in this study. The significance level for all tests was set at 5%.

Results

As demonstrated in Figs. 2, 3, and Video 1, each resident can self-assemble this device. Furthermore, the resident still can

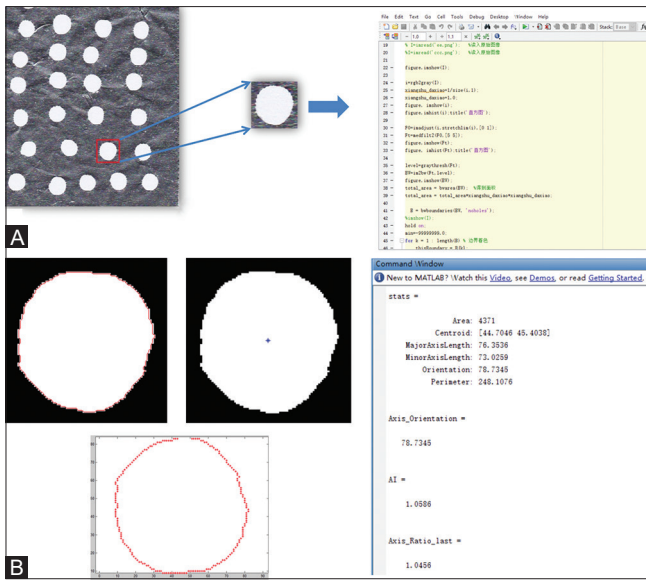


Figure 4: Data extraction of CCC-related parameters. Panel A represents one case of CCC and the MATLAB code used in this study; Panel B represents the CCC boundary detection and final output values of the CCC-related parameters (acircularity index, axis ratio, perimeter, and area). CCC, continuous curvilinear capsulorhexis

mimic CCC-related complications (tearing out CCC saving, small CCC enlargement) to deal with the corresponding surgical skills. After training for approximately 1000 cases with the self-assembled CCC device, the trainees (DJ and WXG) could successfully finish the CCC procedure in the wetlab pig eyes and real-life surgical cases. Using 2.5 times magnification and the practical CCC marker, the trainees could correctly experience and feel the capsulorhexis size and shape encountered in actual clinical settings.

Capsulorhexis complications, including tearing, residual flap, failure of raising the flap, and surrounding capsule laceration were found in this study [Fig. 6]. Table 1 demonstrates capsulorhexis complications information during successful consecutive 50 cases manipulation using this device. Tearing and residual flap were the two main complications for A group, which demonstrated that these two complications should be mainly noticed at the beginning of capsulorhexis learning. With practice cases increasing, all the complications demonstrated significantly lower tendency in B and C groups, which showed the potential learning curve.

We included 50 consecutive completed cases in each subgroup of the three main groups. Table 2 shows average capsulorhexis parameters for each group. The values of all CCC-related parameters in subgroups 1 and 4 were

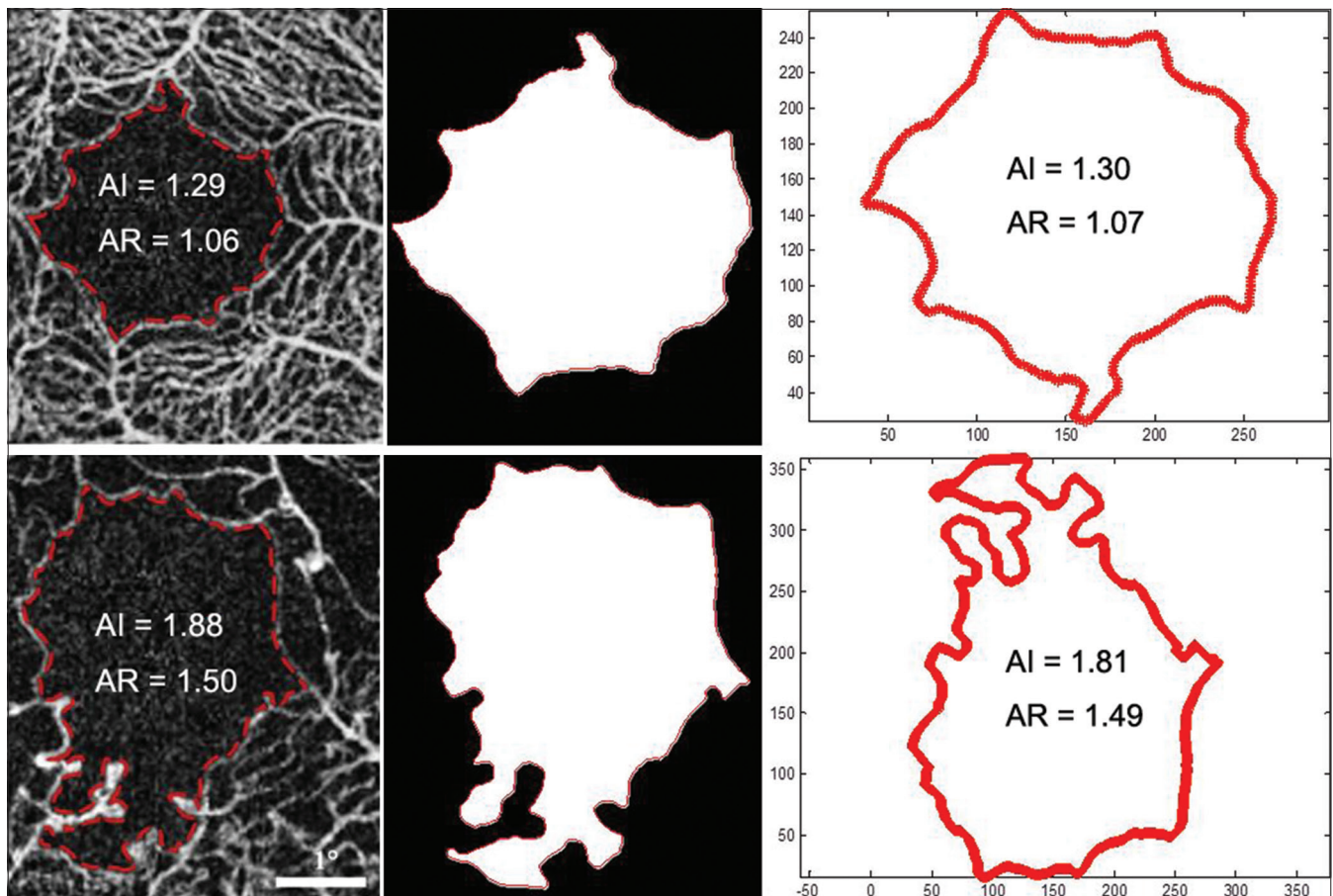


Figure 5: Validation of the acircularity index (AI) and axis ratio (AR) values that were estimated by our MATLAB algorithm using published data (first row: Figure 3 panel A; second row: Figure 3 panel D) of Krawitz *et al.*'s study.^[28] Images on the left represent the published output data; images on the right show our output values for foveal avascular zone boundary and corresponding AI and AR. The middle images show the foveal avascular zone extracted using our algorithm

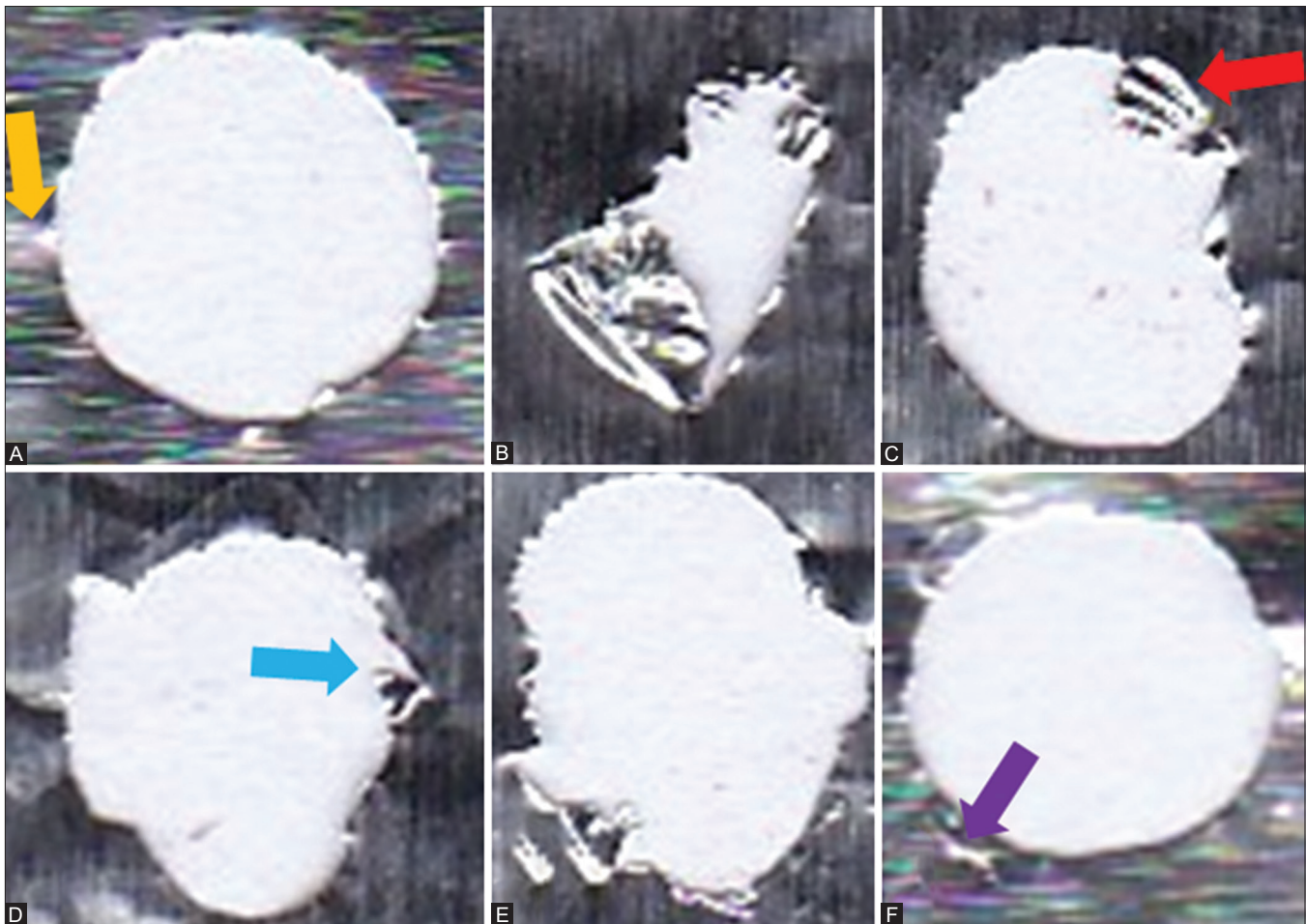


Figure 6: Capsulorhexis complications during manipulation. Panel A demonstrates a completed CCC case, and the yellow arrow demonstrates the tinfoil paper reflection in the scanning image; Panel B shows raising flap failure; red arrow in Panel C demonstrates wrinkled residual flap; blue arrow in Panel D shows tearing flap; and Panel E demonstrates tearing and residual flap; purple arrow in Panel F demonstrates laceration of the surrounding capsule. CCC, continuous curvilinear capsulorhexis

significantly different among the three groups (Fig. 7; all $P < 0.001$). The values of capsulorhexis time in subgroup 2 were significantly different among the three groups ($P < 0.001$) but not for AI ($P = 0.196$) and AR ($P = 0.924$). The values of capsulorhexis time and AI in subgroup 3 were significantly different among the three groups ($P < 0.001$) but not for AR ($P = 0.518$). Moreover, with increasing manipulation experience (from A group to C group), the capsulorhexis time, the AI, and AR demonstrated to decrease in each subgroup. With the help of the CCC marker in subgroups 3 and 4, the AI and AR were more stable and closer to 1.0, which demonstrated that the CCC marker guidance was helpful for a better CCC profile.

For manipulation experience with >1000 cases (C group), the capsulorhexis time increased with more restrictions (anterior chamber cover, CCC marker, 2.5 times magnification). Moreover, the AI and AR were more stable and getting closer to a perfect circle with the help of the CCC marker [Fig. 8].

Discussion

In this study, we introduced a self-designed CCC resident training system. This training system was helpful for training residents. Moreover, with the help of the CCC marker, the capsulorhexis size and centration can be improved.

The previously developed CCC practice materials and training systems have the following limitations: (1) grape or persimmon: lack of an anterior chamber and incision structure due to the limitations of an anterior chamber and incision operation space. This leads to a lack of practice in the pivot concept needed during CCC manipulation^[24,25]; with our self-designed system, the practitioner can use plastic covers of other products to mimic the anterior chamber cover, with a specific size inlet to train the pivot concept needed during CCC; (2) rabbit or pig eyes: it is difficult to maintain the corneal transparency at all times, and moreover, cannot be practiced anywhere without supply limitations; (3) all types of training simulators, such as the Eyesi ophthalmic virtual reality surgical simulator^[32,33]: providing good results for resident training and reducing the unnecessary risk of CCC-related complications for live patients, but not available for training each resident or even in each hospital, and moreover, simulators are expensive. In this study, our self-designed CCC device can overcome the above-mentioned limitations faced during CCC training. More importantly, our system can be used anywhere, anytime, without any practice limitations, and it may shorten the learning curves of resident for CCC.

After training for >1000 cases, the AI and AR in the without CCC marker group was approximately 1.06 and 1.13,

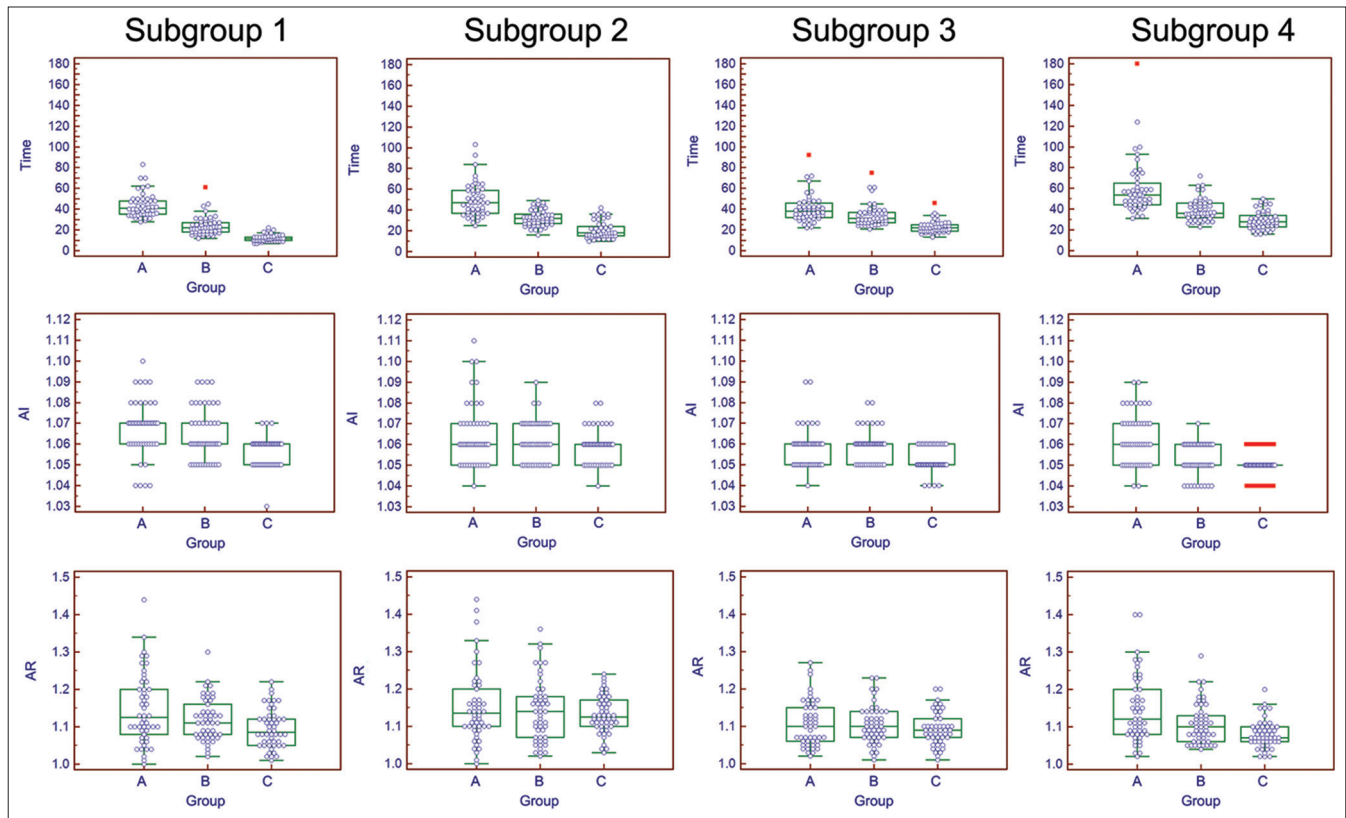


Figure 7: Comparison of output parameters in each subgroup among the three groups illustrated using box-and-whisker plots. A group = capsulorhexis experience with <50 cases; B group = capsulorhexis experience with 400–500 cases; C group = capsulorhexis experience with >1000 cases; subgroup 1 = without the anterior chamber cover and the CCC marker; subgroup 2 = with the anterior chamber cover but without the CCC marker; subgroup 3 = with the anterior chamber cover and the CCC marker; and subgroup 4 = under 2.5 times magnification with the anterior chamber cover and the CCC marker. CCC, continuous curvilinear capsulorhexis

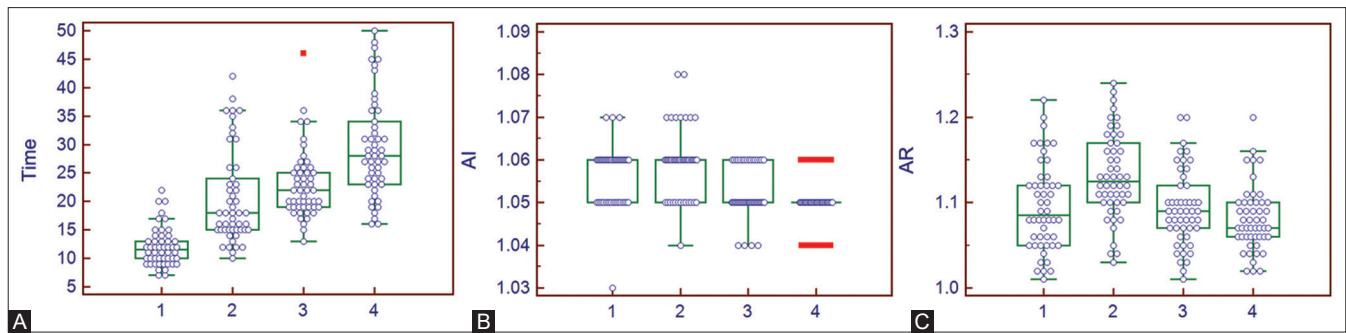


Figure 8: The capsulorhexis time (Panel A), acircularity index (AI, Panel B), and axis ratio (AR, Panel C) changing tendency for group C. 1 = subgroup without the anterior chamber cover and the CCC marker; 2 = subgroup with the anterior chamber cover but without the CCC marker; 3 = subgroup with the anterior chamber cover and the CCC marker; and 4 = subgroup under 2.5 times magnification with the anterior chamber cover and the CCC marker. CCC, continuous curvilinear capsulorhexis

respectively. This result was not significantly different from the ideal circularity number. This observation demonstrated that the use of our training device and repeated training could help a practitioner to learn and control the CCC procedure. The use of the CCC marker helped to obtain lower values of AI and AR than that without the CCC marker, even under the magnification manipulation condition. This demonstrated that the use of the CCC marker could improve the CCC profile and stabilize the procedure, making it reproducible and reliable. Moreover, with our self-designed system, a practitioner can

train to perform saving techniques of tearing capsulorhexis and smaller capsulorhexis.

Our comparison results of subgroups suggested that beginners can plan a learning scheme step by step from subgroups 1–4. With the manipulation restriction conditions from 1 to 4, the trainer is able to gradually practice continuous capsulorhexis, pivot concept, CCC size, and microscope manipulation. Subgroup 1 condition is suitable for beginners without any experience and can help the resident to realize the concept of continuous capsulorhexis. With the anterior

chamber cover and specific size inlet restriction in subgroup 2, the trainee can realize the importance of the pivot concept during CCC. Further combination with the CCC marker in subgroup 3, the trainee gradually realizes the specific stable size CCC awareness building, which is essential and beneficial for currently refractive cataract surgery. With magnification similar to the microscope manipulation practice in subgroup 4, the trainee can actually realize and practice the whole procedure of CCC as a real-life case. Therefore, the four subgroups in this study noticed almost all the CCC-related influencing factors in real life, and this learning protocol could be included in a future resident training system.

Our study had several limitations. First, this device can only be used for CCC training. It does not include the complete phacoemulsification or manual small incision cataract surgical procedure. However, because of the importance of CCC in cataract surgery, this training system works well and will be useful for training residents. Second, CCC practice with our device generally does not combine the use of a microscope; however, practitioners can use a microscope to practice their micromanipulation stability and skills. Alternatively, a real-time smartphone video camera with adequate magnification can be used to simulate microscopic manipulation. Moreover, the feeling and details experienced during an actual CCC can be practiced well using the naked eye. Third, the consistency of the tinfoil paper, which was used to replicate the anterior capsule, differs from the biological capsule. However, we used a 10- μm -thick tinfoil paper, with a thickness similar to that of a human anterior lens capsule (average, 11–15 μm). Last but not least, this device is not able to mimic all the real situations using the current version, such as pediatric cataract, intralenticular pressure in intumescent cataract and hypermature cataract, anterior capsular opacification, etc., but we trust with the development of better capsule imitating material, the above-mentioned imperfection could be improved. Additionally, it can provide the feelings experienced during capsulorhexis manipulation, such as the pivot concept, tearing the flap, puncturing the capsule, and raising the flap.^[34]

Conclusion

In conclusion, we introduce an improved CCC self-training system, which is economical and practical than the systems currently available. Our system is expected to shorten the learning curves of residents for CCC. Further studies, including more residents training evaluation from multiple medical centers, to evaluate the validation and making this a cost-effective and practical training system used as needed.

Ethics approval and consent to participate

The research protocols were approved by the ethics committee of Shanxi Eye Hospital and were conducted in accordance with the tenets of the Declaration of Helsinki.

Acknowledgements

We thank student Yutao Wang for drawing a stereogram of the training device. Moreover, our device system has been patented by the National Intellectual Property Administration, PRC with patent number: ZL 2019 2 0074159.6 and reprinted from acircularity index and axis ratio of the foveal avascular zone in diabetic eyes and healthy controls measured by optical coherence tomography angiography. Krawitz BD, Mo S, Geyman LS, *et al.*, 177-186, Copyright (2017), with permission from Elsevier. The paper's medical English was professionally edited by using Elsevier Language Editing Services.

Financial support and sponsorship

This work was supported by the National Natural Science Foundation of China under Grant no. 81971697. The funders had no role in study design, data collection and analysis, decision to publish, or preparation of the manuscript.

Conflicts of interest

There are no conflicts of interest.

References

- Gimbel HV, Neuhann T. Continuous curvilinear capsulorhexis. *J Cataract Refract Surg* 1991;17:110-1.
- Ouchi M. Primary posterior continuous curvilinear capsulorhexis combined with diffractive multifocal intraocular lens implantation. *Eye (Lond)* 2016;30:95-101.
- Raina UK, Gupta V, Arora R, Mehta DK. Posterior continuous curvilinear capsulorhexis with and without optic capture of the posterior chamber intraocular lens in the absence of vitrectomy. *J Pediatr Ophthalmol Strabismus* 2002;39:278-87.
- Gimbel HV. Posterior continuous curvilinear capsulorhexis and optic capture of the intraocular lens to prevent secondary opacification in pediatric cataract surgery. *J Cataract Refract Surg* 1997;23:652-6.
- Chen M. Refractive cataract surgery-what we were, what we are, and what we will be: A personal experience and perspective. *Taiwan J Ophthalmol* 2019;9:1-3.
- Li S, Hu Y, Guo R, Shao Y, Zhao J, Zhang J, *et al.* The effects of different shapes of capsulorhexis on postoperative refractive outcomes and the effective position of the intraocular lens in cataract surgery. *BMC Ophthalmol* 2019;19:59.
- Okada M, Hersh D, Paul E, van der Straaten D. Effect of centration and circularity of manual capsulorhexis on cataract surgery refractive outcomes. *Ophthalmology* 2014;121:763-70.
- Torquetti L. Toric intraocular lens rotation related to the capsulorhexis. *J Cataract Refract Surg* 2015;41:483.
- Hassaballa MA, Osman AA. Delineating the extent of anterior capsulorhexis with gentian violet using capsulorhexis marker: A preliminary study of efficacy and toxicity in an animal model. *Clin Ophthalmol* 2011;5:831-6.
- Wallace RB, 3rd. Capsulotomy diameter mark. *J Cataract Refract Surg* 2003;29:1866-8.
- Haeussler-Sinangin Y, Dahlhoff D, Schultz T, Dick HB. Clinical performance in continuous curvilinear capsulorhexis creation supported by a digital image guidance system. *J Cataract Refract Surg* 2017;43:348-52.
- Kranitz K, Takacs A, Mihaltz K, Kovács I, Knorz MC, Nagy ZZ. Femtosecond laser capsulotomy and manual continuous curvilinear capsulorhexis parameters and their effects on intraocular lens centration. *J Refract Surg* 2011;27:558-63.
- Friedman NJ, Palanker DV, Schuele G, Andersen D, Marcellino G, Seibel BS, *et al.* Femtosecond laser capsulotomy. *J Cataract Refract Surg* 2011;37:1189-98.
- Hausmann N, Richard G. Investigations on diathermy for anterior capsulotomy. *Invest Ophthalmol Vis Sci* 1991;32:2155-9.
- Hooshmand J, Abell RG, Allen P, Vote BJ. Thermal capsulotomy: Initial clinical experience, intraoperative performance, safety, and early postoperative outcomes of precision pulse capsulotomy technology. *J Cataract Refract Surg* 2018;44:355-61.
- Feldman BH. Femtosecond laser will not be a standard method for cataract extraction ten years from now. *Surv Ophthalmol* 2015;60:360-5.

17. Jing W, Otten H, Sullivan L, Lovell-Simons L, Granek-Catarivas M, Fritzsche K. Improving the doctor-patient relationship in China: The role of balint groups. *Int J Psychiatry Med* 2013;46:417-27.
18. Thomsen AS, Smith P, Subhi Y, Cour M, Tang L, Saleh GM, *et al.* High correlation between performance on a virtual-reality simulator and real-life cataract surgery. *Acta Ophthalmol* 2017;95:307-11.
19. Bozkurt Oflaz A, Ekinci Koktekir B, Okudan S. Does cataract surgery simulation correlate with real-life experience? *Turk J Ophthalmol* 2018;48:122-6.
20. Hashimoto C, Kurosaka D, Uetsuki Y. Teaching continuous curvilinear capsulorhexis using a postmortem pig eye with simulated cataract. *J Cataract Refract Surg* 2001;27:814-6.
21. Alfawaz AM. Ophthalmology resident surgical training: Can we do better? *Saudi J Ophthalmol* 2019;33:159-62.
22. Ruggiero J, Keller C, Porco T, Naseri A, Sretavan DW. Rabbit models for continuous curvilinear capsulorhexis instruction. *J Cataract Refract Surg* 2012;38:1266-70.
23. Gogate PM, Deshpande MD. The crisis in ophthalmology residency training programs. *Indian J Ophthalmol* 2009;57:74-5.
24. Gogate PM, Biswas P, Natarajan S, Ramamurthy D, Bhattacharya D, Golnik K. Residency evaluation and adherence design study: Young ophthalmologists' perception of their residency programs I: Clinical and surgical skills. *Ind J Ophthalmol* 2017;65:452-60.
25. Biswas P, Gogate PM, Maskati QB, Natarajan S, Verma L, Bansal P. Residency evaluation and adherence design study III: Ophthalmology residency training in India: Improving with time? *Ind J Ophthalmol* 2018;66:785-92.
26. Young AL, Jhanji V, Liang Y, Congdon N, Chow S, Wang F, *et al.* A survey of perceived training differences between ophthalmology residents in Hong Kong and China. *BMC Med Edu* 2015;15:158.
27. Lin HY, Chuang YJ, Tang X, Lin CC, Chen HY, Lin PJ. Pivot concept: Achieving a good-quality capsulorhexis through a 2.2 mm or less clear corneal incision by using standard capsulorhexis forceps. *Int J Ophthalmol* 2017;10:1175-7.
28. Figueira EC, Wang LW, Brown TM, Masselos K, Pandya VB, Dauber SL, *et al.* The grape: An appropriate model for continuous curvilinear capsulorhexis. *J Cataract Refract Surg* 2008;34:1610-1.
29. Tam J, Dhamdhare KP, Tiruveedhula P, Manzanera S, Barez S, Bearse MA Jr, *et al.* Disruption of the retinal parafoveal capillary network in type 2 diabetes before the onset of diabetic retinopathy. *Invest Ophthalmol Vis Sci* 2011;52:9257-66.
30. Ming-Kuei H. Visual pattern recognition by moment invariants. *IRE Transactions on Information Theory* 1962;8:179-87.
31. Krawitz BD, Mo S, Geyman LS, Agemy SA, Scripsema NK, Garcia PM, *et al.* Acircularity index and axis ratio of the foveal avascular zone in diabetic eyes and healthy controls measured by optical coherence tomography angiography. *Vision Res* 2017;139:177-86.
32. McCannel CA, Reed DC, Goldman DR. Ophthalmic surgery simulator training improves resident performance of capsulorhexis in the operating room. *Ophthalmology* 2013;120:2456-61.
33. Lam CK, Sundaraj K, Sulaiman MN, Qamarruddin FA. Virtual phacoemulsification surgical simulation using visual guidance and performance parameters as a feasible proficiency assessment tool. *BMC Ophthalmol* 2016;16:88.
34. Barraquer RI, Michael R, Abreu R, Lamarca J, Tresserra F. Human lens capsule thickness as a function of age and location along the sagittal lens perimeter. *Invest Ophthalmol Vis Sci* 2006;47:2053-60.