






## SHORT RESEARCH ARTICLE

# Epilepsy and inborn errors of metabolism in adults: The diagnostic odyssey of a young woman with medium-chain acyl-coenzyme A dehydrogenase deficiency

Ilaria Cani<sup>1</sup> | Federica Pondrelli<sup>1</sup> | Laura Licchetta<sup>2</sup>  | Raffaella Minardi<sup>2</sup> | Tania Giangregorio<sup>3</sup> | Barbara Mostacci<sup>2</sup> | Lorenzo Muccioli<sup>1</sup>  | Lidia Di Vito<sup>2</sup> | Anna Fetta<sup>3</sup>  | Carmen Barba<sup>4,5</sup>  | Carlo Alberto Castioni<sup>2</sup> | Andrea Bordugo<sup>6</sup> | Paolo Tinuper<sup>1,2</sup> | Francesca Bisulli<sup>1,2</sup> 

<sup>1</sup>Department of Biomedical and Neuromotor Sciences, University of Bologna, Bologna, Italy

<sup>2</sup>IRCCS Istituto delle Scienze Neurologiche di Bologna, Full member of the European Reference Network EpiCARE, Bologna, Italy

<sup>3</sup>Department of Medical and Surgical Sciences, University of Bologna, Bologna, Italy

<sup>4</sup>Neuroscience Department, Meyer Children's Hospital, Firenze, Italy

<sup>5</sup>University of Florence, Florence, Italy

<sup>6</sup>Inherited Metabolic Diseases Unit and Regional Centre for Newborn Screening, Diagnosis and Treatment of Inherited Metabolic Diseases and Congenital Endocrine Diseases, Azienda Ospedaliera Universitaria Integrata, Verona, Italy

## Correspondence

Francesca Bisulli, Department of Biomedical and Neuromotor Sciences, IRCCS Istituto delle Scienze Neurologiche di Bologna, University of Bologna, Bellaria Hospital, Via Altura 3 Bologna 40139, Italy.  
Email: [francesca.bisulli@unibo.it](mailto:francesca.bisulli@unibo.it)

## Abstract

We describe a case of epileptic encephalopathy in a young woman with undiagnosed medium-chain acyl-coenzyme A dehydrogenase deficiency (MCADD), who presented with an early-onset focal motor status epilepticus (SE) then followed by permanent left hemiplegia and drug-resistant epilepsy with neurodevelopmental delay. Throughout her clinical history, recurrent episodes of lethargy, feeding difficulties, and clustering seizures occurred, progressing into a super refractory SE and death at the age of 25 years. Although epilepsy is not a distinctive feature of MCADD, we advise considering this metabolic disease as a possible etiology of epileptic encephalopathy and hemiconvulsion-hemiplegia-epilepsy syndrome of unknown origin, on the chance to provide a timely and targeted treatment preventing development delay and evolution to SE. Adult patients with epilepsy of unknown etiology not screened at birth for inborn errors of metabolism, such as MCADD, should be promptly investigated for these treatable conditions.

## KEYWORDS

epileptic syndrome, fatty acid oxidation disorder, inherited metabolic disorder, intellectual disability, newborn screening

This is an open access article under the terms of the [Creative Commons Attribution-NonCommercial-NoDerivs](https://creativecommons.org/licenses/by-nc-nd/4.0/) License, which permits use and distribution in any medium, provided the original work is properly cited, the use is non-commercial and no modifications or adaptations are made.

© 2022 The Authors. *Epilepsia Open* published by Wiley Periodicals LLC on behalf of International League Against Epilepsy.

## 1 | INTRODUCTION

Epileptic encephalopathies (EEs) are a group of severe infantile or childhood-onset epilepsies characterized by drug-resistant seizures, neurodevelopmental delay, and cognitive impairment.<sup>1</sup>

EEs are clinically and etiologically heterogeneous, with a high prevalence of syndromes of unknown causes.<sup>2</sup> In the last few years, thanks to the progress of research and diagnostic technologies, the etiology of an increasing number of EE cases has been clarified, also in adulthood.<sup>3</sup>

This population of undiagnosed adult patients represents the so-called “lost generation,” who had to experience the frustration and diagnostic delay of continuous but inconclusive investigations (diagnostic odysseys), before the advent of next-generation technology.<sup>4</sup>

Medium-chain acyl-CoA dehydrogenase deficiency (MCADD) is the most common fatty acid beta-oxidation disorder with a prevalence of 5.3 per 100 000 births.<sup>5</sup> It is caused by loss-of-function mutations of the gene *ACADM* that reduce the activity of the enzyme MCAD leading to a beta-oxidation defect of medium-chain fatty acids and a subsequent impairment of the energy supply. Clinical presentation typically occurs in early infancy during periods of catabolic stress (infections, fasting), although cases with adult onset have also been reported.<sup>6</sup> Metabolic crises include hypoketotic hypoglycemia, vomiting, lethargy, Reye-like syndrome, progression to altered mental status, coma, and even death.<sup>5</sup>

Seizures provoked by severe hypoglycemia have been reported in 17%–43% of patients during metabolic crises, while epilepsy is rarely described in patients with MCADD.<sup>7,8</sup> Moreover, only 7%–16% of children with MCADD develop intellectual disability as the result of brain injury derived from acute metabolic events.<sup>7,9</sup>

Here, we report the case of a 25-year-old female patient with drug-resistant epileptic encephalopathy who received a delayed MCADD diagnosis.

## 2 | CASE REPORT

The patient was born in 1996 from a regular pregnancy and delivery. She had normal psychomotor development until 18 months when, during febrile pharyngitis, she presented with lethargy, feeding difficulties, and vomiting for a few days (Figure S1).

She then developed left hemiclonic seizures progressing into refractory focal motor status epilepticus (SE), which required intensive care unit admission and third-line therapy with anesthetics. Laboratory tests documented severe hypoglycemia (6 mg/dL) and elevated liver enzymes. CSF analysis was negative, except for hypoglycorrachia, ruling

out any infectious etiologies. Ictal EEG revealed recurrent epileptiform activity in the right frontotemporal regions. Brain magnetic resonance imaging (MRI) in the acute phase showed cerebral edema over the right hemisphere, evolving to hemiatrophy at later stages. Nevertheless, owing to the assumption of herpetic encephalitis, acyclovir, mannitol, and antibiotics were empirically administered. After the refractory SE resolution, the patient had residual left hemiparesis. She also developed drug-resistant epilepsy characterized by multiple focal motor seizures per day, causing neurodevelopmental delay and cognitive impairment. Several antiseizure medications (ASMs) and vagus nerve stimulation (VNS) brought only a temporary improvement in seizure frequency.

Over the following years, the patient had recurrent metabolic crises with hyporexia, vomiting, and lethargy, triggered by infectious illnesses. These episodes provoked seizure clusters characterized by left tonic-dystonic posturing evolving into hemiclonic phase, which required rescue treatment with benzodiazepines (BZD).

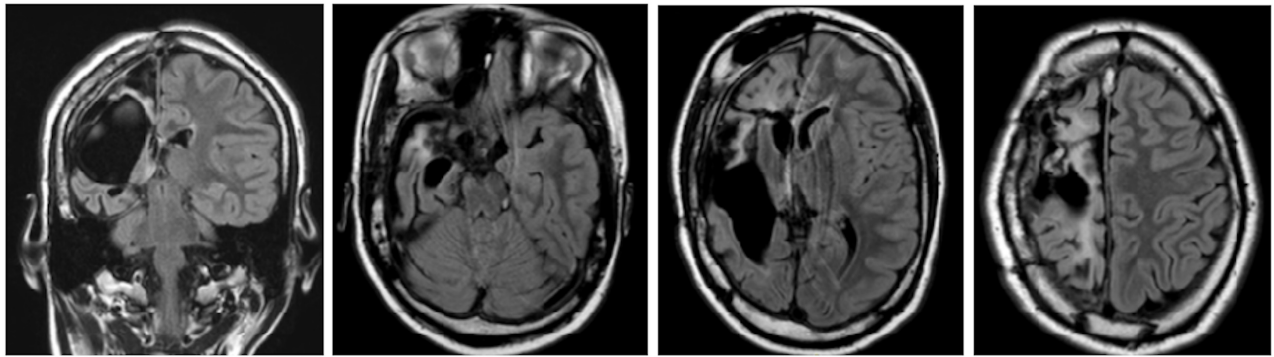
At the age of 8 years, an etiological reassessment was performed including lysosomal enzymes, urinary organic acids, and aminoacidogram on blood and CSF which were normal, except for a mild elevation of glycine and ornithine in blood and abnormal plasma/CSF glycine ratio. Brain FDG-PET scan showed a diffuse hypocaptation on the right hemisphere, raising the suspicion of Rasmussen encephalitis. A brain biopsy before and then a right peri-insular hemispherotomy (Figure 1A) was performed at the age of 8 and 16 years, respectively, detecting nonspecific focal cortical dysplasia type III<sub>d</sub><sup>10</sup> and excluding the diagnosis of Rasmussen encephalitis. After surgery, in concomitance with dose escalation of valproate, seizures mildly decreased in severity; however, the patient developed a slow and progressive clinical deterioration with reduced vigilance, hyporexia, and weight loss by 20 kg, which spontaneously returned to normal level in approximately 6 months.

She has been referred to our clinic at 22 years as part of a transition program from child to adult neurology. To shed light on a possible genetic cause of epilepsy, we performed further diagnostic tests including whole-exome sequencing (WES), in the setting of the Epi25 collaborative (<http://epi-25.org>). Antiseizure therapy was revised achieving a temporary but relevant improvement in seizure frequency and severity.

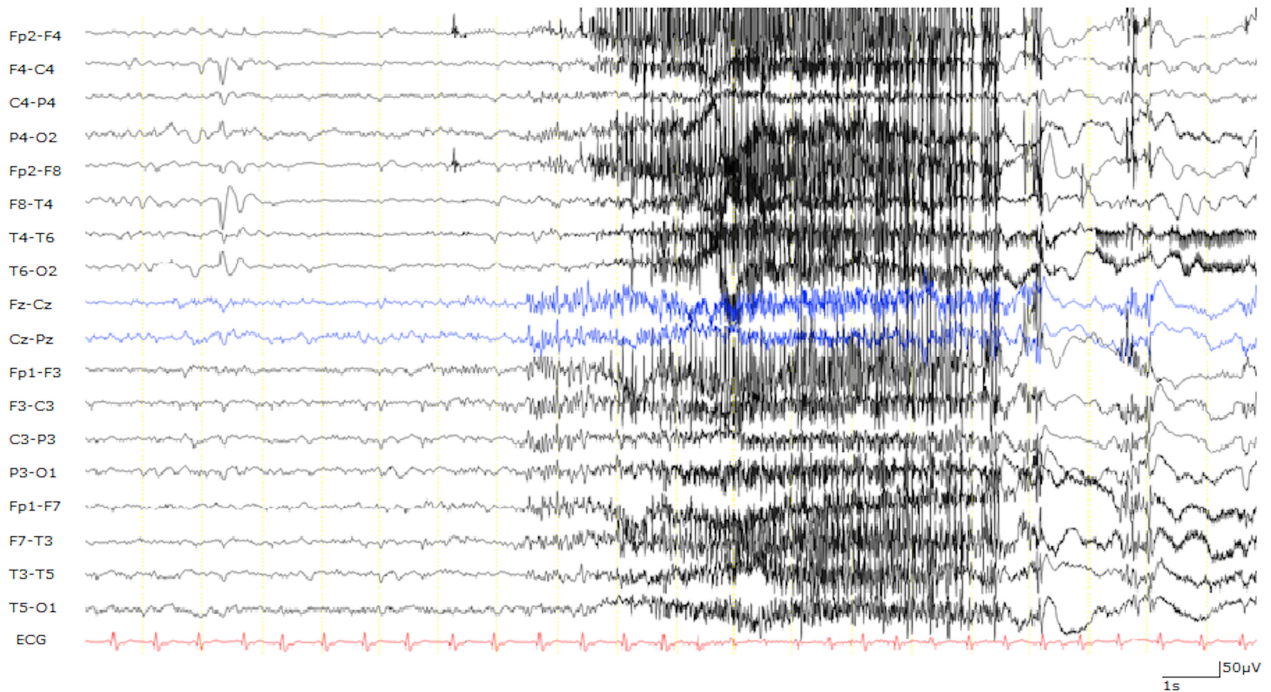
However, at the age of 25 years, during a prolonged metabolic crisis triggered by pneumonia, repeated seizure clusters evolved into focal motor SE (Figure 1B), requiring hospitalization.

Status epilepticus was initially responsive to BZD and ASMs, but subsequently recurred despite treatment with several second- and third-line therapies, resulting in super refractory SE (SRSE) (Figure 2).

A



B



**FIGURE 1** Neuroradiological and electroencephalographic features. (A) Brain MRI was performed at the age of 17 years after peri-insular hemispherotomy. Severe atrophy of the right hemisphere, with enlarged subarachnoid spaces in the right frontotemporal regions in coronal and axial T2-weighted fluid-attenuated inversion recovery (FLAIR) images. (B) Ictal EEG during a brief left tonic-dystonic seizure initially shows a slow wave over the right frontotemporal regions followed by a diffuse rhythmic spiky activity maximal on the left hemisphere.

At that stage, we finally received the analyzed data from WES that revealed two pathogenic variants in *ACADM* (NM\_000016; MIM \*607008):c.244dupT (p.Trp82Leufs\*23) and c.985A>G (p.Lys329Glu). Following the segregation study, which disclosed the two variants were paternally and maternally inherited respectively, a molecular diagnosis of MCADD was made.

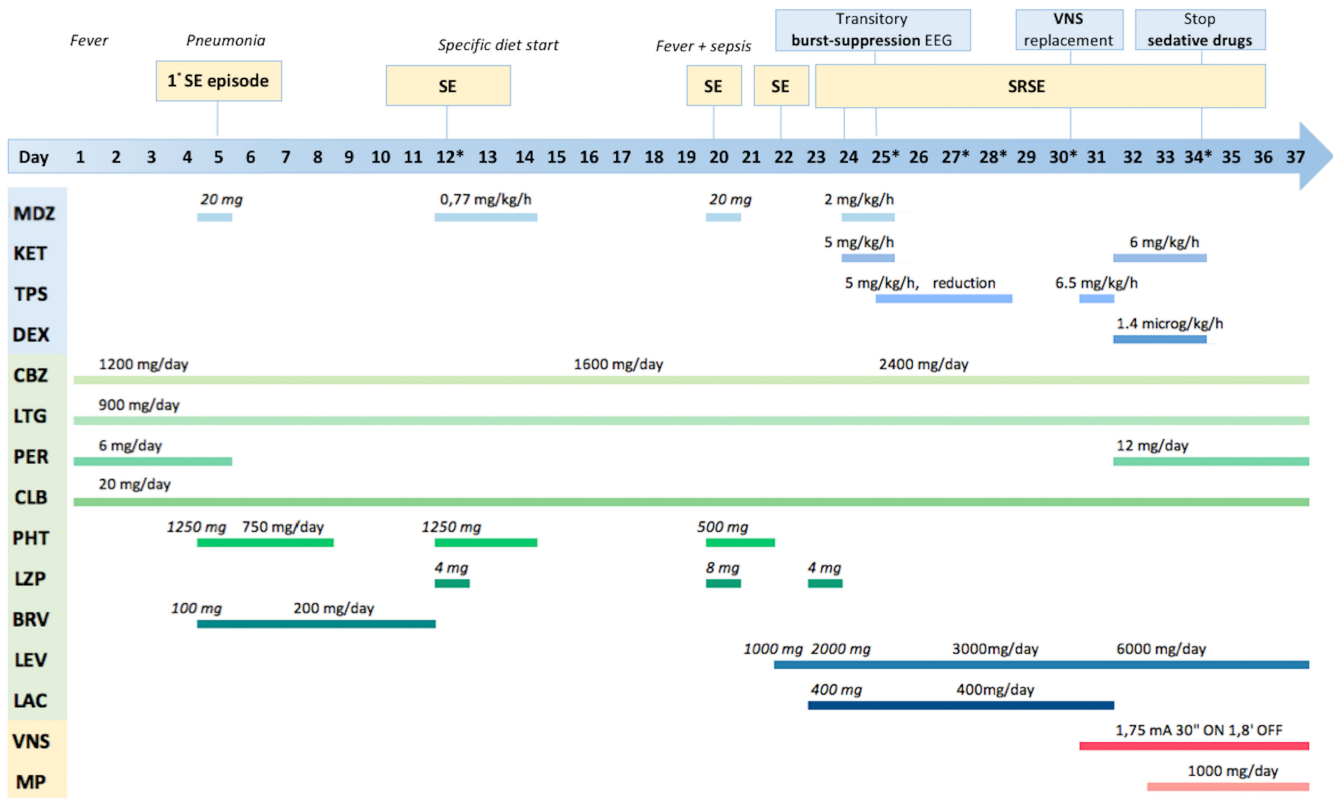
The diagnosis was confirmed by biochemical analysis, which documented an abnormal acylcarnitine profile with elevated octanoyl-carnitine (C8) in blood with concomitant low levels of free carnitine acylcarnitine (C0) and elevated urinary excretion of dicarboxylic acids (i.e., suberic acid) and hexanoylglycine (Table 1). Thus, she

was started on specific nutritional supplementation, consisting of continuous intravenous glucose infusion, avoidance of medium-chain fatty acids and implementation of carnitine, leading to the metabolic failure resolution, as documented by biochemical analysis.

This notwithstanding, SRSE did not resolve, and the patient eventually died after 37 days from the onset of the SE.

### 3 | DISCUSSION

To our knowledge, this is the first report of drug-resistant EE associated with infancy-onset MCADD undiagnosed until adulthood.



**FIGURE 2** Disease course and treatment of the super refractory status epilepticus at the age of 25 years. The patient was admitted for prolonged lethargy, difficulties in feeding, and seizure clusters. She then developed several episodes of focal motor status epilepticus (SE) (5th, 12th, and 20th day) in conjunction with several complications such as febrile pneumonia, phlebitis, and sepsis. SE was initially responsive to benzodiazepine and antiseizure medications, but it became super refractory on Day 24. Thus, high-dose thiopental first, then ketamine and dexmedetomidine have been administered reaching burst suppression for approximately 36 h. Vagal nerve stimulation has been concurrently switched on again and rapidly increased. The specific nutritional support with continuous intravenous administration of glucose, avoidance of medium-chain fatty acids, and implementation of carnitine was started on the 12th day. Medications are reported as total daily doses of mg/day or mg/kg/h in the case of continuous intravenous infusions. \*See corresponding EEG recordings in Appendix S1. Abbreviations: BRV, brivaracetam; CBZ, carbamazepine; CLB, clobazam; DEX, dexmedetomidine; EEG, electroencephalogram; KET, ketamine; LCM, lacosamide; LEV, levetiracetam; LTG, lamotrigine; LZP, lorazepam; MDZ, midazolam; MP, methylprednisolone; PER, perampanel; PHT, phenytoin; SE, status epilepticus; TPS, sodium thiopental; VNS, vagal nerve stimulation.

When promptly diagnosed and treated, this metabolic disorder has a good prognosis with few or no long-term sequelae. However, the untreated metabolic crises in early life may cause acute neurological dysfunction and brain damage secondary to hypoglycemia, resulting in developmental delay and epilepsy.<sup>11,12</sup>

Our patient presented with refractory status epilepticus without previous history of epilepsy or other neurological disorders, a clinical presentation consistent with new-onset refractory status epilepticus (NORSE). While both febrile infection-related epilepsy syndrome (FIRES) and infantile hemiconvulsion-hemiplegia and epilepsy syndrome (HHE) are characterized by NORSE during a febrile episode, our patient developed a clinical presentation consistent with the latter.<sup>13</sup> Indeed, HHE is defined as a specific syndrome in a patient <2 years presenting as NORSE with unilateral motor seizures, high-grade fever at the time of onset of RSE, and unilaterally abnormal acute

imaging, followed by hemiparesis lasting at least 24 h, and excluding definite infectious encephalitis.<sup>14</sup> Notably, most of the patients with HHE afterward develop a drug-resistant epilepsy sometimes associated with developmental disabilities.<sup>15</sup> Moreover, the recurrent hypoglycemic states with frequent seizures due to uncontrolled MCADD likely have contributed to the further worsening of the epilepsy and cognitive deterioration.

Only a few reports of previously undiagnosed adult patients with MCADD are described in the literature; all consisted of asymptomatic individuals who at the time of first severe catabolic stress died or promptly received the diagnosis and appropriate treatment of MCADD.<sup>6,16</sup>

In contrast, our patient and her family experienced a consistent diagnostic delay: A diagnostic odyssey where several hypotheses ranging from Herpes simplex encephalitis to Rasmussen encephalitis has followed one another finally leading to hemispherotomy. During one of these

	Day 11	Day 17	Day 29	Cut-off
Plasma acylcarnitine analysis				
C0-acylcarnitine (μmol/L)	1.9	27.06	Normal	>8.22
C6-acylcarnitine (μmol/L)	-	0.33	Normal	<0.14
C8-acylcarnitine (μmol/L)	0.58	0.68	Normal	<0.19
C10:1-acylcarnitine (μmol/L)	0.17	0.15	Normal	<0.15
Urine organic acid analysis				
3OH-isovaleric acid (mM/Mcreu)	27	19	24	<15
7OH-ottanoic acid (mM/Mcreu)	16	Normal	Normal	
Suberic acid (mM/Mcreu)	29	Normal	Normal	<2
Urine acylglycine analysis				
Hexanoylglycine (C6) (mM/Mcreu)	26	Normal	Normal	<2

TABLE 1 Biochemical analysis at different time of disease course of the superrefractory status epilepticus

Note: The diagnosis of medium-chain acyl-CoA dehydrogenase deficiency (MCADD) was confirmed after first biochemical analysis on Day 11, showing mild alterations apart from free carnitine level which were very low indicating severe chronic consumption. On Day 12, she was started on specific nutritional supplementation, consisting of continuous intravenous glucose infusion, avoidance of medium-chain fatty. Follow-up biochemical analysis was performed on Days 17 and 29 confirming a normalization of the previous biochemical alterations.

MCAD deficiency impairs the initial dehydrogenation of acyl-CoAs with a chain length between 6 and 12 carbon atoms. This results in an increase of metabolites including serum C8-acylcarnitine (with a lesser elevation of C6- and C10-acylcarnitine) and medium-chain acylglycines (hexanoylglycine and octanoylglycine) in urines. During acute episodes, urinary dicarboxylic acids (suberic, ottanoic acid, and decanedioic acid) may be elevated as well. Chronic nutritional treatment includes nutritional support with complex carbohydrates and glucose intravenous during emergency to reverse the catabolic state and prevent hypoglycemia. L-carnitine supplementation may be useful to avoid a secondary carnitine deficiency for the excess acylcarnitines excreted by kidney and trapped as C6-C8-C10 carnitine derivatives. Recently, Mohsen et al.<sup>25</sup> proposed Triheptanoin as anaplerotic treatment for MCAD.

diagnostic reassessments, the patient underwent also to biochemical tests which apparently excluded inborn errors of metabolism. However, the final diagnosis came through WES performed for research purposes in a patient with EE of apparently known etiology.

Clinical diagnosis of MCADD is difficult not only for the variable and nonspecific clinical presentations but also for the chance of obtaining normal biochemical analysis when the subjects are not under metabolic stress.<sup>5</sup> The newborn screening (NBS) program in Italy has currently solved the problem by providing a preclinical diagnosis. However, an extended NBS for inborn errors of metabolism (IEM) has been available only in the early 2000s, reaching a national diffusion in 2016. Similarly, other European and Northern American countries endorsed by the recommendations of the World Health Organization developed an extended NBS between 2010 and 2014, although with different number of diseases targeted. However, several countries in Sub-Saharan Africa, Latin America, and Asia (including China) have not attained the same mission, and the screening for IEM is not yet implemented.<sup>17,18</sup>

Hence, there is a worldwide “lost generation” of children and adults not regularly screened for the disease, where the diagnosis remains based on clinical suspicion.<sup>3</sup>

Other conditions may contribute to the underdiagnoses of IEMs such as MCADD in the lost generation. First, we mainly faced adult patients where it is unlikely to include an IEM into the differential diagnosis of their diseases. Then, undiagnosed patients with a long disease history may develop complex clinical pictures where common features of MCADD (hypoglycemia, vomiting, and lethargy) are no longer easily identifiable, as happened to our patient. Facing patients with EE, adult neurologists are still unfamiliar with IEM and their diagnostic process.

In our case, detection by WES of compound heterozygous variants in *ACADM* suggested the possibility of MCADD, successively confirmed by specific biochemical analysis. However, besides WES that is a costly technique, the currently used epilepsy gene panels are unhelpful for the diagnosis of MCADD, since they usually do not include genes for IEMs.<sup>19</sup> Hence, a significant clinical suspicion and awareness of IEM-related epilepsies are essential to successfully address the genetic tests toward IEMs.

This single case report is paradigmatic of a lost generation of patients who remained undiagnosed for a long time, especially between the high number of EEs of unknown etiology. We advise adult epileptologists to consider IEMs in the diagnostic process of EEs, as early diagnosis and treatment may affect disease outcomes.<sup>20</sup>

Indeed, metabolic epilepsies (epilepsies that results directly from an inherited metabolic disorder in which seizures are a core symptom of the disorder<sup>1</sup>) are increasingly diagnosed, accounting for 25% of EEs of unknown etiology tested with WES.<sup>20,21</sup>

Making a diagnosis of MCADD is crucial considering that a preventive nutritional support is necessary to achieve a good prognosis: Among patients not previously diagnosed, about 25% die during an acute episode of metabolic distress, while prognosis strongly improves after recognition of the enzyme defect.<sup>22</sup>

Early identification of MCADD is even more important in patients with epilepsy, where diagnosis not only may reduce the burden of recurrent metabolic crises but also control seizures, prevent brain damage, and avoid development delay. Moreover, diagnosis of MCADD includes some implications in seizures treatment, such as avoidance of valproate,<sup>23</sup> ketogenic diet, and anesthetics that may negatively impact fatty acid disorders, such as propofol.<sup>24</sup> Finally, presurgical evaluation in patients with epilepsy and cognitive deterioration of uncertain etiology should include genetic and metabolic assessment, especially when a clear-cut lesion is not visible on MRI.

In the end, a diagnosis of a genetic disease is of paramount importance to give parents counseling for future pregnancies.

## 4 | CONCLUSION

Our report expands the clinical spectrum of MCADD and provides new insights into the consequences of recurrent hypoglycemic episodes.

We advise considering MCADD as a possible etiology of hypoglycemic brain injuries and related epileptic encephalopathy or HHE, even in adult patients, as proper diagnosis and treatment may affect disease outcomes.

### AUTHOR CONTRIBUTIONS

IC and FB conceived and designed the study. IC, FP, LL, and LM analyzed and interpreted the clinical data. BM, LDV, and AC helped in the acquisition and analysis of the data. RM and TG interpreted the genetic data. FB, CB, AB, and PT contributed to revising the manuscript.

### ACKNOWLEDGMENTS

We thank V. Carelli, A. Burlina, L. Brodosi, G. Cantalupo, T. Granata, A. Ardisson, all the members of the European Reference Network for Hereditary Metabolic Disorders (MetabERN), and European Reference Network for rare and complex epilepsies (EpiCARE) with whom we had the opportunity to openly discuss this case. We are grateful to all the colleagues from the Intensive Care Unit of

Bellaria Hospital, especially I. Minardi and R. Aspide with whom we have taken care of the patient. A special thanks to Prof. Trinkka and collaborators for the close support and special advice during status epilepticus management. We also thank Prof. Janigro for his precious suggestions and the English language editing. Our last thought sincerely goes to the patient and her family. Open access funding provided by BIBLIOSAN. WOA Institution: IRCCS Istituto Delle Scienze Neurologiche di Bologna Consortia Name : BIBLIOSAN Gold 2022 Open access funding provided by BIBLIOSAN. WOA Institution: IRCCS Istituto Delle Scienze Neurologiche di Bologna Consortia Name : BIBLIOSAN Gold 2022

### CONFLICT OF INTEREST

The authors report no relevant disclosures or conflicts of interest for this manuscript.

### ETHICS APPROVAL AND CONSENT TO PARTICIPATE

Written informed consent was obtained from the patient's relatives for the inclusion of deidentified clinical data in a scientific publication, in accordance with the Declaration of Helsinki.

### CONSENT FOR PUBLICATION

All authors agreed with this final version.

### ETHICAL PUBLICATION STATEMENT

We confirm that we have read the Journal's position on issues involved in ethical publication and affirm that this report is consistent with those guidelines.

### ORCID

Laura Licchetta  <https://orcid.org/0000-0001-7979-9895>

Lorenzo Muccioli  <https://orcid.org/0000-0001-6827-0099>

Anna Fetta  <https://orcid.org/0000-0003-0175-6486>

Carmen Barba  <https://orcid.org/0000-0001-5445-5842>

Francesca Bisulli  <https://orcid.org/0000-0002-1109-7296>

### REFERENCES

- Scheffer IE, Berkovic S, Capovilla G, Connolly MB, French J, Guilhoto L, et al. ILAE classification of the epilepsies: position paper of the ILAE Commission for Classification and Terminology. *Epilepsia*. 2017;58(4):512–21.
- Fiest KM, Sauro KM, Wiebe S, Patten SB, Kwon CS, Dykeman J, et al. Prevalence and incidence of epilepsy. *Neurology*. 2017;88:296–303.
- Minardi R, Licchetta L, Baroni MC, Pippucci T, Stipa C, Mostacci B, et al. Whole-exome sequencing in adult patients with developmental and epileptic encephalopathy: it is never too late. *Clin Genet*. 2020;98(5):477–85.

4. Galizia EC, Srikantha M, Palmer R, Waters JJ, Lench N, Ogilvie CM, et al. Array comparative genomic hybridization: results from an adult population with drug-resistant epilepsy and comorbidities. *Eur J Med Genet.* 2012;55:342–8.
5. Merritt JL, Chang IJ. Medium-chain acyl-coenzyme A dehydrogenase deficiency. In: Adam MP, Mirzaa GM, Pagon RA, Wallace SE, Bean LJH, Gripp KW, et al., editors. *GeneReviews®*. Seattle, WA: University of Washington; 1993.
6. Lang TF. Adult presentations of medium-chain acyl-CoA dehydrogenase deficiency (MCADD). *J Inherit Metab Dis.* 2009;32(6):675–83.
7. Iafolla AK, Thompson RJ, Roe CR. Medium-chain acyl-coenzyme A dehydrogenase deficiency: clinical course in 120 affected children. *J Pediatr.* 1994;124(3):409–15.
8. Pollitt RJ, Leonard JV. Prospective surveillance study of medium chain acyl-CoA dehydrogenase deficiency in the UK. *Arch Dis Child.* 1998;79(2):116–9.
9. Grosse SD, Khoury MJ, Greene CL, Crider KS, Pollitt RJ. The epidemiology of medium chain acyl-CoA dehydrogenase deficiency: an update. *Genet Med.* 2006;8(4):205–12.
10. Blümcke I, Thom M, Aronica E, Armstrong DD, Vinters HV, Palmini A, et al. The clinicopathologic spectrum of focal cortical dysplasias: a consensus classification proposed by an ad hoc Task Force of the ILAE Diagnostic Methods Commission. *Epilepsia.* 2011;52(1):158–74.
11. Kapoor D, Sidharth SS, Patra B, Mukherjee SB, Pemde HK. Electroclinical spectrum of childhood epilepsy secondary to neonatal hypoglycemic brain injury in a low resource setting: a 10-year experience. *Seizure.* 2020;79:90–4.
12. Gataullina S, Delonlay P, Lemaire E, Bodaert N, Bulteau C, Soufflet C, et al. Seizures and epilepsy in hypoglycaemia caused by inborn errors of metabolism. *Dev Med Child Neurol.* 2015;57(2):194–9.
13. Auvin S, Bellavoine V, Merdarius D, Delanoë C, Elmaleh-Bergés M, Gressens P, et al. Hemiconvulsion-hemiplegia-epilepsy syndrome: Current understandings. *Eur J Paediatr Neurol.* 2012;16(5):413–21.
14. Hirsch LJ, Gaspard N, van Baalen A, Nabbout R, Demeret S, Loddenkemper T, et al. Proposed consensus definitions for new-onset refractory status epilepticus (NORSE), febrile infection-related epilepsy syndrome (FIRES), and related conditions. *Epilepsia.* 2018;59(4):739–44.
15. Albakaye M, Belaïdi H, Lahjouji F, Errguig L, Kuate C, Maiga Y, et al. Clinical aspects, neuroimaging, and electroencephalography of 35 cases of hemiconvulsion-hemiplegia syndrome. *Epilepsy Behav.* 2018;80:184–90.
16. Schatz UA, Ensenaer R. The clinical manifestation of MCAD deficiency: challenges towards adulthood in the screened population. *J Inherit Metab Dis.* 2010;33(5):513–20.
17. Borrajo GJC. Newborn screening in Latin America: a brief overview of the state of the art. *Am J Med Genet Part C Semin Med Genet.* 2021;187(3):322–8.
18. Kapoor S, Thelma BK. Status of newborn screening and inborn errors of metabolism in India. *Indian J Pediatr.* 2018;85(12):1110–7.
19. Varadkar S. The biochemical basis of genetic epilepsies and the genetic basis of inherited metabolic disease. *Dev Med Child Neurol.* 2016;58(10):1001–2.
20. Tumiene B, Ferreira CR, van Karnebeek CDM. 2022 Overview of metabolic epilepsies. *Genes (Basel).* 2022;13(3):508.
21. Demos M, Guella I, DeGuzman C, McKenzie MB, Buerki SE, Evans DM, et al. Diagnostic yield and treatment impact of targeted exome sequencing in early-onset epilepsy. *Front Neurol.* 2019;10:434.
22. Wilcken B. Fatty acid oxidation disorders: outcome and long-term prognosis. *J Inherit Metab Dis.* 2010;33(5):501–6.
23. Njølstad PR, Skjeldal OH, Agsteribbe E, Huckriede A, Wannag E, Søvik O, et al. Medium chain acyl-CoA dehydrogenase deficiency and fatal valproate toxicity. *Pediatr Neurol.* 1997;16(2):160–2.
24. Redshaw C, Stewart C. Anesthetic agents in patients with very long-chain acyl-coenzyme A dehydrogenase deficiency: a literature review. *Pediatr Anesth.* 2014;24(11):1115–9.
25. Mohsen A-W, Vockley J, Karunanidhi A, Basu S, Zhao X-J, D'Annable O. Hepranoate and derivatives as therapy for MCAD deficiency: preclinical evidence of efficacy and implications for anaplerotic drug class therapy. *Mol Genet Metab.* 2022;135(4):288–9.

## SUPPORTING INFORMATION

Additional supporting information can be found online in the Supporting Information section at the end of this article.

**How to cite this article:** Cani I, Pondrelli F, Licchetta L, Minardi R, Giangregorio T & Mostacci B et al. Epilepsy and inborn errors of metabolism in adults: The diagnostic odyssey of a young woman with medium-chain acyl-coenzyme A dehydrogenase deficiency. *Epilepsia Open.* 2022;7:810–816. <https://doi.org/10.1002/epi4.12630>