

# The rate of intraspinal problems and clinical evaluation of scoliosis: A cross-sectional, descriptive study

Filiz Tuna , Hakan Tuna 

Department of Physical Medicine and Rehabilitation, Trakya University, Faculty of Medicine, Edirne, Turkey

Received: March 31, 2019 Accepted: July 12, 2019 Published online: August 18, 2020

## ABSTRACT

**Objectives:** This study aims to define the chronological, angular, and topographic classes in presumed idiopathic scoliosis and to investigate the frequency of generalized joint hypermobility, pain, neurological deficit, ankle deformity, Risser grade, and magnetic resonance imaging (MRI) findings in these patients.

**Patients and methods:** This cross-sectional, descriptive study included a total of 36 patients (11 males, 25 females; mean age 13.4±4.6 years; range, 6 to 24 years) with idiopathic scoliosis between January 2015 and January 2019. Data including age, sex, complaint of pain, generalized joint hypermobility (based on Beighton score), neurological deficit, ankle deformity, and definition of scoliosis were recorded. Chronological, angular, and topographic classification were carried out. The Risser grade and MRI findings were noted.

**Results:** Of all patients, 30 (83.3%) were idiopathic, five (13.9%) were neuromuscular, and one (2.8%) was congenital scoliosis based on MRI findings. Of 13 (36.1%) spine MRI scans, six (46.2%) were intraspinal anomalies, four were syringomyelia (30.8%), one was Chiari type 1 malformation (7.7%), and one was hemivertebrae with diastematomyelia (7.7%). The highest rates of classes according to chronological, angular, and topographical classifications of idiopathic scoliosis were adolescent (17/30, 56.7%), low angular (24/30, 80.0%), and lumbar scoliosis (15/30, 50.0%), respectively. Ten patients (33.3%) complained of pain, while 23 patients (76.7%) had no neurological deficit and seven (23.3%) had hypoesthesia. Seventeen patients (56.7%) had generalized joint hypermobility.

**Conclusion:** Idiopathic scoliosis with non-severe spinal deformity may present with intraspinal neural axis abnormalities, even when it is neurologically intact. Based on our study results, it seems to be useful to consider whole spine MRI for the evaluation of thoracic and lumbar scoliosis.

**Keywords:** Chiari, hypermobility, scoliosis, spine, syringomyelia.

Idiopathic scoliosis was first defined by Kleinberg<sup>[1]</sup> for defining all cases in which “*it is not possible to find a specific disease causing the deformity*” in 1922. Although the etiology of scoliosis has not been completely elucidated, it has been accepted as multifactorial. Recently, the prevention against visible disability and decrease in quality of life have focused on the identification of early stages of scoliosis with screening studies, since scoliosis has begun to occur in apparently healthy children.<sup>[2]</sup> Efforts for defining scoliosis with school screening have been gaining importance, as the occurring or progressing of the disease is mostly associated with multiple factors during any rapid period of growth.<sup>[3]</sup> Yılmaz et al.<sup>[4]</sup>

reported, for the first time, the prevalence of adolescent idiopathic scoliosis with a Cobb angle above 10° as 2.3% in an epidemiological study conducted in Turkey, and it is consistent with the literature with a prevalence ranging from 2 to 3%.<sup>[3]</sup>

The need for preventing scoliosis-associated disability (e.g., health problems in adult life, pain, and progressive functional limitations) is underlined by the International Scientific Society on Scoliosis Orthopaedic and Rehabilitation Treatment (SOSORT) as follows: If the Cobb angle at completion of growth exceeds an angle between 30° and 50° named as “critical threshold”, there is a higher risk of disability.<sup>[3,5]</sup>

**Corresponding author:** Filiz Tuna, MD. Trakya Üniversitesi Tıp Fakültesi, Fiziksel Tıp ve Rehabilitasyon Anabilim Dalı, 22030 Edirne, Türkiye.

e-mail: drftuna@hotmail.com

Cite this article as:

Tuna F, Tuna H. The rate of intraspinal problems and clinical evaluation of scoliosis: A cross-sectional, descriptive study. Turk J Phys Med Rehab 2020;66(3):329-335.

Presented as an oral presentation at the 27<sup>th</sup> National Congress of Physical Medicine and Rehabilitation, 17-21 April 2019, Antalya, Turkey.

The 2016 SOSORT guidelines present the evidence-based clinical recommendations on the management of all growing patients with idiopathic scoliosis and report flow-charts for clinical practice of all the possible treatments which can be proposed for idiopathic scoliosis based on knowledge about an angular, chronological class of idiopathic scoliosis in addition to Risser grade, and pain status.<sup>[3]</sup> In addition, classifications of scoliosis have been endorsed by the SOSORT due to the fact that different scoliosis has a different prognosis.<sup>[3]</sup>

Magnetic resonance imaging (MRI) is used in idiopathic scoliosis with importance in the surgical setting. Nevertheless, beyond its importance in the symptoms and signs of neurological deficit, in the everyday use for deformity evaluation, this technique is not supported by the actual evidence, if it is used to rule out the diagnosis of non-idiopathic scoliosis.<sup>[6-9]</sup> Therefore, current literature prompts the hypothesis that physicians who diagnose idiopathic scoliosis would not be aware of etiology, unless they are curious about it and start to search it. However, the spinal deformity caused by scoliosis should be examined as a sign of a reason that has not identified, yet.

In the present study, we aimed to define the frequency of classes (e.g., chronological, angular, and topographic) endorsed by the SOSORT in our patients suspected of having idiopathic scoliosis, and to investigate the frequency of generalized joint hypermobility (GJH), pain, neurological deficit, ankle deformity, Risser grade status, and MRI findings in these patients.

## PATIENTS AND METHODS

In this cross-sectional, descriptive study, patients who presented to the Physical Medicine and Rehabilitation Pediatric Rehabilitation Unit of Trakya University, Faculty of Medicine between January 2015, and January 2019, and were suspected of having idiopathic scoliosis were screened. Those with a previously known reason for neurological scoliosis (e.g., cerebral palsy, myelomeningoceles, and muscular dystrophy) or connective tissue syndromes were excluded. *Inclusion criteria were as follows:* having complete data obtained from medical files including age, sex, complaint of pain, GJH (Beighton scoring), neurological deficit, ankle deformity, definition of scoliosis with a Cobb angle of  $\geq 10^\circ$  and axial rotation at the apical vertebra. A written informed consent was obtained from

**TABLE 1**  
Clinical and radiological findings of scoliosis cases

	n	%
Presumed idiopathic scoliosis		
MRI evaluation	13	36.1
Evaluated with MRI	23	63.9
Not evaluated with MRI		
Scoliosis evaluated with MRI		
Intraspinal anomalies was found	6	46.2
Not found	7	53.8
Scoliosis classification after MRI evaluation		
Idiopathic	30	83.3
Neuromuscular	5	13.9
Congenital	1	2.8
Finally idiopathic scoliosis		
Chronological classification		
Infantile	0	0.0
Juvenile	9	30.0
Adolescent	17	56.7
Adult	4	13.3
Radiological evaluations		
Angular classification		
Low	24	80.0
Moderate	4	13.3
Moderate to severe	2	6.7
Severe	0	0.0
Severe to very severe	0	0.0
Very severe	0	0.0
Topographic classification		
Thoracic	8	26.7
Thoracolumbar	4	13.3
Lumbar	15	50.0
Double curve	2	6.7
Three curve	1	3.3
Risser grading		
Grade 0	12	40.0
Grade 1	1	3.3
Grade 2	3	10.0
Grade 3	5	16.7
Grade 4	2	6.7
Grade 5	7	23.3
Clinical evaluation		
Beighton scoring		
GJH	17	56.7
Not evaluated	9	30.0
Non-GJH	4	13.3
Pain/findings		
Not neurologic deficit	23	76.7
Pain	10	33.3
Hypoesthesia	7	23.3
Ankle deformities		
Unilateral valgus	13	43.3
No deformity	11	36.7
Bilateral valgus	6	20.0

MRI: Magnetic resonance imaging; GJH: Generalized joint hypermobility.

each adult patient and/or parent of each child. The study protocol was approved by the Trakya University, Faculty of Medicine Ethics Committee (TÜTF-BAEK 2019/63). The study was conducted in

**TABLE 2**  
Reclassification of presumed idiopathic scoliosis cases based on MRI findings

	Presumable idiopathic scoliosis									
	Infantile		Juvenile		Adolescent		Adult		Total	
	n	%	n	%	n	%	n	%	n	%
After MRI evaluation										
Idiopathic scoliosis	0		9		17		4		30	83.3
Neuromuscular scoliosis	0		1**		3**		1***		5	13.9
Congenital scoliosis	1*		0		0		0		1	2.8
Total	1	2.8	10	27.8	20	55.6	5	13.9	36	100.0

MRI: Magnetic resonance imaging; \* Diastematomyelia, Hemivertebra; \*\* Syringomyelia; \*\*\* Chiari type 1 malformation.

accordance with the principles of the Declaration of Helsinki.

**Classifications of scoliosis**

Initially, all patients were evaluated by a single physiatrist. Finally, medical records of a total of 36 patients (11 males, 25 females; mean age 13.4±4.6 years; range, 6 to 24 years) with the first definition of idiopathic scoliosis were included in the study. We used the classifications endorsed by the SOSORT Consensus.<sup>[3]</sup> Idiopathic scoliosis was classified as chronological, angular, and topographic. The chronological classification was based on the age of the case at the time of diagnosis: infantile (≤2 years and 11 months), juvenile (range, 3 to 9 years and 11 months), adolescent (range, 10 to 17 years and 11 months), and adult (≥18 years).

The angular classification was based on the Cobb angle as follows: low (up to 20°), moderate (21 to 35°), moderate to severe (36 to 40°), severe (41 to 50°), severe to very severe (51 to 55°), and very severe (≥56°).

The topographic classification was based on the anatomic location of apex.

**Radiological evaluation**

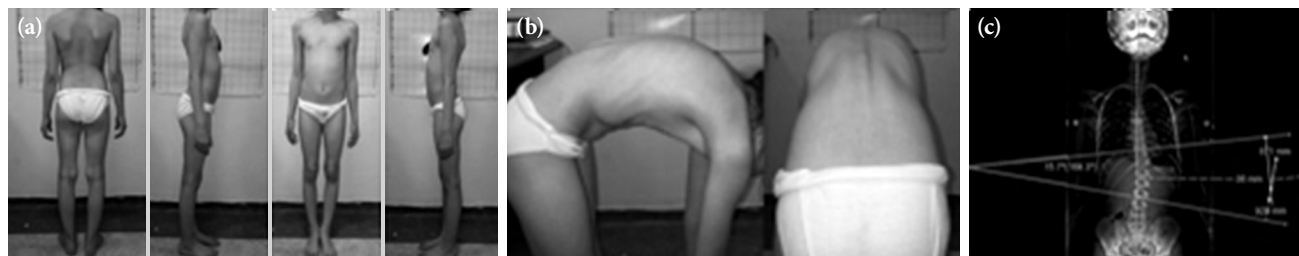The angle degree of scoliosis was evaluated in the upright position, frontal to radiograph based on the Cobb and digital computer-assisted (semi-automatic) method. The angle was limited by the most tilted upper and lower end vertebrae. The landmarks used to evaluate Cobb angle were manually marked using a computer mouse and were, then, calculated automatically.<sup>[10]</sup>

The anatomic location of scoliosis was defined according to apex as follows: thoracic (from disc T1-2 to disc T11-12), thoracolumbar (from T12 to L1), and lumbar (disc L1-2).<sup>[3,11]</sup> Double (S-shaped) and three curves pattern were also defined.

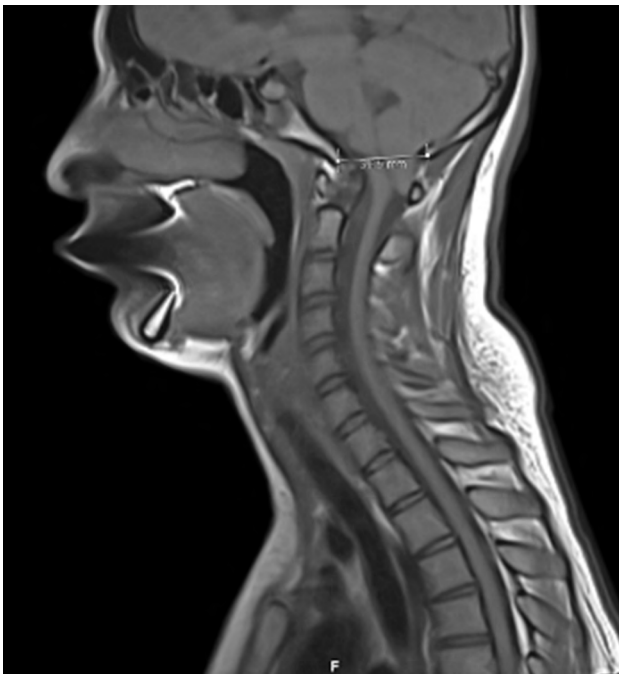The Risser grading was done using the same posteroanterior X-rays to evaluate scoliosis. The MRI findings at the time of the first definition were also recorded.

**Statistical analysis**

Statistical analysis was performed using the IBM SPSS version 20.0 software (IBM Corp., Armonk,



**Figure 1.** An 11-year-old female with presumed idiopathic scoliosis (left lumbar) in the absence of neurological findings. Syringomyelia was detected based on whole spine magnetic resonance imaging. Finally, neuromuscular scoliosis was defined. (a) An aesthetic profile of trunk of patient affected by spinal deformities. (b) The trunk forward bending test (Adam’s forward test). (c) Cobb angle.



**Figure 2.** Chiari malformation in 19-year-old female with presumed idiopathic scoliosis (right thoracic) diagnosed using whole spine magnetic resonance imaging (level of brainstem to sacrum). Finally, neuromuscular scoliosis was defined.

NY, USA). Descriptive statistics were expressed in mean  $\pm$  standard deviation (SD), median (min-max) or number and frequency.

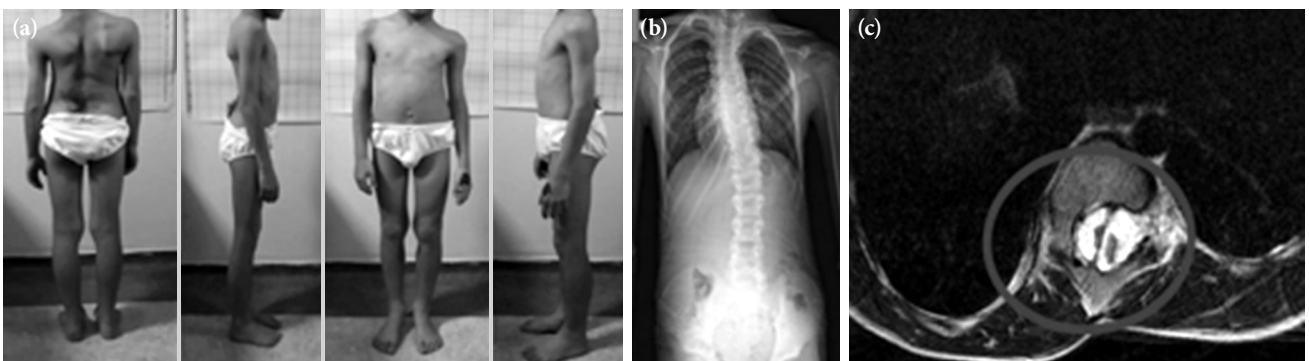
## RESULTS

Of a total of 36 patients, the mean age at the time of first evaluation in our outpatient clinic was  $13.4 \pm 4.6$  (range, 6 to 24) years. The mean age at the time of the first diagnosis of scoliosis was  $12.0 \pm 4.9$

(range, 1.5 to 24) years. Clinical and radiological findings are summarized in Table 1. Of all presumed idiopathic scoliosis patients, spine MRI was performed in 13 (36.1%) patients and MRI revealed intraspinal anomalies in six of them (6/13, 46.2%). Syringomyelia (4/13, 30.8%), Chiari type 1 malformation (1/13, 7.7%), and hemivertebrae with diastematomyelia (1/13, 7.7%) were also found (Table 2, Figures 1-3). Five cases redefined as neuromuscular scoliosis were painless (5/5), while two of them had hypoesthesia (2/5) and only one had GJH. Angular classifications of redefined cases were as follows: low (3/6), moderate (2/6), and severe (1/6). Topographic coronal plane curve patterns of redefined six cases were as follows: thoracic (3/6), lumbar (2/6), and three curves pattern (1/6). We found left-sided lumbar (2/6) and right-sided thoracic curve (4/6) in these cases. Neurological deficit was observed only in three cases.

## DISCUSSION

In this study, we attempted to define the chronological, angular, and topographic classes in patients suspected of having idiopathic scoliosis and to investigate the frequency of GJH, pain, neurological deficit, ankle deformity, Risser grade, and MRI findings in these patients. Our study results showed that the incidence of intraspinal deformity in presumed idiopathic scoliosis, including the low Cobb angles was 42.6% and 50% of them had an intact neurologic status. The most common problem was the syringomyeli. We believe that this study is valuable as it contributes to the existing literature and underlines the data required for the practical management of idiopathic scoliosis. It also provides an opportunity to discuss the association between



**Figure 3.** A 12-year-old male with presumed idiopathic scoliosis (left lumbar) in the absence of neurological findings. (a) An aesthetic profile of trunk of patient affected by spinal deformities. (b) A frontal radiographic study. (c) Magnetic resonance imaging evaluation showing diastematomyelia at the level of Th10-Th11 intervertebral discs (the spinal cord is divided longitudinally into two parts by a fibrous septum). Finally, congenital scoliosis was defined.

idiopathic scoliosis, intraspinal anomalies, and need for MRI evaluation.

In the present study, the female-to-male ratio was found to be consistent with a recent prospective, cross-sectional epidemiological study conducted in Turkey (the ratio of affected girls-to-boys was reported as 251 to 118).<sup>[4]</sup> With an etiological point of view, most of the patients were idiopathic compatible with the classical knowledge stating that scoliosis was secondary to another pathological process in about 20% of cases, while the remaining 80% were cases of idiopathic scoliosis.<sup>[3]</sup> In addition, 30% of idiopathic scoliosis were juvenile, and it was the second prevalent problem after adolescent scoliosis. We prefer to use infantile and juvenile scoliosis as separate terms as in the James classification instead of the term early-onset scoliosis, which is used currently, given the fact that infantile scoliosis has a different prognosis. It has a regressive prognosis, resulting from intrauterine malposition and is not three-plane deformity.<sup>[3,12,13]</sup>

In our study, the most common rate of growth status was found to be Risser Grade 0, the first 2/3 of pubertal development, in which the linear growth rate of the skeleton was the highest.<sup>[3]</sup> Interestingly, four of six cases with intraspinal deformity were also Risser Grade 0. Indeed, bracing, the most effective treatment option of conservative treatment, has been recommended by the 2016 SOSORT guidelines for the treatment of still growing (Risser Grade 0-3) idiopathic scoliosis cases with a mean curve above  $20^{\circ} \pm 5^{\circ}$  Cobb, and with demonstrated progression of deformity or increased risk of worsening.<sup>[3]</sup> Therefore, similar to our cases, a definition of cases in an acceptable stage may create the opportunity for the bracing. Our study findings are consistent with Yilmaz et al.<sup>[4]</sup> who reported the low angular class ( $10^{\circ}$  to  $15^{\circ}$ ) as the most prevalent angular group of the adolescent idiopathic scoliosis in their epidemiological study carried out in Turkey in which intraspinal deformities were unable to be evaluated due to its epidemiological nature. In addition, the aforementioned authors reported the most common scoliosis pattern as a single curved (69.3%), followed by a double curved (29.3%), and the most common topographically as lumbar scoliosis. However, we found thoracic scoliosis in the second place differently of reported in the study of Yilmaz et al.<sup>[4]</sup> as thoracolumbar scoliosis.

The assessment of children with idiopathic scoliosis should be combined with the evaluation of GJH due to the fact that GJH is recommended as a potential factor of a higher risk of scoliosis progression.<sup>[3]</sup> More

than half of the cases with idiopathic scoliosis had GJH, consistent with 51.4% previously reported by Czaprowski et al.<sup>[14]</sup> On the contrary, the presence of joint hypermobility was not found to be associated with the presence of scoliosis by Bozkurt et al.<sup>[15]</sup> and no significant relationship between GJH prevalence and scoliosis curve size or curve pattern was reported.<sup>[15,16]</sup>

Over time, idiopathic scoliosis has been reported to be accompanied by many problems.<sup>[7,8,17]</sup> While intraspinal problems are one of the main etiological causes in the development of scoliosis, it does not always present with abnormal neurological findings, pain or at a young age as reported previously in the literature. In our study, 50% of the patients were neurologically intact. In a recent study, the incidence of intraspinal neural axis abnormalities in severe spinal deformity was reported as 42.6%, and 65.1% of them were reported as neurologically intact, similar to our study results from non-severe spinal deformities. Indeed, 37.5% of reported abnormalities were located in thoracic and 31.3% in the cervical region, and the most common problem was found in the syrinx.<sup>[7]</sup> Interestingly, our incidence of total intraspinal anomalies was quite similar; however, only one of the cases had severe scoliosis. In addition, pain (rarely disabling) occurs in about 32% of patients with adolescent idiopathic scoliosis,<sup>[18]</sup> consistent with our findings of idiopathic cases. However, five patients redefined as neuromuscular scoliosis were painless in our study.

In our study, we used the 2016 SOSORT guidelines to define classes of scoliosis in accordance with the recent literature, in which classifications are relevant for conservative care.<sup>[3]</sup> The right convex thoracic with or without left lumbar curve is usually accepted the typical curve pattern in adolescent idiopathic scoliosis, and left thoracic, particularly in males, is accepted as the atypical curve pattern.<sup>[19,20]</sup> Further investigation is needed for an atypical curve (e.g., a curve less than six segments [a short curve], kyphosis near to curve's apex, decreased rotation of apex, and rapid progression) and sclerosis or osseous destruction (e.g., an infection or underlying tumor).<sup>[20,21]</sup> Unfortunately, intraspinal problems (e.g., syrinx or tethered cord) occasionally show the same curve pattern as typical scoliosis.<sup>[20]</sup> In our study, most of the scoliosis with intraspinal problems were topographically thoracic. These findings support that thoracic scoliosis is more prone to the worst prognosis than double structural ones.<sup>[22]</sup> It was also shown that the syrinx in thoracolumbar or lumbar spine scoliosis had a much lower caudal extent and lower level of syrinx/cord ratio than the syrinx located

on the thoracic spine.<sup>[23]</sup> The most dominant side of scoliosis in cases with an intraspinal deformity in our study (right-sided thoracic and left-sided lumbar, respectively) differed from a left-sided thoracic curve in studies which reported it as usually associated with an intraspinal pathology.<sup>[22,24]</sup>

In the clinical practice, MRI should be performed to rule out the diagnosis of neural axis abnormalities such as Chiari malformation, syringomyelia, diastematomyelia, and tethered spinal cord, which is found in patients with presumed idiopathic scoliosis in the absence of neurological findings. Magnetic resonance imaging can be beneficial for these purposes, when performed from the level of the brainstem to the sacrum.<sup>[6-8]</sup> The most common complaint related to a Chiari I malformation is posterior cervical or occipital pain due to the compression of dural or neural structures by the herniated cerebellar tonsils.<sup>[25,26]</sup> However, our case was painless. Therefore, we should underline MRI use in thoracic scoliosis in accordance with the adage of early is on time, on time is late, and late is unacceptable.

Nonetheless, this study has some limitations. First, the sample size is small and further large-scale studies are needed to confirm our findings. Second, this study was conducted using convenience sampling of the scoliosis patients who were admitted to the pediatric rehabilitation unit of physical medicine and rehabilitation outpatient clinic and, thus, it may not be a representative of the entire scoliosis population.

In conclusion, our study results highlight the importance of considering scoliosis as a sign for intraspinal anomalies and exclude it before scoliosis is defined as idiopathic. In clinical practice, it may be useful to consider whole spine MRI for the evaluation of thoracic and lumbar scoliosis, even in the intact neurological evaluation to prevent disability related to scoliosis and improve early detection of intraspinal neural axis abnormalities.

#### Declaration of conflicting interests

The authors declared no conflicts of interest with respect to the authorship and/or publication of this article.

#### Funding

The authors received no financial support for the research and/or authorship of this article.

## REFERENCES

1. Kleinberg S. The operative treatment of scoliosis. *Arch Surg* 1922;5:631-45.
2. Grivas TB, Wade MH, Negrini S, O'Brien JP, Maruyama T, Hawes MC, et al. SOSORT consensus paper: school screening for scoliosis. Where are we today? *Scoliosis* 2007;2:17.
3. Negrini S, Donzelli S, Aulisa AG, Czaprowski D, Schreiber S, de Mauroy JC, et al. 2016 SOSORT guidelines: orthopaedic and rehabilitation treatment of idiopathic scoliosis during growth. *Scoliosis Spinal Disord* 2018;13:3.
4. Yılmaz H, Zateri C, Kusvuran Ozkan A, Kayalar G, Berk H. Prevalence of adolescent idiopathic scoliosis in Turkey: an epidemiological study. *Spine J* 2020;20:947-55.
5. Weinstein SL, Dolan LA, Spratt KF, Peterson KK, Spoonamore MJ, Ponseti IV. Health and function of patients with untreated idiopathic scoliosis: a 50-year natural history study. *JAMA* 2003;289:559-67.
6. Inoue M, Minami S, Nakata Y, Otsuka Y, Takaso M, Kitahara H, et al. Preoperative MRI analysis of patients with idiopathic scoliosis: a prospective study. *Spine (Phila Pa 1976)* 2005;30:108-14.
7. Zhang Y, Xie J, Wang Y, Bi N, Li T, Zhang J, et al. Intraspinal neural axis abnormalities in severe spinal deformity: a 10-year MRI review. *Eur Spine J* 2019;28:421-5.
8. Ozturk C, Karadereler S, Ornek I, Enercan M, Ganiyusufoglu K, Hamzaoglu A. The role of routine magnetic resonance imaging in the preoperative evaluation of adolescent idiopathic scoliosis. *Int Orthop* 2010;34:543-6.
9. Do T, Frasc C, Burke S, Widmann RF, Rawlins B, Boachie-Adjei O. Clinical value of routine preoperative magnetic resonance imaging in adolescent idiopathic scoliosis. A prospective study of three hundred and twenty-seven patients. *J Bone Joint Surg [Am]* 2001;83:577-9.
10. Langensiepen S, Semler O, Sobottke R, Fricke O, Franklin J, Schönau E, et al. Measuring procedures to determine the Cobb angle in idiopathic scoliosis: a systematic review. *Eur Spine J* 2013;22:2360-71.
11. Ponseti IV, Friedman B. Prognosis in idiopathic scoliosis. *J Bone Joint Surg [Am]* 1950;32A:381-95.
12. James JI. The management of infants with scoliosis. *J Bone Joint Surg [Br]* 1975;57:422-9.
13. El-Hawary R, Akbarnia BA. Early Onset Scoliosis - Time for Consensus. *Spine Deform* 2015;3:105-6.
14. Czaprowski D, Kotwicki T, Pawłowska P, Stoliński L. Joint hypermobility in children with idiopathic scoliosis: SOSORT award 2011 winner. *Scoliosis* 2011;6:22.
15. Bozkurt S, Kayalar G, Tezel N, Güler T, Kesikburun B, Denizli M, et al. Hypermobility Frequency in School Children: Relationship With Idiopathic Scoliosis, Age, Sex and Musculoskeletal Problems. *Arch Rheumatol* 2018;34:268-73.
16. Czaprowski D. Generalised joint hypermobility in caucasian girls with idiopathic scoliosis: relation with age, curve size, and curve pattern. *ScientificWorldJournal* 2014;2014:370134.
17. Swarup I, Silberman J, Blanco J, Widmann R. Incidence of Intraspinal and Extraspinal MRI Abnormalities in Patients With Adolescent Idiopathic Scoliosis. *Spine Deform* 2019;7:47-52.
18. Ramirez N, Johnston CE, Browne RH. The prevalence of back pain in children who have idiopathic scoliosis. *J Bone Joint Surg [Am]* 1997;79:364-8.



19. Dewan V, Gardner A, Forster S, Matthews J, Newton Ede M, Mehta J, et al. Is the routine use of magnetic resonance imaging indicated in patients with scoliosis? *J Spine Surg* 2018;4:575-82.
20. Malfair D, Flemming AK, Dvorak MF, Munk PL, Vertinsky AT, Heran MK, et al. Radiographic evaluation of scoliosis: review. *AJR Am J Roentgenol* 2010;194(3 Suppl):S8-22.
21. Schwend RM, Hennrikus W, Hall JE, Emans JB. Childhood scoliosis: clinical indications for magnetic resonance imaging. *J Bone Joint Surg [Am]* 1995;77:46-53.
22. Mejia EA, Hennrikus WL, Schwend RM, Emans JB. A prospective evaluation of idiopathic left thoracic scoliosis with magnetic resonance imaging. *J Pediatr Orthop* 1996;16:354-8.
23. Tan H, Shen J, Feng F, Zhang J, Wang H, Chen C, et al. Clinical manifestations and radiological characteristics in patients with idiopathic syringomyelia and scoliosis. *Eur Spine J* 2018;27:2148-55.
24. Barnes PD, Brody JD, Jaramillo D, Akbar JU, Emans JB. Atypical idiopathic scoliosis: MR imaging evaluation. *Radiology* 1993;186:247-53.
25. Steinbok P. Clinical features of Chiari I malformations. *Childs Nerv Syst* 2004;20:329-31.
26. Palamar D, Güler H, Hancı M, Sucuoğlu H, Sanus GZ, Tüzün Ş. Posturographic examination of body balance in patients with Chiari type I malformation and correlation with the presence of syringomyelia and degree of cerebellar ectopia. *Turk J Phys Med Rehabil* 2018;65:74-9.