

Posterior Glenoid Reconstruction Using a Distal Tibial Allograft



Joseph D. Cooper, M.D., Joseph J. Ruzbarsky, M.D., Philip-C. Nolte, M.D., M.A.,
Bryant P. Elrick, M.Sc., and Peter J. Millett, M.D., M.Sc.

Abstract: Posterior shoulder instability is increasingly recognized and diagnosed in young athletes. These patients often present with vague shoulder pain rather than the frank instability commonly seen with anterior instability. Three common causes of posterior shoulder instability are congenital retroversion, a single traumatic event, or repetitive microtrauma with erosive effects. The critical determination when deciding on the appropriate treatment of posterior shoulder instability is the presence and degree of glenoid bone loss. In patients without bone loss, arthroscopic procedures have a high success rate with a failure rate of less than 10% and an 89% return-to-sport rate. The determination of the critical amount of bone loss that would permit an arthroscopic procedure is controversial, but recent reports that attempt to quantify the critical bone loss value posteriorly have ranged from 13.5% to 20%. This Technical Note describes our preferred method of open surgical treatment of posterior shoulder instability with posterior glenoid bone loss using an intra-articular distal tibial allograft.

Posterior instability is increasingly recognized as a source of shoulder pain and dysfunction. It is commonly seen in athletes, especially those involved in overhead sports, football offensive linemen, and those who bench press.¹⁻⁴ Due to both its less common frequency and less pronounced symptomatology, the diagnosis can be more challenging than anterior instability, as many patients have vague shoulder pain rather than complaints of frank instability.⁵ Three common causes of posterior shoulder instability are

congenital retroversion, a single traumatic event, or repetitive microtrauma with erosive effects.^{2,4,6,7} While most posterior shoulder instability can be treated conservatively with rehabilitation, surgical correction is warranted in cases of persistent pain, limitations of activities or activities of daily living, or recurrent continued instability.⁸⁻¹¹

Similar to anterior instability, but less well defined, the critical determination when deciding on the appropriate treatment of posterior shoulder instability is the presence and degree of glenoid bone loss. When bone loss occurs, it is typically encountered between the 6:30 and 9:30 o'clock positions with a mean slope of 30.7 degrees relative to the long axis of the native glenoid.¹² The greater the degree of slope difference compared with the long axis of the native glenoid, the greater the risk of recurrent instability.¹³ Similar to anterior shoulder instability, in patients without bone loss, arthroscopic procedures have a high success rate with a failure rate of less than 10% and an 89% return-to-sport rate.^{8,14,15} The critical bone loss posteriorly and the amount of bony attrition at which arthroscopic procedures fail at an unacceptably high rate are still poorly defined. Recent studies have demonstrated that in the setting of anterior instability, glenoid bone loss values as low as 15% have been defined as the critical limit for open procedures anteriorly.¹⁶ Recent reports that attempt to quantify the critical bone loss value posteriorly have ranged from 13.5% to 20%.^{13,17,18}

From the Steadman Philippon Research Institute, Vail, Colorado, U.S.A. (J.D.C., J.J.R., P.-C.N., B.P.E., P.J.M.) and The Steadman Clinic, Vail, Colorado, U.S.A. (J.D.C., J.J.R., P.J.M.).

The authors report the following potential conflicts of interest or sources of funding: P.-C.N. receives support from Arthrex. P.J.M. is a consultant for and receives royalties from Arthrex, Medbridge, and Springer; owns stock in GameReady and VuMedi; receives support from the Steadman Philippon Research Institute and Vail Valley Medical Center; and has corporate sponsorship from the Steadman Philippon Research Institute, Smith & Nephew, Arthrex, Siemens, and Össur. Full ICMJE author disclosure forms are available for this article online, as [supplementary material](#).

Received October 26, 2020; accepted January 11, 2021.

Address correspondence to Peter J. Millett, M.D., M.Sc., Steadman Philippon Research Institute, The Steadman Clinic, 181 W Meadow Dr, Ste 400, Vail, CO 81657, U.S.A. E-mail: drmillett@thesteadmanclinic.com

© 2021 THE AUTHORS. Published by Elsevier Inc. on behalf of the Arthroscopy Association of North America. This is an open access article under the CC BY-NC-ND license (<http://creativecommons.org/licenses/by-nc-nd/4.0/>).

2212-6287/201767

<https://doi.org/10.1016/j.eats.2021.01.023>

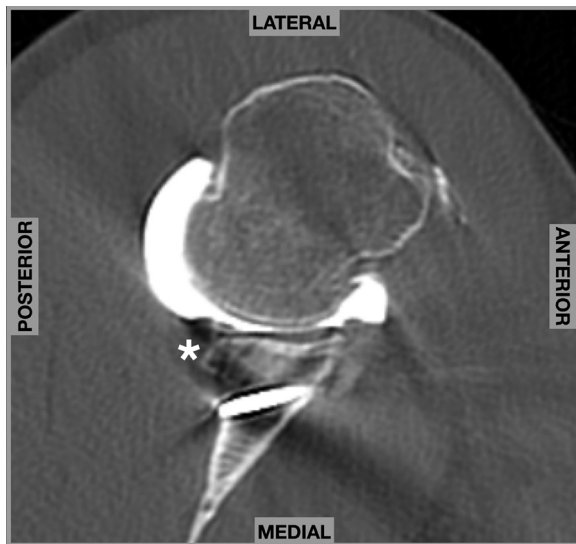


Fig 1. Computed tomography image of a right shoulder in the transverse plane. Note the screw from the prior Latarjet procedure. Asterisk: Area of posterior glenoid bone loss.

This Technical Note describes our preferred method of open surgical treatment of posterior shoulder instability with posterior glenoid bone loss using an intra-articular distal tibial allograft.

Preoperative Planning

In addition to the history focusing on activities, goals, comorbidities, and a detailed dislocation history and physical examination that includes a neurovascular examination, rotator cuff strength assessment, and posterior instability-specific examination maneuvers, a thorough imaging evaluation is necessary to identify possible posterior bone loss. Radiograph evaluation in conjunction with magnetic resonance imaging or computed tomography (CT) (Fig 1), with or without 3D-dimensional reconstructions, allows not only for assessment of soft tissue pathology, including labral tissue and cartilage, but also for a reverse Hill Sachs lesion and the location and extent of posterior glenoid bone loss, details crucial for appropriate preoperative planning.

Patient Position and Anesthesia

Prior to positioning, an examination under anesthesia of the effected shoulder, as well as the contralateral shoulder, is performed for comparison. The patient is positioned lateral decubitus with a beanbag and an arm holder. Care should be taken to position the proximal beanbag in a manner to allow access to the posterior shoulder for the open incision. Furthermore, it is also useful to adjust the bed into a reverse-Trendelenburg position to place the glenoid plane perpendicular relative to the ground. The complete surgical technique is depicted in Video 1.

Superficial Surgical Approach

The complete surgical technique is depicted in Video 1. A 12-cm vertical incision is made 2 cm lateral to the perceived glenohumeral joint line (Fig 2). The incision is carried sharply down to the level of deltoid fascia, and full-thickness skin flaps are raised. At this point, a spinal needle is used to confirm joint location. The deltoid fascia is then split at the level of and parallel to the glenohumeral joint. Electrocautery is then used to split the deltoid muscle fibers in line with the facial incision. Once dissection is continued through the anterior deltoid fascia, a potential space is identified just posterior to the rotator cuff muscles.

Deep Surgical Approach

Upon encountering the posterior rotator cuff, a fat stripe can be visualized that identifies the interval between the infraspinatus and the teres minor (Fig 3). This interval is developed beginning 3 to 4 cm lateral to the joint line and working medially to the tendinous insertion. The muscles of the rotator cuff are carefully mobilized, beginning medially, to separate them from the underlying capsule. Once the capsule is clearly identified at the level of the glenohumeral joint, a long-handled knife is used to incise the often patulous and redundant capsule vertically in line with the posterior glenoid rim. Exposure of the posterior glenoid is facilitated by use of a Fukuda retractor that is then placed within the joint to retract the humeral head laterally, a 3-pronged glenoid retractor within the capsulotomy but along the posterior neck of the glenoid, and a wide Richardson retractor to retract the musculature inferiorly.

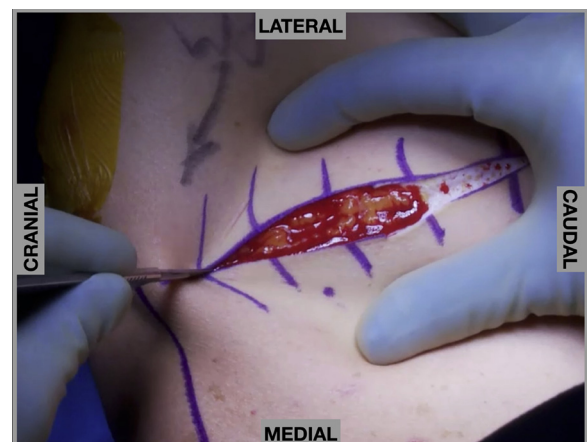


Fig 2. Intraoperative images of a right shoulder in the lateral decubitus position. A 12-cm vertical incision is made approximately 2 cm lateral to the perceived glenohumeral joint.

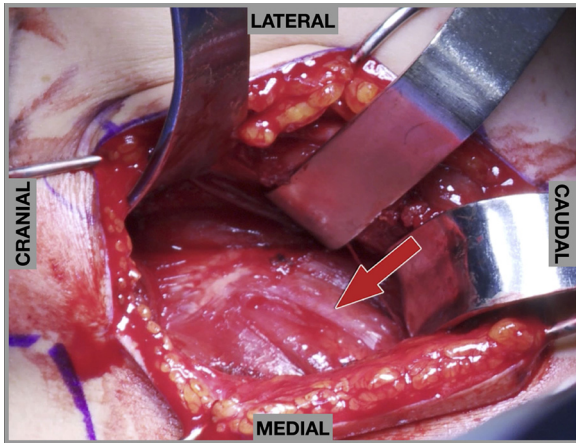


Fig 3. Intraoperative images of a right shoulder in the lateral decubitus position. View of the rotator cuff muscles from posteriorly. A fat stripe (red arrow) demarcates the interval between the infraspinatus and the teres minor, which is developed to gain access to the capsule.

Glenoid Preparation

The posterior labrum is completely excised from the 6 to 9:30 o'clock positions. The posterior glenoid is then decorticated through the use of a high-speed bone-cutting burr and rongeur (Fig 4). The Arthrex (Naples, FL) distal tibial allograft guide system is used to approximate the size of the appropriate bone block to be fashioned in order to re-create the native glenoid morphology (Fig 5). Care is taken to size not only the magnitude of the bone block but also the slope of the graft at the articular surface.

Graft Preparation and Insertion

The desired sized fresh distal tibia allograft is fashioned with the help of the Arthrex distal tibia allograft graft prep station. Next, a pulsatile lavage is used for 60 seconds to remove any theoretic antigenicity.

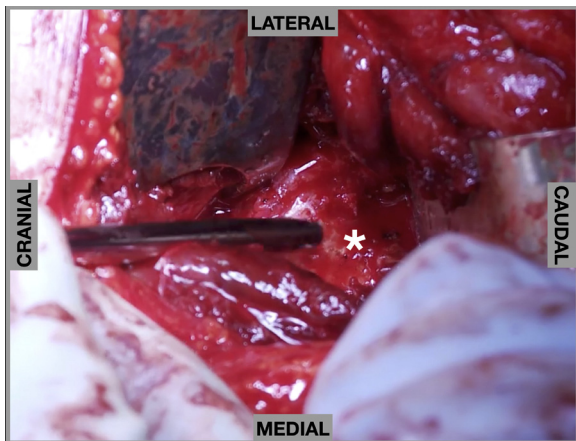


Fig 4. Intraoperative images of a right shoulder in the lateral decubitus position. The posterior glenoid is decorticated with a high-speed bone cutting burr. Asterisk: Glenoid neck.

Finally, the graft is soaked in platelet-rich plasma for an additional 60 seconds.

A 3.5-mm drill is used to create 2 parallel gliding holes in the graft to facilitate the eventual lag by technique fixation with the goal of achieving maximum hole separation (Fig 6). The prepared graft is then positioned to the desired location on the posterior glenoid and temporarily fixed in place with a K-wire.

A 2.5-mm drill bit is then placed through the superior predrilled hole in the graft, and an appropriate-length 3.5-mm solid cortical screw is placed (Fig 7A). Once provisionally tightened, these same steps are repeated for the inferior screw, thus completing graft fixation using lag by technique principles using solid cortical screws (Fig 7B).

Capsulorrhaphy and Closure

Following bone block fixation, a No. 2 nonabsorbable suture is used to imbricate the often redundant posterior capsule. After capsular closure, an additional No. 2 nonabsorbable suture is used to reapproximate the musculature interval between the infraspinatus and teres minor. The deltoid fascia is closed using a No. 0 absorbable suture, while the rest of the wound is closed in a layered fashion.

Postoperative Rehabilitation

The patient is placed into a simple shoulder sling following the procedure that is worn for a total of 6 weeks. Early gentle passive range of motion is initiated immediately. At 6 weeks, a CT scan is obtained to evaluate for bony union, and if present, the rehabilitation is proceeded to active range-of-motion exercises. Scapular and rotator cuff strengthening begins at 8 to 10 weeks postoperatively, with return to full activity typically allowed at 6 months. Pearls and pitfalls of open posterior glenoid reconstruction using an intra-articular distal tibial allograft are presented in Table 1.

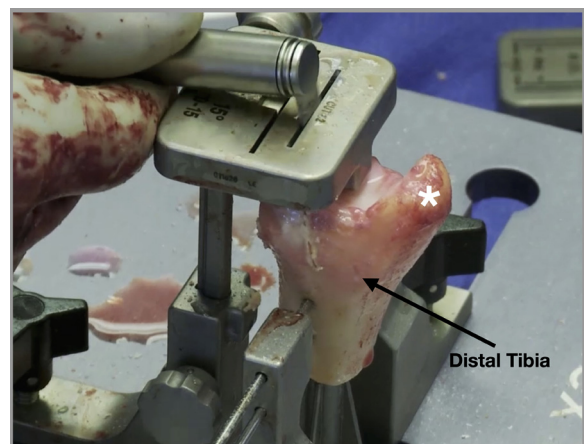


Fig 5. Preparation of the distal tibial allograft on the back table. Asterisk: Medial malleolus.

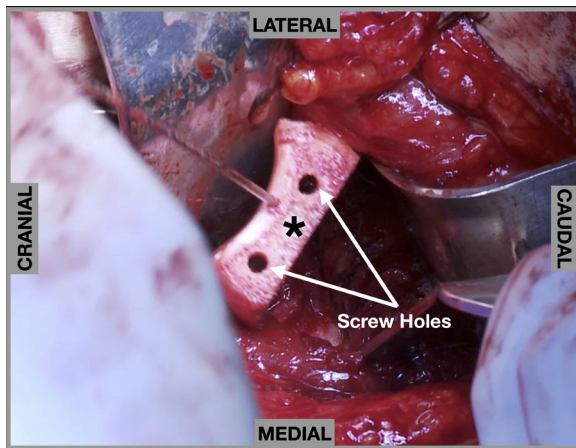


Fig 6. Intraoperative images of a right shoulder in the lateral decubitus position. Two 3.5-mm parallel drill holes are placed in the graft to facilitate eventual lag by technique fixation. Asterisk: Distal tibial allograft.

Discussion

Similar to anterior shoulder instability, outcomes of arthroscopic and open posterior shoulder stabilizations may be related to the underlying cause of the pathology. Bone loss may necessitate and open bone block reconstruction, while an acute traumatic event with a labral tear and minimal bony attrition may be appropriately treated with an arthroscopic procedure.^{19,20} Multiple techniques of open posterior glenoid reconstruction have been described, and both scapular spinal autograft and distal tibial allograft have demonstrated in a cadaveric study equivalence in adequately restoring native posterior glenoid stability in the setting of bone loss.²¹ In this Technical Note, we describe the senior author's (PJM) preferred open technique for treatment of posterior shoulder instability in the setting of glenoid bone loss using an intra-articular distal tibia osteochondral allograft.

In a previously published case series of 2 active male patients with 2-year follow-up treated with the described technique, Millett et al.²² reported CT-confirmed bony union, improved patient-reported outcome measures and pain scores, and return to recreational sports at final follow-up.

The most commonly reported complication when using an open bone block technique in the shoulder is resorption of the posterior bone block, which may or may not correlate with any clinical symptoms.²³⁻²⁶ Clinically, Gosens et al.²⁵ reported an 18% incidence of persistent pain as well as a 36% incidence of limited internal rotation. Long-term follow-up in the same cohort revealed persistent pain and continued instability in 72% and 36%, respectively.²⁴ Walch et al.^{23,26} report on their results of posterior glenoid bone block procedures, with only 13% of patients having persistent apprehension at final follow-up but still a high rate (29%) of internal rotation deficiency. Risks or potential complications related to the approach include injury to the axillary nerve or posterior humeral circumflex artery in the quadrangular space if the proper interval between the teres minor and infraspinatus is not identified. Additional potential complications during the surgery can involve proper drilling for posterior screws, as penetration too far anterior can risk the neurovascular structures and cause irritation to the subscapularis.

In conclusion, posterior shoulder instability is an increasingly recognized, underappreciated origin of shoulder pain. While arthroscopic procedures perform well in the setting of isolated soft tissue injuries, open glenoid reconstruction is required to treat cases with bone loss. This Technical Note describes the senior author's preferred method of open intra-articular posterior glenoid reconstruction with capsulorrhaphy.

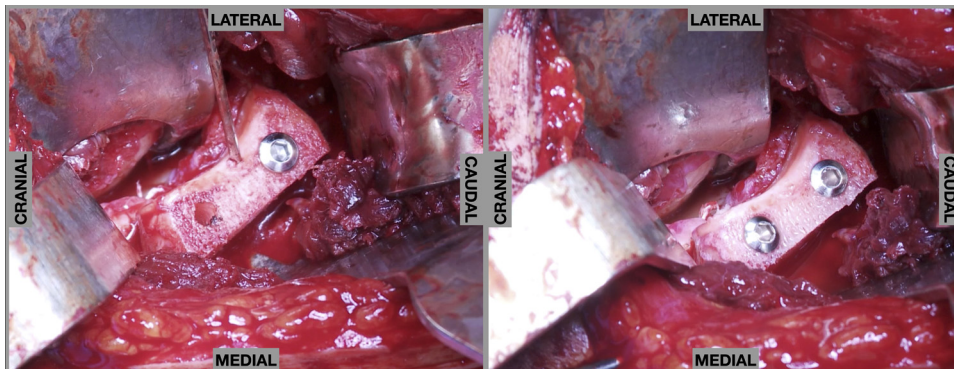


Fig 7. Intraoperative images of a right shoulder in the lateral decubitus position. (A) A superior 3.5-mm solid cortical screw is inserted into the predrilled hole in the graft. (B) An inferior 3.5-mm solid cortical screw is inserted into the predrilled hole in the graft to complete graft fixation using lag-by-technique principles.

Table 1. Pearls and Pitfalls

Pearls	Pitfalls
Start incision 2 cm lateral to glenohumeral joint line, prevents obstruction by soft tissue and facilitates the deep exposure.	Do not place drill holes in graft too close together, can lead to fracture of the graft. Ensure at least 1-cm gap.
Three-pronged retractor medially on the glenoid allows thorough visualization for glenoid bone preparation.	Prevent aggressive range of motion or therapy early; the first 6 weeks should be gentle passive motion only.
Purse lavage donor graft to remove all marrow elements and soak for at least 60 seconds in platelet-rich plasma.	
Place superior screw first without overtightening, can then rotate graft around superior screw to ensure proper alignment with glenoid.	

References

- Provencher MT, Bhatia S, Ghodadra NS, et al. Recurrent shoulder instability: Current concepts for evaluation and management of glenoid bone loss. *J Bone Joint Surg Am* 2010;92:133-151 (suppl 2).
- Provencher MT, LeClere LE, King S, et al. Posterior instability of the shoulder: Diagnosis and management. *Am J Sports Med* 2011;39:874-886.
- DeLong JM, Bradley JP. Posterior shoulder instability in the athletic population: Variations in assessment, clinical outcomes, and return to sport. *World J Orthop* 2015;6:927-934.
- Owens BD, Campbell SE, Cameron KL. Risk factors for posterior shoulder instability in young athletes. *Am J Sports Med* 2013;41:2645-2649.
- Bernhardson AS, Murphy CP, Aman ZS, LaPrade RF, Provencher MT. A prospective analysis of patients with anterior versus posterior shoulder instability: A matched cohort examination and surgical outcome analysis of 200 patients. *Am J Sports Med* 2019;47:682-687.
- Bryce CD, Davison AC, Okita N, Lewis GS, Sharkey NA, Armstrong AD. A biomechanical study of posterior glenoid bone loss and humeral head translation. *J Shoulder Elbow Surg* 2010;19:994-1002.
- Wirth MA, Lyons FR, Rockwood CA Jr. Hypoplasia of the glenoid. A review of sixteen patients. *J Bone Joint Surg Am* 1993;75:1175-1184.
- Robinson CM, Aderinto J. Recurrent posterior shoulder instability. *J Bone Joint Surg Am* 2005;87:883-892.
- Van Tongel A, Karelse A, Berghs B, Verdonk R, De Wilde L. Posterior shoulder instability: Current concepts review. *Knee Surg Sports Traumatol Arthrosc* 2011;19:1547-1553.
- DiMaria S, Bokshan SL, Nacca C, Owens B. History of surgical stabilization for posterior shoulder instability. *JSES Open Access* 2019;3:350-356.
- Moroder P, Danzinger V, Maziak N, et al. Characteristics of functional shoulder instability. *J Shoulder Elbow Surg* 2020;29:68-78.
- Dekker TJ, Peebles LA, Goldenberg BT, Millett PJ, Bradley JP, Provencher MT. Location of the glenoid defect in shoulders with recurrent posterior glenohumeral instability. *Am J Sports Med* 2019;47:3051-3056.
- Beaulieu-Jones BR, Peebles LA, Golijanin P, et al. Characterization of posterior glenoid bone loss morphology in patients with posterior shoulder instability. *Arthroscopy* 2019;35:2777-2784.
- McClincy MP, Arner JW, Thurber L, Bradley JP. Arthroscopic capsulolabral reconstruction for posterior shoulder instability is successful in adolescent athletes. *J Pediatr Orthop* 2020;40:135-141.
- DeLong JM, Jiang K, Bradley JP. Posterior instability of the shoulder: A systematic review and meta-analysis of clinical outcomes. *Am J Sports Med* 2015;43:1805-1817.
- Shin SJ, Koh YW, Bui C, et al. What is the critical value of glenoid bone loss at which soft tissue Bankart repair does not restore glenohumeral translation, restricts range of motion, and leads to abnormal humeral head position? *Am J Sports Med* 2016;44:2784-2791.
- Nacca C, Gil JA, Badida R, Crisco JJ, Owens BD. Critical glenoid bone loss in posterior shoulder instability. *Am J Sports Med* 2018;46:1058-1063.
- Hines A, Cook JB, Shaha JS, et al. Glenoid bone loss in posterior shoulder instability: Prevalence and outcomes in arthroscopic treatment. *Am J Sports Med* 2018;46:1053-1057.
- Lacheta L, Goldenberg BT, Horan MP, Millett PJ. Posterior bony Bankart bridge technique results in reliable clinical 2-year outcomes and high return to sports rate for the treatment of posterior bony Bankart lesions. *Knee Surg Sports Traumatol Arthrosc* 2021;29:120-126.
- Katthagen JC, Tahal DS, Montgomery SR, Horan MP, Millett PJ. Association of traumatic and atraumatic posterior shoulder instability with glenoid retroversion and outcomes after arthroscopic capsulolabral repair. *Arthroscopy* 2017;33:284-290.
- Nacca C, Gil JA, DeFroda SF, Badida R, Owens BD. Comparison of a distal tibial allograft and scapular spinal autograft for posterior shoulder instability with glenoid bone loss. *Orthop J Sports Med* 2018;6:2325967118786697.
- Millett PJ, Schoenahl JY, Register B, Gaskill TR, van Deurzen DF, Martetschläger F. Reconstruction of posterior glenoid deficiency using distal tibial osteoarticular allograft. *Knee Surg Sports Traumatol Arthrosc* 2013;21:445-449.

23. Lèvigne C, Garret J, Walch G. Posterior bone block for posterior instability. *Techn Shoulder Elbow Surg* 2005;6:26-35.
24. Meuffels DE, Schuit H, van Biezen FC, Reijman M, Verhaar JA. The posterior bone block procedure in posterior shoulder instability: a long-term follow-up study. *J Bone Joint Surg Br* 2010;92:651-655.
25. Gosens T, van Biezen FC, Verhaar JA. The bone block procedure in recurrent posterior shoulder instability. *Acta Orthop Belg* 2001;67:116-120.
26. Servien E, Walch G, Cortes ZE, Edwards TB, O'Connor DP. Posterior bone block procedure for posterior shoulder instability. *Knee Surg Sports Traumatol Arthrosc* 2007;15:1130-1136.