







## Case Report

# Multiple Osteochondritis Dissecans in Multiple Joints

Takuto Takeda,<sup>1</sup> Ryuichiro Akagi ,<sup>1</sup> Yusuke Sato ,<sup>1</sup> Takahiro Enomoto ,<sup>1</sup>  
Ryosuke Nakagawa,<sup>1</sup> Seiji Kimura ,<sup>1,2</sup> Satoshi Yamaguchi ,<sup>1,3</sup> Satoru Nishikawa,<sup>4</sup>  
and Takahisa Sasho <sup>1,5</sup>

<sup>1</sup>Department of Orthopedic Surgery, Graduate School of Medicine, Chiba University, Japan

<sup>2</sup>Department of Orthopaedic Surgery, Center for Advanced Joint Function and Reconstructive Spine Surgery, Graduate School of Medicine, Chiba University, Japan

<sup>3</sup>Graduate School of Global and Transdisciplinary Studies, Chiba University, Japan

<sup>4</sup>Nishikawa Orthopedics Clinic, Japan

<sup>5</sup>Musculoskeletal Pain and Diseases, Center for Preventive Medical Sciences, Chiba University, Japan

Correspondence should be addressed to Ryuichiro Akagi; [rakagi@chiba-u.jp](mailto:rakagi@chiba-u.jp)

Received 27 June 2020; Revised 8 December 2020; Accepted 16 January 2021; Published 29 January 2021

Academic Editor: Koichi Sairyō

Copyright © 2021 Takuto Takeda et al. This is an open access article distributed under the Creative Commons Attribution License, which permits unrestricted use, distribution, and reproduction in any medium, provided the original work is properly cited.

**Background.** Osteochondritis dissecans (OCD) rarely occurs in multiple joints. Furthermore, the existence of left-right asymmetric OCDs in different joints of the contralateral side of the body and lesions occurring with a temporal difference is rare. Here, we report a rare case with multiple OCDs sequentially detected in various joints. **Case Presentation.** The 15-year-old male patient was referred to our hospital for an OCD in the medial femoral condyle of the left knee. He had a history of an OCD in his right elbow, and his father had a history of surgically treated OCDs in both knees. One year and five months after, surgery was performed to the lesion in his left medial femoral condyle, a new OCD lesion occurred in the femoral trochlea of the same knee, which was again treated surgically. Five months after the second surgery, the patient returned with pain in the right knee, and an OCD on the right femoral trochlea was detected by an MRI scan. This lesion remained stable without any further restriction in physical activities for 17 months until detachment occurred and was again treated surgically. **Conclusion.** In cases with history and a family history of multiple OCDs, in particular, with a short stature, an MRI scan should be performed for the symptomatic joint to detect and treat the lesion before progression.

## 1. Background

Osteochondritis dissecans (OCD) is a disorder that affects the subchondral bone and potentially leads to detachment of cartilage and bone fragment with progression [1]. It is known to occur more frequently in male than in female. However, the exact etiology of the disease is unknown. Several theories have been described, including trauma, genetics, inflammation, nutritional imbalance, and vascular abnormalities [2–4].

Some cases with bilateral knee OCDs have been reported [5, 6], but there are no previous cases reported for more than three OCDs occurring in multiple joints. We present a case of a patient who presented with clinically symptomatic multiple

OCDs which occurred in multiple joints, including the elbow and knee joint.

## 2. Case Presentation

A 15-year-old boy was referred to our department after the failure of a conservative treatment to an OCD lesion in his left knee. He presented at his orthopedic practitioner three months before referral to our department, complaining of pain in his left knee during sports activity such as baseball. At the initial visit, his height was 150 cm, which was below the -2 standard deviation (SD) cutoff (approximately -2.8 SD) of Japanese average of the same age, with a body mass index of 22. He had a history of OCD in the right elbow at

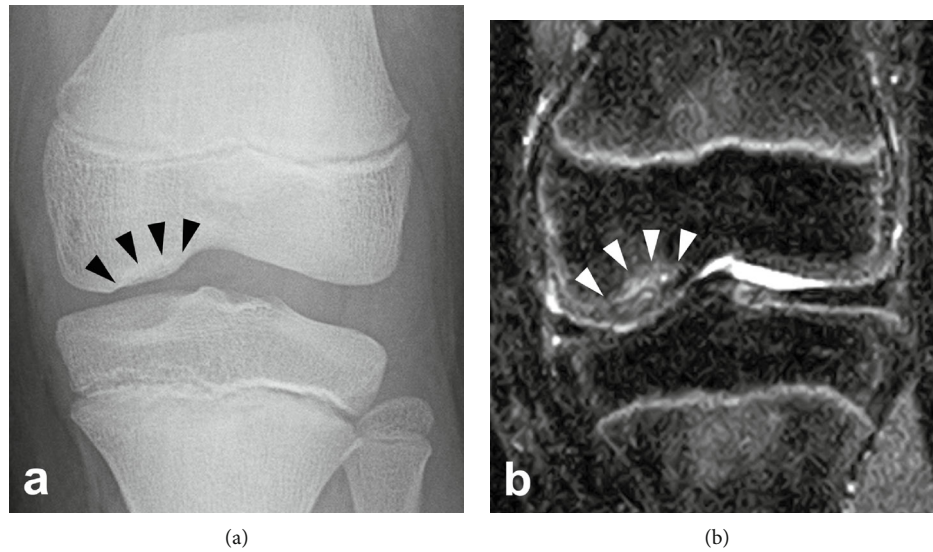


FIGURE 1: (a) Radiograph of the left knee showing Brückl's stage III OCD lesion in the MFC. (b) Short T1 inversion recovery (STIR) sequence MRI coronal image of the left knee indicating Nelson's stage II lesion in the MFC.

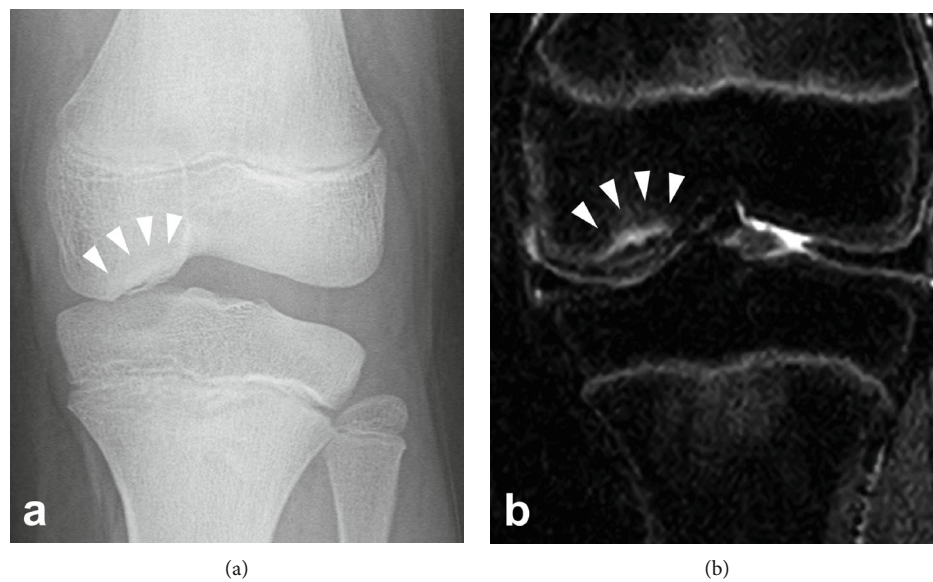


FIGURE 2: (a) Radiograph of the left knee showing Brückl's stage IV OCD lesion in the MFC. (b) STIR MRI coronal image of the left knee indicating Nelson's stage III lesion in the MFC.

the age of 11. The patient's father also had short stature (153 cm, -3.1SD) and had a history of OCDs in both knees, which was surgically treated after maturity. There was no other family history of OCD. There was no swelling or tenderness of the knee joint, and no abnormalities in the range of motion or joint laxity and stability were detected on physical examination. The boy did not have any pain during normal daily activities, including PE. An OCD of the medial femoral condyle (MFC) was detected by radiograph and classified as stage III, according to Brückl [7] (Figure 1(a)). The lesion was confirmed by magnetic resonance imaging (MRI) of the left knee, which was classified as stage II, according to Nelson's classification [8] (Figure 1(b)). He was treated con-

servatively by avoiding intense physical activity, while physical education (PE) at school was permitted. Despite the advertent treatment for three months, the radiographic finding of the lesion progressed to stage IV according to Brückl's classification (Figure 2(a)) and stage III according to Nelson's classification on MRI (Figure 2(b)). At this moment, he was referred to our department for surgical treatment.

Since the patient was asymptomatic at the time he was referred to our department, he was treated conservatively for another three months but did not show any improvement in radiographic finding. Thus, we decided to perform surgical treatment. The operative treatment consisted of an initial arthroscopy. The lesion was identified since there was

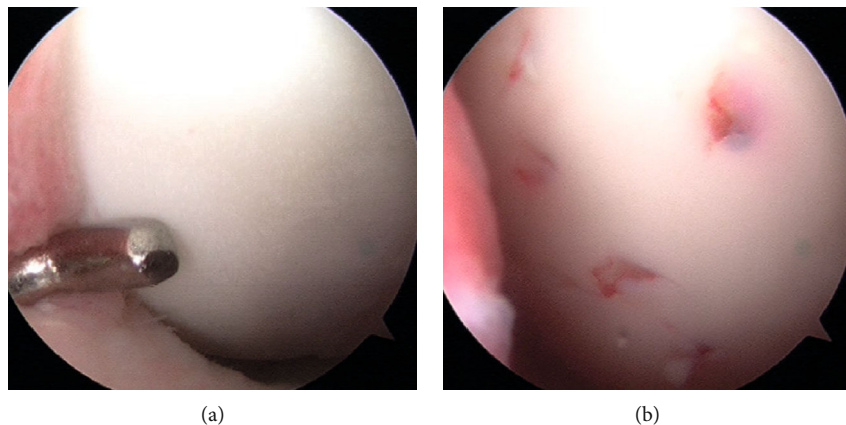


FIGURE 3: Arthroscopic finding of the left medial femoral condyle. (a) The lesion was identified by probing the cartilage surface and cleavage in the rim was detected. (b) Percutaneous drilling was performed in the lesion.

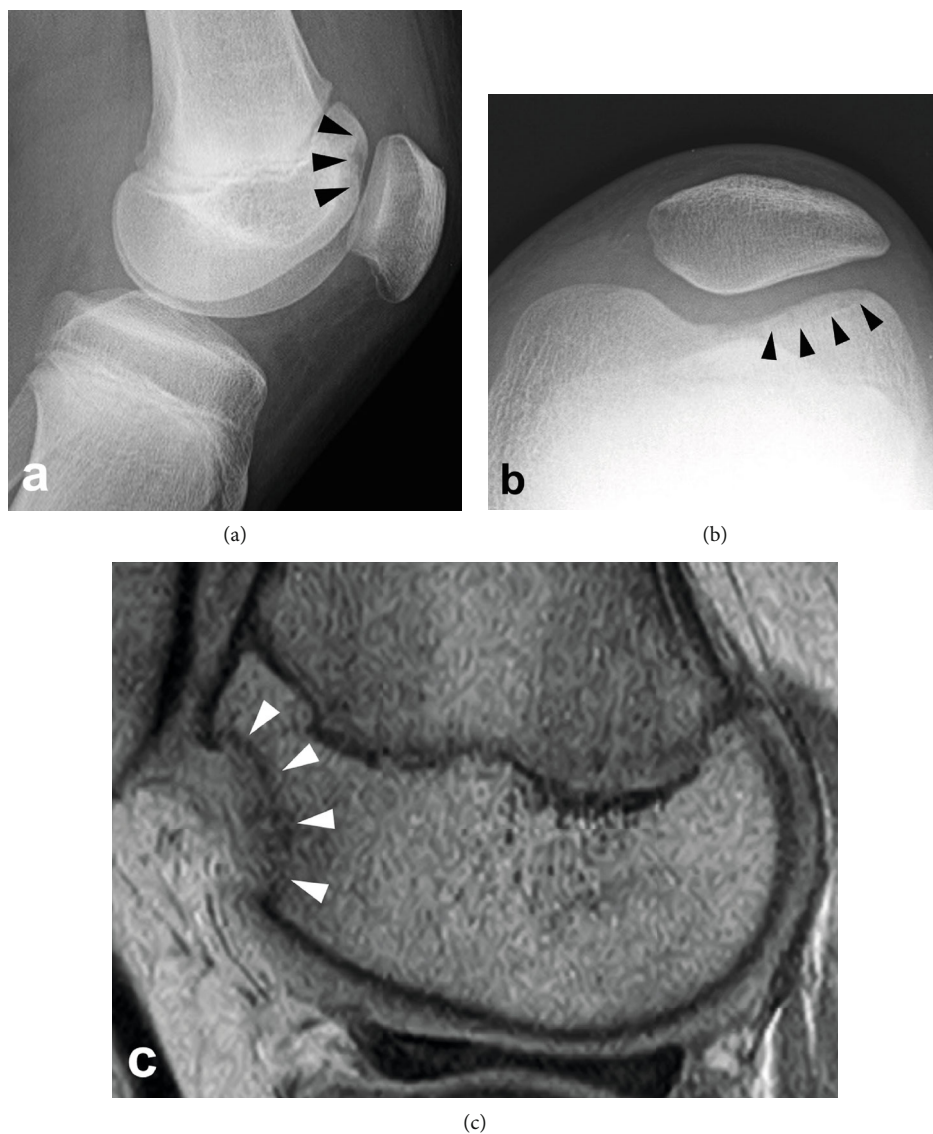


FIGURE 4: (a) Lateral view and (b) skyline view radiograph of the left knee showing Brückl's stage V OCD lesion in the lateral facet of the femoral trochlea. (c) Proton density-weighted MRI sagittal image of the left knee indicating Nelson's stage III lesion in the lateral facet of the femoral trochlea.

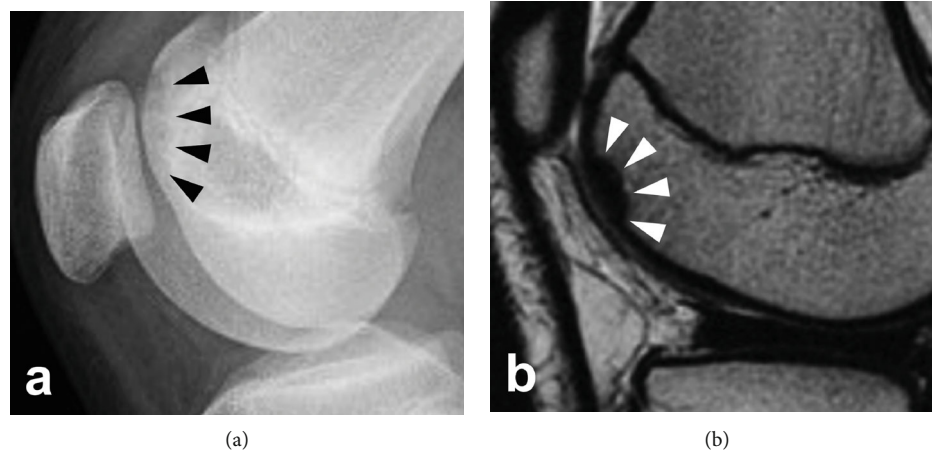


FIGURE 5: (a) Lateral view radiograph of the right knee showing Brückl's stage II OCD lesion in the lateral facet of the femoral trochlea. (b) T2-weighted MRI sagittal image of the right knee indicating Nelson's stage I lesion in the lateral facet of the femoral trochlea.

cleavage in the rim of the lesion by probing (Figure 3(a)), and the cartilage was slightly levitated, but not completely detached from the subchondral bone. The size of the lesion was 10 mm in width and 24 mm in length. Arthroscopic drilling with a 1.6 mm Kirschner wire from the surface of the lesion in MFC was performed, creating ten penetration deep enough to reach the subchondral bone underlying the lesion, for the purpose of inducing bleeding from the bone marrow to stimulate healing (Figure 3(b)). The lesion was confirmed to have achieved bony union by radiograph three months after surgery; sports activities were permitted.

The postoperative course was successful until one year and four months after surgery when he fell and hit the left anterior knee. The radiograph taken immediately after this injury showed no abnormal findings. Since the patient started to feel pain on running, and since an event of locking of the knee joint occurred, we performed another radiographic examination one month after the injury but were unable to detect any abnormal findings, and the patient was conservatively treated. Four months after the injury, the knee became more frequently locked, and knee pain on flexion and swelling of the knee joint became evident, and another radiographic examination was performed. A defect in the lateral facet of the femoral trochlea that had been normal on the previous MRI before this event was detected by radiography, and the lesion was confirmed by MRI scan. The lesion was diagnosed as OCD in the femoral trochlea (Brückl classification stage V in the radiograph, and Nelson classification stage IV in MRI), and no kissing lesion was confirmed on the patella (Figure 4). The osteochondral fragment was treated surgically by fixation to the bed by four biodegradable pins. The fragment was confirmed to be stable by computed tomography and MRI scans, and the patient was allowed to return to sports at four months after surgery.

One month after returning to sports (5 months after fragment fixation surgery), the patient returned to the office complaining of pain in his contralateral knee during sports activities without any obvious history of injury. Radiography and MRI scan were performed for his right knee, and an OCD lesion of Brückl's classification stage II and Nelson's

classification stage I OCD in the lateral facet of the trochlea was identified (Figure 5). The lesion was carefully observed and remained stable without any further restriction in physical activities. However, the lesion became unstable 17 months after its initial detection, and we performed an open reduction and internal fixation surgery under spinal anesthesia. The fragment was confirmed to have achieved union by three months after surgery.

### 3. Discussion and Conclusion

In the presented case, we experienced multiple OCDs occurring in various joints (4 lesions in the three joints), with the temporal difference in occurrence. We failed to detect one of the lesions in the early phase of the disease before detachment from the base and were required to perform surgery to treat the lesion.

In terms of the epidemiology of OCDs, bilateral lesions have been reported to be present in 7.3-29% [9-11] of OCDs of the knee. Bilateral knee OCDs might not be so rare, but a case of multiple OCDs occurring in multiple joints is a relatively rare condition. There were 21 cases of OCDs occurring in multiple joints previously reported in the literature, including bilateral knee cases [3, 5, 6, 12-25]. Among them, there was only one case that was reported for the existence of left-right asymmetric OCDs in different joints of the contralateral side of the body. We were able to identify some case reports regarding multiple OCDs that developed in a single knee joint. There were 10 cases in total. However, there was only one case which had two OCDs in the MFC and the patella-femoral compartment. It is also known that the main lesion of OCD is the classical site in the MFC, which accounts for 69% of the whole OCDs, and OCDs occurring in the trochlea is relatively rare [26].

Considering the timing of diagnosis of multiple OCDs according to the literature, there were 26 cases of multiple OCDs that mentioned the time point of diagnosis of each lesion. In most cases, multiple lesions were identified at the same time, and there were only 6 cases, which was diagnosed one after the other. It was reported that, in 40% of bilateral



OCD cases, the incidentally diagnosed contralateral lesion was asymptomatic [9]. In other words, most lesions seem to occur around the same time regardless of symptoms, and a case that multiple symptomatic OCDs were occurring with a temporal difference is rare. In our case, all lesions were symptomatic at the time of diagnosis but were not necessarily detectable by radiographs until the progression of the disease. The presented case was rare in that (1) multiple OCD lesions in different joints (elbow and knees) were involved, (2) multiple lesions occurred with temporal difference instead of occurring at the same time, and (3) the femoral trochlea was affected bilaterally.

Several theories have been suggested for the etiology of OCDs, including ischemia of subchondral bone, trauma, repetitive microtrauma, genetic factor, metabolic disease, and inflammatory disease [2–4]. However, the cause of this disease is still under debate. In the case presented in this report, the patient and his father both had the phenotypic form of a short stature, with multiple OCDs. There are several case reports of multiple OCDs occurring in twins [3], within the family [12–14, 27], and some reported multiple OCDs occurring in a family with short stature [12, 27–29]. Genetic factors may play a major role in these cases.

There are a couple of limitations in the present paper. First, the lesion at the trochlea of the left knee might not be the OCD but traumatic osteochondral lesion. There were no abnormal findings on the patella on MRI, and lack of kissing lesion in the patella might support our diagnosis as an OCD. Second, an MRI exam of the right knee was performed only once before we detected the OCD in the right trochlea. Thus, we could not tell when the lesion developed.

In conclusion, in cases with history of OCD and a family history of multiple OCDs, in particular, with a short stature, an MRI scan should be performed for the symptomatic joint [30, 31] to detect and conservatively treat the lesion before progression.

## Abbreviation

OCD: Osteochondritis dissecans.

## Ethical Approval

Informed consent was obtained from the patient and from the patient's legal guardians for publication of this case report and any accompanying images. A copy of the written consent is available for review by the Editor-in-Chief of this journal. The ethics approval was waived according to the institutional review board bylaw for publications of case reports.

## Conflicts of Interest

No external funding was applied for this case report and the authors declare that they have no competing interest.

## Authors' Contributions

TT mainly took care of the reported patient during inpatient and drafted the manuscript. RA is the corresponding author

who coordinated the study and helped to draft and substantively revised the manuscript. YS, TE, RN, SK, SY, and SN were involved in patient care and acquisition as well as interpretation of data. TS was the primary doctor of the patient and conceived of the study and was involved in acquisition of the data during outpatient visits. All authors read and approved the final manuscript.

## References

- [1] F. Accadbled and J. Vial, "Osteochondritis dissecans of the knee," *Orthopaedics & Traumatology: Surgery & Research*, vol. 104, no. 1, pp. S97–105, 2018.
- [2] F. Tóth, M. J. Nissi, J. M. Ellermann et al., "Novel application of magnetic resonance imaging demonstrates characteristic differences in vasculature at predilection sites of osteochondritis dissecans," *The American Journal of Sports Medicine*, vol. 43, no. 10, pp. 2522–2527, 2015.
- [3] O. Mei-Dan, G. Mann, G. Steinbacher, R. B. Cugat, and P. D. Alvarez, "Bilateral osteochondritis dissecans of the knees in monozygotic twins: the genetic factor and review of the etiology," *American Journal of Orthopedics (Belle Mead, N.J.)*, vol. 38, no. 9, pp. E152–E155, 2009.
- [4] J. Bruns, M. Werner, and C. Habermann, "Osteochondritis dissecans: etiology, pathology, and imaging with a special focus on the knee joint," *Cartilage*, vol. 9, no. 4, pp. 346–362, 2018.
- [5] M. M. Schneider, S. Preiss, and G. M. Salzmann, "Direct comparison of different surgical approaches in a woman with bilateral osteochondrosis dissecans of her knees: a case report," *Journal of Medical Case Reports*, vol. 10, no. 1, 2016.
- [6] J. S. Filho, E. Garms, J. Sayum et al., "Bilateral osteochondritis dissecans of the knee in a basketball player: case report," *Revista Brasileira de Ortopedia (English Edition)*, vol. 47, no. 2, pp. 257–259, 2012.
- [7] R. Brückl, B. Rosemeyer, and G. Thiermann, "Behandlungsergebnisse der osteochondrosis dissecans des Kniegelenkes bei Jugendlichen," *Zeitschrift für Orthopädie und ihre Grenzgebiete*, vol. 120, no. 5, pp. 717–724, 2008.
- [8] J. D. Dipaola, D. W. Nelson, and M. R. Colville, "Characterizing osteochondral lesions by magnetic resonance imaging," *Arthroscopy*, vol. 7, no. 1, pp. 101–104, 1991.
- [9] T. Cooper, A. Boyles, W. P. Samora, and K. E. Klingele, "Prevalence of bilateral JOCD of the knee and associated risk factors," *Journal of Pediatric Orthopedics*, vol. 35, no. 5, pp. 507–510, 2015.
- [10] F. Hefti, J. Beguiristain, R. Krauspe et al., "Osteochondritis dissecans: a multicenter study of the European Pediatric Orthopedic Society," *Journal of Pediatric Orthopaedics. Part B*, vol. 8, no. 4, pp. 231–245, 1999.
- [11] J. I. Kessler, H. Nikizad, K. G. Shea, J. C. Jacobs, J. D. Bechuk, and J. M. Weiss, "The demographics and epidemiology of osteochondritis dissecans of the knee in children and adolescents," *The American Journal of Sports Medicine*, vol. 42, no. 2, pp. 320–326, 2014.
- [12] O. Cetik, M. Turker, and M. Uslu, "Bilateral osteochondritis dissecans of lateral femoral condyle," *Knee Surgery, Sports Traumatology, Arthroscopy*, vol. 13, no. 6, pp. 468–471, 2005.
- [13] A. Ghali, S. L. J. James, A. Saifuddin, and T. W. R. Briggs, "Bilateral osteochondrosis of the superior pole of the patellae in association with bilateral osteochondritis dissecans of the

- lateral femoral condyle," *Clinical Radiology*, vol. 63, no. 4, pp. 478–482, 2008.
- [14] R. Gudas, R. Simonaitytė, E. Čekanauskas, and T. Mickevičius, "Concomitant autologous chondrocyte implantation with osteochondral grafting for treatment of a massive osteochondral defect in the bilateral knees of a child," *Medicina*, vol. 47, no. 3, pp. 23–23, 2011.
- [15] Y. Hashimoto, G. Yoshida, T. Tomihara et al., "Bilateral osteochondritis dissecans of the lateral femoral condyle following bilateral total removal of lateral discoid meniscus: a case report," *Archives of Orthopaedic and Trauma Surgery*, vol. 128, no. 11, pp. 1265–1268, 2008.
- [16] H. Matsumoto, Y. Suda, T. Otani, and Y. Niki, "Meniscopectomy for osteochondritis dissecans of bilateral lateral femoral condyle combined with discoid meniscus: case report," *The Journal of Trauma: Injury, Infection, and Critical Care*, vol. 49, no. 5, pp. 964–966, 2000.
- [17] R. Kanto, H. Nakayama, T. Iseki, and S. Yoshiya, "Juvenile osteochondritis dissecans in the lateral femoral condyle requiring osteochondral autograft as a revision procedure: a case report," *Journal of Medical Case Reports*, vol. 10, no. 1, 2016.
- [18] C. A. Arnold, D. J. Thomas, and J. O. Sanders, "Bilateral knee and bilateral elbow osteochondritis dissecans," *American Journal of Orthopedics (Belle Mead, N.J.)*, vol. 32, no. 5, pp. 237–240, 2003.
- [19] S. J. Mubarak and N. C. Carroll, "Familial osteochondritis dissecans of the knee," *Clinical Orthopaedics and Related Research*, vol. 140, pp. 131–136, 1979.
- [20] J.-H. Jeong, R. Mascarenhas, and H. S. Yoon, "Bilateral osteochondritis dissecans of the femoral condyles in both knees : a report of two sibling cases," *Knee Surgery & Related Research*, vol. 25, no. 2, pp. 88–92, 2013.
- [21] J. Gorter and J. J. A. M. van Raay, "A suspected genetic form of bilateral osteochondritis dissecans of the knee in a Dutch family," *The Knee*, vol. 22, no. 6, pp. 677–682, 2015.
- [22] Y. Takahashi, K. Nawata, H. Hashiguchi, K. Kawaguchi, D. Yamasaki, and H. Tanaka, "Bilateral osteochondritis dissecans of the lateral trochlea of the femur: a case report," *Archives of Orthopaedic and Trauma Surgery*, vol. 128, no. 5, pp. 469–472, 2008.
- [23] N. H. Park, H. S. Kim, S. Y. Yi, and B. C. Min, "Multiple osteochondritis dissecans of knee joint in a patient with Wilson disease, focusing on magnetic resonance findings," *Knee Surgery & Related Research*, vol. 25, no. 4, pp. 225–229, 2013.
- [24] J. J. Aird, R. Cove, C. J. P. McAllen, and P. Hughes, "Large osteochondral fracture in a patient with bilateral bicondylar osteochondritis dissecans and spondyloepiphyseal dysplasia tarda," *European Journal of Trauma and Emergency Surgery*, vol. 36, no. 2, pp. 183–185, 2010.
- [25] P. A. Bednarz, G. A. Paletta, and C. L. Stanitski, "Bilateral osteochondritis dissecans of the knee and elbow," *Orthopedics*, vol. 21, no. 6, pp. 716–719, 1998.
- [26] P. Aichroth, "Osteochondritis dissecans of the knee. A clinical survey," *Journal of Bone and Joint Surgery. British Volume (London)*, vol. 53, no. 3, pp. 440–447, 1971.
- [27] J. STOUGAARD, "FAMILIAL OCCURRENCE OF OSTEOCHONDROITIS DISSECANS," *Journal of Bone and Joint Surgery*, vol. 46, pp. 542–543, 1964.
- [28] J. White, "Osteochondritis dissecans in association with dwarfism," *Journal of Bone and Joint Surgery. British Volume (London)*, vol. 39-B, no. 2, pp. 261–267, 1957.
- [29] E. L. Stattin, Y. Tegner, M. Domellöf, and N. Dahl, "Familial osteochondritis dissecans associated with early osteoarthritis and disproportionate short stature," *Osteoarthritis and Cartilage*, vol. 16, no. 8, pp. 890–896, 2008.
- [30] M. Mesgarzadeh, A. A. Sapega, A. Bonakdarpour et al., "Osteochondritis dissecans: analysis of mechanical stability with radiography, scintigraphy, and MR imaging," *Radiology*, vol. 165, no. 3, pp. 775–780, 1987.
- [31] S. A. Hanna, W. J. S. Aston, P. D. Gikas, and T. W. R. Briggs, "Bicondylar osteochondritis dissecans in the knee: a report of two cases," *The Journal of Bone and Joint Surgery. British Volume*, vol. 90, no. 2, pp. 232–235, 2008.