


Immune thrombocytopenic purpura secondary to SARS-CoV-2 infection in a child with acute lymphoblastic leukaemia: a case report and review of literature

Amol Dongre,¹ Patel Zeeshan Jameel ,² Mahesh Deshmukh,³ Shweta Bhandarkar⁴

¹Department of Medical Oncology, Alexis Multispeciality Hospital, Nagpur, Maharashtra, India

²Department of Paediatrics, Jawaharlal Nehru Medical College, Wardha, Maharashtra, India

³Department of Pathology, Alexis Multispeciality Hospital, Nagpur, Maharashtra, India

⁴Department of Paediatrics and Neonatology, Alexis Multispeciality Hospital, Nagpur, Maharashtra, India

Correspondence to

Dr Patel Zeeshan Jameel;
zeeshan1311@gmail.com

Accepted 15 October 2021

SUMMARY

Immune thrombocytopenic purpura (ITP) is characterised by isolated thrombocytopenia which may be idiopathic or due to a secondary aetiology. ITP is being increasingly recognised secondary to SARS-CoV-2 infection in the current pandemic. Here, we report a case of a five-and-a-half-year-old female child on maintenance chemotherapy for acute lymphoblastic leukaemia who subsequently developed ITP secondary to SARS-CoV-2 infection. Our patient had prolonged thrombocytopenia secondary to ITP, requiring the use of second-line agents including romiplostim and eltrombopag. This is a unique case where ITP was recognised secondary to SARS-CoV-2. In such cases of thrombocytopenia, ITP should be considered as an important differential in addition to relapse of leukaemia or thrombocytopenia due to chemotherapy drugs.

BACKGROUND

Immune thrombocytopenic purpura (ITP) is an acquired disease, either transient or permanent, where there is immune-mediated destruction of platelets.¹ The risk of major bleeding episode depends on the severity of thrombocytopenia. The estimated incidence rate of ITP in children is 1.1–5.8 per 100 000 person-years, with a higher incidence observed in the 2–5 year age group.^{2,3} ITP can be either primary or secondary to infection, autoimmune diseases or malignancies such as chronic lymphocytic leukaemia (CLL), non-Hodgkin's lymphoma, Hodgkin's lymphoma and large granulocytic leukaemia.^{3,4} Association of ITP with acute lymphoblastic leukaemia (ALL) has been rare and has been infrequently reported in the literature.

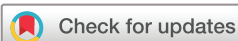Here, we report a case of a girl with ITP secondary to SARS-CoV 2 during ongoing maintenance therapy for ALL.

CASE PRESENTATION

A five-and-a-half-year-old girl was brought with complaints of reddish-purple spots on neck, shoulder, arms and legs. She was a known case of B-cell ALL, diagnosed 18 weeks ago and was started on MCP 841 protocol. She had completed 4 weeks of induction phase with vincristine (1.5 mg/m²; once weekly), L-asparaginase (10 000 IU/m²), oral prednisolone (60 mg/m²/day) and intrathecal methotrexate (6 mg; once weekly). After achieving complete remission, she

was started on consolidation phase for 4 weeks with vincristine (1.5 mg/m²), 6-mercaptopurine (75 mg/m²/day) and intrathecal methotrexate (6 mg; once weekly). After the consolidation phase, she was started on maintenance therapy. Five days into her maintenance therapy, she started to develop high-grade fever with cold and coryza. RT-PCR of the oropharyngeal swab was positive for SARS-CoV-2. In view of this, her chemotherapy was immediately withheld and she was managed symptomatically. Her symptoms subsided over the next 5 days. Routine blood examination was within normal limits at the time. She was planned to be restarted on maintenance chemotherapy after 14 days of recovery from COVID-19. After the initiation of maintenance phase with intrathecal methotrexate and oral 6-mercaptopurine, she was discharged home to review after 2 weeks for complete blood count. However, on the 22nd day of recovery from SARS-CoV-2, she presented with reddish-purple spots on neck, shoulder, arms and legs.

On examination, she was alert and playful. Her vitals were stable. Several pinpoint and round to oval (>1 cm) reddish-purple spots were seen on the skin over neck, shoulder, arms and legs. These lesions were not raised and non-blanching suggestive of petechiae and purpura (figure 1). There were no other bleeding manifestations. The rest of the systemic examination was normal. Routine blood examination showed a normal haemoglobin level (119 g/L), normal white cell count (5.85 × 10⁹/L) but severe thrombocytopenia (3000/mm³). Peripheral smear showed normal morphology of red blood cells, leucocytes but significantly reduced platelets. No blast cells or atypical cells were seen. Liver and kidney function tests were within normal limits. Coagulation profile (prothrombin time (PT), activated partial thromboplastin time (aPTT) and international normalised ratio (INR)) was normal. Fibrinogen level was slightly elevated (411 mg/dL; range 162–401 mg/dL) but serum triglyceride (55 mg/dL) and serum ferritin (350 ng/mL) were within normal limits. Pro-calcitonin levels were also within normal limits. She was given platelet transfusion as the platelet counts were <10 000/mm³ with active bleeding in the form of cutaneous bleed. Differential diagnoses considered were relapse of ALL and ITP secondary to SARS-CoV-2. In order to differentiate between the two, bone marrow aspiration cytology done showed normocellular bone marrow with increased megakaryopoiesis with no blast cells (figure 2). She was further investigated to determine



© BMJ Publishing Group Limited 2021. No commercial re-use. See rights and permissions. Published by BMJ.

To cite: Dongre A, Jameel PZ, Deshmukh M, et al. *BMJ Case Rep* 2021;**14**:e245869. doi:10.1136/bcr-2021-245869

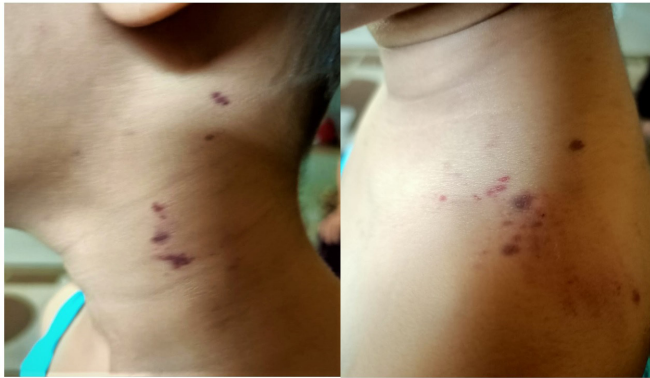

Figure 1 Clinical image showing petechiae, purpura on the left side of the neck and over the left shoulder.

aetiology. Antinuclear antibody (ANA) levels, thyroid function tests done were within normal limits. Anti-HCV-Ab to hepatitis C virus was non-reactive. Direct Coombs' test was negative. Immunoglobulin profile also showed total IgA, IgM, IgE and IgG were within normal limits. With a history of SARS-CoV-2, it was established that she was suffering from ITP secondary to SARS-CoV-2. Intravenous immunoglobulin (IVIg) was administered at 1 g/kg of body weight of the child. She was also started on oral prednisolone (2 mg/kg/day) which was later increased to 4 mg/kg/day. However, there was no response as the platelet count remained below $<10\,000/\text{mm}^3$ with new petechiae appearing along with oral mucosal bleed. She, again, underwent platelet transfusion. In addition, to ongoing steroid, she was started on thrombopoietin (TPO) receptor agonist. A single dose of inj. romiplostim was given once (1 $\mu\text{g}/\text{kg}$) and tab. eltrombopag (25 mg/day) was also started. Two weeks after initiation of TPO receptor agonist, her platelet counts had improved to $24\,000/\text{mm}^3$. On subsequent blood investigations, here platelets had further increased to $157\,000/\text{mm}^3$. After 4 weeks of hospital stay, she was discharged home on prednisolone (tapering dose) and eltrombopag.

OUTCOME AND FOLLOW-UP

On follow-up 2 weeks after discharge, eltrombopag was stopped and prednisolone was further tapered and stopped after 1 more week. She was well with normal blood counts. She was restarted on her maintenance chemotherapy (6-mercaptopurine

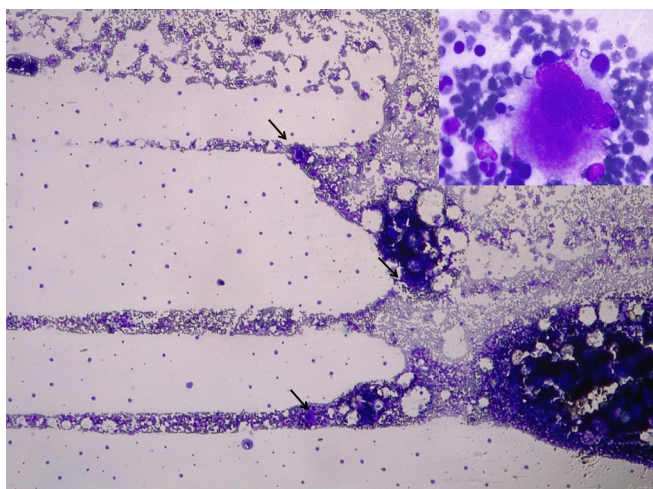


Figure 2 Bone marrow aspiration showing normocellular bone marrow with increased number of megakaryocytes (black arrow) and absence of blast cells. Inset: Megakaryocyte ($\times 100$).

and intrathecal methotrexate) for B-cell ALL after steroids were stopped.

DISCUSSION

ITP is characterised by isolated thrombocytopenia ($<100 \times 10^9/\text{L}$) in the absence of other aetiologies.¹ Even though the exact pathogenesis is yet to be clearly understood, possible mechanisms suggested are antiplatelet autoantibodies against platelet glycoproteins (such as IIb/IIIa, Ib/IX), impaired platelet production due to megakaryocyte apoptosis and cytotoxic T-lymphocyte-mediated platelet destruction.^{3 5}

While only 20% cases of ITP are secondary, a major 80% are primary or idiopathic.³ Secondary ITP has been associated with infections (HIV, hepatitis B, hepatitis C, cytomegalovirus (CMV), varicella zoster virus (VZV), zika, *Helicobacter pylori*), systemic autoimmune disorders (systemic lupus erythematosus, anti-phospholipid antibody syndrome), primary immunodeficiency disorders like common variable immunodeficiency (CVID) and malignancies. Haematological malignancies have been known to be associated with ITP. CLL, Hodgkin's lymphoma and non-Hodgkin's lymphoma are known to be associated with ITP.^{6 7} Very few cases of ITP occurring in children subsequent to a diagnosis of ALL have been reported.⁸⁻¹⁵ Skin or mucosal bleeding is the most common manifestation with up to two-thirds of patients. The risk of bleeding is highest when the platelet count goes down below $30\,000/\mu\text{L}$.³ Major bleeding manifestations in the form of intracranial haemorrhage, gastrointestinal haemorrhage or genitourinary bleeding are uncommon. Even though platelet count is not a universally reliable marker for bleeding risk, but platelet count less than $10\,000/\mu\text{L}$ has been identified as a major predisposing risk factor.¹⁶⁻¹⁹ Furthermore, immature platelet fraction $<10\%$ was additionally identified as an independent predictor of bleeding at platelet counts below $10\,000/\mu\text{L}$.²⁰

Thrombocytopenia has been variably reported in patients with mild to severe COVID-19. SARS-CoV-2 is being increasingly recognised as a possible aetiology for ITP.²¹ In addition, Chen *et al*²² reported a delayed phase thrombocytopenia (>14 days post-COVID-19 symptoms appearance) possibly due to immune-mediated destruction. The mean time for appearance of delayed phase thrombocytopenia was 28.3 days and lasting for less than 7 days (mean duration 4.32 ± 2.15 days). In a systematic review by Bhattacharjee *et al*,²¹ the duration from initial COVID-19 symptom to first ITP manifestation ranged from 2 to 30 days (median 14 days) when a total of 45 cases of ITP due to SARS-CoV-2 were reviewed. In our case, the child presented with clinical symptoms of ITP 3 weeks after recovering from COVID-19 similar to that reported across literature. Such post-acute COVID-19 sequelae are being increasingly recognised and have been classified as subacute or ongoing symptomatic COVID-19 (4-12 weeks after onset of acute COVID-19) and chronic or post-COVID-19 syndrome (>12 weeks after onset of acute COVID-19).²³

Thrombocytopenia is a frequent finding at presentation in children with acute leukaemia (myelocytic or lymphocytic). Bleeding manifestations such as mucosal bleeds, petechiae, easy bruisability can be the initial symptoms leading to the diagnosis of acute leukaemia. Common factors responsible for thrombocytopenia in leukaemia include sepsis, disseminated intravascular coagulation, hypersplenism, chemotherapeutic drugs, radiotherapy, graft versus host disease, liver dysfunction and rarely, immune-mediated destruction. In addition, recent studies have shown that mutations in certain genes responsible for cancer also

Table 1 A summary of the reported cases of ITP developing in patients diagnosed with ALL

Author	Age at diagnosis/sex	Type of ALL	Treatment regimen; phase of treatment	Chemotherapy drugs administered in the prior chemo cycle	Treatment modality used for ITP	Duration of ITP	Aetiology of ITP
Rao <i>et al</i> ¹⁵	8 years/ female	ALL	NM; maintenance therapy	Cyclophosphamide	Prednisolone	NM	Primary ITP
Campbell <i>et al</i> ¹⁰	18 years/female	Pre B-cell ALL (L2)	NM; post-induction period	Vincristine, daunorubicin, prednisolone and L-asparaginase	IVIg (400 mg/kg/day)×3 days given twice, danazol (200 mg/day) prednisolone (60 mg/day)	10 weeks	Primary ITP and associated HLH
Yenicesu <i>et al</i> ⁹	5 years/male	ALL	Saint-Jude total XIII protocol; maintenance therapy	NM	IVIg therapy (1 g/kg/day)×2 days	1 week	Primary ITP (antiplatelet antibody positive)
Price <i>et al</i> ¹⁴	2.6 years/female	ALL	BFM-based high-risk protocol; post-completion of chemotherapy	Vincristine, L-asparaginase, prednisone, dexamethasone, daunomycin, adriamycin, cyclophosphamide, methotrexate, cytarabine, 6-mercaptopurine, 6-thioguanine and intrathecal methotrexate	IVIg (2 g/kg/day)	NM	Primary ITP
	1.8 years/male	ALL	BFM-based high-risk protocol; post-completion of chemotherapy	Vincristine, L-asparaginase, prednisone, dexamethasone, daunomycin, adriamycin, cyclophosphamide, cytarabine, 6-mercaptopurine, 6-thioguanine	IVIg, prednisolone. Finally underwent splenectomy.	1 month	Primary ITP
	10.5 years/female	ALL	BFM-based high-risk protocol; post-completion of chemotherapy	Vincristine, L-asparaginase, prednisone, dexamethasone, daunomycin, adriamycin, cyclophosphamide, methotrexate, cytarabine, 6-mercaptopurine, 6-thioguanine and intrathecal methotrexate	No treatment	NM	Primary ITP (antiplatelet antibody positive)
Kurekci <i>et al</i> ¹³	5 years/male	Pre B- cell ALL	BFM-95 regimen; maintenance therapy	6-Mercaptopurine, methotrexate	IVIg (1 g/kg/day)×2 days, prednisolone (2 mg/kg/day)×3 weeks, vincristine (1.5 mg/m ² , 2 doses, 1 week apart) plus dexamethasone (6 mg/m ² /day, for 7 days)	14 weeks	Secondary ITP (mumps)
Horino <i>et al</i> ¹²	7 years/female	Pre B- cell ALL	Protocol of Japan Association of Childhood Leukaemia Study (JACLS); post-completion of reinduction therapy	L-asparaginase, prednisone, vincristine, cyclophosphamide and THP-adriamycin	IVIg (1 g/kg/day) with intermittent IVIg and prednisolone when undergoing chemo cycles. Later on, rituximab and anti-D immunoglobulin were also given. Finally underwent splenectomy.	14 months	Primary ITP (gp IIb/IIIa antibody positive)
Dua <i>et al</i> ¹¹	15 years/female	Pre B- cell ALL	BFM-95 regimen; maintenance therapy	6-Mercaptopurine, methotrexate	Prednisolone (2 mg/kg/day)×3 weeks followed by tapering	3 weeks	Primary ITP
Yadav <i>et al</i> ²⁵	3 year/male	ALL	NM	NM	Rituximab (375 mg/m ² /week)×4 weeks	NM	Primary ITP
Bayhan <i>et al</i> ⁸	3 years/female	Pre-B-cell ALL	Modified St. Jude Total XV protocol; maintenance therapy	6-Mercaptopurine, methotrexate, pulses of dexamethasone and vincristine	IVIg (1 g/kg/day)	3 weeks	Primary ITP

Continued

Table 1 Continued

Author	Age at diagnosis/sex	Type of ALL	Treatment regimen; phase of treatment	Chemotherapy drugs administered in the prior chemo cycle	Treatment modality used for ITP	Duration of ITP	Aetiology of ITP
Present case	5.5 years/female	Pre B-cell ALL	MCP 841 protocol; maintenance therapy	6-Mercaptopurine, methotrexate	IVIg 1 g/kg/day)×2 courses, prednisolone (2 mg/kg/day), romiplostim (1 mcg/kg)× single dose and eltrombopag (25 mg/day)	5 weeks	Secondary ITP (SARS-CoV-2)

ALL, acute lymphoblastic leukaemia; BFM, Berlin-Frankfurt-Munich protocol; HLH, Hemophagocytic lymphohistiocytosis; ITP, immune thrombocytopenic purpura; IVIg, intravenous immunoglobulin; NM, Not Mentioned

leads to thrombocytopenia and/or platelet function abnormalities. Germline variants in the *ETV6* gene have been identified to cause haematological malignancies, most commonly B-cell ALL, along with thrombocytopenia.²⁴ Analysing thrombocytopenia in a child with leukaemia on chemotherapy has its own diagnostic dilemmas. In a majority of cases, it occurs due to the effect of chemotherapy or relapse of leukaemia. Rarely, it may occur due to the development of ITP. Among the previously reported cases, ITP was diagnosed in five patients who were on maintenance therapy, in three patients after completion of chemotherapy and in one patient each after the induction and reinduction phase (table 1).^{8–15 25} Our patient also developed ITP during the maintenance phase of chemotherapy as observed in majority of previously reported cases. In contrast to all the cases reported except one, no prior history of any form of viral infection was present. In the case reported by Kurekci *et al*,¹³ ITP was identified to be secondary to mumps while in our patient it was secondary to SARS-CoV-2. In three cases, antibodies were identified against platelet antigens.^{9 12 14} In all the cases reported, almost all responded to traditional immunomodulatory therapies recognised in treating ITP. In contrast, our case was refractory to IVIg, steroids requiring use of thrombopoietin receptor agonists (romiplostim, eltrombopag).

In the present case, a prior history of viral infection was present and confirmed with RT-PCR. However, the primary illness, that is, leukaemia, of the child had created a diagnostic dilemma of either relapse or adverse effect of a chemotherapy drug. A strong suspicion of ITP prompted the use of IVIg and prednisolone as the bone marrow examination was normal. Despite this, the child did not respond with platelet count being severely low (<10 000/μL) prompting the use of thrombopoietin receptor agonists. Both romiplostim and eltrombopag are indicated in cases of ITP refractory to first-line agents.^{26 27} In the present case, the child was refractory to first-line treatment modalities, hence, romiplostim and eltrombopag were used as her platelet counts were persistently less than 10 000/μL. After 3–4 weeks, she showed a complete recovery which allowed us to resume her maintenance therapy for ALL.

In conclusion, this case describes a case of ITP secondary to SARS-CoV-2, adding to the varied disease manifestation of the

ongoing COVID-19 pandemic. In addition to the possibility of relapse of ALL or chemotherapy drug-induced thrombocytopenia, ITP should always be given a careful consideration in cases such as ours. A prompt diagnosis and effective management were extremely crucial in the survival of our patient.

Contributors AD and PJZ drafted the initial manuscript, performed the relevant literature search, critical review and revision of the manuscript. MD was involved in data collection and revision of the manuscript. SB was involved in drafting the initial manuscript, supervised data collection, critical review and revision of the manuscript. All the authors approve the manuscript as submitted and agree to be accountable for all the aspects of the work.

Funding The authors have not declared a specific grant for this research from any funding agency in the public, commercial or not-for-profit sectors.

Competing interests None declared.

Patient consent for publication Consent obtained from parent(s)/guardian(s).

Provenance and peer review Not commissioned; externally peer reviewed.

This article is made freely available for use in accordance with BMJ's website terms and conditions for the duration of the covid-19 pandemic or until otherwise determined by BMJ. You may use, download and print the article for any lawful, non-commercial purpose (including text and data mining) provided that all copyright notices and trade marks are retained.

ORCID iD

Patel Zeeshan Jameel <http://orcid.org/0000-0002-8040-4835>

REFERENCES

- Rodeghiero F, Stasi R, Gernsheimer T, *et al*. Standardization of terminology, definitions and outcome criteria in immune thrombocytopenic purpura of adults and children: report from an international Working group. *Blood* 2009;113:2386–93.
- Yong M, Schoonen WM, Li L, *et al*. Epidemiology of paediatric immune thrombocytopenia in the general practice research database. *Br J Haematol* 2010;149:855–64.
- Kohli R, Chaturvedi S. Epidemiology and clinical manifestations of immune thrombocytopenia. *Hamostaseologie* 2019;39:238–49.
- Kistangari G, McCrae KR. Immune thrombocytopenia. *Hematol Oncol Clin North Am* 2013;27:495–520.
- Olsson B, Andersson P-O, Jernäs M, *et al*. T-cell-mediated cytotoxicity toward platelets in chronic idiopathic thrombocytopenic purpura. *Nat Med* 2003;9:1123–4.
- De Back TR, Kater AP, Tonino SH. Autoimmune cytopenias in chronic lymphocytic leukemia: a Concise review and treatment recommendations. *Expert Rev Hematol* 2018;11:613–24.
- Tanous O, Dujovny T, Hertzog G, *et al*. Immune thrombocytopenia secondary to Hodgkin's lymphoma in children. *Isr Med Assoc J* 2020;22:224–6.
- Bayhan T, Ünal Şule, Gümrük F, *et al*. Immune thrombocytopenic purpura during maintenance phase of acute lymphoblastic leukemia: a rare coexistence requiring a high degree of suspicion, a case report and review of the literature. *Turk J Haematol* 2015;32:363–6.
- Yenicesu I, Sanli C, Gürgöy A. Idiopathic thrombocytopenic purpura in acute lymphocytic leukemia. *Pediatr Hematol Oncol* 2000;17:719–20.
- Campbell JK, Mitchell CA. Immune thrombocytopenia in association with acute lymphoblastic leukaemia and a haemophagocytic syndrome. *Eur J Haematol* 1993;51:259–61.
- Dua V, Sharma JB. Immune thrombocytopenic purpura with acute lymphoblastic leukemia an unusual association. *Indian Pediatr* 2012;49:994.

Learning points

- ▶ Immune thrombocytopenic purpura (ITP) is being increasingly recognised secondary to SARS-CoV-2.
- ▶ In such cases of thrombocytopenia, ITP should be considered as an important differential in addition to relapse of leukaemia or thrombocytopenia due to chemotherapy drugs.

- 12 Horino S, Rikiishi T, Niizuma H, *et al.* Refractory chronic immune thrombocytopenic purpura in a child with acute lymphoblastic leukemia. *Int J Hematol* 2009;90:483–5.
- 13 Kurekci AE, Atay AA, Demirkaya E, *et al.* Immune thrombocytopenic purpura in a child with acute lymphoblastic leukemia and mumps. *J Pediatr Hematol Oncol* 2006;28:170–2.
- 14 Price V, Barnes C, Canning P, *et al.* Immune thrombocytopenia following successful treatment of cancer in children. *Pediatr Blood Cancer* 2006;46:372–6.
- 15 Rao S, Pang EJ. Idiopathic thrombocytopenic purpura in acute lymphoblastic leukemia. *J Pediatr* 1979;94:408–9.
- 16 Rosthøj S, Hedlund-Treutiger I, Rajantie J, *et al.* Duration and morbidity of newly diagnosed idiopathic thrombocytopenic purpura in children: a prospective Nordic study of an unselected cohort. *J Pediatr* 2003;143:302–7.
- 17 Neunert CE, Buchanan GR, Blanchette V, *et al.* Relationships among bleeding severity, health-related quality of life, and platelet count in children with immune thrombocytopenic purpura. *Pediatr Blood Cancer* 2009;53:652–4.
- 18 Tsuda H, Tsuji T, Tsuji M, *et al.* Life-threatening bleeding episodes in primary immune thrombocytopenia: a single-center retrospective study of 169 inpatients. *Ann Hematol* 2017;96:1915–20.
- 19 Psaila B, Petrovic A, Page LK, *et al.* Intracranial hemorrhage (ICH) in children with immune thrombocytopenia (ITP): study of 40 cases. *Blood* 2009;114:4777–83.
- 20 McDonnell A, Bride KL, Lim D, *et al.* Utility of the immature platelet fraction in pediatric immune thrombocytopenia: differentiating from bone marrow failure and predicting bleeding risk. *Pediatr Blood Cancer* 2018;65. doi:10.1002/psc.26812. [Epub ahead of print: 17 09 2017].
- 21 Bhattacharjee S, Banerjee M. Immune thrombocytopenia secondary to COVID-19: a systematic review. *SN Compr Clin Med* 2020:1–11.
- 22 Chen W, Li Z, Yang B, *et al.* Delayed-phase thrombocytopenia in patients with coronavirus disease 2019 (COVID-19). *Br J Haematol* 2020;190:179–84.
- 23 Nalbandian A, Sehgal K, Gupta A, *et al.* Post-acute COVID-19 syndrome. *Nat Med* 2021;27:601–15.
- 24 Di Paola J, Porter CC. ETV6-related thrombocytopenia and leukemia predisposition. *Blood* 2019;134:663–7.
- 25 Yadav SP, Chinnabhandar V. Rituximab usage in children: a double edged sword. *Indian Pediatr* 2012;49:335–6 <https://www.indianpediatrics.net/apr2012/apr-335-336.htm>
- 26 Kim TO, Despotovic J, Lambert MP. Eltrombopag for use in children with immune thrombocytopenia. *Blood Adv* 2018;2:454–61.
- 27 Neunert CE, Rose MJ. Romiplostim for the management of pediatric immune thrombocytopenia: drug development and current practice. *Blood Adv* 2019;3:1907–15.

Copyright 2021 BMJ Publishing Group. All rights reserved. For permission to reuse any of this content visit <https://www.bmj.com/company/products-services/rights-and-licensing/permissions/>
BMJ Case Report Fellows may re-use this article for personal use and teaching without any further permission.

Become a Fellow of BMJ Case Reports today and you can:

- ▶ Submit as many cases as you like
- ▶ Enjoy fast sympathetic peer review and rapid publication of accepted articles
- ▶ Access all the published articles
- ▶ Re-use any of the published material for personal use and teaching without further permission

Customer Service

If you have any further queries about your subscription, please contact our customer services team on +44 (0) 207111 1105 or via email at support@bmj.com.

Visit casereports.bmj.com for more articles like this and to become a Fellow