

# An Unexpected Complication of Residual Fibular Strut Graft While Performing A Press fit Hemiarthroplasty for A Secondary Nonunion Fracture Neck of the Femur

Najmul Huda<sup>1</sup>, Julfiqar<sup>1</sup>, Ajay Pant<sup>1</sup>, M Aslam<sup>1</sup>

## What to Learn from this Article?

Utmost care should be taken to completely remove the residual fibular strut graft while performing hemireplacement arthroplasty in patients who have previously undergone fibular strut grafting for femoral neck fracture.

## Abstract

**Introduction:** Perioperative complications are well known during partial and total hip arthroplasty. One of the common categories of these complications is an intraoperative fractures of the proximal femur. Here we discuss a case of perforation of posteromedial cortex of the proximal femur, while doing a press fit modular bipolar hemiarthroplasty, in a young adult with secondary nonunion of the femoral neck fracture. The cause of this proximal femur perforation was residual fibular strut graft that, redirected the femoral stem into undesirable direction. This complication of residual fibular strut graft has not been discussed much in the orthopedic literature previously.

**Case Report:** A press fit modular bipolar hip arthroplasty was performed in a young adult male with nonunion fracture neck of the femur secondary to initial fixation using 6.5mm cannulated hip screws and nonvascularized free fibular strut grafting. Failure to completely remove the fibular strut from the proximal femur lead to difficult negotiation of the femoral stem into the femoral canal and ultimately a perforation in the proximal femur at the level of the lesser trochanter. A revision procedure was done to completely remove the residual fibular graft, and then a fresh press fit modular bipolar hemiarthroplasty was done.

**Conclusion:** Complete removal of fibular strut graft should be done, while performing hip arthroplasty in patients with failed fibular grafting for fracture neck of the femur.

**Keywords:** Nonunion fracture neck of femur, hemiarthroplasty, press fit, proximal femoral fracture

## Introduction

Intraoperative femoral fractures are well known during partial or total hip arthroplasty. The incidence of intraoperative femur fractures during total hip arthroplasty varies from 0.3% to 20.9%, depending upon primary or revision arthroplasty, cemented or cementless arthroplasty, quality of bone, including other factors [1,2].

Unlike in total hip arthroplasty the incidence of intraoperative

femur fractures during hemiarthroplasty has not been studied much. During hemiarthroplasty the incidence of intraoperative femur fractures can be 1.3%-6.8% and, the common causes of these fractures include osteoporosis, iatrogenic (neck osteotomy, reaming, prosthesis introduction, reduction), congenital alteration of bony anatomy, and inadequate soft tissue release prior to hip dislocation during revision of hip surgery [3,4]. Press fit/cementless arthroplasty with the aim to occupy a larger area in the femoral

Access this article online

Website:  
www.jocr.co.in

DOI:  
2250-0685.305

## Author's Photo Gallery



Dr. Najmul Huda



Dr. Julfiqar



Dr. Ajay Pant



Dr. M Aslam

<sup>1</sup>Department of Orthopedics, Teerthanker Mahaveer Medical College and Research Centre (TMMC&RC), TMU, Moradabad, U.P. India

### Address of Correspondence

Dr. Julfiqar

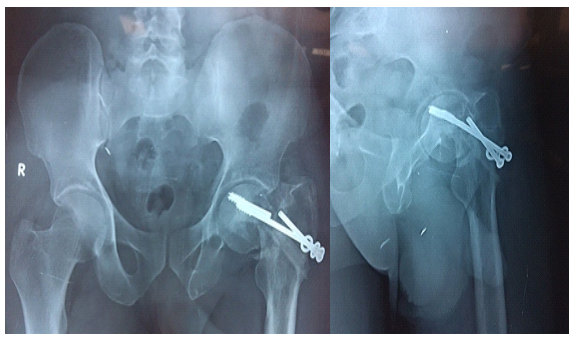
Department of orthopedics, Teerthanker Mahaveer Medical College and Research Centre (TMMC&RC), TMU, NH-24, Near Pakwara, Dist. Moradabad, U.P. India.

E mail – drzulfiqar1983@rediffmail.com

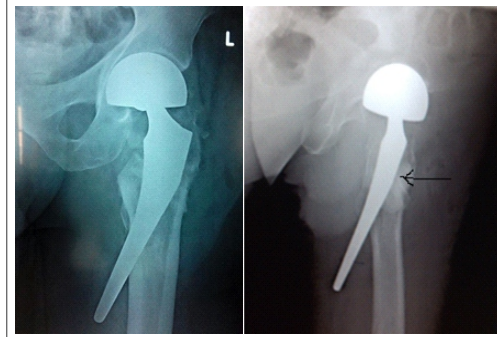
Copyright © 2015 by Journal of Orthopaedic Case Reports

Journal of Orthopaedic Case Reports | pISSN 2250-0685 | eISSN 2321-3817 | Available on www.jocr.co.in | doi:10.13107/jocr.2250-0685.305

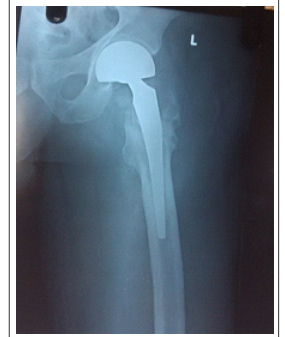This is an Open Access article distributed under the terms of the Creative Commons Attribution Non-Commercial License (<http://creativecommons.org/licenses/by-nc/3.0>) which permits unrestricted non-commercial use, distribution, and reproduction in any medium, provided the original work is properly cited.



**Figure 1:** Radiograph of pelvis including both hips AP view and Lateral view of left showing secondary nonunion of fracture neck of the femur six months after the initial fixation.



**Figure 2:** The residual fibular strut graft highlighted by thin black arrow that redirected the tip of the femoral stem leading to perforation of posteromedial cortex of proximal hip.



**Figure 3:** The final radiograph of the same patient after revision surgery.

canal has lead to an increased incidence as well as new patterns of periprosthetic femur fractures. These fractures can be adequately managed without significantly increasing the patient morbidity, mortality and revision surgery [4].

### Case report

We had a 38 year male patient , shopkeeper by occupation, who presented to us with secondary nonunion of femoral neck fracture six months after the index procedure. An attempt at osteosynthesis was done earlier for his left hip femoral neck fracture by fixation using two 6.5mm cannulated hip screws and supplementary single free fibular strut graft. After his initial surgical fixation six months earlier he was advised for bed rest for six weeks, but he started premature full weight bearing and also sustained mild trauma to his left hip, when he slipped on the floor one month after the index surgery. Following injury he was unable to stand up and bear weight on his left lower limb.

On clinical examination patient was unable to bear weight and walk on the left lower limb, his left lower limb was shortened and externally rotated at hip. Active straight leg raising test was not possible on left side. There was tenderness over left hip joint, his left greater trochanter was smooth on palpation and proximally migrated. Movements of the left hip were painfully restricted. Head of the screws were palpable through the laterally placed surgical scar mark over the left proximal thigh.

At the time of presentation to us his radiograph of pelvis including both hips and lateral view of involved left hip showed a nonunion fracture neck of the femur with varus collapse, with broken hip screws, tip of broken screw reaching almost up to the articular surface of the femoral head, back out of the remaining hip screws and graft fracture [Fig.1].

Based on the clinico-radiological examination we planned for an uncemented modular bipolar prosthesis. His left hip joint was opened by a posterior skin incision, all the hardware was removed, and the fibular strut graft that was visible to the necked eye was also removed from the femoral side. The acetabular cartilage was completely intact. Femoral canal was prepared for uncemented modular bipolar prosthesis, and an uncemented modular bipolar prosthesis was inserted into the prepared femoral canal. There was no audible bony crepitus or abnormal mobility in the femur while introducing the prosthesis into the femoral canal. Subsequently the head of prosthesis was reduced

into the acetabular socket and the stability of the hip joint was checked. The hip joint was not stable and was dislocatable with mild adduction and at 90 degree hip flexion. An urgent x-ray of the left hip (AP and lateral views) was done using the portable x-ray machine. These x-rays [Fig.2] showed perforation of the posteromedial cortex of the proximal femur at the level of lesser trochanter. These x-rays also showed a residual fibular strut graft over the postero lateral cortex of the trochanter flare protruding into the femoral canal. This residual fibular strut graft resisted the smooth passage of the femoral stem along the lateral wall of the proximal femur and redirected the femoral stem into an undesirable direction ultimately leading to perforation of the posteromedial cortex of the proximal femur at the level of lesser trochanter. As we removed the prosthesis we found a perforation hole on the posteromedial femoral cortex at the level of lesser trochanter, however there was no complete fracture. The culprit residual fibular graft was removed with the help of narrow curved osteotome and bone nibblers. And it was flushed with lateral femoral wall. A new modular bipolar prosthesis of the same size was introduced, and joint was reduced, the hip stability was checked again, and it was found satisfactory. The perforation in the postero-medial cortex was sealed with cancellous iliac crest bone graft. A check radiograph was done again and was found satisfactory [Fig.3].

### Discussion

Intraoperative femoral fractures during hip arthroplasty are well known. These intraoperative femoral fractures during total hip arthroplasty are usually caused while preparing the femoral canal by reamers or rasps, while seating the femoral component or while manipulating the femur to reduce or dislocate the prosthesis into/from the acetabulum. Intraoperative unstable femoral fractures usually warrant detailed assessment of the extent and geometry of the fracture and its appropriate management and may also require a custom made implant with either a long neck or long femoral stem or a larger stem with distal fixation and restricted weight bearing [5,6]. A missed or poorly addressed intraoperative proximal femoral fracture can lead to painful nonunion or late loosening of the femoral component. Use of porous and press fit total hip prostheses has lead to new patterns of femoral fractures and these fracture patterns have been reported by Stuchin in approximately 20% of patients in his porous coated/press fit total

hip arthroplasty series, he classified these fracture patterns into five different categories[7]. He recommended the use of collared implants to prevent implant sinking. The intraoperative femoral fractures during cementless total hip arthroplasties not necessarily compromise the initial implant stability and the ultimate functional outcomes are comparable to those patients without any intraoperative femoral fractures, provided the fracture has been adequately managed by the operating surgeon[8]. Unstable intraoperative femoral fractures are rare and are usually seen in dysplastic hips with narrow femoral canal. Stable fractures do not necessarily need an aggressive fracture management nor do they require prolonged bed rest[9]. Our case mentions an intraoperative perforation of the posteromedial femoral cortex at the level of lesser trochanter, caused due to redirection of the tip of femoral stem by the residual fibular strut graft and, it has been managed adequately in the light of above mentioned literature.

### Conclusion

Utmost care should be taken to remove the fibular strut graft, while performing hip arthroplasty, in such femoral neck fracture nonunion patients treated earlier with fibular strut grafting, where further attempts at osteosynthesis may not appear fruitful.

### Clinical Message

In patients with secondary nonunion of fracture neck of the femur, following failed primary fixation and fibular grafting, every effort should be made to remove the fibular graft from the proximal femoral canal. Failure to remove this graft may cause intraoperative femur fracture, during canal reaming or inserting the stem into the femoral canal.

### Reference

1. Darin Davidson, Jeffery Pike, Donald Gurbuz, Clive P Duncan, Bassam A Masri. Intraoperative periprosthetic fractures during total hip arthroplasty. *J Bone Joint Surg Am.* 2008;90:2000-2012.
2. Toni A, Ciaroni D, Sudanese A, Femino F, Marraro MD, Bueno Lozano AL, Giunti A. Incidence of intraoperative femoral fracture. Straight-stemmed versus anatomic cementless total hip arthroplasty. *Acta Orthop Belg.* 1994;60(1):43-54.
3. Liu Y, Lu S, Liu B. The reason and management of intraoperative femur fracture during hip arthroplasty. *Zhonghua Wai Ke Za Zhi.* 1998 Feb;36(2):93-5.
4. J. A. Fernández-Valencia, F. Llobet, N. Pons, I. López-Zabala, X. Gallart, G. Bori, J. Riba. Intraoperative Periprosthetic Femoral Fractures Related to Austin Moore Hemiarthroplasty—A Retrospective Review of 365 Patients. *Open Journal of Orthopedics*, 2013, 3, 189-192
5. Scott RD, Turner RH, Leitzes SM, Aufranc OE. Femoral fractures in conjunction with total hip replacement. *J Bone Joint Surg Am.* 1975 June;57(4):494-501.
6. Thillemann TM, Pedersen AB, Johnsen SP, Soballe K. Inferior outcomes after intraoperative femoral fractures in total hip arthroplasty: outcomes in 519 patients from the Danish hip arthroplasty registry. *Acta Orthop* 2008 Jun; 79(3):327-34.
7. Stuchin SA. Femoral shaft fracture in porous and press fit total hip arthroplasty. *Orthop Rev.* 1990 Feb; 19(2):153-9.
8. Sharkey PF, Hozak WJ, Booth RE Jr, Rothman RH. Intraoperative femoral fractures in cementless total hip arthroplasty. *Orthop Rev.* 1992 Mar, 21(3):337-42.
9. Dorman T, Sibinski M, Kmiec K, Bira M, Borowski A, Synder M. Cementless hip joint alloplasty complicated by intraoperative fracture of the femoral bone. *Ortop Traumatol Rehabil.* 2010 May-Jun;12(3):237-44.

**Conflict of Interest:** Nil  
**Source of Support:** None

### How to Cite this Article

Huda N, Julfiqar, Pant A, Aslam M. An Unexpected Complication of Residual Fibular Strut Graft While Performing A Press fit Hemiarthroplasty for A Secondary Nonunion Fracture Neck of the Femur. *Journal of Orthopaedic Case Reports* 2015 July - Sep;5(3): 45-47