

**Conclusion.** There is a clear negative linear correlation between pre-bone biopsy antibiotic exposure and culture positivity in patients diagnosed with osteomyelitis. In addition, elevated CRP and method of osteomyelitis diagnosis independently correlate with culture positivity.

**Disclosures.** All authors: No reported disclosures.

**292. Ceftolozane/Tazobactam for Treatment of Osteomyelitis due to Multi-Drug-Resistant *Pseudomonas aeruginosa***

Anthony Gerlach, PharmD, FCCM, FCCP<sup>1</sup> and Jose Bazan, D.O.<sup>2</sup>; <sup>1</sup>Pharmacy, The Ohio State University Wexner Medical Center, Columbus, Ohio, <sup>2</sup>The Ohio State University College of Medicine, Columbus, Ohio

**Session:** 54. Bone and Joint Infections

Thursday, October 4, 2018: 12:30 PM

**Background.** Ceftolozane/tazobactam (C/T) has potent activity against *Pseudomonas aeruginosa* (PA). Clinical data describing the use of C/T for PA osteomyelitis are limited. Our purpose is to describe clinical and microbiologic outcomes of adult patients treated with C/T for multidrug-resistant (MDR-PA) osteomyelitis.

**Methods.** This was a retrospective study of hospitalized patients who received C/T  $\geq 48$  hours for MDR-PA osteomyelitis between June 2015 and July 2017. MDR-PA was defined as resistance to  $\geq 1$  antibiotic from  $\geq 3$  antibiotic classes. Osteomyelitis was diagnosed by imaging, presence of systemic inflammatory signs and symptoms, elevated C-reactive protein, and positive culture for MDR-PA. Combination antibiotic therapy was defined as systemic antibiotics susceptible to MDR-PA for  $\geq 48$  hours with C/T. Clinical cure was defined as complete or partial resolution of signs and symptoms of infection without need for escalation of antimicrobials during inpatient and outpatient therapy. Microbiological success is defined as eradication of MDR-PA in follow-up bone cultures. Descriptive statistics were used and presented at percent or median [Interquartile range].

**Results.** Eighteen patients met inclusion and four patients were lost to follow-up. Demographics were male (81.2%), age 58.5 [53.5–68.5] years, 61.1% admitted to ICU, Charlson Comorbidity Index 5.5 [4–8] and APACHE II score 13.5 [11–21]. Site of osteomyelitis was pelvic in 55.6%, sacral in 22.2% and other sites in 22.2%. Surgical debridement occurred in 22.2%, and osteomyelitis was polymicrobial in 77.8%. Duration of hospitalization was 23.5 [12–37] days and all cause in-patient mortality was 16.7%. The median mean inhibitory concentration of C/T was 2 [2–4]  $\mu\text{g/mL}$ . Median total duration of C/T was 42 [27–42] days. Combination antibiotics were used in 27.8% (16.7% polymyxins, 11.1% aminoglycosides, 5.6% ciprofloxacin) and 2 patients on polymyxins developed renal insufficiency. No patient developed hypersensitivity, neurologic events or *C. difficile* infections. Overall, clinical cure was 64.3% and 4 patients had repeat cultures with 75% achieving a microbiologic cure.

**Conclusion.** These preliminary data suggest C/T maybe an option for treating patients with MDR-PA osteomyelitis, but more data are needed.

**Disclosures.** A. Gerlach, Merck: Grant Investigator, Grant recipient

**293. Concurrent Atlantoaxial Septic Arthritis and Septic Thrombosis of the Ophthalmic Vein due to *Staphylococcus aureus*: A Case Report and Review of the Literature**

Zeina Hajar, MD<sup>1</sup>; Neel Fotedar, MD<sup>2</sup> and Robin Jump, MD, PhD<sup>3</sup>; <sup>1</sup>Infectious Diseases, Case Western Reserve University- University Hospitals Cleveland Medical Center, Cleveland, Ohio, <sup>2</sup>Case Western Reserve University- University Hospitals Cleveland Medical Center, Cleveland, Ohio, <sup>3</sup>Case Western Reserve University School of Medicine, Cleveland, Ohio

**Session:** 54. Bone and Joint Infections

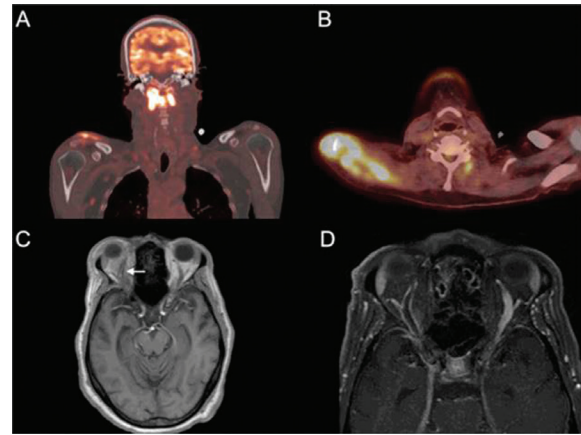
Thursday, October 4, 2018: 12:30 PM

**Background.** Atlantoaxial joint septic arthritis and superior ophthalmic vein thrombosis (SOVT) are uncommon sequelae of infections. Here, we describe a patient who presented concurrently with two uncommon manifestations of a common pathogen, methicillin-susceptible *Staphylococcus aureus* (MSSA), and review the associated literature. A 68-year-old man presented to the hospital with a 4-day history of worsening neck pain, right shoulder pain, and one episode of diplopia. He reported left wrist pain and swelling 3 weeks prior to presentation. A whole body <sup>18</sup>F-positron emission tomography scan detected abnormal hypermetabolic activity in the atlantoaxial joint and in the right shoulder (Figure 1A and B). Magnetic resonance imaging revealed the presence of right SOVT (Figure 1C and D). Blood cultures grew MSSA. He underwent debridement of his right shoulder and was started on intravenous cefazolin. Conservative management of his atlantoaxial septic arthritis was unsuccessful and several weeks into his antibiotic course, he developed right-arm weakness for which he underwent C4 fusion to address atlanto-axial instability.

**Methods.** We reviewed previous reports describing atlantoaxial septic arthritis ( $n = 6$ ) and septic ophthalmic vein thrombosis ( $n = 6$ ).

**Results.** Previous reports of atlantoaxial septic arthritis detailed clinical presentations of subacute to acute onset of neck pain with fever, five of which were due to *S. aureus*. Four of the cases required a surgical intervention involving the cervical spine. Previous reports of SOVT describe patients ipsilateral proptosis, ptosis and chemosis. In all six cases, the SOVT developed in concurrence with a head and neck infections. Three cases required surgery or an interventional procedure for source control. Two cases recovered completely and three cases improved but with diplopia or permanent loss of vision in the affected eye.

**Conclusion.** Even with early recognition and prompt initiation of antibiotic therapy, our patient still suffered from long-term sequelae atlantoaxial septic arthritis and SOVT, a testament to the potential for MSSA to cause severe infections.



**Disclosures.** All authors: No reported disclosures.

**294. Spondylodiscitis After Spine Surgery: Microbiology, Clinical Findings, Outcome and Comparison With Spontaneous Spondylodiscitis**

Uh Jin Kim, MD<sup>1</sup>; Younggon Jung, MD<sup>2</sup>; Tae Hoon Oh, MD<sup>3</sup>; Ji Yun Bae, MD<sup>3</sup>; Seong Eun Kim, MD<sup>1</sup>; Chung-Jong Kim, MD<sup>4</sup>; Seung-Ji Kang, MD<sup>5</sup>; Hee-Chang Jang, MD<sup>1</sup>; Sook-In Jung, MD<sup>1</sup>; Kyoung-Ho Song, MD, PhD<sup>6</sup>; Eu Suk Kim, PhD<sup>7,8</sup>; Hong Bin Kim, MD, PhD<sup>6</sup>; Wan Beom Park, MD, PhD<sup>6</sup>; Nam Joong Kim, MD, PhD<sup>6</sup> and Kyung-Hwa Park, MD<sup>1</sup>; <sup>1</sup>Chonnam National University Medical School and Hospital, Gwangju, Korea, Republic of (South), <sup>2</sup>Chonnam National University Hospital, Gwangju, Korea, Republic of (South), <sup>3</sup>Department of Internal Medicine, Ewha Womans University mokdong hospital, Seoul, Korea, Republic of (South), <sup>4</sup>National Evidence-based Healthcare Collaborating Agency, Seoul, Korea, Republic of (South), <sup>5</sup>Internal Medicine, Chonnam National University Hwasun Hospital, Hwasun, Korea, Republic of (South), <sup>6</sup>Department of Internal Medicine, Seoul National University College of Medicine, Seoul, Korea, Republic of (South), <sup>7</sup>Internal Medicine, Seoul National University College of Medicine, Seoul, Korea, Republic of (South), <sup>8</sup>Seoul National University Bundang Hospital, Seoul, Korea, Republic of (South)

**Session:** 54. Bone and Joint Infections

Thursday, October 4, 2018: 12:30 PM

**Background.** Although postoperative spondylodiscitis has become a major problem, consensus on empirical antibiotics therapy is still controversial. To find out appropriate management of postoperative spondylodiscitis, this study investigated the microbiology, clinical characteristics, and outcome of postoperative pyogenic spondylodiscitis (P-PS) and compared with spontaneous pyogenic spondylodiscitis (S-PS).

**Methods.** This retrospective cohort study evaluated patients with microbiologically proven spondylodiscitis from three university-affiliated hospitals in South Korea between January 2005 and December 2015, with a follow-up of at least 12 months after completion of antibiotics or until the patient was transferred. Patients with prosthesis at the time of diagnosis of spondylodiscitis or who had a spine operation within 1 year of the diagnosis of spondylodiscitis were defined as having postoperative spondylodiscitis. The spine operations included discectomy, laminectomy, arthrodesis, and instrumentation for stabilization of the spine.

**Results.** The study evaluated 104 patients with P-PS and 441 patients with S-PS. In P-PS, the most common isolate was *S. aureus* (34%), followed by coagulase-negative staphylococci (31%), and the proportion of methicillin-resistant strains was 75%. In S-PS, the most common isolates were *S. aureus* (47%) and streptococci (21%). Of the staphylococci, 39% were methicillin resistant in S-PS. The proportion of patients with Gram-negative bacilli was 14% in P-PS and 20% in S-PS. Pre-existing or synchronous nonspinal infection (13% vs. 33%,  $P < 0.001$ ) was observed more frequently in S-PS. Although the duration of antibiotic use was similar in both groups, surgical procedures were done more frequently in P-PS. The mortality rate was similar in both groups. However, the treatment failure and relapse rates at 12 months were higher in the P-PS group (23% vs. 13%,  $P = 0.009$ ; 14% vs. 7%,  $P = 0.028$ , respectively). Methicillin-resistant *S. aureus* was associated with treatment failure or relapse.

**Conclusion.** Gram-positive organisms, mainly methicillin-resistant staphylococci, should be considered when prescribing empirical antibiotics in P-PS. Although surgical drainage was applied more often in P-PS than in S-PS, the treatment failure and relapse rates at the 12-month follow-up were higher in P-PS.

**Disclosures.** All authors: No reported disclosures.

**295. Outcomes of Orthopedic Hardware-Related Osteomyelitis Treated Via a County Hospital Outpatient Parenteral Antimicrobial Therapy (OPAT) Program**

Ethan Valinetz, MD<sup>1</sup>; Cole Beeler, MD<sup>2</sup> and Sharon Erdman, PharmD<sup>1</sup>; <sup>1</sup>Indiana University School of Medicine, Indianapolis, Indiana, <sup>2</sup>Infectious Diseases, Indiana University School of Medicine, Indianapolis, Indiana

**Session:** 54. Bone and Joint Infections

Thursday, October 4, 2018: 12:30 PM

**Background.** Orthopedic hardware-related osteomyelitis (OHRO) is associated with high morbidity and cost from prolonged courses of antibiotics and additional surgery. There is limited published data describing OPAT for the treatment of OHRO.