

## Common hepatic duct perforation in a sickle cell disease child

Talal A. Al-Malki, FRCSC\*; Ashraf H. M. Ibrahim, FRCSI\*\*

From the \*Department of Surgery, Medicine and Medical Sciences, King Khalid University, and \*\*Pediatric Surgery Department, Asir Central Hospital, Abha, Saudi Arabia

Accepted for publication: July 2003

The cause of biliary duct perforation is not well understood. Distal obstruction and/or congenital weakness of the common bile duct (CBD) are assumed to play a role.<sup>1</sup> Idiopathic perforation is the second most common cause of surgical jaundice in infants.<sup>2</sup> The site of perforation is always at the junction of the cystic and common hepatic duct. Bile duct perforation and choledochalcyt may be different manifestations of a complex congenital biliary tract anomaly.<sup>3</sup> Secondary perforation of the biliary duct due to CBD stones in a sickler child is rare and not previously reported.

### Case

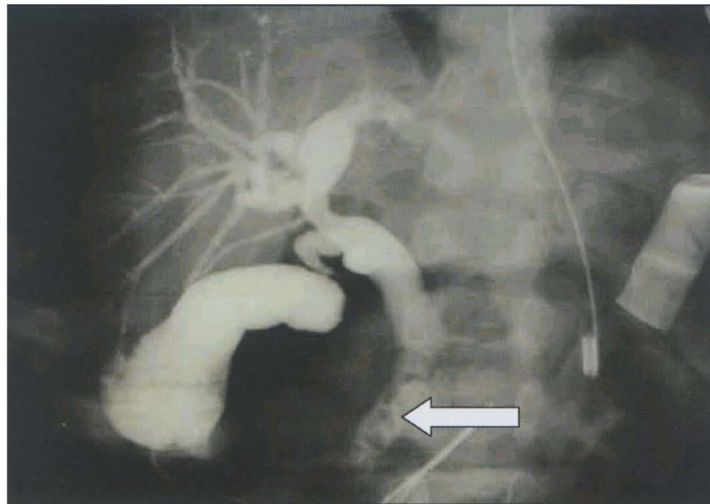
A 9-year-old male child with sickle cell disease presented with abdominal pain of four days and bilious vomiting for one day. The urine was dark and the stool was pale. Upon admission, the patient was sick and deeply jaundiced. The vital signs were stable but for a low-grade fever. The abdomen showed generalized tenderness, especially in the epigastrium and right hypochondrium. There was no organomegaly. The complete blood count showed leukocytosis and reticulocytosis (Table 1). Serum electrolytes were normal. The liver function tests showed an elevated total bilirubin (TB) and direct bilirubin (DB). Alkaline phosphatase was elevated; serum amylase and liver transaminases were within normal limits. The coagulation profile showed a slight elevation versus control. The plain abdominal x-rays were normal. Hemoglobin electrophoresis showed a hemoglobin-S of 90%. Abdominal ultrasonography (US) showed a contracted gallbladder with no evidence of acute inflammation, but with very doubtful small stones or sludge within. There was mild intrahepatic biliary dilatation. However, the CBD was not dilated and did not contain any stones. No free intra-abdominal fluid was seen. The spleen was not visualized. The patient was treated conservatively in the hope that a small CBD stone or sludge would pass. The patient improved within a few days. Blood culture

**Table 1.** Laboratory values on admission.

Leukocytes	15X10 <sup>9</sup> /mL
Hemoglobin (g/dL)	7.9
Hematocrit	21%
Platelets	549 X 10 <sup>9</sup> /L
Reticulocytes	14.4%
Total bilirubin (mg/dL)	23
Direct bilirubin (mg/dL)	16
Alkaline phosphatase (units/L)	712

showed no growth. Hepatitis serology and HIV tests were negative. Ten days later, symptoms recurred. The patient became febrile (38.5°C), and total and direct bilirubin increased to 50 and 32 mg/dL, respectively. Serum amylase remained normal. Repeated abdominal U.S showed normal gallbladder and CBD but with free fluid in the peritoneal cavity. A computed tomography was normal apart from the free fluid in the peritoneal cavity and an absent spleen. Endoscopic retrograde cholangiopancreatography (ERCP) showed free flow of bile into the duodenum, no stones in the CBD and no leakage of the dye through the biliary tree. ERCP was not performed on first admission because the patient was seen in the pediatric medical service at that time. The patient improved clinically and his total and direct bilirubin declined to 18 and 12 mg/dL, respectively. Five days later, the patient became very sick with more severe symptoms and signs. The abdomen became distended and tender all over with rigidity and rebound tenderness. The patient was optimized for surgery. By laparotomy, about 500 mL of bilious ascetic fluid was drained. Operative cholecystogram showed multiple small stones in the gallbladder (GB) and distal portion of the CBD. A cholecystectomy was done and the CBD explored. Multiple small pigment stones were removed with saline irrigation. A sealing perforation was found in the mid-CHD. A T-tube (T-T) with a long proximal limb was inserted to stint the perforation site and the perforation was repaired with absorbable sutures. An omental patch was used to support the repair site. A repeat operative T-tube cholangiogram showed no other leaks. A tube drain was left in the subhepatic region. The patient improved

Correspondence to:  
Talal A. Al-Malki, FRCSC  
Department of Surgery  
College of Medicine and Medical  
Sciences  
P.O. Box 641  
Abha, Saudi Arabia  
E-mail: talmallki@netscape.net



**Figure 1.** An operative cholangiogram showing multiple small stones in the gall bladder and in the distal position of CBD (arrow) in a 9-year-old male with sickle cell disease.

clinically and his total and direct bilirubin declined to 7.2 and 5 mg/dL, respectively. There was leak of bile around the T-tube, which started one week postoperatively. Blood culture grew *Enterobacter* species, which were treated by antibiotic. A T-tube cholangiogram 20 days postoperatively showed minimal leak from the CBD and no residual stones with free flow of dye to the duodenum. The T-tube was later removed followed by tube drainage three days later. The patient was discharged in good health.

### Discussion

In the past, hemolytic disease was the most common cause of gallstones.<sup>4</sup> Reports of idiopathic cholelithiasis have increased by more than 80% and reports of cholelithiasis due to hemolysis have decreased to 20% (5.6). Studies have confirmed the increased frequency of gallstones in SCD patients. The incidence has risen from 10% in patients under the age of 10 to as high as 55% in between 10 and 18 years old.<sup>7</sup> Al-Salem et al in 1997 performed a study by abdominal US examination on 305 children with SCD aged 1 to 18 years. Gallstones were present in 60 children (19.7%); an additional 50 patients in the same study had biliary sludge alone (16.4%). On follow-up of 35 of the 50 children with sludge, 23 (65.7%) had developed gallstones.<sup>8</sup> Gallstones are the cause of recurrent abdominal pain and cholecystitis in patients with SCD. These complications are difficult to distinguish from the very frequent episodes of vaso-occlusive abdominal pain.<sup>9</sup> Moreover, abdominal laboratory tests, US and biliary scintigraphy have a low positive predictive value for detection of acute biliary disease in these patients.<sup>10</sup> The possibility of gross organ infarction and rupture, infection, or other complications cannot be

ignored. Acute episodes of the disease selectively affect the liver in 10%, causing hepatic crisis with abdominal pain, nausea, fever, jaundice and transaminase elevation, which may be indistinguishable from viral hepatitis. Acute cholecystitis or choledocholithiasis may have clinical and laboratory features similar to sickle cell hepatic crisis or viral hepatitis.<sup>11</sup>

Extrahepatic biliary system perforation can be idiopathic or secondary to iatrogenic injury, trauma, and parasitic infestation or very rarely due to distal CBD obstruction by stenosis, stricture or stones.<sup>12-16</sup> Idiopathic perforation of the extrahepatic biliary system is the second most common cause of surgical jaundice in infants.<sup>2</sup> The site of perforation is almost always at the junction of the cystic duct and common hepatic duct. Distal obstruction is uncommon.<sup>1</sup> Patients usually present with slowly progressive ascites and jaundice. Diagnosis is by US, paracentesis and isotopic scan. During surgery, cholecystostomy is important for an operative cholangiogram to help find the site of perforation. Identification of distal obstruction, repair of the perforation and cholecystectomy are not necessary. The operative cholangiogram can be misleading. Simple drainage is enough and the lesion is generally self-limiting;<sup>3</sup> an exception has been reported.<sup>17</sup>

In older children, in whom the most likely cause is secondary perforation, local drainage with repair of the duct are indicated along with management of distal obstruction.<sup>1</sup> In the present case, the perforation was found in the common hepatic duct and distal obstruction was due to multiple small pigment stones. Ultrasound was not helpful in diagnosis. Paracentesis was not done because the amount of free fluid was little. ERCP was misleading. Operative

cholangiogram through cholecystostomy showed multiple small stones in the gallbladder as well as in the distal CBD. Cholecystectomy and CBD exploration were necessary, along with repair of the perforation and adequate drainage. A T-tube was left in-situ for drainage, postoperative healing assessment and to rule out residual obstruction.

In conclusion, the authors report a unique case of CHD perforation in a child with SCD due to distal CBD obstruction by pigment stones. The preoperative diagnosis was difficult. Although, emergency surgery was straightforward, the outcome was complicated by minimal CBD leakage and sepsis, which resolved on conservative treatment.

## References

1. Kottmeier PK. Ascites. In: Welch KJ, Randolph JG, Ravitch MM, et al, eds. *Pediatric Surgery*. Chicago, IL: Yearbook; 1986: 925-928.
2. Holland RM, Lilly JR. Surgical jaundice in infants other than biliary atresia. *Semin Ped Surg*. 1992;1: 125-129.
3. Lilly JR, Weintraub WH, Altman RP. Spontaneous perforation of the extra hepatic bile ducts and bile peritonitis in infancy. *Surgery*. 1974;75: 664-671.
4. Lau GE, Andrassy RJ, Mahour GH. A thirty year review of the management of gallbladder disease at a children's hospital. *Am Surg*. 1983;49: 411.
5. Goodman DP. Cholelithiasis in persons under twenty-year old. *JAMA*. 1976;236: 1731.
6. Holcomb GW Jr, O'Neill JA Jr, Holcomb GW III. Cholecystitis, cholelithiasis and common duct stenosis in children and adolescents. *Ann Surg*. 1980; 191: 626.
7. Lackman BS, Lazerson J, Starshak RJ, et al. The prevalence of cholelithiasis in sickle cell disease as diagnosed by ultrasound and cholecystography. *Pediatrics*. 1979; 64: 601.
8. Al-Salem AH, Qaisruddin S. The significance of biliary sludge in children with sickle cell disease. *Pediatr Surg Int*. 1997;13: 14-16.
9. De-Lagausie P, Eymery JC, Tavakoli D. Value of elective cholecystectomy in children with homozygote sickle cell anemia. Apropos of 3 recent cases. *Ann Chir*. 1989;34 (5): 361-362.
10. Serafini AN, Spoliensky G, Sfakianakis GN, Montalvo B, Jensen WN. Diagnostic studies in patients with sickle cell anemia and acute abdominal pain. *Arch Intern Med*. 1987; 147 (6): 1061-1062.
11. Schubert TT. Hepatobiliary system in sickle cell disease. *Gastroenterology*. 1986; 90 (6): 2013-2021.
12. Lambiase RE, Cronan JJ, Ridlen M. Perforation of the common bile duct during endoscopic sphincterotomy: recognition on computed tomography and successful precutaneous treatment. *Gastrointest-Radiol*. 1989; 14(2): 133-136.
13. Kumar A, Kataria R, Cattopadhyay TK, Tarak PK, Tandon RK. Biliary peritonitis secondary to perforation of common bile duct: and unusual presentation of chronic calcific pancreatitis. *Postgrad Med J*. 1992; 68 (804): 837-839.
14. Tiou MM, Huang SC, Huang SC, Shieh CS, Lee CH. Idiopathic common bile duct perforation: a case report. *Chang-Keng-I-Hsueh*. 1995;18(3): 270-274.
15. Witcombe JB. Ascaris perforation of the common bile duct demonstrated by intravenous cholangiograph. *Pediatr-Radiol*. 1978; 7 (2): 124-125.
16. Sardar I, Chatterjee M, Mukherjee PK. Common bile duct perforation by roundworm. *J Indian Med Assoc*. 1984; 82 (4): 136-138.
17. Spigland N, Greco R, Rosenfeld D. Spontaneous biliary perforation: does external drainage constitute adequate therapy? *J Pediatr Surg*. 1996;31: 782-784.