

Available online at [www.sciencedirect.com](http://www.sciencedirect.com)

ScienceDirect

journal homepage: [www.elsevier.com/locate/radcr](http://www.elsevier.com/locate/radcr)

## Case report

# Endovascular treatment of a post-traumatic pseudoaneurysm arising from a ruptured posterior tibial artery with Menox. A case report <sup>☆</sup>

Christina Aslanidi, MD\*, Sofia Athanasiou, MD, Christofis Charalambous, MD, Vasilios Mamalis, MD, Costantinos Papadopoulos, MD, Eftichios Arhontakis, MD, Antonios Tsanis, MD

Interventional Radiology Department, Red Cross Hospital Athens, Greece

## ARTICLE INFO

## Article history:

Received 23 July 2021

Accepted 24 July 2021

Available online 26 August 2021

## Keywords:

Pseudoaneurysm

Endovascular treatment

Posterior tibial artery

Post-traumatic

## ABSTRACT

Posterior tibial artery pseudoaneurysms are rare and can occur in the setting of trauma. Endovascular treatment of post-traumatic pseudoaneurysms has become a viable less-invasive method particularly in young patients in whom the presence of collaterals guarantees distal vascularization. We report an unusual case of a 16-year-old patient who sustained blunt trauma to his right lower extremity due to a bicycle injury and developed a delayed symptomatic pseudoaneurysm of the posterior tibial artery in the absence of tibia fracture. Superselective endovascular treatment with Ethylene Vinyl Alcohol Copolymer based liquid embolic system (Menox) was successfully performed, achieving exclusion of the pseudoaneurysm with preservation of the remaining vascularization of the lower limb.

© 2021 The Authors. Published by Elsevier Inc. on behalf of University of Washington.

This is an open access article under the CC BY-NC-ND license

(<http://creativecommons.org/licenses/by-nc-nd/4.0/>)

## Introduction

Pseudoaneurysms (PSAs) or false aneurysms are common vascular abnormalities that usually arise from a disruption in the arterial wall predominantly. Blood leaks through the defect in the arterial wall into the surrounding tissue, which leads to a persistent communication between the originating artery and the adjacent cavity. PSAs can occur as a consequence of trauma, inflammation and various iatrogenic procedures (eg,

surgery, percutaneous biopsy, drainage) [1]. However, arterial PSAs after lower limb trauma have been rarely reported in the literature. Posttraumatic PSAs may be asymptomatic or have a subtle delayed clinical presentation. Early diagnosis is essential considering the catastrophic complications. Treatment options include open surgery, endovascular stenting and embolization. There has been increasing interest in the use of endovascular methods for this type of injury. We describe the case of a 16-year-old patient, who was diagnosed with a large PSA of the posterior tibial artery (PTA) that was discovered 10

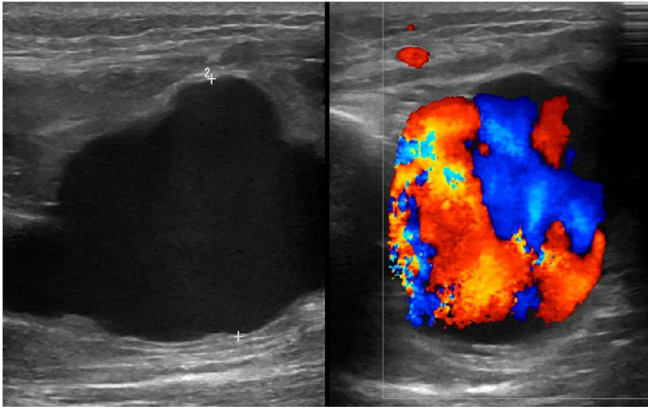
<sup>☆</sup> Competing interests: The authors declare that they have no known competing financial interests or personal relationships that could have appeared to influence the work reported in this paper.

\* Corresponding author.

E-mail address: [christina.aslanidi178@gmail.com](mailto:christina.aslanidi178@gmail.com) (C. Aslanidi).

<https://doi.org/10.1016/j.radcr.2021.07.057>

1930-0433/© 2021 The Authors. Published by Elsevier Inc. on behalf of University of Washington. This is an open access article under the CC BY-NC-ND license (<http://creativecommons.org/licenses/by-nc-nd/4.0/>)



**Fig. 1 – B-mode ultrasound revealed a well-circumscribed hypoechoic mass. (B) Duplex Doppler Ultrasound demonstrated the hallmark “yin-yang” sign of pseudoaneurysm, which indicates bidirectional flow due to the swirling of the blood in the sac.**

days after a blunt lower limb trauma. We present the technique employed for minimally invasive treatment and discuss the various treatment options.

### Case report

A 16-year-old patient was admitted to our emergency department, 10 days after a blunt trauma to his right lower extremity following a bicycle accident. He presented with increasing pain due to the formation of a pulsatile mass located in the posterior mid-portion of the tibia. Plain radiographs showed no bone lesion. Doppler ultrasound revealed a hypoechoic cystic structure with circulating blood originating from the distal third of the right tibia, following the typical swirling motion called the “yin-yang sign” (Fig. 1). Subsequently, he underwent CT angiography (CTA) of the right lower limb, which revealed an enlarged PSA at the level of the distal PTA (Fig. 2). An endovascular treatment plan was formulated with the intention to exclude the pseudoaneurysm from the circulation by placing a covered stent graft into the feeding vessel. However, the diagnostic digital subtraction angiography via the right femoral artery with a 5F-Envoy guiding catheter (Codman) revealed a PSA originating from the distal PTA with extensive wall disruption of the vessel, thus making the placement of the stent infeasible (Fig. 3A). Consequently, our initial plan was abandoned and it was decided that the most appropriate treatment option was to use Menox in order to occlude the pseudoaneurysm. In particular, after superselective catheterization of the right PTA with the Echelon-10 microcatheter/Avigo hydrophilic microwire combination, the microcatheter was flushed with 0.34 mL of dimethyl sulfoxide (DMSO) and then 0.4 mL of Menox (Ethylene Vinyl Alcohol-EVOH) was injected under fluoroscopic control. However, despite the occlusion of the feeding pedicle, blood flow remained inside the PSA due to the presence of a collateral branch, which originated from the distal right peroneal artery (Fig. 3B).

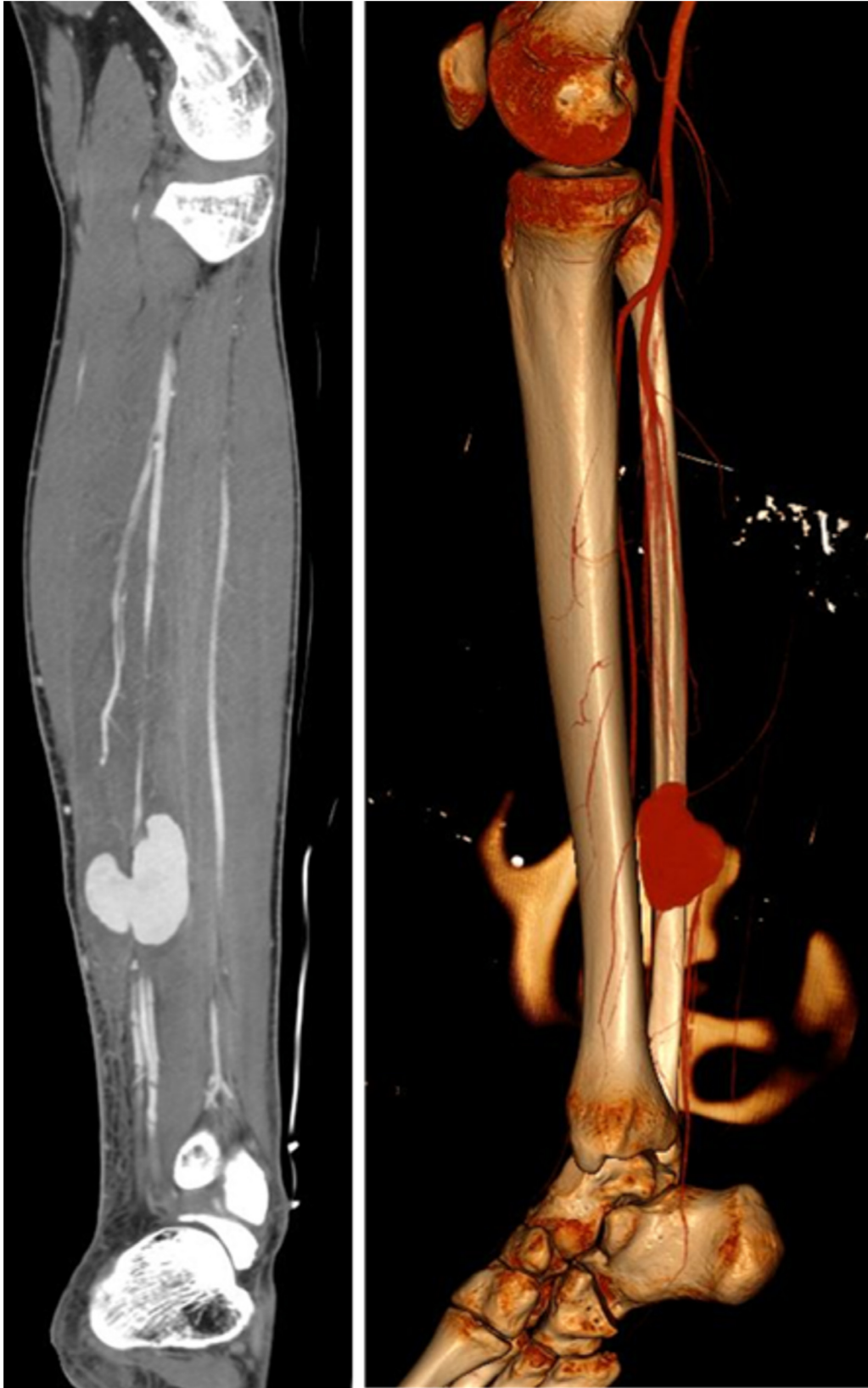Subsequently, superselective catheterization of the right peroneal artery with Marathon microcatheter/ Mirage.008 hydrophilic microwire and injection of 0.2 mL DMSO and 0.7 mL Menox in the distal peroneal artery and its collateral branch was performed (Fig. 4A). Completion angiography revealed complete PSA exclusion with patent right PTA and peroneal artery (Fig. 4B). One week after the procedure, the patient was entirely asymptomatic, whilst the postoperative Doppler Ultrasound confirmed the tibioperitoneal trunk integrity and the complete removal of the PSA (Fig. 5). At the 6-month follow-up, the patient remained asymptomatic without any evidence of pathologic findings in the Doppler Ultrasound.

### Discussion

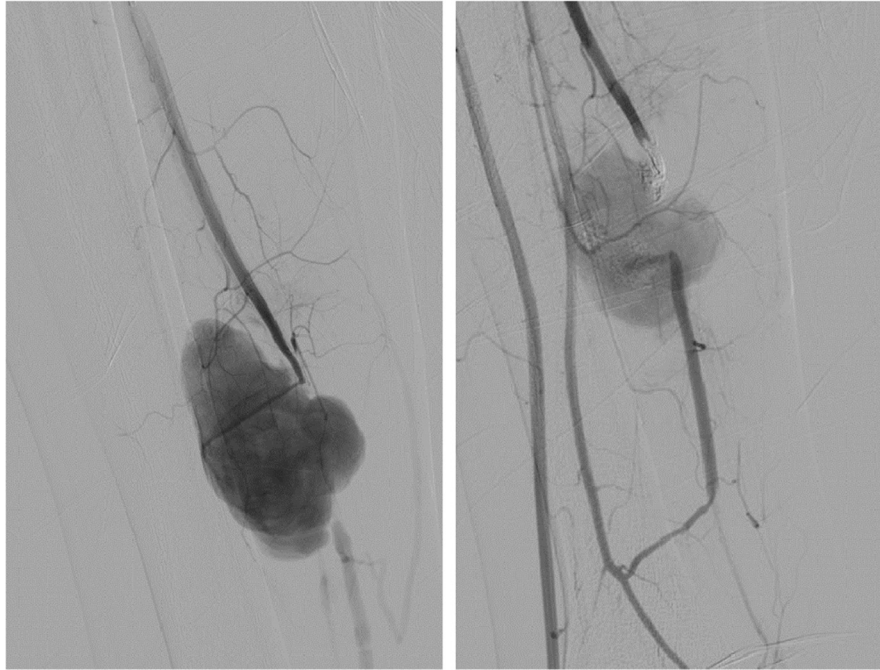
The formation of a PSA results from a leakage of blood into the perivascular space at the site of the vessel wall disruption due to trauma, infection or iatrogenic causes [1]. In contrast to true aneurysms, PSAs are contained by the adventitia or surrounding soft-tissue structures making them more prone to rupture and therefore requiring urgent management [1]. PTA PSAs are extremely uncommon and they typically occur because of penetrating or blunt trauma [2], fractures of the lower limb [3] and orthopedic procedures [4]. They usually present with pain, swelling or an expanding pulsatile mass, while the severity of the symptoms is associated with the size of the PSA [5]. As for the complications, ischemia of the surrounding soft-tissues may develop secondary to vascular compromise [1]. Neuropathy, venous obstruction and even thrombosis may be caused due to the compression of the adjacent nerves or veins [1,5]. Additionally, a ruptured pseudoaneurysm may lead to compartment syndrome, which is associated with high rates of disability and limb loss [5]. Therefore, early diagnosis is of utmost importance.

Doppler Ultrasound constitutes the first-line imaging modality and provides accurate information about the dimensions, morphology, flow pattern, neck anatomy and feeding vessels of the PSA [5]. In cases of an inconclusive ultrasound exam, CTA may be used for further evaluation [6]. CTA provides a global perspective of the entire vasculature, which is crucial when endovascular or surgical treatment is planned. MR-Angiography is another accurate non-invasive imaging tool that provides excellent quality imaging and important information about the vascular anatomy and flow [5]. Digital subtraction angiography remains the gold-standard imaging method, as it can demonstrate a PSA that may not be recognized in the other non-invasive imaging methods [6]. When the diagnosis is uncertain, a combination of the above invasive and non-invasive methods is recommended in order to establish the diagnosis [6].

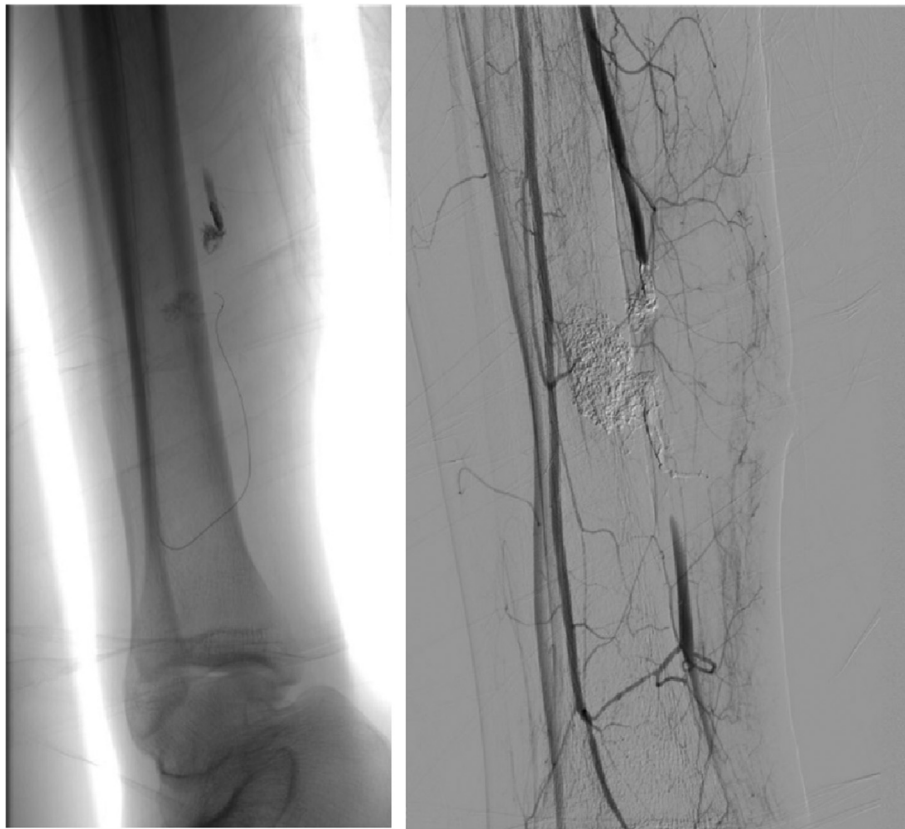
Numerous suitable options of treatment of PTA pseudoaneurysms have been described in the literature. Current therapeutic methods include ultrasound-guided compression, thrombin injection, surgery and endovascular treatment [5,6]. In cases of small (<1 cm) and asymptomatic PSAs no treatment is needed and US follow-up is sufficient [7]. The most crucial factor affecting the treatment method is the feeding artery of the PSA, which can be a major arterial branch or



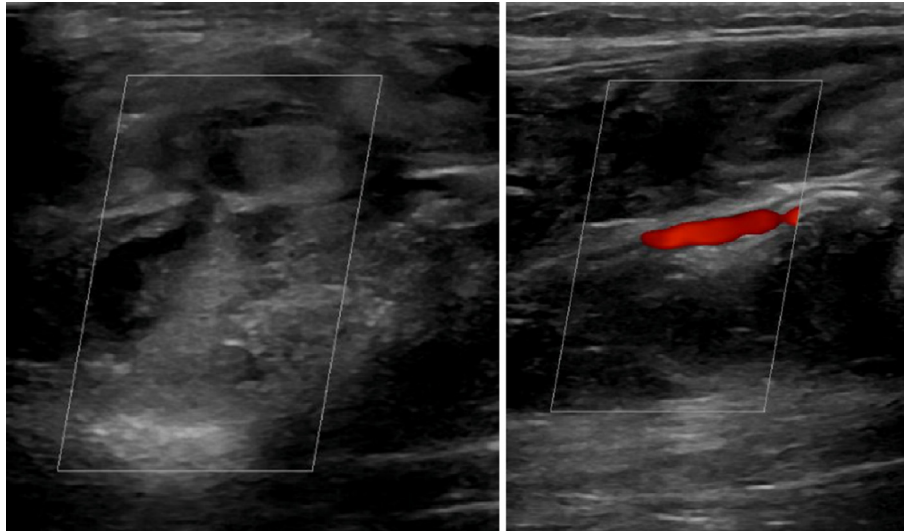
**Fig. 2 – CTA (MIP reconstruction) demonstrating the enlarged PSA originating from the distal posterior tibial artery. (B) Three-dimensional reconstruction image confirms the volume of PSA.**



**Fig. 3 – (A) Angiogram after superselective catheterization of the right PTA showing the PSA. (B) Remaining blood flow inside the PSA, despite the occlusion of the feeding artery with EVOH liquid embolic system, due to collateral flow.**



**Fig. 4 – (A) Digital subtraction angiography during superselective catheterization with microwire of the peroneal artery and its collateral branch. (B) Post intervention angiogram shows successful exclusion of the PTA pseudoaneurysm.**



**Fig. 5 – One-week follow-up ultrasonographic images revealed the complete exclusion of PSA (A) and the integrity of the posterior tibial artery (B).**

small deep muscular branches [8]. Traditionally, surgical exploration and repair was the first choice of treatment [6]. Surgical treatment is still preferred in the presence of compartment syndrome, in infected PSAs or rapid growth [6,9]. However, surgical treatment requires long hospitalization time, general anesthesia and has an associated morbidity [9]. PSAs arising from superficial arteries can be treated by percutaneous injection of thrombin under US guidance [8].

Over the past few years, endovascular treatment methods have taken the first place in the treatment of PSAs involving deep and small muscular branches [8]. Endovascular approach can be accomplished using a wide range of techniques, including catheter-guided embolization with coils or injection of liquid embolic agents such as thrombin, n-butyl cyanoacrylate (NBCA), EVOH or percutaneous implantation of endovascular-covered stents [9]. They can be used either alone or as complementary tools. Coil embolization is the most common form of treatment, as coils are the most appropriate embolic material for ruptured narrow-necked PSAs. The main disadvantage of their usage is potential recanalization of the embolized sac if the coils are not tightly packed or if the patient has coagulation disorders [6]. Stent-grafts are used especially for the treatment of wide-necked PSAs involving a large caliber artery (over 5mm), preventing the long-term risk of thrombosis. Although, there are no stent grafts designed for specific peripheral intervention so far, coronary devices have to be used to treat tibial arteries [10].

Liquid embolic agents such as NBCA or EVOH can be very useful in large PSAs. NBCA can be used in combination with coils or alone in the treatment of traumatic PTA PSAs. However, due to the fact that NBCA polymerizes on contact with blood, considerable experience is required to achieve optimal results. Besides, NBCA embolization of a PSA developing from the root of the feeding artery runs a high risk of reflux into the adjacent branches, leading to potential complications [8]. As opposed to NBCA, EVOH is a non-adhesive liquid embolic agent comprised of ethylene-vinyl alcohol copolymer

dissolved in DMSO and suspended micronized tantalum powder for fluoroscopy contrast. EVOH is delivered by slow controlled injection. The DMSO solvent dissipates into the blood, causing the ethylene-vinyl alcohol copolymer and suspended tantalum to precipitate into a spongy, coherent embolus. It immediately forms a skin as the embolus solidifies from the outside in whilst travelling distally to the lesion [8]. Menox (EVOH) is our preferred liquid embolic agent, as its management is easier than other agents and it does not run the risk of polymerization within the catheter. Therefore, Menox can be administered in a slower, more accurate and controlled way than the other embolic agents, significantly minimizing the risk of ischemic complications, avoiding unintentional occlusion and reflux to the adjacent branches [11]. To the best of our knowledge, our case is the first-reported use of Menox for the embolization of a post-traumatic PTA pseudoaneurysm.

## Conclusion

In conclusion, post-traumatic PSA of the PTA is a rare vascular entity with serious and even life-threatening complications. Early diagnosis is essential in order to plan the appropriate treatment and management of the patient. Minimally invasive techniques, such as Menox (EVOH) embolization, represents a rapid, safe and reliable method of treatment in large PSAs involving deep muscular branches, avoiding the risk and dangers of an open surgery procedure.

## Patient consent

I confirm that written, informed consent for publication of their case was obtained from the patient.

---

## Supplementary materials

Supplementary material associated with this article can be found, in the online version, at doi:10.1016/j.radcr.2021.07.057.

---

## REFERENCES

- [1] Saad NE, Saad WE, Davies MG, Walkdman DL, Fultz PJ, Rubens DJ. Pseudoaneurysms and the role of minimally invasive techniques in their management. *Radiographics* 2005;25(1):S173–89 Suppl.
- [2] Murphy A, Chan M, Fairbank S. Tibial nerve palsy as the presenting feature of posterior tibial artery pseudoaneurysm. *ANZ J Surg* 2018;88:1206–8.
- [3] Farzad Amiri, Zachary Sanford, Constantinos Constantinou. Traumatic posterior tibial pseudoaneurysm: a rare late complication repaired conventionally. *Marshall J Med* 2016;2(Iss. 3) Article 3.
- [4] Wanken Zachary J, Barnes JAaron, Eppolito Anna J, Zwolak Robert M, Suckow Bjoern D. Coil embolization of an aberrant posterior tibial artery pseudoaneurysm after total knee arthroplasty. *J Vasc Surg Cases Innov Tech* 2019;5(4):497–500.
- [5] Raheerintantenaina F, Rajaonanaaharya TMA, Rakoto Ratsimba HN. Management of traumatic arterial pseudoaneurysms as a result of limb trauma. *Formosan Journal of Surgery* 2016;49(3):89–100 VolumeIssue.
- [6] Orkun Sarioglu, Ergin Capar Ahmet, Belet Umit. Interventional treatment options in pseudoaneurysms: different techniques in different localizations. *Pol J Radiol* 2019;84:e319–27.
- [7] Elens S, Bossu N, Puech P, Ghekiere J, Delcour C, Casselman J. Two rare cases of posttraumatic peripheral artery pseudoaneurysm. *J Belg Soc Radiol* 2016;100(1):112.
- [8] Cantasdemir Murat, Kantarci Fatih, Mihmanli Ismail, Numan Furuzan. Embolization of profunda femoris artery branch pseudoaneurysms with ethylene vinyl alcohol copolymer (Onyx). *J Vasc Interv Radiol* 2002;13(7):725–8.
- [9] Singh D, Ferero A. Traumatic pseudoaneurysm of the posterior tibial artery treated by endovascular coil embolization. *Foot Ankle Spec* 2013;6(1):54–8.
- [10] Joglar Fernando, Kabutey Nii-Kabu, Maree Andrew, Farberhe Alik. Role of stent grafts in the management of traumatic tibial artery pseudoaneurysms: case report and review of the literature. *Vas Endovascular Surg* 2010;44(5):407–9.
- [11] Rennert J, Herold T, Schreyer AG, Banas B, Jung EM, Feuerbach S, et al. Evaluation of a liquid embolization agent (Onyx) for transcatheter embolization for renal vascular lesions. *Rofo* 2009;181(10):996–1001.