

Noninvasive flow evaluations of coronary artery bypass grafting using dynamic cardiac CT

Daisuke Sakabe, RT, PhD^a, Toshihiro Fukui, MD, PhD^b, Seitaro Oda, MD, PhD^{c,*}, Osamu Tominaga, MD^d, Ken Okamoto, MD, PhD^b, Shingo Kato, MD, PhD^e, Tsuneo Yamashiro, MD, PhD^e, Yoshinori Funama, RT, PhD^f, Masafumi Kidoh, MD, PhD^c, Osamu Ikeda, MD, PhD^c, Daisuke Utsunomiya, MD, PhD^e

Abstract

We aimed to investigate the correlation of graft flow measurements between transit-time flow measurement (TTFM) during coronary artery bypass grafting (CABG) surgery and dynamic cardiac CT after the surgery.

Fourteen patients underwent CABG with TTFM and postoperative dynamic cardiac CT; 11 internal thoracic artery (ITA) grafts and 15 saphenous venous grafts (SVGs) were included for analysis. Pearson's correlation analysis was performed for the comparisons of the TTFM and cardiac dynamic CT flow parameters.

TTFM was not significantly correlated with the CT flow of the ITA grafts ($r = -0.23$, $P = .49$), but it had a very strong correlation with the CT flow of the SVGs ($r = 0.83$, $P < .01$).

In patients who underwent CABG surgery, dynamic cardiac CT enabled quantitative evaluation of SVG flow, with good correlation with TTFM.

Abbreviations: CABG = coronary artery bypass grafting, CT = computed tomography, ITA = internal thoracic artery, SVG = saphenous venous graft, TTFM = transit-time flow measurement, VOI = volume of interest.

Keywords: coronary artery bypass grafting, dynamic cardiac CT, saphenous venous grafts, internal thoracic artery grafts, transit-time flow measurement

1. Introduction

Coronary artery bypass grafting (CABG) has been the standard strategy for revascularization of multivessel disease and left main

trunk lesion and is the most common cardiac surgery worldwide.^[1] In the Synergy between PCI with Taxus and Cardiac Surgery (SYNTAX) trial, Thuijs et al reported that CABG provided a significant survival benefit in patients with triple-vessel disease after a 10-year follow-up period.^[2] Among patients who underwent CABG between 2013 and 2016, the proportion of triple-vessel CABG was approximately 35%.^[3] The combination of internal thoracic artery (ITA) grafts and saphenous venous grafts (SVGs) has been commonly used for multivessel CABG.

For the clinical outcomes, graft patency, advancement of the disease in native vessels, and comorbid conditions were the reported major predictors of long-term mortality, particularly in patients aged 65 years or older.^[4] Of these, long-term graft patency remains one of the most important challenges. Intraoperative quality control of the grafts using transit-time flow measurement (TTFM) has been shown to reduce the rate of adverse events and graft failure,^[5,6] and it has been recommended in the European Association for Cardio-Thoracic Surgery and the European Society of Cardiology guidelines for myocardial revascularization.^[7]

Cardiac computed tomography (CT) is widely used for the anatomical evaluation of graft patency after CABG; however, it cannot provide the functional information of the graft. A previous study suggested the usefulness of dynamic cardiac CT for the functional assessment of coronary vessels.^[8] We hypothesized that cardiac dynamic CT enables not only anatomical but also functional evaluation of the graft in the management of patients undergoing CABG. Therefore, the purpose of our study was to investigate the correlation of the flow measurements between TTFM during surgery and dynamic cardiac CT after surgery.

Editor: Ovidiu Constantin Baltatu.

We have no direct or indirect financial interest in the products used or the subject matter discussed in this manuscript.

The datasets generated during and/or analyzed during the current study are available from the corresponding author on reasonable request.

^aDepartment of Central Radiology, Kumamoto University Hospital, ^bDepartment of Cardiovascular Surgery, Faculty of Life Sciences, ^cDepartment of Diagnostic Radiology, Faculty of Life Sciences, Kumamoto University, 1-1-1 Honjo, Chuo-ku, Kumamoto, ^dDepartment of Cardiovascular Surgery, Fukuoka Wajiro Hospital, 2-2-75, Wajirogaoka, Higashi-ku, Fukuoka, ^eDepartment of Diagnostic Radiology, Yokohama City University Graduate School of Medicine, 3-9 Fukuura, Kanazawa-ku, Yokohama, Kanagawa, ^fDepartment of Medical Physics, Faculty of Life Sciences, Kumamoto University, 1-1-1 Honjo, Chuo-ku, Kumamoto, Japan.

*Correspondence: Seitaro Oda, Department of Diagnostic Radiology, Faculty of Life Sciences, Kumamoto University, 1-1-1 Honjo, Chuo-ku, Kumamoto 860-8556, Japan (e-mail: seisei0430@nifty.com).

Copyright © 2020 the Author(s). Published by Wolters Kluwer Health, Inc. This is an open access article distributed under the terms of the Creative Commons Attribution-Non Commercial License 4.0 (CCBY-NC), where it is permissible to download, share, remix, transform, and buildup the work provided it is properly cited. The work cannot be used commercially without permission from the journal.

How to cite this article: Sakabe D, Fukui T, Oda S, Tominaga O, Okamoto K, Kato S, Yamashiro T, Funama Y, Kidoh M, Ikeda O, Utsunomiya D. Noninvasive flow evaluations of coronary artery bypass grafting using dynamic cardiac CT. *Medicine* 2020;99:48(e23338).

Received: 4 May 2020 / Received in final form: 21 August 2020 / Accepted: 19 October 2020

<http://dx.doi.org/10.1097/MD.0000000000002338>

2. Materials and methods

2.1. Patient population

The study population comprised 16 patients who underwent primary elective CABG with TTFM and postoperative dynamic cardiac CT within 2 weeks after surgery between July 2017 and February 2018. The study was approved by the ethics committee of the Kumamoto University Hospital (approve number, #2341) and informed consent was obtained from all patients. Two patients were excluded due to poor image quality. The remaining 14 patients (11 ITA grafts and 15 SVGs) were included for analysis: sequential and composite grafts were excluded. The demographic and clinical data of the patients are shown in Table 1.

2.2. CABG surgery and TTFM

All SVGs were harvested using an open technique. ITA grafts were harvested in a skeletonized fashion. All procedures were performed through median sternotomy, standard cannulation, and extracorporeal circulation for on-pump procedures or with the use of stabilizers for off-pump procedures (12 off-pump and 2 on-pump). The coronary vessel diameter was measured using a surgical metal probe. Distal and Y-anastomoses were made using 8–0 polypropylene. The proximal anastomoses were made using 6–0 polypropylene during partial aortic clamping.

The TTFM values [i.e., mean graft flow volume (ml/minutes) and pulsatility index] of all grafts were recorded intraoperatively in a standardized manner. In particular, at 5 minutes after the patient was weaned from cardiopulmonary bypass and the hemodynamic condition was assessed as being stable, the TTFM values and respective flow curves were obtained using a dedicated TTFM system (Medistim VeriQ; Medistim USA Inc., Plymouth, MN, USA). The TTFM probe was fitted precisely around the middle portion for the ITA grafts and proximally around for the SVGs.

2.3. Dynamic cardiac CT data acquisition

CT examinations were performed using a 320-detector row CT scanner (Aquilion One Geneis Edition; Canon Medical Systems, Otawara, Tochigi, Japan). This scanning protocol was modified based on previously reported methods.^[8] Dynamic cardiac CT was scanned at mid-diastole during 15 to 20 (median, 18) cardiac cycles with prospective electrocardiogram gating. Iodinated contrast medium at 420 mgI/kg (Oiparomin 370; Fuji Pharmaceutical Company, Toyama, Japan) was injected over a fixed duration of 17 seconds, followed by a 30-ml saline flush, which was injected at the same rate as the contrast medium. Image

acquisition was determined by the test bolus data, from the arrival time to the ascending aorta to 10 seconds after the peak time. The scan parameters included gantry rotation time of 0.275 seconds, tube voltage of 100 kV, tube current of 100 mA, and field of view of 200 mm. Coronary CT angiography was obtained as a boost scan during the dynamic scanning, with tube voltage of 100 kV and tube current of 400 mA at 8 seconds after the peak time that was obtained by the test bolus data. All CT images were reconstructed using model-based iterative reconstruction (FIRST, Canon Medical Systems). All patients received sublingual nitroglycerin and β -blockers before the CT study.

2.4. CT flow measurement

For increasing the precision of the CT flow measurement, the dynamic data sets were interpolated with 3 additional data sets using motion coherence image processing software (PhyZiodynamics; Ziosoft Inc., Tokyo, Japan), which can perform deformable registration to track all the voxels throughout multiple phases and can interpolate images between phases to generate new phases. The spherical volume of interest (VOI) was located on the middle portion of the ITA grafts and on the proximal portion of the SVGs; the VOIs were automatically tracked throughout all phases. The time–density curve of the grafts was generated. The CT flow of the graft vessels was defined as the maximum upslope from the time–density curves.

2.5. Visual evaluation for standard coronary CT angiography

From the boost scan data of the dynamic cardiac CT, standard coronary CT angiographic images were generated. Two reviewers consensually performed visual evaluation of the grafts, according to a 4-point grading, as follows: 4 (excellent), the entire graft and anastomosis could be clearly identified; 3 (good), the graft patency could be evaluated but the anastomosis was unclear; 2 (fair), the graft patency was partially obscured; and 1 (poor), the graft could not be identified.

2.6. Statistical analysis

Continuous data were expressed as mean \pm SD. Pearson's correlation analysis was performed for the pairwise comparisons of the TTFM and cardiac dynamic CT flow parameters. The strength of correlation was described, as follows: perfect correlation ($r=1$); very strong correlation ($r=0.8$ to 0.99); strong correlation ($r=0.6$ to 0.79); moderate correlation ($r=0.4$ to 0.59); weak correlation ($r=0.2$ to 0.39); and no to very weak correlation ($r=0$ to 0.19). Statistical analysis was performed with the computer software (MedCalc version 17.2, MedCalc, Mariakerke, Belgium). A P value of $< .05$ was considered statistically significant.

3. Results

For the ITA grafts, the CT flow was not significantly correlated with the mean graft flow volume by TTFM ($r=-0.23$, $P=.49$) (Fig. 1a). On the other hand, a very strong correlation was found between the CT flow of the SVGs and the mean graft flow volume by TTFM ($r=0.83$, $P<.01$) (Fig. 1b). The CT flow was not significantly correlated with the pulsatility index for both the ITA grafts ($r=0.11$, $P=.76$) and the SVGs ($r=-0.34$, $P=.21$). The

Table 1

Patient characteristics.

Number of patients	14
Age (years)	73.0 \pm 6.7
Female/male	3/11
Number of grafts (ITA grafts/SVGs)	11/15
Body weight (kg)	56.9 \pm 10.8
Body mass index (kg/m ²)	21.9 \pm 3.5
Average heart rate (beats/minutes)	62.3 \pm 4.5

Data are presented as mean \pm SD.

ITA = internal thoracic artery, SVG = saphenous venous graft.

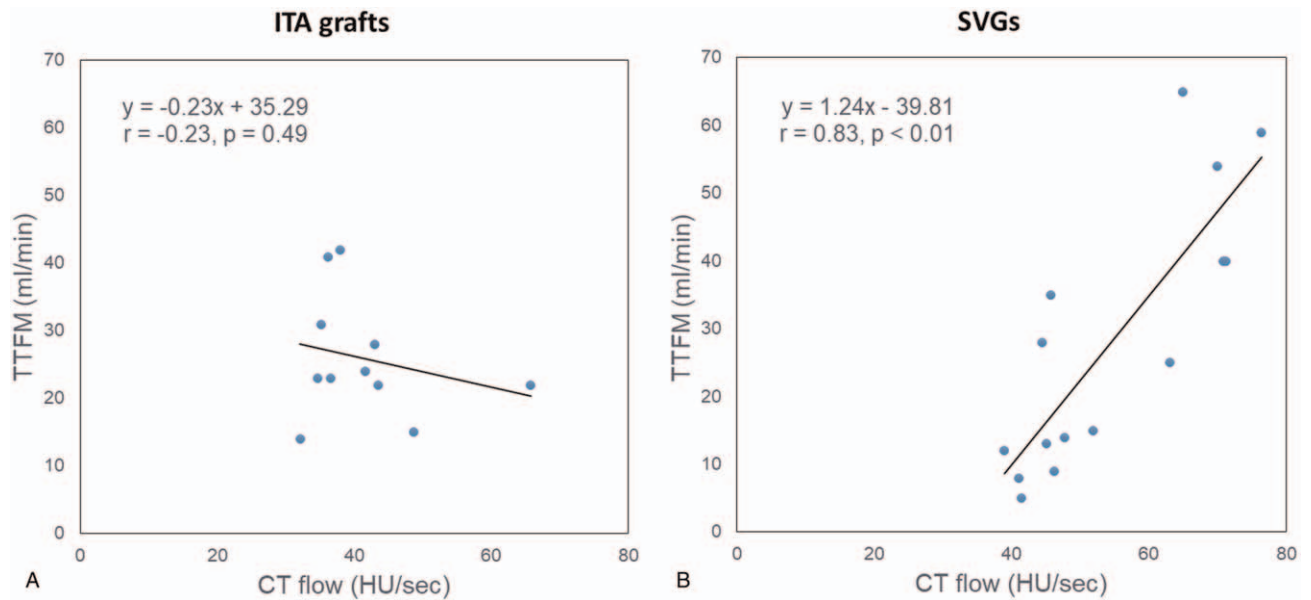


Figure 1. The correlation of graft flow measurements between TTFM and dynamic cardiac CT. (a) The CT flow of the ITA grafts is not significantly correlated with the mean graft flow volume by TTFM ($r = -0.23, P = .49$). (b) A very strong correlation is found between the CT flow of the SVGs and the mean graft flow volume by TTFM ($r = 0.83, P < .01$).

mean visual score for the standard coronary CT angiography was 3.7, and there were no patients who had scores of 1 (fair) and 2 (poor). The mean estimated effective radiation dose for dynamic cardiac CT was 4.4 ± 0.9 mSv.

4. Discussion

Multivessel CABG involves 2 or 3 grafts between the aorta and coronary artery circulation; arterial (ITA) and venous grafts (SVG) have been widely used as bypass grafts. However, compared with ITA grafts, SVGs were reported to have high failure rates of 10% to 25% in the first 12 to 18 months,^[9] leading to recurrent angina and myocardial infarction.^[10] Therefore, follow-up evaluation of the graft flow should be especially important for SVGs. By analyzing the time–density curve of the SVG, our study revealed that dynamic cardiac CT provided functional information of the SVG and its significant correlation ($r = 0.87$) with TTFM. Furthermore, our results showed that the standard CT angiography that was derived from the dynamic CT data clearly demonstrated anatomical information on graft patency and the anastomosis for arterial and venous conduits. We believe that combined anatomical and functional assessment of the grafts by dynamic cardiac CT has the potential to enable early intervention for grafts with insufficient flow, although further studies should be conducted to verify this.

In this study, the dynamic cardiac CT and TTFM flow evaluations of the ITA grafts were not significantly correlated, suggesting the difficulty and complicated process of using dynamic cardiac CT to assess ITA flow measurement. One of the reasons may be the long course of the arterial grafts from the ascending aorta to the brachiocephalic artery and ITA. Furthermore, although we used wide-coverage CT (16 cm), the entire ITA could not be scanned by the dynamic cardiac CT. On the other hand, the long-term patency of ITA grafts is good, and we considered that the standard visual evaluation of the ITA grafts may be clinically adequate.

Radiation dose reduction is important during dynamic cardiac CT, because the dynamic scan requires repeated radiation exposures of the patients. Therefore, we used a low-kilovoltage scan plus model-based iterative reconstruction techniques.

From the viewpoint of clinical practice, the time required for both TTFM and CT is short (a few minutes to around 15 minutes), and it is considered to be highly practical. TTFM aims to evaluate intraoperative graft failure. On the other hand, dynamic cardiac CT may be useful for assessing postoperative graft failure. The combined use of these modalities may contribute to quality improvement and cost reduction in CABG patient management. Further verification is needed in this regard.

The usefulness of immunofluorescence imaging in the evaluation of intraoperative graft failure has been reported.^[11] It should be possible to improve the accuracy of intraoperative graft evaluation by combining quantitative functional evaluation by TTFM and qualitative morphological evaluation by immunofluorescence imaging. Furthermore, dynamic cardiac CT enables both qualitative morphological evaluation and quantitative functional evaluation as postoperative graft evaluation, which may improve the quality of patient management after CABG.

There were some limitations in our study. First, wide-coverage CT machine and a dedicated workstation are necessary for dynamic cardiac CT. Moreover, analysis of the dynamic data can be time-consuming, even for experienced radiological technologists or radiologists. Therefore, automatic analysis should be imperative. Second, our study population was small, and there was no patient with graft failure in this study. The relationship of dynamic cardiac CT and graft failure after CABG should be verified in future studies. Third, since sequential and composite grafts were excluded in this study, the validity of dynamic cardiac CT with these grafts is unknown. Lastly, we have not verified the difference in the dynamic cardiac CT findings between off-pump and on-pump CABG. Since the differences between off-pump and on-pump CABG in TTFM have been reported,^[12] there may be a difference in dynamic cardiac CT as well.

In conclusion, dynamic cardiac CT enabled quantitative evaluation of SVG flow, with good correlation with TTFM, in patients who underwent CABG surgery. Its possible application in clinical practice may be promising.

Author contributions

Conceptualization: Seitaro Oda, Ken Okamoto, Daisuke Utsunomiya.

Data curation: Daisuke Sakabe, Ken Okamoto.

Formal analysis: Seitaro Oda, Yoshinori Funama.

Investigation: Daisuke Sakabe, Yoshinori Funama, Masafumi Kidoh.

Methodology: Seitaro Oda, Yoshinori Funama.

Supervision: Toshihiro Fukui, Osamu Tominaga, Shingo Kato, Osamu Ikeda, Daisuke Utsunomiya.

Visualization: Masafumi Kidoh.

Writing – original draft: Daisuke Sakabe, Seitaro Oda.

Writing – review & editing: Toshihiro Fukui, Osamu Tominaga, Tsuneo Yamashiro, Osamu Ikeda, Daisuke Utsunomiya.

References

- [1] Melly L, Torregrossa G, Lee T, et al. Fifty years of coronary artery bypass grafting. *J Thorac Dis* 2018;10:1960–7.
- [2] Thuijs DJFM, Kappetein AP, Serruys PW, et al. Percutaneous coronary intervention versus coronary artery bypass grafting in patients with three-vessel or left main coronary artery disease: 10-year follow-up of the multicentre randomised controlled SYNTAX trial. *Lancet* 2019;394:1325–34.
- [3] Alkhouli M, Alqahtani F, Kalra A, et al. Trends in characteristics and outcomes of patients undergoing coronary revascularization in the United States, 2003-2016. *JAMA Netw open* 2020;3:e1921326.
- [4] Shahian DM, O'Brien SM, Sheng S, et al. Predictors of long-term survival after coronary artery bypass grafting surgery: results from the society of thoracic surgeons adult cardiac surgery database (The ASCERT Study). *Circulation* 2012;125:1491–500.
- [5] Jokinen JJ, Werkkala K, Vainikka T, et al. Clinical value of intra-operative transit-time flow measurement for coronary artery bypass grafting: a prospective angiography-controlled study. *Eur J Cardiothoracic Surg* 2011;39:918–23.
- [6] Kieser TM, Rose S, Kowalewski R, et al. Transit-time flow predicts outcomes in coronary artery bypass graft patients: A series of 1000 consecutive arterial grafts. *Eur J Cardio-thoracic Surg* 2010;38:155–62.
- [7] Sousa-Uva M, Neumann FJ, Ahlsson A, et al. 2018 ESC/EACTS Guidelines on myocardial revascularization. *Eur J Cardio-thoracic Surg* 2019;55:4–90.
- [8] Nagao M, Yamasaki Y, Kamitani T, et al. Quantification of coronary flow using dynamic angiography with 320-detector row CT and motion coherence image processing: Detection of ischemia for intermediate coronary stenosis. *Eur J Radiol* 2016;85:996–1003.
- [9] FitzGibbon GM, Kafka HP, Leach AJ, et al. Coronary bypass graft fate and patient outcome: angiographic follow-up of 5,065 grafts related to survival and reoperation in 1388 patients during 25 years. *J Am Coll Cardiol* 1996;28:616–26.
- [10] Watson PS, Hadjipetrou P, Cox SV, et al. Angiographic and clinical outcomes following acute infarct angioplasty on saphenous vein grafts. *Am J Cardiol* 1999;83:1018–21.
- [11] Alander JT, Kaartinen I, Laakso A, et al. A review of indocyanine green fluorescent imaging in surgery. *Int J Biomed Imaging* 2012;2012:940585.
- [12] Balacumaraswami L, Abu-Omar Y, Selvanayagam J, et al. The effects of on-pump and off-pump coronary artery bypass grafting on intraoperative graft flow in arterial and venous conduits defined by a flow/pressure ratio. *J Thorac Cardiovasc Surg* 2008;135:533–9.