

Management of iatrogenic renal arteriovenous fistula and renal arterial pseudoaneurysm by transarterial embolization

A single center analysis and outcomes

Hongjie Guo, MD, Chengen Wang, MD, PhD, Min Yang, MD, Xiaoqiang Tong, MD, Jian Wang, MD, Haitao Guan, MD, PhD, Li Song, MD, Yinghua Zou, MD*

Abstract

The purpose of this study was to evaluate the efficacy and safety of transarterial embolization (TAE) for iatrogenic renal arterial pseudoaneurysm and arteriovenous fistula at our center.

Our retrospective analysis included 27 patients who received TAE for iatrogenic renal arterial pseudoaneurysm and arteriovenous fistula between January 2006 and January 2016. Data on demographics, type of minimally invasive renal procedures, clinical manifestation, imaging features, embolization procedure, and perioperative details were collected. The technical and clinical success rates were analyzed. Furthermore, the changes in serum creatinine and eGFR before and after embolization were recorded and compared by *t* test.

The median time between iatrogenic renal injury and TAE was 3 days (range, 0–110 days), with most patients (24/27, 88.9%) receiving TAE within 14 days. Only 1 patient was diagnosed with renal artery pseudoaneurysm 110 days after laparoscopic partial nephrectomy. The technical and clinical success rates were 100% and 96.3%, respectively, with 1 patient requiring a second embolotherapy at the third postoperative day. No other patient required additional endovascular or surgical intervention due to recurrent hemorrhage. The mean serum creatinine before TAE was $92.8 \pm 25.3 \mu\text{mol/L}$ and after TAE, $96.1 \pm 27.7 \mu\text{mol/L}$ ($P = .095$). The eGFR of pre- and postembolization was $75.2 \pm 26.5 \text{ mL/min/1.73 m}^2$ and $72.5 \pm 26.2 \text{ mL/min/1.73 m}^2$ ($P = .16$). No severe complications were observed during follow-up.

This retrospective review demonstrated that TAE for the treatment of iatrogenic renal artery pseudoaneurysm and/or arteriovenous fistula was safe and associated with high technical and clinical success rate.

Abbreviations: LPN = laparoscopic partial nephrectomy, PCNL = percutaneous nephrolithotomy, PES = postembolization syndrome, PN = percutaneous nephrostomy, RAP = renal arterial pseudoaneurysm, RAVF = renal arteriovenous fistula, RB = renal biopsy, TAE = transarterial embolization, TOE = time to embolization.

Keywords: arteriovenous fistula, embolization, iatrogenic injury, pseudoaneurysm

1. Introduction

As minimally invasive renal procedures become widely available for the diagnosis and treatment of renal pathologies such as laparoscopic partial nephrectomy (LPN), percutaneous nephrostomy (PN), percutaneous nephrolithotomy (PCNL), and renal biopsy (RB), hemorrhagic complications became unavoidable.^[1]

Editor: Malindretos Pavlos.

HG and CW contributed equally to this work and share co-first authorship.

The authors have no funding and conflicts of interest to declare.

Department of Interventional Radiology and Vascular Surgery, Peking University First Hospital, Beijing, China.

* Correspondence: Yinghua Zou, Department of Interventional Radiology and Vascular Surgery, Peking University First Hospital, Xishiku Street No. 8, Beijing 100034, China (e-mail: zouyinghuabdy@sina.com).

Copyright © 2017 the Author(s). Published by Wolters Kluwer Health, Inc. This is an open access article distributed under the terms of the Creative Commons Attribution-Non Commercial-No Derivatives License 4.0 (CCBY-NC-ND), where it is permissible to download and share the work provided it is properly cited. The work cannot be changed in any way or used commercially without permission from the journal.

Medicine (2017) 96:40(e8187)

Received: 23 April 2017 / Received in final form: 30 August 2017 / Accepted: 8 September 2017

<http://dx.doi.org/10.1097/MD.00000000000008187>

Iatrogenic vascular lesions such as renal arteriovenous fistula (RAVF) and renal arterial pseudoaneurysm (RAP) are relatively rare hemorrhagic manifestations but potentially life-threatening and necessitate rapid clinical evaluation and treatment.^[2] Emergency transarterial embolization (TAE) is an effective treatment modality for the management of hemodynamically unstable patients with RAP or RAVF.^[3] Literatures focusing on the endovascular management of RAP and RAVF have been sparse, with most series involved small number of patients.^[4] We present clinical outcomes after TAE in a series of 27 patients with iatrogenic-induced RAP or RAVF.

2. Materials and methods

The institutional Ethical Committee of the Peking University First Hospital has approved this study, and the procedures were in accordance with the ethical standards. This is a retrospective review of TAE treatment of RAP and RAVF confirmed by renal angiography under digital subtraction, between January 2006 and January 2016. Medical records and imaging findings of 27 patients, including demographics (age and gender), type of minimally invasive renal procedures (LPN, PN, PCNL, or RB), clinical symptoms, angiographic features, technical success, clinical success, complications, renal function, and recurrent hemorrhage were reviewed.

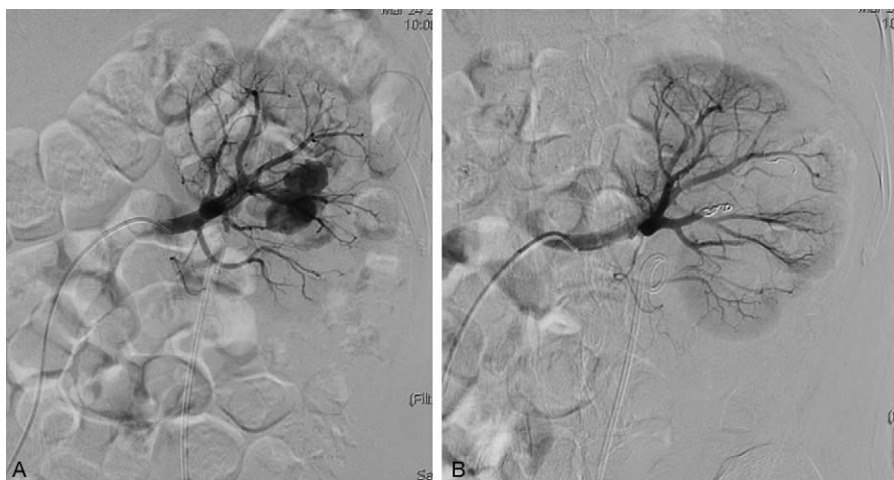


Figure 1. Renal angiography of RAP before and after TAE. (A) Angiography showed 2 pseudoaneurysms after PCNL. (B) Angiography after coil embolization revealed the disappearance of the RAP. PCNL = percutaneous nephrolithotomy, RAP = renal arterial pseudoaneurysm, TAE = transarterial embolization.

In all cases, renal angiography and selective arterial embolization were performed by senior endovascular interventionalists from the department of interventional radiology and vascular surgery. In all cases, the right femoral artery was punctured using a modified Seldinger technique under local anesthesia. A 5-Fr sheath was then placed into the common femoral artery. A global aortogram using a multiple-hole pigtail catheter was performed. This first evaluation allowed the identification of the main and accessory renal arteries. Occasionally, the site of hemorrhage could be seen on the initial flush aortogram. Selective renal angiograms were performed to demonstrate the vascular lesions (extravasation of contrast agent, formation of RAP or RAVF) and visualization of parenchymal staining and drainage veins. The main angiographic sign of a pseudoaneurysm was extravasation of contrast in the form of a sac. A super-selective microcatheter (Progreat, Terumo, Tokyo, Japan) was placed into the culprit vessel branch of the renal artery feeding the lesion. Platinum coil (Cook Medical Incorporated, Bloomington, IN) was the main embolization material used for RAP and RAVF. It was used to embolize the proximal feeding and distal emptying vessels and to avoid occluding the normal branches. The size and number of coils used depended on the size of the vessel to be embolized. The size should be slightly larger than the vessel to achieve complete embolization. The end point for embolization was the cessation of contrast extravasation or the early filling of the renal vein.

All patients were closely monitored after TAE at the time of hospitalization. The changes of symptoms, physical signs, and adverse events were recorded. The examination of bedside ultrasound or emergent CT scan was performed to determine whether there was new bleeding in the patients with worsening symptoms. The level of serum creatinine was tested to assess renal function after the endovascular procedure. The patients were examined by ultrasound to detect the recurrence of pseudoaneurysms or fistulas and renal infarction during follow-up.

On CT scans and angiograms, RAP was defined as a focal, saccular dilation of a renal artery with high attenuation on the arterial phase.^[5] RAVF was defined as early filling of a renal vein adjacent to an arterial vessel during the arterial phase.^[5] Technical success was defined as complete occlusion of the observed bleeding site and vascular anomaly on completion angiography.^[6] Clinical success was defined as absence of clinical

and imaging evidence of bleeding as determined by the resolution of gross hematuria, retroperitoneal bleeding, further decrease in hemoglobin and hypotension, after TAE.^[7] Postembolization syndrome (PES) was defined as fever, abdominal pain, nausea, or vomiting after TAE.^[8]

Data were analyzed using SPSS statistical software, version 19.0 (Armonk, NY). Nominal variables were summarized as counts and percentages, whereas continuous variables were reported as means and standard deviations (SD). If the variables were not normally distributed, they were reported as median. To compare groups, Student *t* test was used for continuous variables between 2 groups. Statistical significance was defined as $P < .05$

3. Result

There were 17 men and 10 women, with a mean age of 46.6 ± 15.8 years (range 9–73 years). Iatrogenic renal injuries consisted of LPN ($n=7$), PN ($n=2$), PCNL ($n=4$), and RB ($n=14$). The most common clinical manifestation of RAP/RAVF patients at presentation were gross hematuria, flank pain, and increased bloody drainage fluid.

Emergent CT or bedside ultrasound examination before therapeutic embolization was performed as the first imaging modality in all patients. A total of 27 patients underwent digital subtraction angiography and endovascular embolotherapy for iatrogenic renal hemorrhage: 16 RAP (Figs. 1 and 2), 7 RAVF, and 4 RAP+RAVF (Fig. 3). The demographic, clinical, and angiographic data were summarized in Table 1. The median interval between iatrogenic renal injury and TAE was 3 days (range, 0–110 days) with most patients (24/27, 88.9%) receiving embolization within 14 days. There was 1 patient in whom the injury was not detected until 110 days after LPN. After selective catheterization and identification of the vascular lesions and injured arterial branches, coil was used as the primary embolization material. In 5 patients (18.5%), hemostasis was not achieved with coils alone, thus additional gelatin sponge was deployed. Technical success was achieved in all patients (100%) with complete occlusion of the bleeding site and no embolization of normal arterial branches was seen. No endovascular procedure-related complications such as puncture-site hematoma, nontarget embolization, coil migration, or artery dissections were recognized. The hemoglobin and erythrocyte stopped

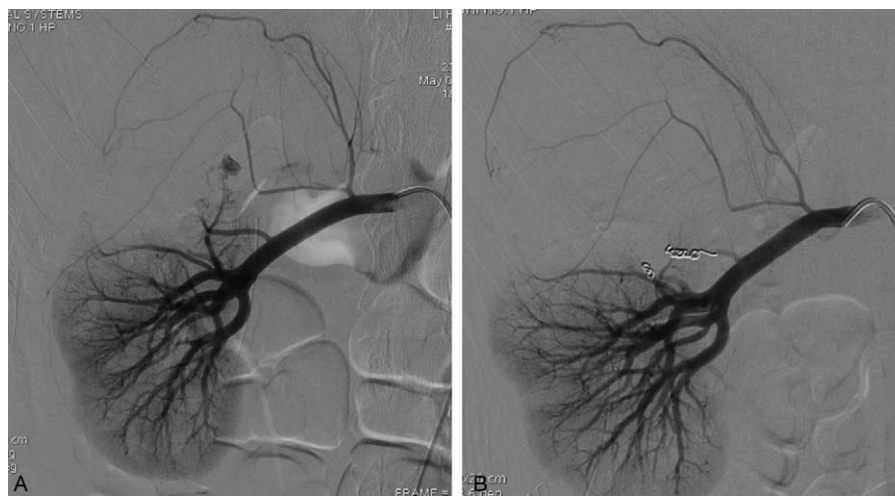

Figure 2. Renal angiography of RAP before and after TAE. (A) Angiography showed a pseudoaneurysm after LPN. (B) Angiography after coil embolization revealed the disappearance of the RAP. LPN = laparoscopic partial nephrectomy, RAP = renal arterial pseudoaneurysm, TAE = transarterial embolization.

decreasing after operation. The gross hematuria disappeared completely, and flank pain was relieved gradually. Clinical success was attained in 26 cases (96.3%) after the first TAE. Gross hematuria in 1 patient was not relieved after embolization and a second embolotherapy was performed on the third postoperative day. Subsequently, there was no recurrent hematuria or progression of hematoma identified in the patient. None of the remaining patients required additional endovascular or surgical intervention due to recurrent hemorrhagic episodes during follow-up period.

Excluding 5 patients with preoperative creatinine >300 μmol/L requiring temporary hemodialysis after embolization to prevent renal failure, the effect of TAE on renal function was assessed in 22 patients. The mean serum creatinine before and after TAE was 92.8 ± 25.3 and 96.1 ± 27.7 μmol/L, respectively ($P = .095$). The eGFR of pre- and postembolization was 75.2 ± 26.5 mL/min/1.73 m² and 72.5 ± 26.2 mL/min/1.73 m² ($P = 0.16$). Although decreased renal perfusion was detected due to embolization of hemorrhagic branch at angiography, TAE did not induce renal dysfunction as reflected by serum creatinine and eGFR levels. No

severe complications such as renal abscess formation and infectious peritonitis requiring emergency surgery or interventional treatment were encountered after embolotherapy. Four patients in this study developed PES and symptoms resolved by conservative therapy within 5 days.

4. Discussion

In recent years, with the increase of minimally invasive and complex renal surgeries and procedures such as RB, LPN, PCNL, and PN, the incidence of renal hemorrhage gradually increased.^[1] It is a life-threatening complication and usually related to injury of anterior and/or posterior segmental arteries, interlobular arteries, or arcuate arteries.^[1] The main reason for bleeding in our series was renal vasculature damage secondary to RB (14/27, 51.9%) and LPN (7/27, 25.9%). Although route of RB was carefully selected in areas devoid of blood vessels, mostly in the inferior pole of the kidney under the ultrasound guidance, distal branches of renal artery may still be damaged and result in hematuria, hemorrhage, and perirenal hematoma.^[1] The

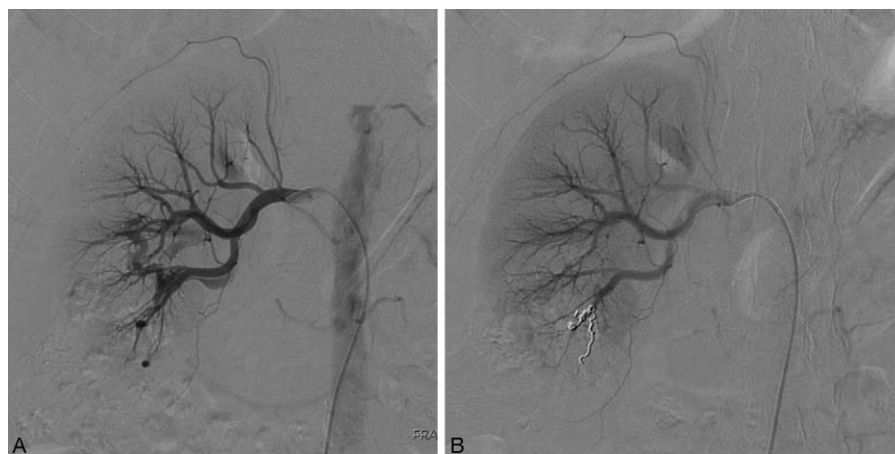

Figure 3. Renal angiography of RAVF and RAP before and after TAE. (A) Angiography showed early filling of the renal vein branches and 2 pseudoaneurysms after RB. (B) Following coil embolization the RAVF and RAP no longer existed. RAP = renal arterial pseudoaneurysm, RAVF = renal arteriovenous fistula, RB = renal biopsy, TAE = transarterial embolization.

Table 1**Characteristics of 27 patients undergoing TAE for iatrogenic RAP/RAVF.**

Characteristics	Value
Patients	27
Age, y	46.6 ± 15.8
Sex	
Male	17
Female	10
Surgery type	
LPN	7
PN	2
PCNL	4
RB	14
TOE (median, d)	3
Angiographic findings	
RAP	16
RAVF	8
RAP + RAVF	3

LPN = laparoscopic partial nephrectomy, PCNL = percutaneous nephrolithotomy, PN = percutaneous nephrostomy, RAP = renal arterial pseudoaneurysm, RAVF = renal arteriovenous fistula, RB = renal biopsy, TOE = time to embolization (days).

hemorrhage after LPN was mainly attributed to poor suturing. During PCNL or PN, percutaneous renal puncture and the establishment of percutaneous tract may damage the renal artery branch.^[9] These injuries might lead to pseudoaneurysm and/or arteriovenous fistula formation in the kidney.^[9,10]

RAP related to renal trauma, extracorporeal lithotripsy, PCNL, partial nephrectomy, PN, and RB have been reported.^[11] RAP was thought to arise from a transected or punctured renal artery branch that leaked into a hematoma cavity which was initially contained by the vascular adventitia, renal parenchyma, or renal fascia, and may even be encapsulated by a fibrous capsule.^[5,12] However, when blood extravasated into the extravascular space and connected with the collecting system and surrounding tissue, hematuria or perirenal hematoma may occur.^[12] RAVF, a related entity in which injury occurred in a renal artery branch and vein in close proximity, resulting in blood crossing from a higher pressure system directly into adjacent veins.^[5] Fistulization to collecting system or surrounding tissue may lead to clinical hemorrhage and cause drop in hemoglobin.^[5]

RAP and RAVF typically present immediately after renal vessel injury but delayed presentation after a couple of weeks or several months is not uncommon and may have severe consequences.^[13] As described in the literature, both conditions appeared most frequently few hours to days after renal surgery or procedure.^[13] Nevertheless, there were a few cases in which manifested clinically from 3 to 5 months after the procedure. Delayed hemorrhage after partial nephrectomy tended to be rare, and usually attributed to the manifestation of RAP. In this study, we found that RAP/RAVF occurred within 2 weeks after the operation in most of the patients (24/27, 88.9%), which was in agreement with the literature.^[4] However, there was 1 case with RAP diagnosed 110 days after LPN. This result suggested that RAP/RAVF had a peak occurrence within 2 weeks after renal operation and could be diagnosed when it developed within a short time after renal surgery. However, making the diagnosis of RAP/RAVF would be extremely difficult if the iatrogenic renal hemorrhage did not appear until 3 months or longer after renal surgery.^[4] Therefore, it is worth noting that postdischarge follow-up would be essential to discover potentially unexpected hemorrhage, and RAP/RAVF should still be considered even a

long time after the operation, especially when the patient experienced hematuria and flank pain.

If iatrogenic renal hemorrhage is suspected, imaging examinations including bedside ultrasound, emergent CT are necessary to make an immediate diagnosis. Renal angiography under DSA confirms the diagnosis of RAP/RAVF and demonstrates the exact location of the lesion.^[11] In our study, all patients underwent bedside ultrasound or emergent CT as the first imaging modality with the diagnosis of renal hemorrhage or perinephric hematoma. Ultrasonography was valuable for detecting hemorrhage and enhanced CT was useful to discover RAP/RAVF with the feature of a well-circumscribed dense collection of contrast medium or early visualization of draining veins in the arterial phase.^[13,14] Concerning the potential unfavorable impact from a load of contrast medium in those who may receive additional renal angiography and embolization if RAP/RAVF was confirmed,^[15] enhanced CT was not considered as the first diagnostic tool of choice in our center.

Conservative treatment had been ineffective in RAP/RAVF. Bookstein et al first reported a patient with RAVF after RB who was successfully treated by TAE.^[16] With the development of catheterization techniques and embolic materials, TAE can preserve most of the renal tissue, and its effectiveness and safety have improved. Super-selective renal artery embolization has become a primary method for the treatment of iatrogenic renal hemorrhage accompanied by RAP or RAVF.^[3] The final decision to embolize was made according to the clinical symptoms and imaging features. A total of 27 patients in our study underwent renal angiography and TAE with 100% technical success and 96.3% clinical success. As reported by Chiramel et al, embolization was performed in 53 patients with the manifestation of RAP or RAVF in the first renal angiography, of which 38 (71.7%) showed clinical resolution.^[17] Incomplete embolization with coils may explain the relatively lower resolution rate compared with that in our study. In another study including 21 patients receiving TAE for iatrogenic arterial kidney bleeding, Ierardi et al reported that the technical success rate was 100% and overall clinical success rate was 95%, which was in agreement with our results.^[6] TAE has proved to be an effective approach for iatrogenic renal hemorrhage. Although high clinical success rates after first embolization have been reported, repeat TAE was needed when the clinical course allowed. Thus, the overall clinical success rate of TAE and kidney preservation rate could be maximized. Our experience with TAE for iatrogenic renal hemorrhage accompanied by RAP or RAVF suggested that a second TAE could be performed after clinical failure.

Coils were systematically used to treat RAP/RAVF. They provided satisfactory occlusion of responsible vessels and facilitated the rapid cessation of blood flow into the pseudoaneurysm and adjacent veins.^[18] If hemostasis was not achieved with coils alone, additional gelatin sponge was used as a complement to maximize the embolic effect. Abdel-Aal et al reported a case of RAVF embolized by the Amplatzer Vascular Plug 2, but the efficacy and safety need further investigation in a larger series of patients with iatrogenic renal arterial lesions.^[19]

Parameters of renal function deserved more close attention from doctors at the time of hospitalization. TAE had little effect on renal function, and serum creatinine and eGFR levels usually returned to preoperative values.^[9] There were no statistical significant changes in serum creatinine and eGFR after selective TAE in our series. Only the contributing branches to the RAP/RAVF were embolized and the noninvolved renal parenchyma was spared. It was important to recognize acute renal failure. For

patients with preoperative creatinine $>300\mu\text{mol/L}$, temporary hemodialysis was started after TAE to maximally protect renal function and prevent renal failure during hospitalization. No renal failure was observed in any patient during the postembolization period. TAE may be a safe and effective procedure in patients with iatrogenic RAP/RAVF. In published data, many studies measured serum creatinine or eGFR levels to assess renal function, as we did in the present study. As reported by Strobl et al, eGFR value after TAE did not decrease significantly.^[17] In another retrospective series of patients with iatrogenic renal hemorrhages, no significant change in serum creatinine level was observed after embolotherapy.^[17]

The common manifestations after TAE included nausea, vomiting, fever, and abdominal pain which usually last <5 days and could be relieved with conservative treatment.

Limitations of this study include its retrospective nature and small sample size. RAVF and RAP are relatively rare hemorrhagic manifestations following minimally invasive renal procedures, and it is difficult to conduct a prospective randomized clinical trial with a large number of patients. To our knowledge, the number of cases in our study is larger than that in most literatures. In addition, the analysis of renal function is limited to serum creatinine and eGFR which are approximate indicators.

5. Conclusion

RAP and RAVF were relatively rare complications of minimally invasive renal procedures, including LPN, PN, PCNL, and RB. Hematuria, flank pain, and increased bloody drainage fluid were the most common manifestations of these iatrogenic injuries. Bedside ultrasound and emergent CT may rapidly diagnose hemorrhage, and renal angiography can confirm RAP/RAVF and demonstrate the exact location of the lesion. TAE was a preferred method for the treatment of iatrogenic RAP/RAVF with high cure rates and safety. There was no statistical significant increase in serum creatinine and eGFR after TAE.

References

- [1] Huang N, Yang WZ, Jiang N, et al. Application of Guglielmi detachable coils in embolization of iatrogenic renal hemorrhage. *Ann Vasc Surg* 2013;27:1081–7.
- [2] Breyer BN, Mcaninch JW, Elliott SP, et al. Minimally invasive endovascular techniques to treat acute renal hemorrhage. *J Urol* 2008; 179:2248–52.
- [3] Sam K, Gahide G, Soulez G, et al. Percutaneous embolization of iatrogenic arterial kidney injuries: safety, efficacy, and impact on blood pressure and renal function. *J Vasc Interv Radiol* 2011;22:1563–8.
- [4] Chen J, Yang M, Wu P, et al. Renal arterial pseudoaneurysm and renal arteriovenous fistula following partial nephrectomy. *Urol Int* 2016; [Epub ahead of print].
- [5] Hyams ES, Pierorazio P, Proteek O, et al. Iatrogenic vascular lesions after minimally invasive partial nephrectomy: a multi-institutional study of clinical and renal functional outcomes. *Urology* 2011;78:820–6.
- [6] Ierardi AM, Floridi C, Fontana F, et al. Transcatheter embolisation of iatrogenic renal vascular injuries. *Radiol Med* 2014;119:261–8.
- [7] Strobl FF, D'Anastasi M, Hinzpeter R, et al. Renal pseudoaneurysms and arteriovenous fistulas as a complication of nephron-sparing partial nephrectomy: technical and functional outcomes of patients treated with selective microcoil embolization during a ten-year period. *Rofo* 2016; 188:188–94.
- [8] Wang C, Yang M, Tong X, et al. Transarterial embolization for renal angiomyolipomas: A single centre experience in 79 patients. *J Int Med Res* 2017;45:706–13.
- [9] Zeng G, Zhao Z, Wan S, et al. Failure of initial renal arterial embolization for severe post-percutaneous nephrolithotomy hemorrhage: a multicenter study of risk factors. *J Urol* 2013;190:2133–8.
- [10] Ngo TC, Lee JJ, Gonzalgo ML. Renal pseudoaneurysm: an overview. *Nat Rev Urol* 2010;7:619–25.
- [11] Jain V, Ganpule A, Vyas J, et al. Management of non-neoplastic renal hemorrhage by transarterial embolization. *Urology* 2009;74: 522–6.
- [12] Saad DF, Gow KW, Redd D, et al. Renal artery pseudoaneurysm secondary to blunt trauma treated with microcoil embolization. *J Pediatr Surg* 2005;40:e65–7.
- [13] Tinto HR, Di Primio M, Tselikas L, et al. Selective arterial embolization of life-threatening renal hemorrhage in four patients after partial nephrectomy. *Diagn Interv Imaging* 2014;95:601–9.
- [14] Ghoneim TP, Thornton RH, Solomon SB, et al. Selective arterial embolization for pseudoaneurysms and arteriovenous fistula of renal artery branches following partial nephrectomy. *J Urol* 2011;185: 2061–5.
- [15] Aspelin P, Aubry P, Fransson SG, et al. Nephrotoxic effects in high-risk patients undergoing angiography. *N Engl J Med* 2003;348: 491–9.
- [16] Bookstein JJ, Goldstein HM. Successful management of postbiopsy arteriovenous fistula with selective arterial embolization. *Radiology* 1973;109:535–6.
- [17] Chiramel GK, Keshava SN, Moses V, et al. Clinical outcomes of endovascularly managed iatrogenic renal hemorrhages. *Indian J Radiol Imaging* 2015;25:380–90.
- [18] Leyon JJ, Littlehales T, Rangarajan B, et al. Endovascular embolization: review of currently available embolization agents. *Curr Probl Diagn Radiol* 2014;43:35–53.
- [19] Abdel-Aal AK, Elsabbagh A, Soliman H, et al. Percutaneous embolization of a postnephrectomy arteriovenous fistula with intervening pseudoaneurysm using the Amplatzer vascular plug 2. *Vasc Endovascular Surg* 2014;48:516–21.