

Case Report

Osteblastoma of the scaphoid bone – A rare case report

*Khodamorad Jamshidi^a, Dawood Jafari^a, Farid Najd Mazhar^{*b},
Hamidreza Modarresnejad^c*

Abstract

Osteblastoma is rarely found in the hand or wrist. Review of literature revealed that only five cases of osteblastoma have been reported in scaphoid bone. This paper presents a rare case of scaphoid osteblastoma with unusual course in a young patient and its treatment process.

KEYWORDS: Hand, osteblastoma, scaphoid, wrist.

JRMS 2009; 14(2): 135-138

Osteblastoma is a rare bone-forming neoplasm that occurs most commonly in adolescents and young adults in the second and third decades of life. Approximately 60% of the tumors occur in the spine and long tubular bones.^{1,2} It is rarely found in the hand or wrist; so the diagnosis of osteblastoma is rarely considered in the differential diagnosis of bone tumors of the hand.^{3,4} Review of literature revealed that only five cases of osteblastoma have been reported in scaphoid bone.^{3,5-8} We present a rare case of scaphoid osteblastoma with unusual course in a younger patient.

Case Report

An 11 year-old right-handed girl was referred to our clinic for her painful and swollen left wrist. The patient was a successful student and there was no relevant family history. She had painful wrist without swelling for past two years and had no history of antecedent trauma. The pain was constant, dull and more intense at nights and was not activity-related, so she referred to a health medical center where the

general practitioner took an X-ray from her left wrist and referred her to an orthopaedic surgeon because a lytic lesion was in her carpal scaphoid bone (Figure 1). At that time, the patient was advised for a complete work up but her parents refused further investigation. In spite of constant pain, the patient did not take any pain killer or anti inflammatory agent to subside the pain. Gradually the wrist started to

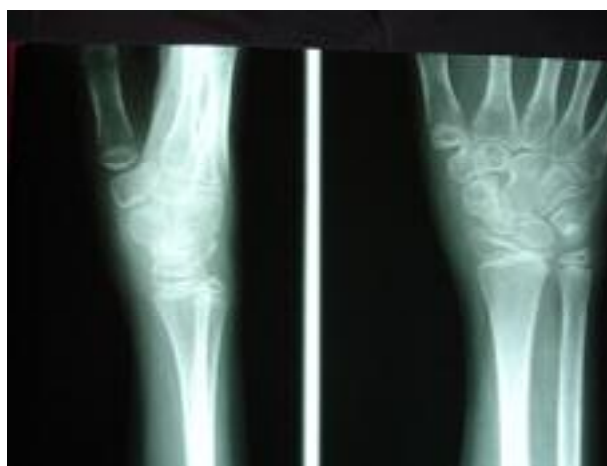

Figure 1. The first X-ray, two years before surgery

^a Assistant Professor of Orthopaedic Surgery, Iran University of Medical Sciences, Tehran, Iran.

^b Hand Surgery Fellow, Iran University of Medical Sciences, Department of Hand Surgery, Shafa Yahyaian Rehabilitation Center, Baharestan Sq., Tehran, Iran.

^c Orthopaedic Surgeon, Iran University of Medical Sciences, Tehran, Iran.

* Corresponding Author

E-mail: najdmazhar@yahoo.ca

swell and pain became worse and finally two years later she was referred and admitted to an orthopaedic surgery unit in a university hospital where a complete work up was done. At this time, left wrist was swollen, there was a tumor with hard consistency on dorsal and wrist palmar especially on radial side with mild tenderness. The wrist was stiff with minimal motion range and grip power was decreased. Physical examination otherwise was normal. New X-ray revealed marked osteopenia of the wrist and adjacent bones and an osteolytic expansile lesion with opacities in its matrix in the scaphoid area (Figure 2).

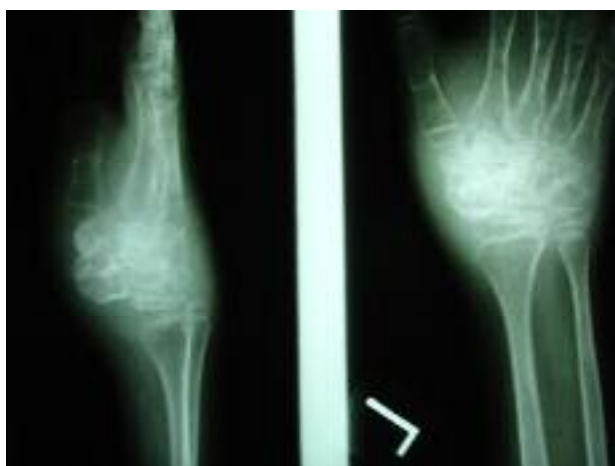

Figure 2. Preoperative X-ray two years after first X-ray

Bone scan showed increased uptake in the scaphoid area. CT scan revealed lytic expansile lesion with internal calcification in scaphoid (Figure 3).

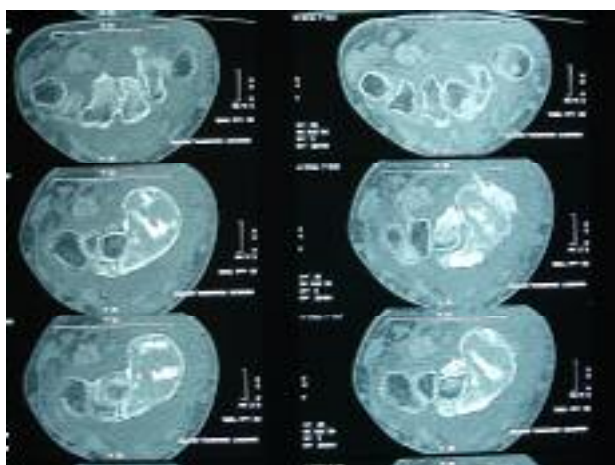


Figure 3. CT Scan of the wrist, axial view

MRI of wrist reported a relatively well-defined heterosignal mass lesion in the scaphoid bone, which was surrounded by edema in adjacent soft tissues with central signal void foci, which could be calcification, hemosiderin or flow void vascular structures and no evidence of fluid-fluid level. Chest X-ray and blood tests were normal. The patient underwent a biopsy through volar approach and specimen sent to histology revealing osteoblastoma. Once again her parents refused further operation at that hospital. Four weeks later the patient was admitted to our center. This time the pain was more intense and the wrist was swollen and stiff and there was a longitudinal scar on volar radial side of the wrist. The tumor was palpable on volar and dorsal of the wrist radial side. After consultation with parents, we opened the joint through volar approach with incorporating the scar of previous incision. The anterior capsule was invaded by red tan tumor of scaphoid but other carpal bones were unaffected. A 2×2.5×2 cm tumor along the affected soft tissue was removed (Figure 4).

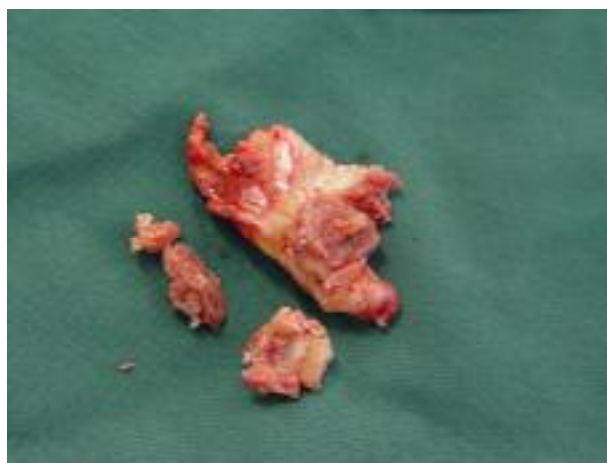

Figure 4. Excised tumor

Again the histologic report indicated osteoblastoma (Figure 5). We did not disturb radial collateral ligament of the wrist. The palmaris longus tendon was placed in the void space and strip of flexor carpi radialis attached to its insertion was used to reinforce the anterior aspect of joint by passing it through a hole in the

distal radius. Then the wrist was immobilized in long arm cast after insertion of a transarticular pin. Six weeks later, we opened the cast and removed the pin to start physical therapy (Figure 6,7). After 12 weeks of physical therapy, the patient was pain free and the wrist was stable in clinical examination. The wrist motion range was 20 degrees in extension, 15 degrees in flexion, 5 degrees radial deviation and 10 degrees ulnar deviation. The patient will have long term follow up in regard to the aggressive nature of the tumor.

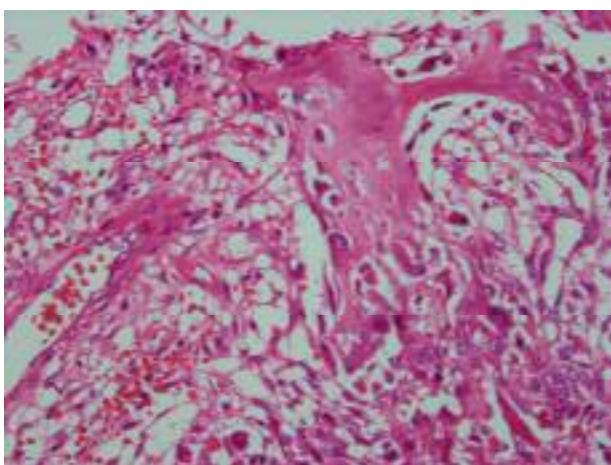


Figure 5. Histology of the excised tumor

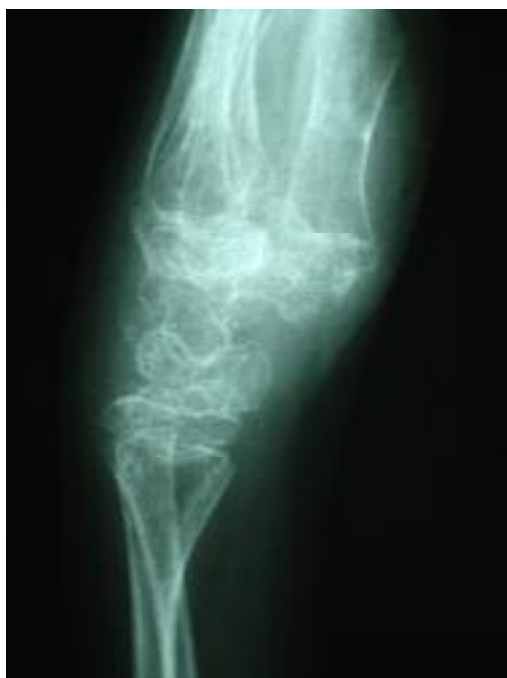

Figure 6. Lateral X-ray of the left wrist three months post surgery

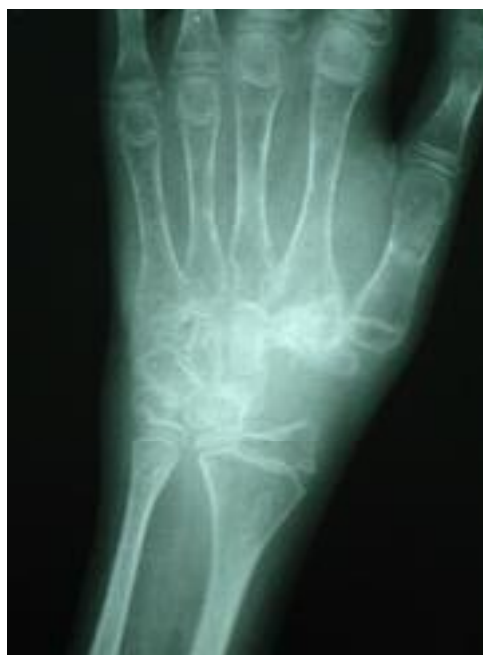

Figure 7. Anteroposterior X-ray of the left wrist three months post surgery

Discussion

Osteblastoma is an uncommon bone tumor which resembles osteoid osteoma but its larger size (greater than 2 cm) and progressive nature make it significantly different.⁹ Pain is also more prominent in osteoid osteoma. Osteoid osteoma elicits a profound osteoblastic response in surrounding medullary and cortical bone. This gives the characteristic picture of sclerosis around a lucent nidus.⁹ In contrast, in osteblastoma the pain is dull, persistent and less localized so the clinical course may be longer than osteoid osteoma, and pain may be present for periods ranging from weeks to years before medical attention is sought.² In radiography, osteblastoma is eccentric and expansile lesion with an intact surrounding shell of bone. Osteblastoma easily recurs after incomplete surgical removal, but even incomplete curettage can affect a cure in a great percentage of cases.^{1,2} Osteblastoma rarely occurs in the hand.⁶ It has been previously reported in metacarpal and also in the carpal bones like hamate.^{4,10} Review of the literature revealed only five cases of this tumor in the scaphoid bone.^{3,5-8} All of the previously reported cases of this tumor were presented with pain but they have

been treated in different ways. The first case of the scaphoid osteoblastoma was presented in 1993 in a 31 year-old woman with long standing history of wrist pain.⁶ After curettage and bone grafting, there was no recurrence during follow up period. In another case of the scaphoid osteoblastoma, the authors emphasized the rarity of osteoblastoma in hand and wrist localizations and recommended pathological examination before treatment due to lack of distinctive clinical and radiological features.⁵ In that case, the rapidly aggressive progression, similar to a malignant tumor, led the authors to do radical treatment with Scaphoidectomy. A case of the carpal scaphoid osteoblastoma was also presented in 2002.⁷ The authors stated that review of the literature revealed

two more cases that have been previously reported. They presented the diagnostic difficulties. Their case was treated by proximal row carpectomy and tendon transfers for wrist stabilization. There is also a case of a scaphoid osteoblastoma in a 13 year-old girl with curettage of tumor,⁸ in which the patient became disease free after ten years follow up. The last reported case of the scaphoid osteoblastoma was treated successfully by curettage of the tumor and bone grafting.³

We believe that the case we are presenting here is unique in its unusual course, lower age of involvement, the size of the tumor and the treating procedure compared to the reported similar cases of the scaphoid osteoblastoma.

Conflict of Interest

Authors have no conflicts of interest.

Authors' Contributions

KhJ carried out the diagnosis, treatment, post operative follow up experiments and participated in manuscript preparation.

DJ provided assistance for diagnosis, treatment and participated in manuscript preparation.

FNM provided assistance for treatment, post operative follow up experiment and participated in manuscript preparation.

HM provided assistance for post operative follow up.

All authors have read and approved the content of the manuscript. They participated in editing and revision processing.

References

1. Kroon HM, Schurmans J. Osteoblastoma: clinical and radiologic findings in 98 new cases. *Radiology* 1990; 175(3):783-90.
2. Marsh BW, Bonfiglio M, Brady LP, Enneking WF. Benign osteoblastoma: range of manifestations. *J Bone Joint Surg Am* 1975; 57 (1): 1-9.
3. Meade RA, Allende CA, Tsai TM. Osteoblastoma of the scaphoid: a case report. *J Surg Orthop Adv* 2005; 14(3):125-8.
4. Mosher JF, Peckham AC. Osteoblastoma of the metacarpal: A case report. *J Hand Surg [Am]* 1978; 3(4):358-60.
5. Ragois P, Leclerc P, Hallonet D. Aggressive osteoblastoma of the carpal scaphoid bone. *Rev Chir Orthop Reparatrice Appar Mot* 2000; 86(1):94-7.
6. Fanning JW, Lucas GL. Osteoblastoma of the scaphoid: a case report. *J Hand Surg [Am]* 1993; 18(4):663-5.
7. Xarchas KC, Leviet D. Osteoblastoma of the carpal scaphoid frequency and treatment. *Acta Orthop Belg* 2002; 68(5):532-6.
8. Castello JR, Garro L, San Miguel P, Campo M. Osteoblastoma of the scaphoid-long-term results following curettage: a case report. *J Hand Surg [Am]* 1996; 21(3):426-7.
9. Healey JH, Ghelman B. Osteoid osteoma and osteoblastoma. Current concepts and recent advances. *Clin Orthop Relat Res* 1986;(204):76-85.
10. Apergis E, Tsamouri M, Theodoratos G, Maris I, Antoniou N. Osteoblastoma of the hamate bone: a case report. *J Hand Surg [Am]* 1993; 18(1):137-40.