

## Clinical Significance of Occult Micrometastases in Axillary Lymph Nodes in “Node-negative” Breast Cancer Patients

Yoshihisa Umekita,<sup>1</sup> Yasuyo Ohi,<sup>1</sup> Yoshiatsu Sagara<sup>2</sup> and Hiroki Yoshida<sup>1</sup>

<sup>1</sup>Department of Pathology, Faculty of Medicine, Kagoshima University, 8-35-1 Sakuragaoka, Kagoshima 890-8520 and <sup>2</sup>Sagara Hospital, 3-31 Matsubara-cho, Kagoshima 892-0833

The most important subgroup of breast cancer patients for whom reliable prognostic indicators are needed is women without axillary lymph node metastases. We evaluated the clinical significance of occult micrometastases in axillary lymph nodes in 148 consecutive “node-negative” breast cancer patients. The median age of the patients at surgery was 52 years and the median follow-up period after surgery was 98.5 months. Occult micrometastases were detected in 21 of 148 patients (14.2%) by means of immunohistochemical analysis using AE1/3 antibody and a single unstained section after routine histopathological examination. Log-rank tests indicated that the 7-year disease-free survival (DFS) and overall survival (OS) rates by Kaplan-Meier methods were significantly better in patients without occult micrometastases than in patients with occult micrometastases [DFS, 93% versus 71% ( $P=0.0009$ ); OS, 96% versus 76% ( $P=0.0001$ )]. According to Cox’s multivariate analysis, the presence of occult micrometastases had the most significant effect on DFS ( $P=0.0053$ ) and OS ( $P=0.0035$ ). These findings suggest that the presence of occult micrometastases is an independent and significant predictor of clinical outcome, and that their immunohistochemical detection after routine histopathological examination is useful for selecting the “node-negative” breast cancer patient subgroup at high risk for relapse and death.

Key words: Immunohistochemistry — Breast cancer — Micrometastases

It is well known that axillary lymph node status is the most important prognostic factor in primary breast cancer patients. However, it has also been shown that 15–20% of patients without lymph node metastases assessed by routine histological examination relapse or die within 10 years.<sup>1,2</sup> Thus, detecting subgroups of “node-negative” patients at high risk for relapse or death is important for providing adjuvant therapy. To date, one of the most intensely investigated prognostic factors in “node-negative” breast-cancer patients has been occult micrometastases in axillary lymph nodes, which cannot be detected by routine histopathological analysis. A number of studies have examined the prognostic significance of occult micrometastases in axillary lymph nodes and have reported conflicting data.<sup>3–6</sup> Our aim in this study is to determine whether the presence of occult micrometastases is an independent prognostic indicator in “node-negative” breast cancer patients.

### MATERIALS AND METHODS

**Patients** We selected 148 female patients with primary breast carcinoma who had been consecutively treated by modified radical mastectomy (126 patients) or breast-conserving surgery (22 patients) at Sagara Hospital (Kagoshima) between November 1990 and December 1993. Their ages ranged from 26 to 78 years (median: 51.9 years).

All patients were followed up for 15 to 126 months post-operatively. The median follow-up time was 98.5 months. The follow-up was conducted at 1-month intervals during the first year, at 3-month intervals for the next 2 years and at 6-month intervals thereafter. Metastases were evaluated by physical examination and laboratory tests, including serum tumor marker, X-ray computed tomography, ultrasonography and radioisotope scanning. All patients were given adjuvant endocrine therapy and 91 patients received adjuvant chemotherapy. All patients were diagnosed as negative for axillary lymph node involvement by conventional histological examination. The original hematoxylin-eosin-stained slides were re-examined to confirm the negative nodal status. None of the patients showed signs of distant metastases at the time of operation. Steroid hormone receptor status was determined by the dextran-coated charcoal separation method.<sup>7</sup> A concentration greater than 14 fmol/mg for estrogen receptor (ER) or 13 fmol/mg for progesterone receptor (PgR) was considered positive. Breast cancer recurred in 14 patients (9.4%) and 12 patients (8.1%) died due to metastasis during the follow-up period. Deaths from unrelated causes were censored for the purposes of survival analyses.

**Histology** All breast cancers were histologically classified as invasive ductal carcinoma (IDC) according to the criteria of the World Health Organization. Histological grade was determined using slightly modified criteria from Bloom and Richardson’s method.<sup>8</sup>

**Immunohistochemistry** Pieces of tumor and axillary

E-mail: umekita@m2.kufm.kagoshima-u.ac.jp

lymph nodes were fixed in 10% neutrally buffered formalin, and embedded in paraffin. After blocking of endogenous peroxidase activity, deparaffinized sections (3  $\mu$ m thick) were pretreated in 1 mM ethylenediaminetetraacetic acid buffer (pH 8.0) by microwaving (500 W, full power) for 15 min. After cooling for 60 min, sections were incubated with primary antibodies overnight at 4°C in a moist chamber. Immunostaining was performed using streptavidin-horseradish peroxidase conjugate (Zymed, South San Francisco, CA) as described previously.<sup>9)</sup> The primary antibodies used were monoclonal anti-cytokeratin antibody, AE1/3 (clone, AE1 and AE3; DAKO, Carpinteria, CA) diluted 1:1000. Negative controls were performed using non-immune serum instead of the primary antibody. Non-metastatic lymph nodes in the same sections also served as negative controls. Metastatic breast carcinoma samples to the axillary lymph nodes by histological examination were used as positive controls for AE1/3. Staining results were assessed without knowledge of the outcome data by two pathologists (Y. U. and Y. O.).

**Statistical analysis** Analyses of patients and tumor characteristics were performed using the  $\chi^2$  test. Actuarial curves for disease-free survival (DFS) and overall survival (OS) were calculated by the Kaplan-Meier technique.<sup>10)</sup> DFS and OS were calculated from the date of first surgery to the date of clinical or pathological relapse or death. The significance of differences in DFS and OS were tested with the log-rank test. To account for the effect of known prognostic factors, differences in DFS and OS were adjusted with Cox's proportional-hazards model.<sup>11)</sup> All statistical analyses were performed with a computer program package (Dr SPSS 8.0J, SPSS Japan Inc., Tokyo). The cut-off for significance was taken as  $P=0.05$ .

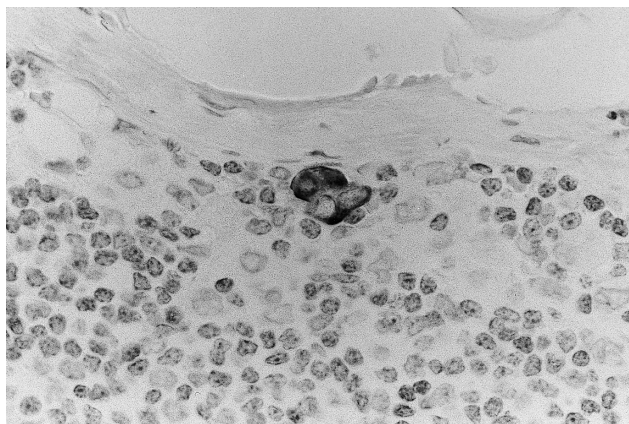


Fig. 1. Immunohistochemical staining with AE1/3 antibody. A few clusters of carcinoma cells in the parenchyma of the lymph nodes showed cytoplasmic staining (original,  $\times 230$ ).

**RESULTS**

A total of 1454 axillary lymph nodes were investigated. The average number of lymph nodes examined per patient was 9.8. Occult micrometastases were defined as cancer cells in lymph nodes which could not be detected by hematoxylin and eosin staining, but could be detected by immunohistochemistry, and were morphologically consistent with cancer cells. Occult micrometastases were observed in 21 of 148 patients (14.2%). The number of lymph nodes with occult micrometastases was one in all cases. Small emboli of carcinoma cells in the subcapsular sinuses of the lymph nodes or a few clusters of carcinoma cells in the lymph node parenchyma (Fig. 1) were identified. The size of micrometastatic foci was less than 0.1 mm in all cases. There was no significant association between the presence of occult micrometastases and tumor size, histological grade, hormone receptor status, or menopausal status (Table I). At 5 and 7 years, the respective DFS rates for all patients were 94% and 90%, whereas their OS rates were 97% and 94%, respectively. In patients with occult micrometastases, 6 of 21 (28%) relapsed and 6 of 21 (28%) died. In patients without occult micrometastases, 8 of 127 (6.3%) relapsed and 6 of 127 (4.7%) died. The seven-year DFS rate was 93% in patients with-

Table I. Association between Micrometastases and Clinicopathological Parameters

	Micrometastases		P value
	Present (21 tumors)	Absent (127 tumors)	
Tumor size (mm)			
0-20	8	54	NS
21-50	11	69	
51-100	2	4	
ER			
positive	14	69	NS
negative	7	58	
PgR			
positive	10	62	NS
negative	11	65	
Histological grade			
I	4	32	NS
II	13	58	
III	4	37	
Menopausal status			
pre	13	59	NS
post	8	68	

NS: not significant.

out occult micrometastases and 71% in patients with occult micrometastases. The seven-year OS rate was 96% in patients without occult micrometastases and 76% in patients with occult micrometastases. Univariate analysis showed significant differences in DFS ( $P=0.0009$ ) and OS ( $P=0.0001$ ) according to the presence of occult micrometastases (Fig. 2). Cox's multivariate analysis demonstrated that the presence of occult micrometastases was the only retained variable in OS ( $P=0.0035$ ) and DFS ( $P=0.0053$ ) (Table II).

## DISCUSSION

Since the first description of the correlation between immunohistochemical detection of occult lymph node metastases and clinical outcome in breast cancer patients,<sup>12</sup> several studies investigating the clinical significance of occult metastases have been reported. Hainsworth *et al.* reported that the presence of occult metastases in two or more nodes was associated with a reduced DFS and OS.<sup>4</sup> Cote *et al.* reported that occult lymph node metastasis detected by immunohistochemistry was an independent and highly significant predictor of relapse in postmenopausal breast cancer patients, but not in premenopausal patients.<sup>3</sup> It was originally reported that occult lymph node metastasis detected by immunohistochemistry was an independent predictor of relapse and death.<sup>12</sup> However, it was later suggested that the value of immunohistochemical detection was debatable in IDC with a longer follow-up study, since it was less well correlated with OS.<sup>6</sup> In addition, Nasser *et al.* reported that occult metastases had no significant prognostic impact as a group.<sup>5</sup> Thus, the clinical significance of the occult micrometastases in IDC detected by immunohistochemistry is still controversial. The positivity of occult micrometastases in our study was lower than that of Cote *et al.* (19%, 112/595),<sup>3</sup> and higher than that of De Mascarel *et al.* (10%, 13/129)<sup>6</sup> and Hainsworth (9.3%, 31/333),<sup>4</sup> but almost the same as that of Nasser *et al.* (14%, 22/159).<sup>5</sup> These discrepancies may be attributed to differences in methodology of immunohistochemistry, including the type of antibodies used, cohort sizes, follow-up times, patient characteristics and definition of micrometastases. As CAM5.2, a murine monoclonal antibody that is specific for human keratin polypeptides corresponding to component numbers 8 and 18, has been reported to have a staining reaction to fibroblastic reticulum cells of human lymph nodes,<sup>13</sup> we used AE1/3 antibody, which is a widely used cost-effective antibody. In addition, it has been suggested that Japanese invasive breast cancer patients without lymph node metastasis tend to show a survival advantage compared to their Caucasian counterparts.<sup>14</sup> Indeed, the respective DFS and OS rates of all patients at 5 years in our study were 94% and 97%, being similar to the rates reported by Saimura *et al.*

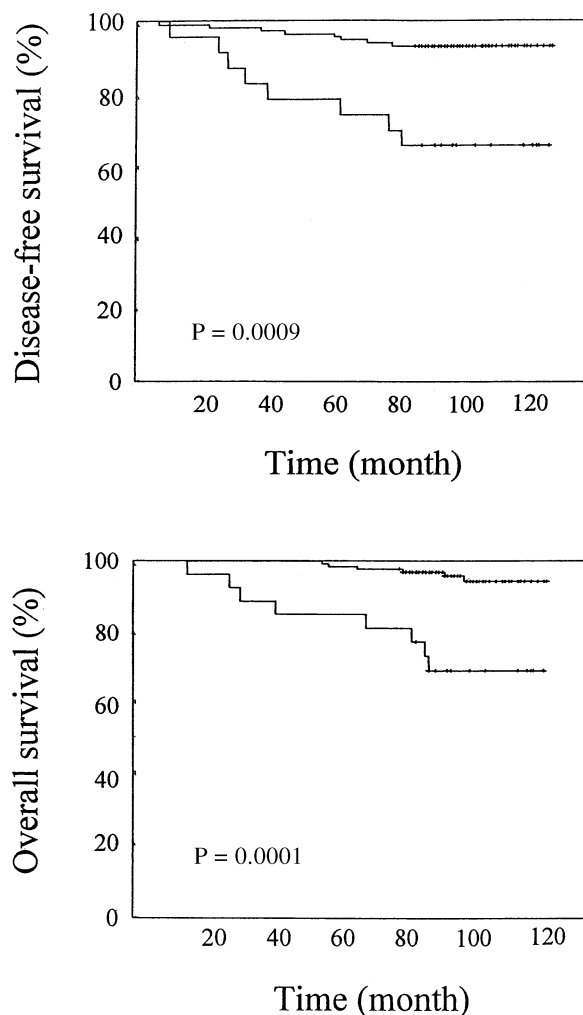


Fig. 2. DFS and OS curves according to the presence of occult micrometastases in invasive ductal carcinoma patients diagnosed as “node-negative.” There were 21 patients in the group with occult micrometastases (lower curve), and 127 patients in the group without occult micrometastases (upper curve).

Table II. Cox's Multivariate Analysis of DFS and OS in “Node-negative” Breast Cancer Patients

Prognostic factor	DFS		OS	
	Relative risk	P value	Relative risk	P value
Tumor sizes		0.1187		0.1042
Histological grade		0.9747		0.7106
Micrometastases	4.8113	0.0053	5.7518	0.0035
ER		0.6226		0.804
PgR		0.9423		0.9938
Menopausal status		0.4936		0.882

Relative risks are presented only for the retained variables.

(DFS, 90.8%; OS, 93.9%).<sup>14)</sup> To our knowledge, our present investigation is the second, after that of Trojani *et al.*,<sup>12)</sup> to report that occult micrometastasis detected by immunohistochemistry is a highly significant and independent predictor of shorter DFS and OS, regardless of the size or number of micrometastases and menopausal status. Recently, Masuda *et al.* reported that the presence of micrometastases in axillary lymph nodes detected by reverse transcription-PCR (RT-PCR) methods was an independent and significant predictor of clinical outcome in Japanese breast cancer patients.<sup>15)</sup> Our findings support their result. Although the detection rates of occult micrometastases by RT-PCR methods seem to be higher than by immunohistochemistry, we propose that immunohistochemical detection of occult micrometastases is a less cumbersome, expensive and time-consuming method than RT-PCR, and can be recommended as a routine procedure in many laboratories. However, routine pathological examination of lymph nodes usually examines only half of a lymph node, and the remainder is discarded. Therefore, we still may not be

able to detect all occult micrometastases. Serial macroscopic sectioning in combination with immunohistochemistry may improve the detection rates of occult micrometastases.<sup>6)</sup> Although a larger series and longer follow-up are required, our present investigation suggests that immunohistochemical detection of occult micrometastases in axillary lymph nodes after routine pathological examination could be useful in identifying the “node-negative” breast cancer patients subgroup at high risk for relapse and death.

#### ACKNOWLEDGMENTS

The authors are grateful to M. Souda and T. Kodama for their assistance with the immunohistochemical analysis. This work was supported in part by a grant (13670181) from the Ministry of Education, Culture, Sports, Science and Technology, Japan and a grant from the Kodama Memorial Fund for Medical Research.

(Received November 20, 2001/Revised March 29, 2002/  
Accepted April 5, 2002)

#### REFERENCES

- 1) Fisher, B., Bauer, M., Wickerham, L., Redmond, C. K. and Fisher, E. R. Relation of number of positive axillary nodes to the prognosis of patients with primary breast cancer: an NSABP update. *Cancer*, **52**, 1551–1557 (1983).
- 2) Rosen, P. P., Saigo, P. E., Braun, D. W., Weathers, E. and Depalo, A. Predictors of recurrence in stage I (T<sub>1</sub>N<sub>0</sub>M<sub>0</sub>) breast carcinoma. *Ann. Surg.*, **193**, 15 (1981).
- 3) Cote, R. J., Peterson, H. F., Chaiwun, B., Gelber, R. D., Goldhirsch, A., Castiglione-Gertsch, M., Gusterson, B. and Neville, A. M. (International Breast Cancer Study Group). Role of immunohistochemical detection of lymph node metastases in management of breast cancer. *Lancet*, **354**, 896–900 (1999).
- 4) Hainsworth, P. J., Tjandra, J. J., Stillwell, R. G., Machet, D., Henderson, M. A., Rennie, G. C., Mckenzie, I. F. C. and Bennett, R. C. Detection and significance of occult metastases in node-negative breast cancer. *Br. J. Surg.*, **80**, 459–463 (1993).
- 5) Nasser, I. A., Lee, A. K. C., Bosari, S., Saganich, R., Heatley, G. and Silverman, M. L. Occult axillary lymph node metastases in “node-negative” breast carcinoma. *Hum. Pathol.*, **24**, 950–957 (1993).
- 6) De Mascarel, I., Bonichon, F., Coindre, J. M. and Trojani, M. Prognostic significance of breast cancer axillary lymph node micrometastases assessed by two special techniques: reevaluation with longer follow-up. *Br. J. Cancer*, **66**, 523–527 (1992).
- 7) McGuire, W. L., De La Garza, M. and Chammnes, G. C. Evaluation of estrogen receptor assays in human breast cancer tissue. *Cancer Res.*, **37**, 637–639 (1977).
- 8) Elston, C. W. and Ellis, I. O. Pathological prognostic factors in breast cancer. I. The value of histological grade in breast cancer: experience from a large study with long-term follow-up. *Histopathology*, **19**, 403–410 (1991).
- 9) Umekita, Y., Sagara, Y. and Yoshida, H. Estrogen receptor mutations and changes in estrogen receptor and progesterone receptor protein expression in metastatic or recurrent breast cancer. *Jpn. J. Cancer Res.*, **89**, 27–32 (1998).
- 10) Kaplan, E. L. and Meier, P. Nonparametric estimation from incomplete observations. *J. Am. Stat. Assoc.*, **53**, 457–481 (1958).
- 11) Cox, D. R. Regression models and life-tables. *J. R. Stat. Soc.*, **34**, 187–220 (1972).
- 12) Trojani, M., De Mascarel, I., Bonichon, F., Coindre, J. M. and Delsol, G. Micrometastases to axillary lymph nodes from carcinoma of breast: detection by immunohistochemistry and prognostic significance. *Br. J. Cancer*, **55**, 303–306 (1987).
- 13) Doglioni, C., Dell’Orto, P., Zanetti, G., Iuzzolino, P., Coggi, G. and Viale, G. Cytokeratin-immunoreactive cells of human lymph nodes and spleen in normal and pathological conditions: an immunohistochemical study. *Virchows Arch. Pathol. Anat.*, **416**, 479–490 (1990).
- 14) Saimura, M., Fukutomi, T., Tsuda, H., Sato, H., Miyamoto, K., Akashi-Tanaka, S. and Nanasawa, T. Prognosis of a series of 763 consecutive node-negative invasive breast cancer patients without adjuvant therapy: analysis of clinicopathological prognostic factor. *J. Surg. Oncol.*, **71**, 101–105 (1999).
- 15) Masuda, N., Tamaki, Y., Sakita, I., Ooka, M., Ohnishi, T., Kadota, M., Aritake, N., Okubo, K. and Monden, M. Clinical significance of micrometastases in axillary lymph nodes assessed by reverse transcription-polymerase chain reaction in breast cancer patients. *Clin. Cancer Res.*, **6**, 4176–4185 (2000).