

Received: 2016.12.31  
Accepted: 2017.01.27  
Published: 2017.04.09

## Basal Ganglia Calcification with Tetanic Seizure Suggest Mitochondrial Disorder

### Authors' Contribution:

Study Design A  
Data Collection B  
Statistical Analysis C  
Data Interpretation D  
Manuscript Preparation E  
Literature Search F  
Funds Collection G

ABCDEF 1 **Josef Finsterer**  
BDF 2 **Barbara Enzelsberger**  
BDF 3 **Adam Bastowansky**

1 Department of Neurology, Krankenhaus Rudolfstiftung, Vienna, Austria  
2 2<sup>nd</sup> Department of Medical, Cardiology and Intensive Care Medicine, Krankenhaus Rudolfstiftung, Vienna, Austria  
3 Department of Radiology, Krankenhaus Rudolfstiftung, Vienna, Austria

**Corresponding Author:** Josef Finsterer, e-mail: [fifigs1@yahoo.de](mailto:fifigs1@yahoo.de)

**Conflict of interest:** None declared

**Patient:** Female, 65  
**Final Diagnosis:** Mitochondrial disorder  
**Symptoms:** Headache • tetanic seizure  
**Medication:** Diazepam  
**Clinical Procedure:** Admission  
**Specialty:** Neurology

**Objective:** Challenging differential diagnosis

**Background:** Basal ganglia calcification (BGC) is a rare sporadic or hereditary central nervous system (CNS) abnormality, characterized by symmetric or asymmetric calcification of the basal ganglia.

**Case Report:** We report the case of a 65-year-old Gypsy female who was admitted for a tetanic seizure, and who had a history of polyneuropathy, restless-leg syndrome, retinopathy, diabetes, hyperlipidemia, osteoporosis with consecutive hyperkyphosis, cervicalgia, lumbalgia, struma nodosa requiring thyroidectomy and consecutive hypothyroidism, adipositas, resection of a vocal chord polyp, arterial hypertension, coronary heart disease, atheromatosis of the aorta, peripheral artery disease, chronic obstructive pulmonary disease, steatosis hepatis, mild renal insufficiency, long-term hypocalcemia, hyperphosphatemia, impingement syndrome, spondylarthrosis of the lumbar spine, and hysterectomy. History and clinical presentation suggested a mitochondrial defect which also manifested as hypoparathyroidism or Fanconi syndrome resulting in BGC. After substitution of calcium, no further tetanic seizures occurred.

**Conclusions:** Patients with BGC should be investigated for a mitochondrial disorder. A mitochondrial disorder may also manifest as tetanic seizure.

**MeSH Keywords:** Epilepsy • Genetics, Medical • Mitochondrial Diseases

**Full-text PDF:** <http://www.amjcaserep.com/abstract/index/idArt/903120>



1011



2



1



24



## Background

Basal ganglia calcification (BGC) is a rare sporadic or hereditary central nervous system (CNS) abnormality characterized by symmetric or asymmetric deposition of calcium in the basal ganglia, the dentate nuclei, or the centrum semiovale [1,2]. Occasionally, BGC has been reported as a CNS manifestation of a mitochondrial disorder (MID) (Table 1) [3,4]. BGC in MIDs may be due to involvement of the parathyroid gland, resulting in hypoparathyroidism and thus hypocalcemia, or due to dysfunction of the proximal tubular system (Fanconi syndrome) [5]. Isolated affection of the parathyroid gland or the kidney in MIDs is rare. Usually, the parathyroid gland or kidneys are affected in multisystem MIDs, as was observed in this patient case.

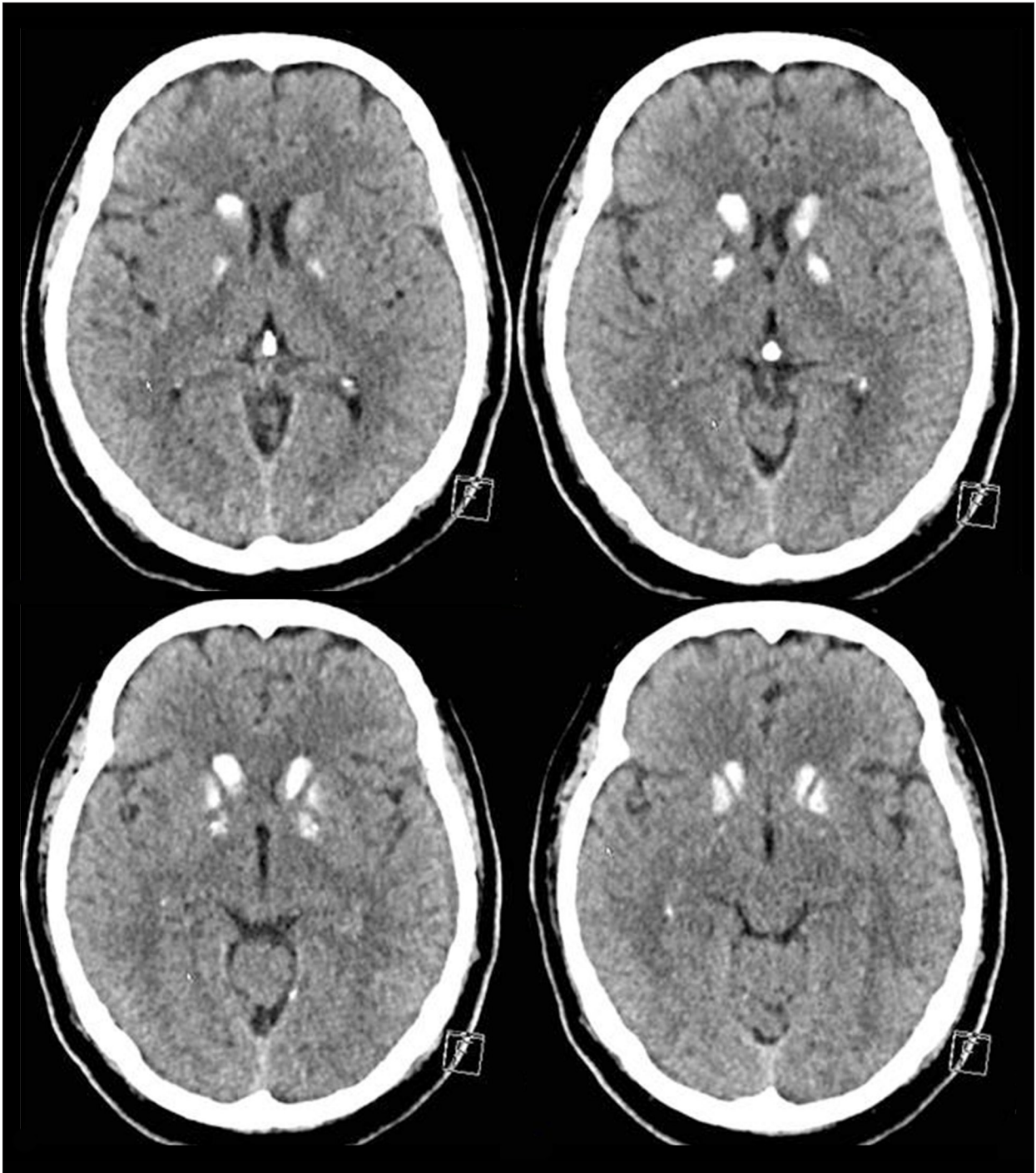
## Case Report

The patient was a 65-year-old Gypsy female, height 160 cm, weight 85 kg, who was admitted to the intensive care unit (ICU) after developing severe headache followed by shivering, dyspnea, and a bluish face, being initially interpreted as tonic clonic seizure. The individual and family history for seizure, however, was negative. She received diazepam from the emergency doctor but did not require intubation in the ICU. Her previous individual history was complex and included polyneuropathy, restless-leg syndrome, retinopathy, non-insulin dependent diabetes, hyperlipidemia, osteoporosis with wedge-shaped vertebrae T8 and T9 and consecutive hyperkyphosis, cervicalgia, lumbalgia, struma nodosa requiring thyroidectomy with consecutive hypothyroidism, adipositas, resection of

**Table 1.** Blood chemical values between 1998 and 2014.

Parameter (normal range)	5/1998	7/1998	5/1999	6/1999	3/2000	3/2003	9/2005	12/2008	2/2013	10/2013	10/2013	9/2014	9/2014	9/2014
C-reactive protein (0–5 mg/dL)	Nd	<0.5	Nd	0.77	<0.5	Nd	<b>73.8</b>	<b>6.3</b>	<b>22.4</b>	<b>42.6</b>	<b>48.0</b>	<b>35.3</b>	<b>24.0</b>	<b>32.9</b>
Erythrocytes (4.2–5.5 T/L)	Nd	Nd	Nd	Nd	Nd	5.2	<b>5.57</b>	<b>6.8</b>	5.3	4.74	5.27	<b>6.25</b>	<b>6.12</b>	<b>5.77</b>
Hemoglobin (14–16 g/dL)	Nd	Nd	Nd	Nd	Nd	<b>13.6</b>	15.8	<b>19.2</b>	15.4	<b>12.9</b>	14.3	<b>16.6</b>	15.7	15.1
Hematocrit (40–50%)	Nd	Nd	Nd	Nd	Nd	40.8	46.7	<b>55.2</b>	45.4	40.1	44.6	50.7	50.7	47.6
Creatinine (<1.1 mg/dL)	Nd	0.74	Nd	0.75	0.81	0.8	0.68	<b>1.18</b>	0.74	0.87	1.02	<b>1.38</b>	0.89	0.87
GFR (>90 ml/min/1.73 m <sup>2</sup> )	Nd	Nd	Nd	Nd	Nd	Nd	Nd	<b>&gt;60</b>	<b>&gt;60</b>	<b>66</b>	<b>55</b>	<b>39</b>	<b>64</b>	<b>66</b>
Uric acid (3.5–7.0 mg/dL)	Nd	3.4	Nd	3.5	2.6	Nd	Nd	<b>8.2</b>	Nd	5.4	Nd	<b>9.6</b>	<b>8.3</b>	Nd
Calcium (2.19–2.55 mmol/L)	<b>1.99</b>	2.19	<b>1.87</b>	<b>2.03</b>	<b>1.86</b>	Nd	Nd	<b>1.47</b>	Nd	<b>1.98</b>	Nd	<b>1.79</b>	<b>1.79</b>	<b>1.64</b>
Phosphorus (0.87–1.45 mmol/L)	Nd	Nd	<b>2.05</b>	1.69	1.44	Nd	Nd	<b>1.79</b>	Nd	<b>1.92</b>	Nd	<b>1.75</b>	<b>1.43</b>	<b>1.61</b>
Magnesium (0.7–1.0 mmol/l)	Nd	Nd	Nd	0.75	0.77	Nd	Nd	Nd	Nd	0.8	Nd	<b>0.6</b>	Nd	Nd
HbA1c (0–6.0%)	Nd	Nd	Nd	Nd	Nd	Nd	Nd	<b>7.7</b>	Nd	<b>6.9</b>	Nd	<b>8.6</b>	Nd	Nd
Creatine-kinase (<170 U/L)	Nd	Nd	Nd	Nd	Nd	Nd	132	<b>186</b>	79	72	Nd	74	64	50
Triglycerides (50–170 mg/dL)	<b>200</b>	<b>321</b>	Nd	<b>378</b>	<b>355</b>	Nd	Nd	597	Nd	<b>202</b>	Nd	<b>331</b>	<b>207</b>	Nd
Parathormone (10–65 pg/mL)	Nd	41	<b>9.4</b>	<b>8.8</b>	Nd	Nd	Nd	Nd	Nd	Nd	Nd	Nd	11.3	Nd
Calcitonine (<10 pg/mL)	Nd	<1	3.75	6.4	Nd	Nd	Nd	Nd	Nd	Nd	Nd	Nd	Nd	Nd

On April 28, 1999 a thyroidectomy was performed.



**Figure 1.** Cerebral CT scan showing bilateral calcification of the caudate nuclear head and the globus pallidus and partially also of the putamen.

a vocal chord polyp, arterial hypertension, coronary heart disease, atheromatosis of the aorta, peripheral artery disease, chronic obstructive pulmonary disease with emphysema, steatosis hepatis, mild renal insufficiency, impingement syndrome, spondylarthrosis of the lumbar spine, and hysterectomy. Her family history was positive for breast cancer (sister).

Clinical neurologic examination revealed right-sided hypoacusis, sore neck muscles, asymmetric lid fissures, bilateral dysmetria, wasting of the thighs, and reduced tendon reflexes on the lower limbs. Blood tests revealed polyglobulia, hypocalcemia and hyperphosphatemia over years, increased HbA1c, hypertriglyceridemia, renal insufficiency, hyperuricemia, and

**Table 2.** MIDs in which BGC has been reported.

MID	Age/sex	Genetic defect	Calcifications	Reference
EM	Nr	Nr	BGC	Markesbery 1975
KSS	Nr	Nr	BGC	Robertson 1979
KSS	Nr	Nr	BGC	Allen 1983
KSS	10y/m	Nr	BGC	Yoda 1984
MIMODS	14y/m	Nr	BGC	Kuriyama 1984
MELAS	12y/m	Nr	BGC	Werneck 1987
MERRF	18y/CIII	Deficiency	BGC	Federico 1988
MELAS	29y/f	Nr	BGC	Kishi 1988
MELAS	12y/m	Nr	BGC	Gubbay 1989
MELAS	14y/f	Nr	BGC	Hamazaki 1989
Leigh	8 patients	Nr	BGC	Lera 1994
MELAS	16y/f	tRNA(Leu)	BGC	Chiang 1995
MM	41y/m	Nr	BGC	Etcharry-Bouyx 1995
MERRF/PEO	26y/f	tRNA(Leu)	BGC	Verma 1996
MELAS	5 patients	Nr	BGC	Robeck 1996
EM	16y/m	tRNA(Thr)	BGC	Seki 1997
MELAS	14/26 pat.	tRNA(Leu)	BGC	Sue 1998
MELAS	52y/f	tRNA(Leu)	BGC	Drouet 2000
PS	8y/f	mtDNAdel	BGC	Lacbawan 2000
MIDD	4 patients	tRNA(Leu)	BGC	Lien 2001
MIMODS	37/m	tRNA(Val)	BGC	Sacconi 2002
MIDD	28/f	tRNA(Leu)	BGC	Kang 2005
MIMODS	36 patients	Nr	BGC	Finsterer 2005
MIMODS	68/m	Nr	BGC	Hagiwara 2006
MIMODS	75/f	Nr	BGC	Finsterer 2008
MIMODS	19/f	Nr	BGC	Panduranga 2012
MIMODS	/m	POLG1	BGC+CB+P	Sidiropoulos 2013
MELAS	11 patients	tRNA(Leu)	BGC	Tschampa 2013
MIMODS	85/m	Nr	BGC	Finsterer 2015
NARP	/f	m.8729G>A	BGA	Miyawaki 2015

EM – encephalomyopathy; KSS – Kearns-Sayre syndrome; MIMODS – non-specific mitochondrial multiorgan disorder syndrome; MERRF – myoclonic epilepsy with ragged red fibers; MELAS – mitochondrial encephalomyopathy lactic acidosis and stroke-like episodes; MM – mitochondrial myopathy; PS – Pearson syndrome; MIDD – maternally inherited diabetes and deafness; CB – cerebellum; P – pons; Nr – not reported.

vitamin-D deficiency (Table 1). Parathormone in the serum was two times normal and two times slightly reduced (Table 1). Calcitonin was normal. There was no diabetes insipidus or hypothyroidism. ECG showed sinus rhythm, occasional ventricular ectopic beats, and transient left bundle branch block. Cerebral CT showed extensive hyperdensities of the basal ganglia bilaterally and a small bleeding of the left parietal cortex (Figure 1), which was confirmed by cerebral MRI. The bleeding was suspected to have resulted from rupture of a cavernoma. Computed tomography angiography (CTA) did not reveal a vascular malformation that could explain the bleeding. There were no cerebellar calcifications. EEG did not show paroxysmal activity. After substitution of calcium, no further tetanic seizures occurred.

## Discussion

This patient case is interesting for several reasons. First, the patient most likely suffered from a non-specific mitochondrial multiorgan disorder syndrome (MIMODS). The patient's clinical indications for MID were the multisystem nature of the clinical presentation and the specific combination of abnormalities. She had diabetes, hyperlipidemia, osteoporosis, thyroid dysfunction, steatosis hepatis, mild renal insufficiency, and short stature. A further argument for a MID was that a long-standing electrolyte disturbance already existed prior to her thyroidectomy, and the BGC. Though she had a number of cardiovascular risk factors (smoking, arterial hypertension, diabetes, hyperlipidemia), which could explain atherosclerosis, it could also be attributed to a mitochondrial defect. The presence of a similar clinical profile as in this patient has been previously reported in MID patients [6–10]. Since a MID would explain all of the clinical manifestations in the presented case, this constellation further supported the presence of a MID. Unfortunately, the patient did not undergo further detailed investigations for a MID, which is why information about the presence of a biochemical abnormality or a genetic defect is lacking in this report.

Second, the patient presented with marked BGC, which has been previously reported as a phenotypic feature of a MID (Table 2). BGC is usually associated with disturbed calcium or phosphate metabolism due to hypoparathyroidism or Fanconi syndrome [11–14]. MIDs with BGC, however, do not always show an association with parathyroid dysfunction. Additionally, BGC may be associated with infectious, metabolic, or genetic disease [15]. However, the exact pathogenetic background of BGC remains elusive; however, T2-hyperintensities in the basal ganglia in these patients may reflect a focal, slowly

progressive inflammatory or metabolic process [16]. In an autopsy study of a single patient with MELAS syndrome, BGC was attributable to calcifications in the small arteries of the globus pallidus [17]. Stimulation of glutamate receptors in rats has been shown to result in calcification of various brain areas including the basal ganglia [18]. Patients with BGC frequently present with movement disorders (such as Parkinson syndrome, choreoathetosis, or ataxia), psychiatric abnormalities (such as behavioral disturbances, mood disorders, dysexecutive syndrome, or psychosis), stroke-like episodes, epilepsy, or dementia [19–22]. The prevalence of BGC is unknown but the incidence of BGC has been reported as 0.3–1.2% [23,24]. Treatment of BGC is symptomatic and does not follow a standardized regimen [16].

Third, the initial event which led to hospitalization was most likely a tetanic seizure based upon hypocalcemia on admission, absence of a history for epilepsy, absence of clinical features of a recent seizure (normal CK, no tongue bite, secessus, or postictal muscle aching or confusion and reorientation), and a negative history for meningitis, trauma, or epilepsy in other family members. An argument in favor of an epileptic seizure is the minimal cortical bleeding. The initial clinical manifestation, however, was similar to that of a tetanic seizure, which manifests with fear, inner agitation, short-lived impaired consciousness, hypoesthesias, paresthesias, muscle cramps, carpopedal spasms, Chvostek sign, Lust sign, Trousseau sign, tongue phenomenon, laryngospasms, obstetrician's hand, expiratory apnea, intestinal colics, or repetitive discharges on needle EMG. Hypocalcemia could be attributed to diabetes insipidus, Fanconi syndrome, hypoparathyroidism, or hypothyroidism, of which only diabetes insipidus is unlikely.

## Conclusions

This case shows that BGC together with diabetes and other endocrine or metabolic abnormalities suggest MID and that MID patients without a history of epilepsy, but with hypocalcemia, are more likely to develop tetanic seizures than epileptic seizures.

## Conflicts of interest

All authors: nothing to declare.

## Ethics

The described patient gave written informed consent for publication of the case

## References:

1. Faye AD, Gawande S, Tadke R et al: A case of psychosis due to Fahr's syndrome and response to behavioral disturbances with risperidone and oxcarbazepine. *Indian J Psychiatry*, 2014; 56: 188–90
2. Manyam BV: What is and what is not 'Fahr's disease'. *Parkinsonism Relat Disord*, 2005; 11(2): 73–80
3. Sidiropoulos C, Moro E, Lang AE: Extensive intracranial calcifications in a patient with a novel polymerase  $\gamma$ -1 mutation. *Neurology*, 2013; 81: 197–98
4. Finsterer J, Kopsa W: Basal ganglia calcification in mitochondrial disorders. *Metab Brain Dis*, 2005; 20: 219–26
5. Tzoufi M, Makis A, Chaliasos N et al: A rare case report of simultaneous presentation of myopathy, Addison's disease, primary hypoparathyroidism, and Fanconi syndrome in a child diagnosed with Kearns-Sayre syndrome. *Eur J Pediatr*, 2013; 172: 557–61
6. Finsterer J, Stöllberger C, Feichtinger H: Noncompaction and endocarditis in suspected mitochondrial disorder. *Int J Cardiol*, 2008; 123: e45–47
7. Kang JH, Kang SY, Choi JC et al: Chorea triggered by hyperglycemia in a maternally inherited diabetes and deafness (MIDD) patient with the A3243G mutation of mitochondrial DNA and basal ganglia calcification. *J Neurol*, 2005; 252: 103–5
8. Sacconi S, Salviati L, Gooch C et al: Complex neurologic syndrome associated with the G1606A mutation of mitochondrial DNA. *Arch Neurol*, 2002; 59: 1013–15
9. Lien LM, Lee HC, Wang KL et al: Involvement of nervous system in maternally inherited diabetes and deafness (MIDD) with the A3243G mutation of mitochondrial DNA. *Acta Neurol Scand*, 2001; 103: 159–65
10. Seki A, Nishino I, Goto Y et al: Mitochondrial encephalomyopathy with 15915 mutation: clinical report. *Pediatr Neurol*, 1997; 17: 161–64
11. Nicolau Ramis J, Espino Ibáñez A, Rivera Irigoín R et al: Extrapyrarnidal symptoms due to calcinosis cerebri in a patient with unknown primary hypoparathyroidism. *Endocrinol Nutr*, 2012; 59: 69–71
12. Goswami R, Sharma R, Sreenivas V et al: Prevalence and progression of basal ganglia calcification and its pathogenic mechanism in patients with idiopathic hypoparathyroidism. *Clin Endocrinol (Oxf)*, 2012; 77: 200–6
13. Baba Y, Broderick DF, Uitti RJ et al: Heredofamilial brain calcinosis syndrome. *Mayo Clin Proc*, 2005; 80: 641–51
14. Senoglu M, Tuncel D, Orhan FO et al: Fahr's syndrome: A report of two cases. *Firat Tip Dergisi*, 2007; 12: 70–72
15. Swami A, Kar G: Intracranial hemorrhage revealing pseudohypoparathyroidism as a cause of Fahr syndrome. *Case Rep Neurol Med*, 2011; 2011: 407567
16. Calabrò RS, Spadaro L, Marra A, Bramanti P: Fahr's disease presenting with dementia at onset: a case report and literature review. *Behav Neurol*, 2014; 2014: 750975
17. Kishi M, Yamamura Y, Kurihara T et al: An autopsy case of mitochondrial encephalomyopathy: Biochemical and electron microscopic studies of the brain. *J Neurol Sci*, 1988; 86: 31–40
18. Mahy N, Prats A, Riveros A et al: Basal ganglia calcification induced by excitotoxicity: An experimental model characterised by electron microscopy and X-ray microanalysis. *Acta Neuropathol*, 1999; 98: 217–25
19. Benke T, Karner E, Seppi K et al: Subacute dementia and imaging correlates in a case of Fahr's disease. *J Neurol Neurosurg Psychiatr*, 2004; 75: 1163–65
20. Lauterbach EC, Cummings JL, Duffy J et al: Neuropsychiatric correlates and treatment of lenticulostratial diseases: A review of the literature and overview of research opportunities in Huntington's, Wilson's, and Fahr's diseases. A report of the ANPA Committee on Research. *J Neuropsychiat Clin Neurosci*, 1998; 10: 249–66
21. Manyam BV, Walters AS, Narla KR: Bilateral Striopallidodentate calcinosis: Clinical characteristics of patients seen in a registry. *Mov Dis*, 2001; 16: 258–64
22. Modrego PJ, Mojonero J, Serrano M, Fayed N: Fahr's syndrome presenting with pure and progressive presenile Dementia. *Neurol Sci*, 2005; 26: 367–69
23. Kazis AD: Contribution of CT scan to the diagnosis of Fahr's syndrome. *Acta Neurol Scand*, 1985; 71: 206–11
24. Fénelon G, Gray F, Paillard F et al: A prospective study of patients with CT detected pallidal calcifications. *J Neurol Neurosurg Psychiatry*, 1993; 56: 622–25