



Letter to the Editor

Sub-acute stent thrombosis secondary to ticagrelor resistance—Myth or reality!!

dysfunction with regional wall motion abnormality in the form of hypokinesia of anterior wall, mid, distal interventricular septum, and apical segments with mild mitral regurgitation. The clinical diagnosis of sub-acute stent thrombosis was suspected. The patient underwent check angiography, which revealed thrombotic occlusion of LAD at the site of the stent placement. We confirmed the patient compliance of the drugs, particularly the dual antiplatelet agents [aspirin, ticagrelor].

Dear Editor,

We came across a 54-years-male patient who underwent percutaneous transluminal coronary angioplasty (PTCA) to the mid segment of the left anterior descending artery (LAD) two weeks back, presented with acute onset of chest discomfort for last 4 h. Electrocardiography showed ST-segment elevation in leads V1 to V6 and I, aVL with reciprocal ST-segment depression in leads II, III, and aVF. Echocardiography showed moderate left ventricular

We performed the thrombo-aspiration using 6Fr. the export catheter and high-pressure post-dilatation of the stent using 3.5×12 mm non-compliant balloon at high pressure [18–20 atm.]. Intracoronary eptifibatide, sodium nitroprusside, nicorandil were given to improve the flow further. At the end of the procedure, the

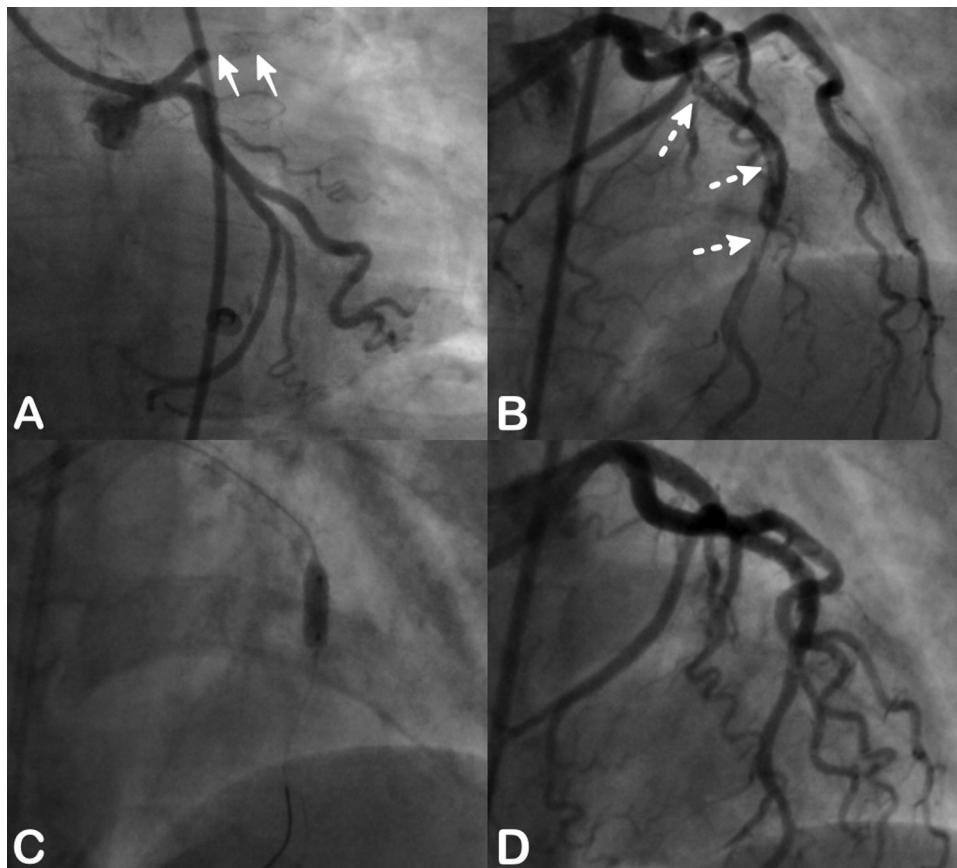


Fig. 1. (A–D) A Patient had ST-segment elevation after 2 weeks of initial PTCA to LAD. Check coronary angiography in AP caudal view revealed the stent thrombosis in the form of thrombotic occlusion of the proximal segment of the LAD with TIMI 0 flow [Panel A, solid arrows]. After the passage of a guide wire, large thrombus was [multiple translucencies] seen inside the stent [Panel B, dashed arrows]. The entire length of the stent was post-dilated using 3.5×12 mm non-compliant balloon, multiple times at high pressure [20–24 atm.] for 20 s [Panel C]. Intracoronary eptifibatide and coronary vasodilators like nicorandil, sodium nitroprusside were administered that resulted in TIMI 3 flow [Panel D].

<https://doi.org/10.1016/j.ihj.2017.10.012>

0019-4832/© 2017 Published by Elsevier B.V. on behalf of Cardiological Society of India. This is an open access article under the CC BY-NC-ND license (<http://creativecommons.org/licenses/by-nc-nd/4.0/>).

patient had partial relief of his chest pain [$>50\%$] with stable hemodynamics with TIMI 3 flow and no residual dissection or under-expansion of the stent (Fig. 1A–D).

He underwent PTCA following an episode of unstable angina (recent onset rest angina) as a clinical presentation 2 weeks before the development of the stent thrombosis. He had 1 mm horizontal ST-segment depression in antero-lateral leads [V2–V6; I; aVL]. His echocardiography had the normal left ventricular function with no regional wall motion abnormality. Coronary angiography revealed a tubular stenosis of the mid-segment of LAD. He was subjected to an elective PTCA next day following adequate doses of the dual antiplatelet agents in the form of ticagrelor, a loading dose of 180 mg and maintenance dose of 90 mg twice daily and oral aspirin, a loading dose of 325 mg and maintenance dose of 75 mg once daily. 3.5×28 mm sirolimus-eluting stent deployed at 14 atm. with inflation time of 15 s. each for 2 times. The under-expansion of stent [stent-boost guided] was post dilated using 3.5×15 mm balloon at 22 atm for 15–20 s. There was no residual stenosis or dissection with TIMI III flow (Fig. 2A–D). Patient discharged on the 2nd day of the procedure in stable condition.

The limitations of our case were that we did not perform platelet function test, as it is not widely available at present and not cost-effective. Also, the use of optical coherence tomography (OCT) or intravascular ultrasound (IVUS) to ascertain the cause of stent thrombosis like stent fracture or malapposition was not done as the patient was hemodynamically unstable and had financial constraints. Our case was an angioplasty of a type A non-calcified

lesion and post-stenting, the lesion was adequately post-dilated using a non-compliant balloon. Hence, We presumed that ticagrelor resistance as the sole cause for the development of stent thrombosis.

Stent thrombosis (ST) is a major dreaded complication of PTCA and it is reported from 2 to 3% but the use of novel antiplatelet agents like prasugrel and ticagrelor has reduced it to $<1\%$. But it could not be eliminated completely.¹ Our point of discussion is stent thrombosis secondary to ticagrelor resistance solely not related to operator or lesion related problems.

ST while on treatment with ticagrelor poses a dilemma for the further use of it as an antiplatelet agent. Though ‘ticagrelor resistance’ is not a described entity yet but there are two case reports of stent thrombosis while its use.^{2,3} In PLATO trial, probable and definite stent thrombosis in patients on Ticagrelor was 2.94% as compared to clopidogrel, which was 3.77%.

Ticagrelor is not a prodrug unlike prasugrel or clopidogrel, which needs to get metabolize to an active drug, enters the blood directly upon absorption leading to potent and consistent P2Y12 inhibition. Thus ST is rare with ticagrelor but not completely eliminated complication. The operator and lesion-related factors are also associated with the occurrence of ST apart from drug resistance.

Dalal et al. studied 539 patients with acute coronary syndrome who underwent PTCA with dual antiplatelet agents – aspirin versus clopidogrel, prasugrel, and ticagrelor. The average percentage platelet inhibition, resistance, and sensitivity to each drug were studied using thrombelastography. Ticagrelor had higher average

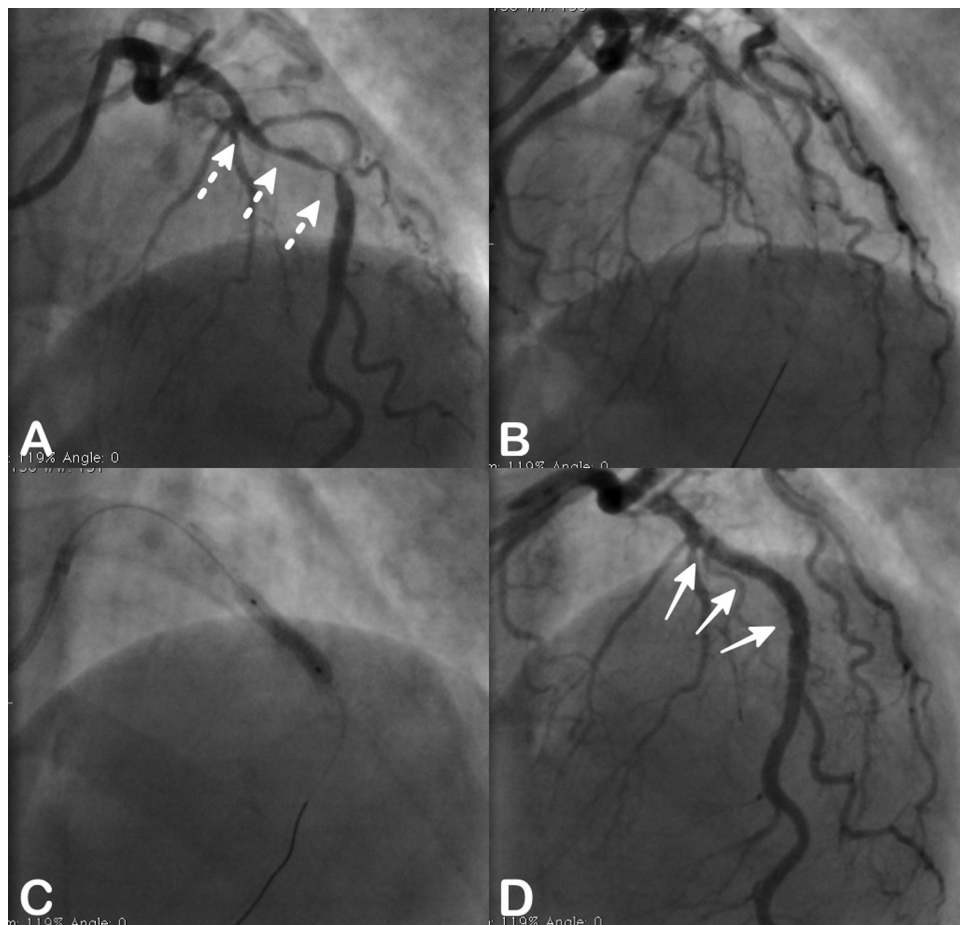


Fig. 2. (A–D) A Coronary angiography showed 90% tubular stenosis of mid-segment of the LAD following a clinical diagnosis of unstable angina [Panel A, dashed arrows]. After predilatation, 3.5×28 mm sirolimus-eluting stent [Panel B] deployed across the lesion, which was post-dilated using non-compliant 3.5×15 mm balloon at 22 atm [Panel C]. Stent expansion was adequate without any dissection [Panel D, solid arrows].

percentage platelet inhibition and least resistance as compared to other antiplatelet agents.⁴

Olechowski et al. reported three cases of Hypo-responsiveness to Clopidogrel, Prasugrel, and Ticagrelor who presented with definite stent thrombosis. They studied responsiveness to clopidogrel, prasugrel, and ticagrelor, using well-validated test, thrombelastography and found pan-hypo responsiveness to all three P2Y12 inhibitors, which is called as a 'resistance' clinically.⁵

In Rapid Activity of Platelet Inhibitor Drugs (RAPID primary PCI) study, residual platelet reactivity was assessed by verifyNow at baseline, 2,4,8 and 12 h after P2Y12 inhibitor administration. High residual platelet reactivity (HRPR) was defined as platelet reactivity unit >240 units. They compared loading dose of 60 mg of prasugrel versus 180 mg of ticagrelor in patients undergoing primary PCI. Both the P2Y12 inhibitors achieved maximum platelet inhibition after 4 h and concomitant use of morphine delayed the effectiveness of the drugs.⁶

Thrombelastography (TEG) and Whole blood luminescence aggregometry (WBLA) test to measure the platelet reactivity to document P2Y12 inhibitor resistance.³ VerifyNow uses inhibition of platelet aggregation which was defined as the percentage decrease in aggregation values obtained at baseline and after treatment: $100 \times (\text{PRU baseline} - \text{PRU after drug}) / \text{PRU baseline}$.⁶ These tests were not done in our case, as they are not widely available for the routine clinical use.

The cautious use of GP IIb/IIIa inhibitors can be advocated while dealing with a case of ST while the use of ticagrelor as inhibits GP IIb/IIIa receptors which are the common final pathway for the inhibition of platelet reactivity, though at the cost of increased bleeding risk. The switching over to another potent P2Y12 inhibitor like prasugrel was described in earlier case reports. But its use in the setting of so-called 'ticagrelor resistance' has very limited experience and should be at the clinician's discretion at this point of time.

There are no documented large randomized controlled trials comparing different antiplatelet agents, particularly P2Y12 inhibitors in term of resistance in various clinical scenarios. Also, there are no definite guidelines about the use of platelet function tests, what tests to be used and what are their proper validated results to be used in the clinical settings.

The use of ticagrelor does not lead to stent thrombosis is a myth but is a definite reality. We do not have many answers yet; at this time and further tests will illuminate us with the reality to deal with them. Till that time clinicians have to use their past experiences to tackle such issues.

References

1. D'Ascenzo F, Bollati MFC, et al. Incidence and predictors of coronary stent thrombosis: evidence from an international collaborative meta-analysis including 30 studies, 221,066 patients, and 4276 thromboses. *Int J Cardiol.* 2013;167:575–584.
2. Musallam A, Lev EIRA. Stent thrombosis in a patient with high on-treatment platelet reactivity despite ticagrelor treatment. *Eur Hear J Acute Cardiovasc Care.* 2014;4:85–87.
3. Suleiman A, Khan A, Posimreddy S, et al. Stent thrombosis secondary to ticagrelor resistance as demonstrated by thromboelastography. *J Cardiol Curr Res.* 2016;6:205.
4. Dalal JJ, Digrajkar A, Gandhi A. Oral antiplatelet therapy and platelet inhibition: an experience from a tertiary care center. *Indian Heart J.* 2016;68:624–631.
5. Olechowski B, Ashby A, Sambu N, et al. Stent thrombosis patients with hyporesponsiveness to clopidogrel, prasugrel, and ticagrelor: a case series using short thromboelastography. *Case Rep Med.* 2016;2016:1–6.
6. Parodi G, Valenti R, Bellandi B, et al. Comparison of prasugrel and ticagrelor loading doses in ST-segment elevation myocardial infarction patients: RAPID (Rapid Activity of Platelet Inhibitor Drugs) primary PCI study. *J Am Coll Cardiol.* 2013;61:1601–1606.

Pankaj Jariwala*

Hemanshu Bhatia

Edla Arjun Padma Kumar

Department of Cardiology, Maxcure-Mediciti Hospitals, Opposite Secretariat, 500063, Hyderabad, Telangana, India

* Corresponding author at: Consultant Interventional Cardiologist, Maxcure-Mediciti Hospitals, Opposite Secretariat, 500063, Hyderabad, Telangana, India.

E-mail address: pankaj_jariwala@hotmail.com (P. Jariwala).

Received 14 October 2017

Available online 26 October 2017