

# Acute limb ischemia following iatrogenic femoral artery injury during orchiopexy

Akash Bihari Pati, Siddhartha Sathia<sup>1</sup>, Santosh Kumar Mahalik\*

Departments of Pediatric Surgery and <sup>1</sup>Cardiothoracic and Vascular Surgery, All India Institute of Medical Sciences, Bhubaneswar, Odisha, India

\*E-mail: dr.santosh25@gmail.com

## ABSTRACT

Orchiopexy for undescended testis is a standard procedure in pediatric patients. Intraoperative complications during orchiopexy are rare. Major complications reported include injury to vas deferens or testicular vessels, leading to testicular atrophy. Damage to the femoral artery has not been described in the literature as a complication during orchiopexy. In this report, we describe a case where injury to the right femoral artery leading to acute limb ischemia occurred while performing orchiopexy.

## INTRODUCTION

Pediatric femoral artery injury can occur following trauma or due to iatrogenic injury. Femoral arterial cannulation is the leading cause of acute arterial thrombosis and acute limb ischemia (ALI), and, in children, there is a 2% risk of arterial injury.<sup>[1]</sup> Femoral artery injury as an intraoperative complication of orchiopexy has never been described in the literature. We report a case of ALI in a child following right femoral artery injury occurring as an iatrogenic complication during orchiopexy.

## CASE REPORT

A 6-year-old male child presented to the emergency department with a history of orchiopexy done elsewhere for a right undescended testis palpable in the superficial inguinal pouch. While performing the orchiopexy, the surgeon had inadvertently injured the right femoral artery by electrocautery. The artery was repaired, but as he failed to palpate a good distal pulse, the patient was referred to us at a tertiary hospital which is about 300 km away. The patient was

transported by road and reported to us about 12 h after the injury. On examination of the referral notes, it was found that a peripheral computed tomography angiography of the lower extremity with aortography was performed immediately after the repair of the femoral artery at the primary institute, which suggested abrupt cutoff of the right femoral artery near the origin of the profunda femoris artery. At presentation, the distal pulses were absent in the right lower limb, and the limb was pale and cold. The patient had a sutured wound over the right upper thigh starting from the pubic bone medially and extending laterally along the skin crease between the thigh and abdomen up to a point lying about 5 cm below the anterior superior iliac spine [Figure 1]. After clinical examination at our institute, Doppler study of the lower limbs was performed to know the extent of the thrombosis, which showed a thrombus extending from the femoral up to the external iliac artery above the inguinal ligament proximally. Immediate reexploration was planned in view of pale and cold peripheries of the affected leg and no distal flow on Doppler. On exploration of the wound, it was found that orchiopexy was not completed by the previous surgeon and the testis was seen lying in the

This is an open access journal, and articles are distributed under the terms of the Creative Commons Attribution-NonCommercial-ShareAlike 4.0 License, which allows others to remix, tweak, and build upon the work non-commercially, as long as appropriate credit is given and the new creations are licensed under the identical terms.

**For reprints contact:** reprints@medknow.com

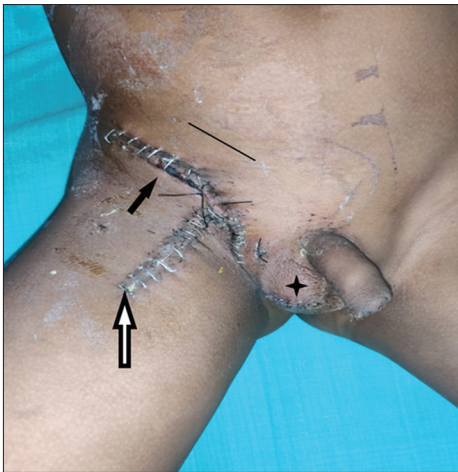
**Received:** 06.05.2020, **Revised:** 24.06.2020

**Accepted:** 16.07.2020, **Published:** 01.10.2020

**Financial support and sponsorship:** Nil.

**Conflicts of interest:** There are no conflicts of interest.

Access this article online	
Quick Response Code:	Website: www.indianjurol.com
	DOI: 10.4103/iju.IJU_254_20



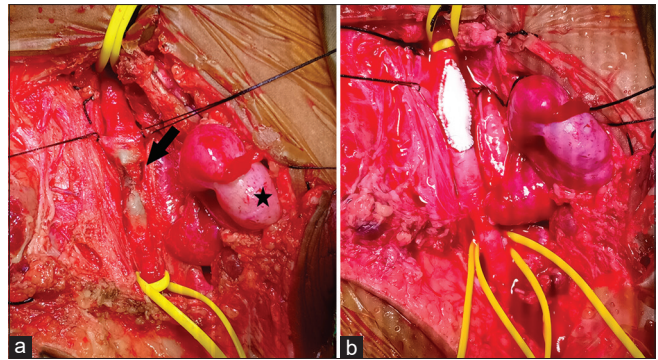
**Figure 1:** Postoperative photograph showing correct incision site (black line), site of incision made at previous surgery (black arrow), incision extended to dissect the femoral artery at subsequent surgery (white arrow), and orchiopey completed (star)

superficial inguinal pouch at the superior flap of the wound. At the middle of the wound, the sutured, contracted femoral artery was seen [Figure 2a]. A longitudinal extension of the incision was made along the long axis of the limb for better exposure of the femoral artery. Systemic heparinization was performed, the artery was isolated, and control was taken with vascular loops, both proximally and distally. The arterial sutures were removed and an intraluminal clot was removed. The lumen was thoroughly irrigated with heparinized saline. A Fogarty balloon thrombectomy was performed proximally and distally. A polytetrafluoroethylene (PTFE) on lay graft was applied over the defect [Figure 2b]. The wounds were closed after completing orchiopey. The patient had a good distal flow on the table. Postoperatively, the patient was continued with low-molecular-weight heparin for 5 days and antiplatelet therapy for 3 months. Doppler study at 3 months showed good caliber and flow in the femoral artery. He is asymptomatic at 6-month follow-up.

## DISCUSSION

Open orchiopey is a common procedure in pediatric surgical practice. In the hands of an experienced pediatric surgeon, the risk of complications is <5%.<sup>[2]</sup> Failure to reach the scrotum, secondary atrophy of testis, retraction of the testis, occlusion of vas deferens, hemorrhage, wound infection, and scrotal edema are described as the possible complications following open orchiopey. Femoral artery injury following orchiopey has never been reported in literature.

Undescended testis palpable in the inguinal canal is approached by the lowest skin crease incision on the abdominal wall during orchiopey. The inguinal ligament forms the floor of the inguinal canal. The external iliac artery continues as the femoral artery deep into the inguinal



**Figure 2:** (a) Operative photograph showing the testis (star mark) and the stitched right femoral artery (arrow mark). (b) Operative photograph after repair of the femoral artery with a polytetrafluoroethylene onlay graft

ligament. The femoral artery passes downward into the femoral triangle, where it is superficial below the deep fascia of the thigh. Hence, an incision at the level of the upper thigh is likely to injure the femoral artery.

In the present case, the primary surgeon had made a very low-lying incision at the root of the scrotum extending laterally at the upper thigh. Such an incision may injure the femoral vessels which lie just below it. It is possible that the surgeon could not locate the testis as it was in the superficial inguinal pouch, hence inadvertently extended the incision to find the testis, causing injury to the femoral artery with electrocautery. The injured vessel was repaired with multiple sutures to stop the bleeding, resulting in a contracture of the femoral artery and compromised distal flow.

The surgical principle during repair of any peripheral artery injury is to take control of the proximal healthy part of the artery followed by exploring the injured area, to reduce the chance of blood loss. Forward and back bleed should be established by an embolectomy catheter wherever required. The injury to the arterial wall should be assessed and repaired primarily or, if required, can be augmented with an onlay PTFE patch using nonabsorbable sutures.

ALI is a potentially catastrophic complication in children, and complete ischemia of nerve and muscle damage starts within 4 to 6 h unless the limb is revascularized.<sup>[3]</sup> In general, ALI progresses to advance limb ischemia within 2 weeks of acute onset.<sup>[4]</sup> Immediate anticoagulation is the mainstay of care after arterial injury or occlusion.<sup>[1]</sup> Therapeutic anticoagulation (with heparin or low-molecular-weight heparin) is advocated, and the duration of anticoagulation is typically 5–7 days. However, some authors have reported extending it up to 3 months depending on the severity of cases and the response rate.<sup>[1,3,4]</sup> In our case, the child did not receive any anticoagulation following the primary arterial repair, possibly contributing to intraluminal thrombus, causing ALI.

Surgical repair of arterial injuries in young patients is challenging due to the small size of the vessels and frequent spasms. However, surgical management offers improved patency and less ischemia-related sequelae. Currently, the surgical treatment for ALI includes thromboembolectomy using balloon catheter, bypass surgery, thromboendarterectomy, patch plasty, and intraoperative thrombolysis.<sup>[4]</sup>

## CONCLUSION

Complications following orchiopexy for undescended testis are infrequent. ALI following injury to the femoral artery is a severe complication, and it should be managed at a tertiary care center with available expertise. Anticoagulation therapy should be started immediately following arterial injury and should be continued postoperatively.

### *Declaration of patient consent*

The authors certify that they have obtained all appropriate patient consent forms. In the form, the legal guardian has given

his consent for images and other clinical information to be reported in the journal. The guardian understands that name and initial will not be published, and due efforts will be made to conceal patient identity, but anonymity cannot be guaranteed.

## REFERENCES

1. Andraska EA, Jackson T, Chen H, Gallagher KA, Eliason JL, Coleman DM. Natural history of iatrogenic pediatric femoral artery injury. *Ann Vasc Surg* 2017;42:205-13.
2. Hutson JM. Undescended Testis, Torsion and Varicocele. In: Coran AG, editor. *Pediatric Surgery*. 7<sup>th</sup> ed. Philadelphia: Elsevier Saunders; 2012. p. 1003-19.
3. Kayssi A, Shaikh F, Roche-Nagle G, Brandao LR, Williams SA, Rubin BB. Management of acute limb ischemia in the pediatric population. *J Vasc Surg* 2014;60:106-10.
4. Obara H, Matsubara K, Kitagawa Y. Acute limb ischemia. *Ann Vasc Dis* 2018;11:443-8.

How to cite this article: Pati AB, Sathia S, Mahalik SK. Acute limb ischemia following iatrogenic femoral artery injury during orchiopexy. *Indian J Urol* 2020;36:309-11.