

AA Amyloidosis Associated with Jugular Paraganglioma as a Rare Cause of Chronic Diarrhea

José M. Olmos-Martínez, MD¹, Remigio Mazorra, MD², Cristina Magadán, MD³, Luis Martín, MD¹, and Javier Crespo, MD, PhD¹

¹Department of Gastroenterology and Hepatology, Hospital Universitario Marqués de Valdecilla-IDIVAL, Universidad de Cantabria, Santander, Spain

²Department of Anatomic Pathology, Hospital Universitario Marqués de Valdecilla-IDIVAL, Universidad de Cantabria, Santander, Spain

³Department of General Surgery, Hospital Universitario Marqués de Valdecilla-IDIVAL, Universidad de Cantabria, Santander, Spain

ABSTRACT

We report a case of a 64-year-old man with chronic diarrhea who was diagnosed of a systemic reactive (AA) amyloidosis associated with a jugular paraganglioma. This neoplasm was diagnosed 30 years previously and it was not removed after extensive evaluation by a multidisciplinary team. Chronic inflammatory diseases are the major cause of AA amyloidosis. However, benign tumors, such as jugular paragangliomas, are considered to be one of the tumors that can result in AA amyloidosis.

INTRODUCTION

Jugular paragangliomas are uncommon neoplasms that arise from paraganglionic chemoreceptor cells.¹ AA amyloidosis occurs in patients with high levels of serum amyloid A protein (SAA). Several proinflammatory cytokines induce SAA production in liver cells. Chronic inflammatory diseases are the primary cause of AA amyloidosis, and tumors are rarely reported to be associated with AA amyloidosis. Amyloid deposition in the gastrointestinal (GI) tract is greatest in the small intestine.² The most common symptoms include diarrhea, steatorrhea, and GI bleeding. These manifestations can be explained by a sprue-like condition induced by amyloid infiltration of the villi and the submucosa, in addition to an autonomic dysfunction caused by amyloid deposits in the Auerbach's and Meissner's plexuses.^{3,4}

CASE REPORT

A 64-year-old man admitted to our hospital reported watery diarrhea for the last 13 months. He had up to 8 bowel movements per day, worsening in the month prior to admission, resulting in 15 to 20 movements per day without response to antidiarrheals. He did not report steatorrhea or blood, mucus, or pus in the stool. He did not suffer from asthenia, anorexia, fever, or vomiting. He did, however, report a 20-kg weight loss during the past year. Arthralgia, dyspnea, or abdominal pain were not present. A right jugular paraganglioma was diagnosed more than 30 years ago, and its extension affected several vital structures (Figure 1). He was not on any medication and had no other medical conditions.

Physical examination revealed normal vital signs, with pale skin and mucus. The right side of the face was deformed by a prominent, tight, hypervascular cervical tumor, with peripheral facial palsy. Abdominal examination showed

ACG Case Rep J 2017;4:e100. doi:10.14309/crj.2017.100. Published online: August 16, 2017.

Correspondence: José M. Olmos-Martínez, Department of Gastroenterology, Hospital Universitario Marqués de Valdecilla-IDIVAL, Avda. Valdecilla s/n. 39008-Santander, Spain (jolmos@humv.es).



Copyright: © 2017 Olmos-Martínez et al. This work is licensed under a Creative Commons Attribution-NonCommercial-NoDerivatives 4.0 International License. To view a copy of this license, visit <http://creativecommons.org/licenses/by-nc-nd/4.0>.

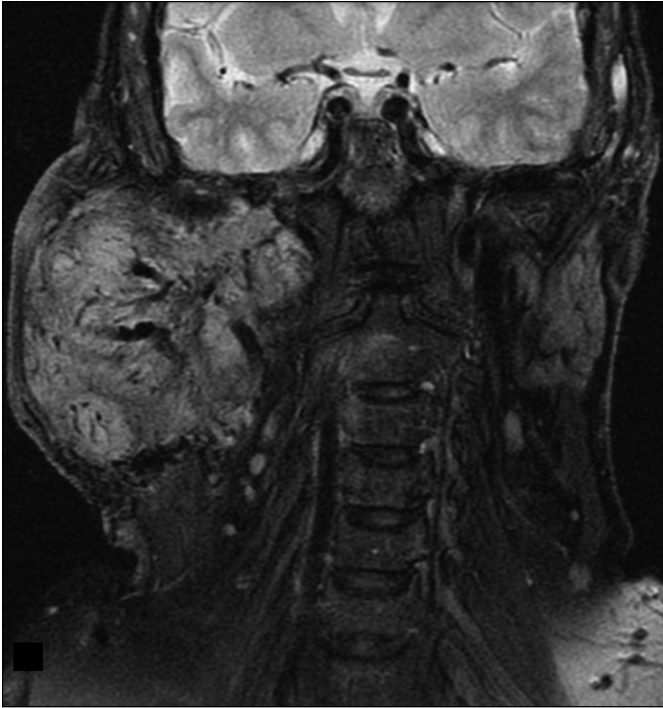

Figure 1. Magnetic resonance imaging of a 9-cm jugular paraganglioma invading the skull base, carotid vessels, and the mastoid part of the temporal bone.

normal bowel sounds without tenderness, distension, or masses. Laboratory studies showed anemia (9.4 g/dL), thrombocytosis (724,000 platelets/ μ L), elevated erythrocyte sedimentation rate (120 mm), and hypoalbuminemia (2.7 g/dL). Alkaline phosphatase and gamma glutamyltransferase were slightly altered at 141 U/L and 100 U/L, respectively. 24-Hour urine collection showed 1.2 g/d proteinuria, with normal creatinine (1.16 mg/dL). Chest x-ray was normal.

Stool specimen culture (including parasite analysis) was negative, and celiac disease antibody tests (anti-tissue transglutaminase antibody) and an intestinal biopsy were unrevealing. Thyroid hormone tests, vasoactive intestinal polypeptide (VIP), and 5-hydroxyindoleacetic acid (5-HIAA) urine tests also returned normal results. Serum electrophoresis and 24-hour urine immunofixation electrophoresis did not show a monoclonal spike. Immunoglobulin G and M levels were normal; however, immunoglobulin A levels were almost twice the upper limit (843 mg/dL). Tests for hepatitis B antigens and anti-hepatitis C antibodies were negative.

Rheumatoid factor, anti-nuclear antibody, anti-smooth muscle antibody, anti-mitochondrial antibody, and QuantiFERON[®] TB tests were also negative. A computed tomography (CT) scan showed mucosal enhancement and local hyperemia in the descending and sigmoid colon without abdominal masses or thickenings. Corresponding with the CT findings, a colonoscopy revealed an unspecific inflamed and friable mucosa.

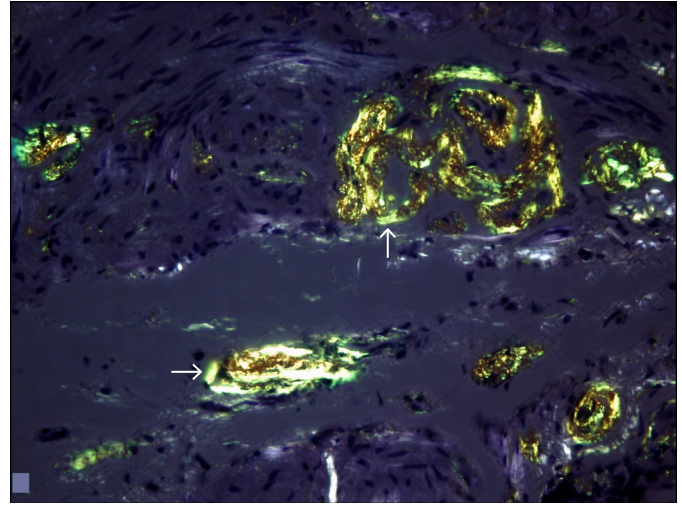


Figure 2. Submucosal deposits of eosinophilic material in extracellular spaces and on the wall of the vessels, with apple-green birefringence after Congo red stain.

A histologic assessment of the affected colon biopsies showed extracellular eosinophilic deposits in the submucosa and vessel walls, with apple green birefringence with Congo red stain, indicative of amyloidosis (Figure 2). An immunohistochemical stain was positive to AA-type amyloid (Figure 3).

DISCUSSION

Head and neck paragangliomas are rare, with an estimated incidence of 1:30,000 and accounting for 3% of all paragangliomas. The most common locations of head and neck paragangliomas in descending order are the carotid artery, the jugular bulb, the tympanic membrane, and the vagal plexus. Jugular paragangliomas, which are the most common tumors of the jugular foramen, are benign tumors that grow slowly

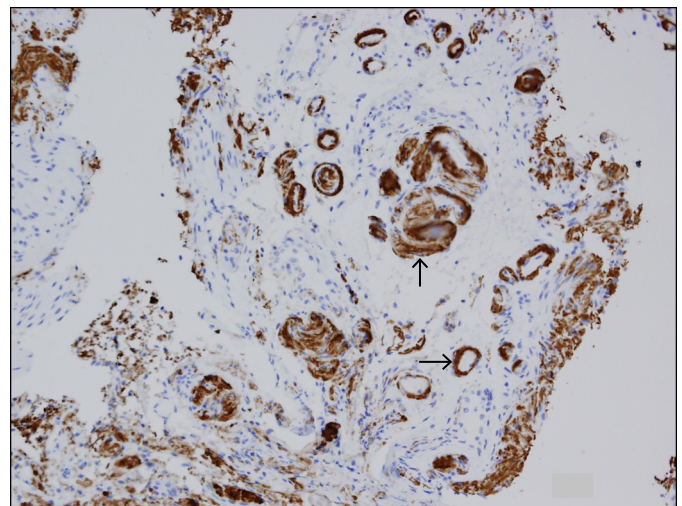


Figure 3. Immunohistochemical staining of the vessel walls positive for AA-type amyloid deposits.

but are locally aggressive. Treatment options for paragangliomas include surgical excision, endovascular embolization, conventional radiotherapy, and stereotactic radiosurgery.^{1,5}

Amyloidosis refers to extracellular tissue deposition of fibrils composed of low molecular mass subunits of a variety of serum proteins. These proteins constitutively circulate in plasma. Systemic reactive amyloidosis or AA amyloidosis (secondary amyloidosis) results from SAA protein deposition in tissue. SAA is one of the main acute-phase reactants.² Common causes of AA amyloidosis are chronic infections (particularly in developing countries) and inflammatory diseases, although systemic amyloidosis may also occur in association with other conditions, including certain neoplasms.^{2,6,7} In one of the largest series in the literature, it accounts for only 2% of the causes.⁸ The association between paragangliomas and AA amyloidosis has rarely been reported.^{9–11} The most common organ affected in AA amyloidosis is the kidney (approximately 80% of cases). This is usually characterized by glomerular amyloid deposition, typically leading to nephrotic syndrome, although presentation may vary.¹² However, the GI tract can also be affected, causing malabsorption, intestinal pseudo-obstruction, bleeding, or diarrhea, which is what occurred in our patient.¹³ While there was no renal biopsy to demonstrate this, our patient likely had renal affectation considering the proteinuria level of 1.2 g/d.

Controlling the underlying disease, which leads to a subsequent reduction in acute-phase reactant levels, including circulating serum SAA levels, is the most effective strategy to stabilize or even to induce regression of amyloid deposition.^{2,9}

The jugular paraganglioma affecting our patient invaded the posterior cranial fossa and the petrous part of the temporal bone at diagnosis. Thus, the risks associated with surgery were considered excessive for a benign tumor. When these risks were explained to the patient, he opted not to pursue surgery. Stereotactic radiosurgery was unsuccessful years before, and endovascular embolization was dismissed due to the involvement of the internal carotid artery, so we could only offer symptomatic treatment.

We detected no other inflammatory, infectious, or neoplastic cause in our patient. There were no clinical or laboratory findings suggesting autoimmune or autoinflammatory diseases. There was no family or personal history or any other

contributing etiology. Therefore, we suggest that systemic reactive (AA) amyloidosis was induced by the tumor-related inflammation itself during a period of more than 30 years. Our case highlights a rare association of jugular paraganglioma inducing secondary amyloidosis.

DISCLOSURES

Author contributions: All authors wrote and edited the manuscript. JM Olmos-Martínez is the article guarantor.

Financial disclosure: None to report.

Informed consent was obtained for this case report.

Received December 29, 2016; Accepted June 23, 2017

REFERENCES

1. Woolen S, Gemmete JJ. Paragangliomas of the head and neck. *Neuroimaging Clin N Am*. 2016;26:259–78.
2. Pinney JH, Lachmann HJ. Systemic AA amyloidosis. *Subcell Biochem*. 2012;65:541–64.
3. Ebert E, Nagar M. Gastrointestinal manifestations of amyloidosis. *Am J Gastroenterol*. 2008;103:776–87.
4. Cowan AJ, Skinner M, Seldin DC, et al. Amyloidosis of the gastrointestinal tract: A 13-year, single-center, referral experience. *Haematologica*. 2013;98:141–6.
5. Lee JH, Barich F, Karnell LH, et al. National Cancer Data Base report on malignant paragangliomas of the head and neck. *Cancer*. 2002;94:730–7.
6. Nienhuis HL, Bijzet J, Hazenberg BP. The prevalence and management of systemic amyloidosis in western countries. *Kidney Dis (Basel)*. 2016;2:10–9.
7. Real de Asúa D, Costa R, Galván JM, et al. Systemic AA amyloidosis: Epidemiology, diagnosis, and management. *J Clin Epidemiol*. 2014;29:369–77.
8. Joss N, McLaughlin K, Simpson K, Boulton-Jones JM. Presentation, survival and prognostic markers in AA amyloidosis. *QJM*. 2000;93:535–42.
9. Larraza-Hernandez O, Albores-Saavedra J, Benavides G, Krause LG, Perez-Merizaldi JC, Ginzo A. Multiple endocrine neoplasia: Pituitary adenoma, multicentric papillary thyroid carcinoma, bilateral carotid body paraganglioma, parathyroid hyperplasia, gastric leiomyoma, and systemic amyloidosis. *Am J Clin Pathol*. 1982;78:527–32.
10. Gupta A, Khaira A, Bhowmik D, Agarwal SK, Tiwari SC. Carotid body tumor and amyloidosis: An uncommon association. *Saudi J Kidney Dis Transplant*. 2010;21:337–8.
11. Dervisoglu E, Ozturk M, Tuncay M, et al. The hidden cost of untreated paragangliomas of the head and neck: Systemic reactive (AA) amyloidosis. *Case Rep Nephrol*. 2015;2015:250604.
12. Scarpioni R, Ricardi M, Albertazzi V. Secondary amyloidosis in autoinflammatory diseases and the role of inflammation in renal damage. *World J Nephrol*. 2016;5:66–75.
13. Nordling E, Abraham-Nordling M. Colonic amyloidosis, computational analysis of the major amyloidogenic species, serum amyloid A. *Comput Biol Chem*. 2012;39:29–34.