

# Widespread Intra-abdominal Carcinomatosis from a Rhabdoid Meningioma after Placement of a Ventriculoperitoneal Shunt: A Case Report and Review of the Literature

## Abstract

Intra-abdominal metastasis (IAM) of central nervous system (CNS) tumors via ventriculoperitoneal shunt (VPS) is rare but has been previously reported (e.g., germinomas and medulloblastomas). However, there has been no previous report in the literature involving meningiomas. A case of primary rhabdoid meningioma with widespread intra-abdominal carcinomatosis after placement of a VPS in a 36-year-old man is described. The patient underwent preoperative angioembolization of the tumor, craniotomy, and surgical excision, followed by postoperative gamma knife radiosurgery. Five months later, he underwent a decompressive craniectomy and surgical excision for tumor recurrence causing raised intracranial pressure and communicating hydrocephalus, necessitating placement of a VPS. One month after placement of the VPS, the patient developed abdominal distension and confusion. He was treated for a VPS infection, and the shunt was explanted. He continued to deteriorate with high output from the peritoneal drain placed at the time of shunt explantation. An exploratory laparotomy revealed multiple diffuse peritoneal and omental nodules which had the same histopathological and immunohistochemical morphology as the primary tumor. We reviewed the current literature on IAM of primary CNS tumors via VPS, which revealed that patients belonging in the pediatric age group, of the male gender, and with a primary intracranial germinoma or medulloblastoma have a higher incidence of IAM. Majority of IAM occurred within 2 years of VPS placement, and patients most commonly present with abdominal distension and ascites. Treatment after diagnosis is varied and the prognosis is poor, with more than half of the patients dying within a year. It is vital for clinicians to maintain a high index of suspicion for similar patients, as early intervention could potentially improve patient outcomes and patient expectations managed more effectively.

**Keywords:** Meningioma, metastasis, rhabdoid

## Introduction

Meningiomas are the second most common symptomatic primary brain tumors in adults and account for one-third of all primary brain and central nervous system (CNS) tumors.<sup>[1,2]</sup> They are a diverse set of tumors derived from arachnoid cap cells of arachnoid villi in the meninges. Rhabdoid meningioma is an aggressive and unusual variant of meningioma that was first described and introduced by Kepes *et al.* and Perry *et al.* in 1998 and then subsequently added into the World Health Organization (WHO) classification of CNS tumors as a Grade III (malignant) tumor in 2000.<sup>[3-5]</sup> The latest 2007 WHO classification identified 15 different types of meningiomas based on morphological criteria and stratified them into three

grades.<sup>[6]</sup> Grade I (benign) tumors form the vast majority while Grade III (malignant) lesions remain rare.<sup>[7]</sup> Treatment of Grade III CNS meningiomas usually comprise of a combination of surgical excision and radiotherapy.<sup>[8]</sup>

Any intracranial pathology is a common cause of acquired hydrocephalus. Implantation of a ventriculoperitoneal shunt (VPS) is the most widely used treatment to manage persistent hydrocephalus, but can be associated with a number of complications, such as mechanical failures, infections, and dissemination of tumor cells.<sup>[9]</sup> Intra-abdominal metastasis (IAM) or seeding of CNS tumors via a VPS is rare but has been reported in literature. We describe the first reported case of widespread intra-abdominal carcinomatosis

**N. G. Jun Jie,  
Kok Ann Teo<sup>1</sup>,  
Asim Shabbir,  
Tseng Tsai Yeo<sup>1</sup>**

*Departments of General Surgery and <sup>1</sup>Neurosurgery, University Surgical Cluster, National University Health System, Singapore*

### Address for correspondence:

*Dr. N. G. Jun Jie,  
Level 8, NUHS  
Tower Block, 1E Kent  
Ridge Road, Singapore 119228.  
E-mail: jun\_jie\_ng@nuhs.edu.sg*

### Access this article online

**Website:** www.asianjns.org

**DOI:** 10.4103/1793-5482.181128

### Quick Response Code:



**How to cite this article:** Jun Jie NG, Teo KA, Shabbir A, Yeo TT. Widespread intra-abdominal carcinomatosis from a rhabdoid meningioma after placement of a ventriculoperitoneal shunt: A case report and review of the literature. *Asian J Neurosurg* 2018;13:176-83.

This is an open access article distributed under the terms of the Creative Commons Attribution-NonCommercial-ShareAlike 3.0 License, which allows others to remix, tweak, and build upon the work non-commercially, as long as the author is credited and the new creations are licensed under the identical terms.

**For reprints contact:** reprints@medknow.com

through a VPS in a patient with rhabdoid meningioma, and present findings from a literature review of patients with primary CNS tumors and subsequent IAM via VPS.

## Case Report

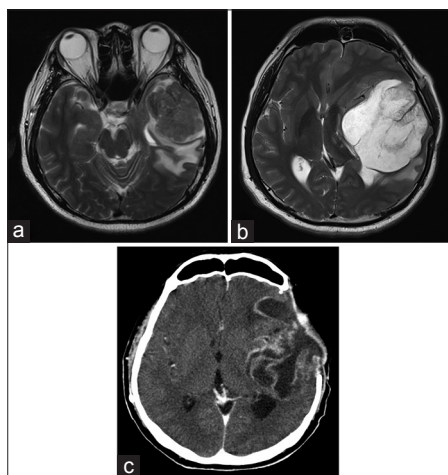
A 36-year-old man presented with left-sided headaches associated with vertiginous giddiness for 3 months. A magnetic resonance imaging (MRI) scan of the brain revealed a 5.7 cm left temporal mass with significant left cerebral edema and midline shift [Figure 1a]. The patient underwent preoperative angioembolization of the tumor followed by a left perional craniotomy and excision of the tumor. Histopathological examination of the resected specimen revealed a meningothelial tumor predominantly consisting of cells with eccentrically placed nuclei, occasional prominent nucleoli, and abundant eosinophilic cytoplasm, consistent with a diagnosis of a meningioma with predominant rhabdoid features [Figure 2a]. Extensive tumor necrosis was also noted [Figure 2b]. Immunohistochemically, the tumor cells showed diffuse strong positivity to vimentin with focal expression of epithelial membrane antigen (EMA) and cytokeratins AE1/3 [Figure 2c]. Placental alkaline phosphatase, activin receptor-like kinase 1 and desmin were not expressed by the tumor cells. The patient recovered well postoperatively and received gamma knife radiosurgery 2 months later for treatment of residual tumors.

Five months following the initial surgery, a routine follow-up MRI scan of the brain showed tumor recurrence in the left middle cranial fossa measuring 7.9 cm with a midline shift, marked sulcal effacement, basal cistern distortion and left uncal herniation [Figure 1b]. An emergency left decompressive craniectomy and excision of the recurrent tumor was performed. On postoperative day 3, the patient developed wound dehiscence over the lateral

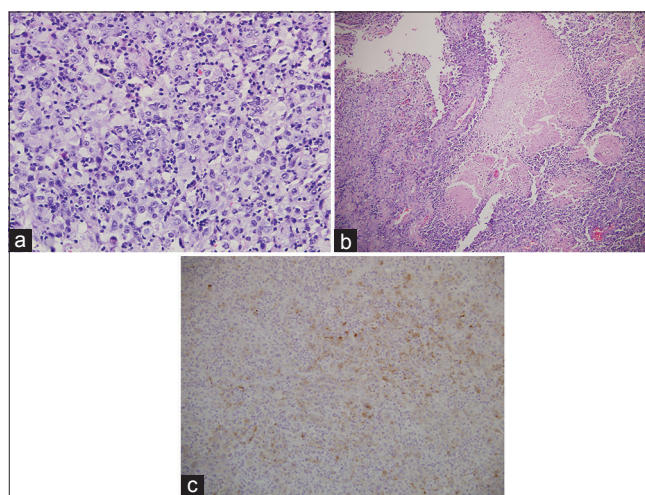
aspect of the craniectomy incision with the significant cerebrospinal fluid (CSF) leak. Computed tomography (CT) scan of the brain revealed increasing ventricular dilatation with intracranial herniation, and a VPS was implanted. The patient subsequently recovered well.

The patient re-presented 1 month later with abdominal pain and distension associated with anorexia, lethargy and confusion. He was disoriented, and his abdomen was distended with generalized tenderness. A CT scan of the brain revealed recurrence of a 7.9 cm left frontotemporal tumor with associated perilesional edema [Figure 1c] while a CT scan of the abdomen revealed moderate amounts of ascites with diffuse peritoneal enhancement suggestive of ongoing peritonitis [Figure 3]. The VPS was explanted with the placement of separate extra-ventricular and peritoneal drains in view of a possible VPS infection. The patient remained septic and critically ill even after removal of the VPS and administration of broad-spectrum antibiotics, requiring increasing inotropic and ventilatory support. CSF and peritoneal fluid cultures were negative. There were 2–3 L of serous fluid drainage from the peritoneal drain daily and multiple samples of peritoneal fluid sent for cytology and culture did not show any malignant cells or infective organisms.

Diagnostic laparoscopy was attempted to elucidate the cause of persistent sepsis, but conversion to a laparotomy was necessary due to dense intra-abdominal adhesions. Intra-operatively, the peritoneal surfaces, greater omentum, serosal surfaces, and mesentery of the small and large bowel were studded with multiple flesh-colored tumor nodules. Histopathological examination of a segment of greater omentum revealed adipose tissue coated and infiltrated by an extensively necrotic tumor which was



**Figure 1:** (a) Magnetic resonance imaging scan of the brain showing the initial left temporal mass prior to surgery. (b) Magnetic resonance imaging scan of the brain showing tumor recurrence 5 months after initial surgery. (c) Computed tomography scan of the brain showing tumor recurrence 6 months after diagnosis and after two separate tumor resections



**Figure 2:** (a) Histology of brain tumor showing meningothelial tumor composed predominantly of cells with abundant eosinophilic cytoplasm, and enlarged eccentrically placed nuclei, with occasional prominent nucleoli, consistent with rhabdoid meningioma (H and E,  $\times 400$ ). (b) Extensive geographical tumor necrosis in the tumor (H and E,  $\times 100$ ). (c) Positive immunostaining of the tumor cells with epithelial membrane antigen ( $\times 200$ )

composed of predominantly epithelioid cells with moderate amount of clear or eosinophilic cytoplasm and marked pleomorphic, irregular, and hyperchromatic with prominent nucleoli [Figure 4a]. Some tumor cells had a rhabdoid appearance [Figure 4b], with eccentric nuclei displaced by rounded intracytoplasmic eosinophilic inclusions, and some had a spindled appearance. The tumor cells stained strongly with vimentin and EMA [Figure 4c]. Morphologically and immunohistochemically, the omental biopsy was similar to that of the primary brain tumor which supports the diagnosis of IAM from the primary brain tumor via the VPS. The patient continued to deteriorate and subsequently died 4 days after laparotomy, secondary to massive bilateral pulmonary embolism.

## Discussion

Rhabdoid meningioma is a highly aggressive tumor with a high recurrence rate and poor prognosis. A recent systematic review showed that out of 48 patients with rhabdoid meningioma, almost 50% died within 1 year of surgery and two-thirds had tumor recurrence, with calculated 3- and 5-year recurrence-free survival rates of 41.4% and 27.6%, respectively. It also showed that metastasis most commonly disseminate through the CSF to the spinal cord or other intracranial locations, but extraneural metastasis is rare.<sup>[10]</sup> Extraneural metastasis to the lung, parotid gland, and liver have been reported and are most likely due to hematogenous seeding.<sup>[10-12]</sup> Tumor dissemination via VPS to the peritoneal cavity causing widespread intra-abdominal carcinomatosis have been reported in CNS tumors of other histological cell types, but to our knowledge, not in rhabdoid meningioma. In our case, we believe that the VPS was the conduit for the transcelomic spread of malignant cells that were present in the CSF into the peritoneal cavity leading to widespread intra-abdominal carcinomatosis. The patient had no abdominal symptoms 5 months after the initial diagnosis of rhabdoid meningioma and symptoms

of abdominal distension and pain only started 1 month after placement of the VPS – sufficient time for malignant cells to deposit and grow within the peritoneal cavity. Furthermore, there was no evidence of other synchronous primary malignancies that could have accounted for the intra-abdominal carcinomatosis and the metastatic lesions found in the abdomen had similar histopathological and immunohistochemical morphology as that of the primary rhabdoid meningioma.

A survey of the literature published from 1979 to 2014, pertaining specifically to patients diagnosed with primary CNS tumors with subsequent IAM from VPS, was conducted. Thirty-eight articles with a total of 43 patients were reviewed [Table 1].<sup>[13-50]</sup> The mean age of patients was 15 years and 3 months, with 69.8% (30 out of 43) of the patients in the pediatric age group (<18 years of age), and 67.4% male (29 out of 43). The overall predominant histological subtypes of primary CNS tumors with VPS-related metastasis were germinomas (11 out of 43, 25.6%) and medulloblastomas (5 out of 43, 11.6%). Other common histological subtypes include endodermal sinus tumors (4 out of 43, 9.3%), glioblastomas (4 out of 43, 9.3%) and atypical teratoid/rhabdoid tumors (3 out of 43, 7.0%). In the adult age group ( $\geq 18$  years of age), germinomas and medulloblastomas remain the predominant histological subtype at 38.5% (5 out of 13) and 15.4% (2 out of 13) of patients, respectively. The mean time interval from VPS insertion to the occurrence of IAM was 21 months, with 74.3% (26 out of 35) occurring within 2 years of VPS insertion. The most common presenting symptoms of IAM were abdominal distension (41.7%, 15 out of 36), abdominal pain (36.1%, 13 out of 36), constipation (19.4%, 7 out of 36),

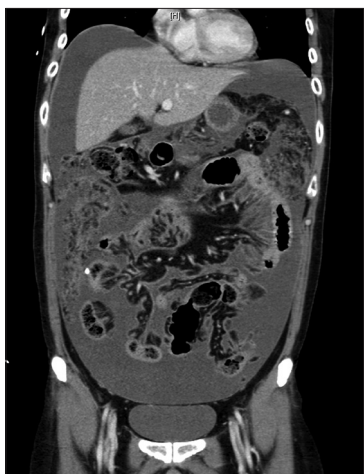

Figure 3: Computed tomography scan of the abdomen showing ascites with diffuse peritoneal enhancement with diffuse omental thickening and stranding

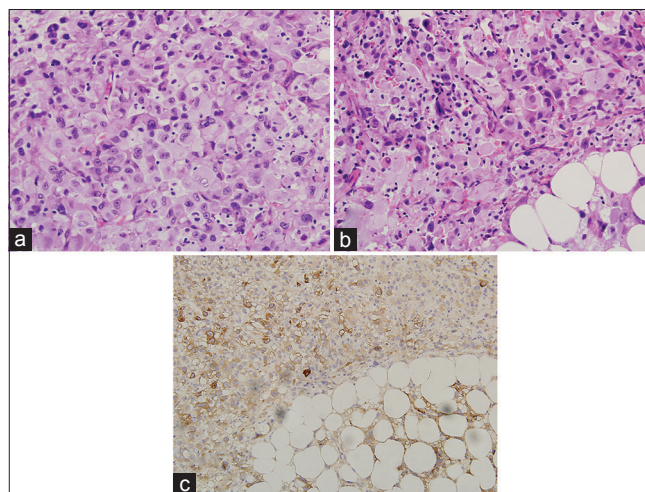


Figure 4: (a) Histology of omental biopsy showing tumor composed of predominantly epithelioid cells with moderate amount of clear or eosinophilic cytoplasm and markedly pleomorphic, irregular, hyperchromatic nuclei with prominent nucleoli, consistent with anaplastic meningioma (H and E,  $\times 400$ ). (b): Cells with rhabdoid appearance characterized by eccentric nuclei displaced by rounded intracytoplasmic eosinophilic inclusions (H and E,  $\times 400$ ). (c) Positive immunostaining of the tumor cells with epithelial membrane antigen ( $\times 200$ )

**Table 1: Review of 43 cases of ventriculoperitoneal shunt related intra-abdominal metastasis reported between 1979 and 2014**

Author	Primary central nervous system tumor	Age/gender	Presenting symptoms of intra-abdominal metastasis	Time to IAM after VPS insertion (months)	Nature of intra-abdominal metastasis	Treatment for intra-abdominal metastasis	Survival after diagnosis of IAM
Yoo <i>et al.</i> <sup>[13]</sup>	Melanotic neuroectodermal tumor of infancy	28 months/ female	Right groin pain and swelling	16	Ascites, peritoneal thickening	Chemotherapy	5 months
Han <i>et al.</i> <sup>[14]</sup>	Atypical teratoid/rhabdoid tumor	8 years/ female	Abdominal pain, constipation	11	Ascites, multiple abdominal masses	Nil	1 month
Pettersson <i>et al.</i> <sup>[15]</sup>	Anaplastic medulloblastoma	5 years/ male	Fever, nausea, vomiting, thoracoabdominal wall mass adjacent to VPS	3	Thoraco-abdominal wall mass along VPS tract, peritoneal nodules, thickened omentum	Chemotherapy	5 months
Belongia and Joga <sup>[16]</sup>	Mixed malignant germ cell tumor with predominant embryonal carcinoma component	7 years/ male	Asymptomatic, incidental finding on spinal imaging	5	Multiple intra-abdominal masses	Chemotherapy	10 months
Murray <i>et al.</i> <sup>[17]</sup>	Pineal germinoma	11 years/ female	Abdominal distension	17	Ascites, pelvic mass, peritoneal nodules	Chemotherapy, resection of mass	>34 months
Boyd <i>et al.</i> <sup>[18]</sup>	Primitive neuroectodermal tumor	23 months/ male	Abdominal distension, vomiting	7	Multiple abdominal masses	Nil	1 month
Cajaiba <i>et al.</i> <sup>[19]</sup>	Neurocutaneous melanocytosis	7 years/ male	NS	84	Ascites, peritoneal nodules	Nil	NS
	Neurocutaneous melanocytosis	4 months/ male	Abdominal distension	32	Ascites, peritoneal nodules	Chemotherapy	5 months
Yokosuka <i>et al.</i> <sup>[20]</sup>	High-grade glioma	12 years/ male	Abdominal pain and fullness	92	Ascites, multiple abdominal masses	Chemotherapy (systemic and intraperitoneal)	13 months
Loiacono <i>et al.</i> <sup>[21]</sup>	Medulloblastoma	35 years/ female	Abdominal pain, constipation	54	Ascites, pelvic and abdominal mass	Palliative resection of mass	NS
Ingold <i>et al.</i> <sup>[22]</sup>	Atypical teratoid/rhabdoid tumor	45 years/ female	Postmortem diagnosis	N/A	Multiple abdominal and peritoneal nodules	Nil	12 days
Donovan and Prauner <sup>[23]</sup>	Choroid plexus carcinoma	3 years/ male	Vomiting, poor nutritional intake	8	Fluid collection	Nil	NS
Yasuhara <i>et al.</i> <sup>[24]</sup>	Glioblastoma	47 years/ female	Postmortem diagnosis	N/A	Splenic nodule	Nil	NS
Magtibay <i>et al.</i> <sup>[25]</sup>	Medulloblastoma	37 years/ female	Urinary frequency	60	Pelvic, retroperitoneal and right upper abdominal masses	Chemotherapy, resection of mass	>10 months
Altundag <i>et al.</i> <sup>[26]</sup>	Pineal germinoma	23 years/ male	Abdominal distension	24	Ascites, pelvic mass, multiple liver nodules	Chemotherapy	>36 months
Thambi Dorai <i>et al.</i> <sup>[27]</sup>	Medulloblastoma	4 years/ male	Right inguinoscrotal swelling	24	Spermatic cord mass	Resection of mass, chemotherapy	6 months
Araki <i>et al.</i> <sup>[28]</sup>	Anaplastic ganglioglioma	53 years/ female	Abdominal distension	14	Ascites, peritoneal and omental nodules	Nil	1 month

Contd...

Table 1: Contd...

Author	Primary central nervous system tumor	Age/gender	Presenting symptoms of intra-abdominal metastasis	Time to IAM after VPS insertion (months)	Nature of intra-abdominal metastasis	Treatment for intra-abdominal metastasis	Survival after diagnosis of IAM
Korones et al. <sup>[29]</sup>	Atypical teratoid/rhabdoid tumor	4 years/female	Abdominal pain	13	Ascites, pelvic mass, peritoneal nodules	Nil	1 month
Rickert et al. <sup>[30]</sup>	Cerebral teratocarcinoma	24 years/male	Acute ileus	7	Abdominal mass	Resection of mass	1 month
Back et al. <sup>[31]</sup>	Pineal germinoma	10 years/male	Abdominal pain and distension	13	Abdominal mass	Chemoradiotherapy, resection of mass	>4 months
Wong et al. <sup>[32]</sup>	Pineal germinoma	23 years/male	Abdominal pain	13	Abdominal mass	Nil	<1 month
Pollack et al. <sup>[33]</sup>	Astrocytoma	6 months/male	Abdominal distension	2	Ascites	Chemotherapy	>60 months
Jamjoom et al. <sup>[34]</sup>	Medulloblastoma	6 years/male	Left scrotal swelling	10	Spermatic cord mass	Resection of mass	1 month
Ung et al. <sup>[35]</sup>	Pineal germinoma	13 years/male	Abdominal pain	37	Abdominal mass	Chemotherapy, resection of mass	>24 months
Newton et al. <sup>[36]</sup>	Glioblastoma multiforme	13 years/male	Abdominal distension, weight gain	NS	Ascites thickened omentum	Intraperitoneal chemotherapy	1 month
Jiménez-Jiménez et al. <sup>[37]</sup>	Astrocytoma	4 years/female	Abdominal distension	5	Ascites, peritoneal nodules	Nil	<1 month
Pallini et al. <sup>[38]</sup>	Pineal germinoma	15 years/male	Abdominal pain, constipation	2	Pelvic mass, peritoneal nodules	Nil	4 months
Kim et al. <sup>[39]</sup>	Pineal germinoma	36 years/male	Abdominal distension, vomiting	12	Ascites, peritoneal nodules	Chemotherapy	>6 months
Talamo and Mendelow <sup>[40]</sup>	Germinoma	25 years/male	Asymptomatic, liver function abnormalities	10	Ascites, multiple abdominal masses	Nil	1 month
Bamberg et al. <sup>[41]</sup>	Endodermal sinus tumor	16 years/male	Abdominal pain and distension, vomiting	3	Multiple abdominal masses	Nil	<1 month
Devkota et al. <sup>[42]</sup>	Pineal germinoma	12 years/male	Abdominal pain and distension, vomiting	24	Pelvic mass, peritoneal nodules	Nil	<1 month
Trigg et al. <sup>[43]</sup>	Optic glioma	3 years/male	Abdominal distension, constipation	4	Ascites	Chemotherapy	>12 months
Haimovic et al. <sup>[44]</sup>	Pineal germinoma	27 years/male	Constipation	36	Abdominal mass	Radiotherapy	NS
Kun et al. <sup>[45]</sup>	Germinoma	14 years/male	Abdominal pain, constipation	14	Pelvic mass	Radiotherapy	>38 months
Triolo and Schulz <sup>[46]</sup>	Pineal germinoma	15 years/male	Constipation, weight loss	NS	Pelvic and abdominal mass, peritoneal and omental nodules	Nil	21 months
Pasquier et al. <sup>[47]</sup>	Meningeal sarcoma	21 years/female	Postmortem diagnosis	N/A	Liver nodules	Nil	NS
Oberbauer et al. <sup>[48]</sup>	Oligodendroglioma	2 months/male	Postmortem diagnosis	N/A	Peritoneal and omental nodules	Nil	NS

Contd...

Table 1: Contd...

Author	Primary central nervous system tumor	Age/gender	Presenting symptoms of intra-abdominal metastasis	Time to IAM after VPS insertion (months)	Nature of intra-abdominal metastasis	Treatment for intra-abdominal metastasis	Survival after diagnosis of IAM
Wood <i>et al.</i> <sup>[49]</sup>	Pineal germinoma	11 years/male	Rectal discomfort	36	Pelvic mass	Chemoradiotherapy	>24 months
	Pineal germinoma	13 years/female	NS	10	Pelvic mass	Nil	<1 month
	Pineal germinoma	15 years/male	Abdominal pain and distension	36	Fluid collection	Chemotherapy	NS
Wilson <i>et al.</i> <sup>[50]</sup>	Endodermal sinus tumor	4 years/male	Postmortem diagnosis	N/A	Peritoneal and omental nodules	Nil	<1 month
	Endodermal sinus tumor	19 years/female	Abdominal pain and distension, vomiting, diarrhea	NS	Ascites	Chemotherapy	>30 months
	Endodermal sinus tumor	12 years/female	Difficulty with urination	6	Abdominal mass	Nil	1 month

IAM – Intra-abdominal metastasis; VPS – Ventriculoperitoneal shunt; NS – Not significant; NA – Not available

and vomiting (19.4%, 7 out of 36). The diagnosis of IAM was made after postmortem examination in five patients. Two patients presented with scrotal swelling due to tumor seeding of the spermatic cord via a concurrent hernia defect, and two patients were asymptomatic at the time of diagnosis – one had liver function test abnormalities which led to further imaging, and the other was diagnosed incidentally on follow-up spinal imaging. IAM most commonly manifested as ascites (39.5%, 17 out of 43), peritoneal/omental nodules or thickening (34.9%, 15 out of 43), abdominal masses (32.6%, 14 out of 43), and pelvic masses (25.6%, 11 out of 43). Treatment after diagnosis of IAM varied, with 42.1% (16 out of 38) of patients receiving chemotherapy of which two patients received intra-peritoneal chemotherapy. Eight patients (21.1%) underwent surgery to remove the metastatic tumors of which four of them received prior chemotherapy, radiotherapy, or both. Two patients received combined chemoradiotherapy; two patients received radiotherapy alone, and 15 patients (39.5%) had no further treatment after diagnosis of IAM. Survival outcomes in this particular group of patients were poor, with 45.7% (16 out of 35) of patients dying within 1 month and 57.1% (20 out of 35) dying within 1 year of diagnosis of IAM. There is neither particular histological subtype, nature of IAM, nor treatment modality that rendered a superior survival outcome. However, it is obvious that in our review of the literature, a higher incidence of VPS -related IAM is associated with pediatric patients, male gender, and primary intracranial germinomas or medulloblastomas. Our analysis is consistent with an older review by Rickert *et al.*, published in 1998, where patients with VPS -related IAM mainly belonged to the pediatric age group with an overall male predominance and that the most common histological subtypes of primary CNS tumors were germinomas (25.7%) and medulloblastomas (22.9%).<sup>[30]</sup>

With the VPS serving as a conduit for CSF flow from the ventricular cavity into the abdomen, it is a rare but possible means for dissemination of tumor cells, especially in patients with highly aggressive primary tumors that recur or are not completely removed, or tumors that tend to spread via CSF. There have even been cases reported of primary abdominopelvic tumors seeding into the CNS in a retrograde fashion via the VPS.<sup>[51,52]</sup> In an attempt to prevent the metastasis of tumor cells, a Millipore filter can be placed at the distal peritoneal end of the VPS. However, obstruction due to plugging of the shunt was a commonly reported complication.<sup>[21,53]</sup> A CSF irradiation filter, which exposes draining CSF to a localized high-intensity radiation field adequately shielded from surrounding tissue, did not produce promising results either.<sup>[54]</sup> Alternative forms of CSF drainage have also been explored. Placement of only an external ventricular drain can prevent IAM, but patients are at high risk of developing drain-related infections such as ventriculitis or meningitis, which may result in significant morbidity and mortality.<sup>[55]</sup> Endoscopic third ventriculostomy is a safe and effective method to relieve obstructive hydrocephalus in caused by midline tumors and can be a substitute for a VPS in selected cases.<sup>[56]</sup> Matsumoto *et al.* developed a percutaneous long-tunneled ventricular drainage (PLTVD) to be used for highly malignant intracranial tumors such as germ cell tumors (GCTs) and medulloblastomas. This involved the cannulation of the frontal horn of the lateral ventricle with a ventricular catheter that was connected to a flow-controlled CSF reservoir. A peritoneal catheter proximally connected to the reservoir was then subcutaneously tunneled, exiting at the upper abdomen and connected to a drainage system. A study of 13 patients who presented with medulloblastoma or GCT showed zero cases of extraneural metastasis or infections using this method;

however, PLTVD had to be converted to a VPS in one case of communicating hydrocephalus due to dissemination and two cases of adhesive aqueductal stenosis not related to the tumor.<sup>[57]</sup>

## Conclusion

We report the index case of a rhabdoid meningioma metastasizing through the VPS into the peritoneal cavity causing widespread intra-abdominal carcinomatosis. As IAM through a VPS is an unusual phenomenon, whether or not the placement of a VPS increases the risk of a patient with a primary intracranial tumor developing IAM remains controversial, and the lack of statistical evidence means that the management and treatment of patients who require a VPS should not be changed. Alternative means of CSF drainage or diversion such as PLTVD merits further discussion and risk-benefit assessment. Meanwhile, clinicians should maintain a high index of suspicion in patients with a primary intracranial tumor and VPS presenting with abdominal symptoms for IAM, upon which a low threshold for abdominopelvic imaging should be maintained.

## Financial support and sponsorship

Nil.

## Conflicts of interest

There are no conflicts of interest.

## References

1. CBTRUS. Statistical Report: Primary Brain and Central Nervous System Tumours Diagnosed in the United States in 2004-2006. Hinsdale, IL: Central Brain Tumour Registry of the United States; 2010.
2. Wiemels J, Wrensch M, Claus EB. Epidemiology and etiology of meningioma. *J Neurooncol* 2010;99:307-14.
3. Kepes JJ, Moral LA, Wilkinson SB, Abdullah A, Llena JF. Rhabdoid transformation of tumor cells in meningiomas: A histologic indication of increased proliferative activity: Report of four cases. *Am J Surg Pathol* 1998;22:231-8.
4. Perry A, Scheithauer BW, Stafford SL, Abell-Aleff PC, Meyer FB. "Rhabdoid" meningioma: An aggressive variant. *Am J Surg Pathol* 1998;22:1482-90.
5. Louis DN, Budka H, von Deimling A, Kepes JJ. Meningiomas. In: Kleihues P, Cavenee WK, International Agency for Research on Cancer, editors. *World Health Organization Classification of Tumours Pathology and Genetics of Tumours of the Nervous System*. Lyon: IARC Press; 2000. p. 314.
6. Louis DN, Ohgaki H, Wiestler OD, Cavenee WK, Burger PC, Jouvet A, *et al.* The 2007 WHO classification of tumours of the central nervous system. *Acta Neuropathol* 2007;114:97-109.
7. Willis J, Smith C, Ironside JW, Erridge S, Whittle IR, Everington D. The accuracy of meningioma grading: A 10-year retrospective audit. *Neuropathol Appl Neurobiol* 2005;31:141-9.
8. Maclean J, Fersht N, Short S. Controversies in radiotherapy for meningioma. *Clin Oncol (R Coll Radiol)* 2014;26:51-64.
9. Piatt JH Jr, Garton HJ. Clinical diagnosis of ventriculoperitoneal shunt failure among children with hydrocephalus. *Pediatr Emerg Care* 2008;24:201-10.
10. Zhou Y, Xie Q, Gong Y, Mao Y, Zhong P, Che X, *et al.* Clinicopathological analysis of rhabdoid meningiomas: Report of 12 cases and a systematic review of the literature. *World Neurosurg* 2013;79:724-32.
11. Parameshwaran Nair R, Vinod, Sarma Y, Nayal B, Kaur Dil S, Tripathi PK. Metastatic rhabdoid meningioma of the parotid – Mimicking primary salivary gland neoplasm. *Int J Surg Case Rep* 2015;6C:104-6.
12. Wang Z, Kong M, Li J, Xiao W, Zheng S. Intraspinal rhabdoid meningioma metastasis to the liver. *J Clin Neurosci* 2011;18:714-6.
13. Yoo IH, Yum SK, Oh SJ, Kim KM, Jeong DC. Melanotic neuroectodermal tumor of infancy disseminated by a ventriculoperitoneal shunt and diagnosed from the inguinal sac. *J Pediatr Hematol Oncol* 2014;36:e61-4.
14. Han YP, Zhao Y, He XG, Ma J. Peritoneal metastasis of third ventricular atypical teratoid/rhabdoid tumor after VP shunt implantation for unexplained hydrocephalus. *World J Pediatr* 2012;8:367-70.
15. Pettersson D, Schmitz KR, Pollock JM, Hopkins KL. Medulloblastoma: Seeding of VP shunt tract and peritoneum. *Clin Pract* 2012;2:e37.
16. Belongia M, Jugal S. Extraneural metastasis of a nongerminomatous germ cell tumor of the central nervous system in a pediatric patient with a ventriculoperitoneal shunt: A case report and review of the literature. *J Pediatr Hematol Oncol* 2012;34:e12-6.
17. Murray MJ, Metayer LE, Mallucci CL, Hale JP, Nicholson JC, Kirollos RW, *et al.* Intra-abdominal metastasis of an intracranial germinoma via ventriculo-peritoneal shunt in a 13-year-old female. *Br J Neurosurg* 2011;25:747-9.
18. Boyd DT, Hayeri MR, Vyas PK. Supratentorial primitive neuroectodermal tumor metastasis to the abdomen via a ventriculoperitoneal shunt. *Pediatr Radiol* 2010;40 Suppl 1:S123-6.
19. Cajaiba MM, Benjamin D, Halaban R, Reyes-Múgica M. Metastatic peritoneal neurocutaneous melanocytosis. *Am J Surg Pathol* 2008;32:156-61.
20. Yokosuka K, Ishii R, Suzuki Y, Hirano K, Ishii N, Sekihara Y, *et al.* Extraneural metastasis of high grade glioma without simultaneous central nervous system recurrence: Case report. *Neurol Med Chir (Tokyo)* 2007;47:273-7.
21. Loiacono F, Morra A, Venturini S, Balestreri L. Abdominal metastases of medulloblastoma related to a ventriculoperitoneal shunt. *AJR Am J Roentgenol* 2006;186:1548-50.
22. Ingold B, Moschopoulos M, Hutter G, Seeger H, Röthlisberger B, Landolt H, *et al.* Abdominal seeding of an atypical teratoid/rhabdoid tumor of the pineal gland along a ventriculoperitoneal shunt catheter. *Acta Neuropathol* 2006;111:56-9.
23. Donovan DJ, Prauner RD. Shunt-related abdominal metastases in a child with choroid plexus carcinoma: Case report. *Neurosurgery* 2005;56:E412.
24. Yasuhara T, Tamiya T, Meguro T, Ichikawa T, Sato Y, Date I, *et al.* Glioblastoma with metastasis to the spleen – Case report. *Neurol Med Chir (Tokyo)* 2003;43:452-6.
25. Magtibay PM, Friedman JA, Rao RD, Buckner JC, Cliby WA. Unusual presentation of adult metastatic peritoneal medulloblastoma associated with a ventriculoperitoneal shunt: A case study and review of the literature. *Neuro Oncol* 2003;5:217-20.
26. Altundag OO, Celik I, Kars A. Pineal germ cell tumor metastasis via ventriculoperitoneal shunt. *Am J Clin Oncol* 2002;25:104-5.
27. Thambi Dorai CR, Azmi A, Rahman AJ, Subathra S, Hayati AR,

- Zulfiqar A. Spermatic cord metastasis from a medulloblastoma. *Pediatr Surg Int* 2001;17:654-6.
28. Araki M, Fan J, Haraoka S, Moritake T, Yoshii Y, Watanabe T. Extracranial metastasis of anaplastic ganglioglioma through a ventriculoperitoneal shunt: A case report. *Pathol Int* 1999;49:258-63.
  29. Korones DN, Meyers SP, Rubio A, Torres C, Constine LS. A 4-year-old girl with a ventriculoperitoneal shunt metastasis of a central nervous system atypical teratoid/rhabdoid tumor. *Med Pediatr Oncol* 1999;32:389-91.
  30. Rickert CH, Reznik M, Lenelle J, Rinaldi P. Shunt-related abdominal metastasis of cerebral teratocarcinoma: Report of an unusual case and review of the literature. *Neurosurgery* 1998;42:1378-82.
  31. Back MR, Hu B, Rutgers J, French S, Moore TC. Metastasis of an intracranial germinoma through a ventriculoperitoneal shunt: Recurrence as a yolk-sac tumor. *Pediatr Surg Int* 1997;12:24-7.
  32. Wong KT, Koh KB, Lee SH, Chee CP. Intracranial germinoma metastasizing via a ventriculo-peritoneal shunt. *Singapore Med J* 1996;37:441-2.
  33. Pollack IF, Hurtt M, Pang D, Albright AL. Dissemination of low grade intracranial astrocytomas in children. *Cancer* 1994;73:2869-78.
  34. Jamjoom ZA, Jamjoom AB, Sulaiman AH, Naim-Ur-Rahman, al Rabiaa A. Systemic metastasis of medulloblastoma through ventriculoperitoneal shunt: Report of a case and critical analysis of the literature. *Surg Neurol* 1993;40:403-10.
  35. Ung AO, Triscott JA, Leditschke JF, Smith JA. Metastasis of pineal germinoma via ventriculoperitoneal shunt. *Aust N Z J Surg* 1993;63:409-12.
  36. Newton HB, Rosenblum MK, Walker RW. Extraneural metastases of infratentorial glioblastoma multiforme to the peritoneal cavity. *Cancer* 1992;69:2149-53.
  37. Jiménez-Jiménez FJ, Garzo-Fernández C, De Inovenio-Arocena J, Pérez-Sotelo M, Castro-De Castro P, Salinero-Paniagua E. Extraneural metastases from brainstem astrocytoma through ventriculoperitoneal shunt. *J Neurol Neurosurg Psychiatry* 1991;54:281-2.
  38. Pallini R, Bozzini V, Scerrati M, Zuppi C, Zappacosta B, Rossi GF. Bone metastasis associated with shunt-related peritoneal deposits from a pineal germinoma. Case report and review of the literature. *Acta Neurochir (Wien)* 1991;109:78-83.
  39. Kim K, Koo BC, Delaflor RR, Shaikh BS. Pineal germinoma with widespread extracranial metastases. *Diagn Cytopathol* 1985;1:118-22.
  40. Talamo TS, Mendelow H. Primary intracranial germinoma with massive ventriculoperitoneal shunt metastases. *J Surg Oncol* 1985;28:39-41.
  41. Bamberg M, Metz K, Alberti W, Heckemann R, Schulz U. Endodermal sinus tumor of the pineal region. Metastases through a ventriculoperitoneal shunt. *Cancer* 1984;54:903-6.
  42. Devkota J, Brooks BS, el Gammal T. Ventriculoperitoneal shunt metastasis of a pineal germinoma. *Comput Radiol* 1984;8:141-5.
  43. Trigg ME, Swanson JD, Letellier MA. Metastasis of an optic glioma through a ventriculoperitoneal shunt. *Cancer* 1983;52:599-601.
  44. Haimovic IC, Sharer L, Hyman RA, Beresford HR. Metastasis of intracranial germinoma through a ventriculoperitoneal shunt. *Cancer* 1981;48:1033-6.
  45. Kun LE, Tang TT, Sty JR, Camitta BM. Primary cerebral germinoma and ventriculoperitoneal shunt metastasis. *Cancer* 1981;48:213-6.
  46. Triolo PJ, Schulz EE. Metastatic germinoma (pinealoma) via a ventriculoperitoneal shunt. *AJR Am J Roentgenol* 1980;135:854-5.
  47. Pasquier B, Pasquier D, N'Golet A, Panh MH, Couderc P. Extraneural metastases of astrocytomas and glioblastomas: Clinicopathological study of two cases and review of literature. *Cancer* 1980;45:112-25.
  48. Oberbauer RW, Tritthart H, Ascher PW, Walter GF, Becker H. Shunt metastases in posterior fossa tumors. *Neuropadiatrie* 1979;10:296-300.
  49. Wood BP, Haller JO, Berdon WE, Lin SR. Shunt metastases of pineal tumors presenting as a pelvic mass. *Pediatr Radiol* 1979;8:108-9.
  50. Wilson ER, Takei Y, Bikoff WT, O'Brien MS, Tindall GT, Boehm WM. Abdominal metastases of primary intracranial yolk sac tumors through ventriculoperitoneal shunts: Report of three cases. *Neurosurgery* 1979;5:356-64.
  51. Eralp Y, Saip P, Aydin Z, Berkman S, Topuz E. Leptomeningeal dissemination of ovarian carcinoma through a ventriculoperitoneal shunt. *Gynecol Oncol* 2008;108:248-50.
  52. Harada K, Nishizaki T, Kwak T, Fujisawa H, Nishikawa M, Ito H. Intracranial metastasis of Wilms' tumor involving the tectal plate without pulmonary involvement. Case report. *Pediatr Neurosurg* 1999;30:331-4.
  53. Reynolds AF, Weinstein PR, Johnson PC. Adenocarcinoma cells trapped on a millipore filter in a patient with meningeal carcinomatosis. *Neurosurgery* 1980;7:179-81.
  54. Halperin EC, Samulski T, Oakes WJ, Friedman HS. Fabrication and testing of a device capable of reducing the incidence of ventricular shunt promoted metastasis. *J Neurooncol* 1996;27:39-46.
  55. Lwin S, Low SW, Choy DK, Yeo TT, Chou N. External ventricular drain infections: Successful implementation of strategies to reduce infection rate. *Singapore Med J* 2012;53:255-9.
  56. O'Brien DF, Hayhurst C, Pizer B, Mallucci CL. Outcomes in patients undergoing single-trajectory endoscopic third ventriculostomy and endoscopic biopsy for midline tumors presenting with obstructive hydrocephalus. *J Neurosurg* 2006;105 3 Suppl:219-26.
  57. Matsumoto J, Kochi M, Morioka M, Nakamura H, Makino K, Hamada J, *et al.* A long-term ventricular drainage for patients with germ cell tumors or medulloblastoma. *Surg Neurol* 2006;65:74-80.