



## Case report

# Liver transplantation in a patient with complete portal vein thrombosis, is there a surgical way out? A case report



Tommaso Maria Manzia, Laura Fazzolari, Matteo Manuelli, Marco Pellicciaro, Leonardo Baiocchi, Giuseppe Tisone\*

Department of Experimental Medicine and Surgery, Liver Unit, Tor Vergata University of Rome, Viale Oxford n.81, 00133, Rome, Italy

## HIGHLIGHTS

- The Yerdel III–IV portal vein thrombosis should not be considered an absolute contraindication to liver transplantation
- The identification of a well represented spleno-renal shunt on the pre-operative imaging is essential to plan a liver transplantation
- Since the high risk surgery a transplant benefit must be evaluated in order to estimate the gain in terms of survival
- The operation must be lead by a high experienced liver transplant surgeon

## ARTICLE INFO

## Article history:

Received 8 May 2016

Received in revised form

4 August 2016

Accepted 4 August 2016

## Keywords:

Portal vein thrombosis

Spleno-renal shunt

Liver transplantation

Case report

## ABSTRACT

**Introduction:** Due to the complexity of the surgical procedure portal vein thrombosis (PVT) has long been considered an absolute contraindication to liver transplantation (LT). The presence of a large spleno-renal shunt (SRS) could make portal anastomosis a valid option.

**Presentation of case:** We report the case of a 37-year-old female patient with Grade III PVT and a large SRS, who underwent orthotopic LT. Liver was implanted using a 1992-Belghiti piggyback technique and portal anastomosis was performed using the large spleno-renal shunt. We observed good graft reperfusion and postoperative Doppler ultrasound showed normal portal vein flow. She was discharged on postoperative day 7, with an excellent graft function. At six months follow-up, patient is alive with normal hepatic vascularization.

**Discussion:** Due to paucity of reports, there is currently no consensus on the indication to LT and/or surgical technique. In the present case, once the transplant benefit was evaluated, the Grade III PVT was not considered a contraindication to LT.

**Conclusion:** The presence of a Grade III PVT associated with a large SRS should not be considered a contraindication for LT, and the use of the shunt vein should be considered a feasible option to perform portal anastomosis.

© 2016 The Author(s). Published by Elsevier Ltd on behalf of IJS Publishing Group Ltd. This is an open access article under the CC BY-NC-ND license (<http://creativecommons.org/licenses/by-nc-nd/4.0/>).

## 1. Introduction

Portal vein thrombosis (PVT) is a complication of chronic liver disease. It is typically associated with portal vein hypertension and porta-cava shunts, with the formation of venous collaterals that

bypass the narrowed or occluded portal vein, forming ‘surrounding portal vein cavernoma’ or spontaneous *real anatomical* porto-systemic shunts. Of these shunts, the most common, with a prevalence of 20–35% in liver transplantation (LT) candidates [1] is the spleno-renal shunt (SRS).

Although PVT has long been considered an absolute contraindication to LT, it is currently regarded as a relative contraindication, depending on the type of PVT, patient clinical status, and obviously, the surgeon’s experience. In the year 2000, the Birmingham Group graded PVT according to operative findings, as shown in Table 1 [2]. If, on the one hand, the natural SRS protects from variceal development by avoiding fatal bleeding, on the other, it complicates

Abbreviations: PVT, portal vein thrombosis; LT, liver transplantation; SRS, spleno-renal shunt; CT, computed tomography scan; ICU, Intensive Care Unit; LRV, left renal vein.

\* Corresponding author.

E-mail address: [tomanzia@libero.it](mailto:tomanzia@libero.it) (G. Tisone).

**Table 1**  
Birmingham Group Classification of Portal Vein Thrombosis findings during liver transplant procedure [2].

Yerdel grade	Description
I	Minimally or partially thrombosed PV, in which the thrombus is mild or, at the most, confined to 50% of the vessel lumen with or without minimal extension into the SMV
II	>50% occlusion of the PV, including total occlusions, with or without minimal extension into the SMV
III	Complete thrombosis of both PV and proximal SMV. Distal SMV is open.
IV	Complete thrombosis of the PV and proximal as well as distal SMV

SMV: superior mesenteric vein; PV: portal vein.

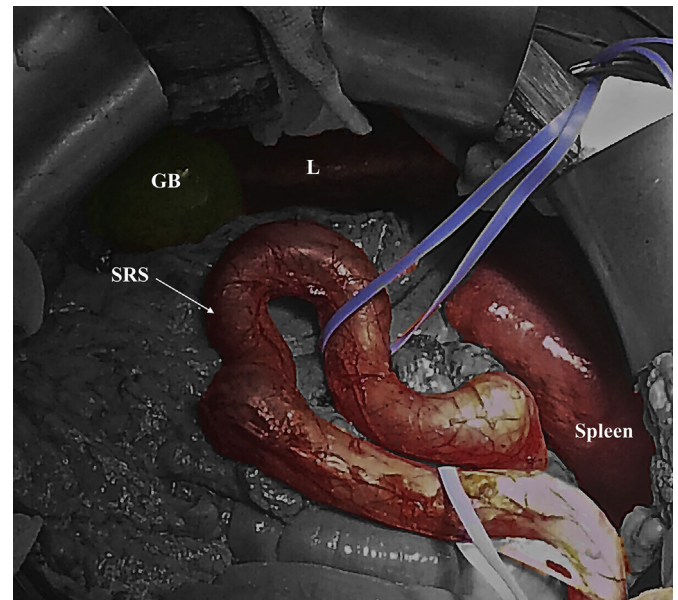
surgery because of the difficulties of retroperitoneal dissection and preparation of the shunt.

We report the case of a young patient with pre-operative *Grade III* PVT, associated with SRS, who subsequently underwent LT for autoimmune cirrhosis. The present case is in line with the CARE criteria [3]. We searched for published studies that described LT in recipients with preoperative PVT Grade III or IV in PubMed (<http://www.ncbi.nlm.nih.gov/pubmed>).

## 2. Presentation of case

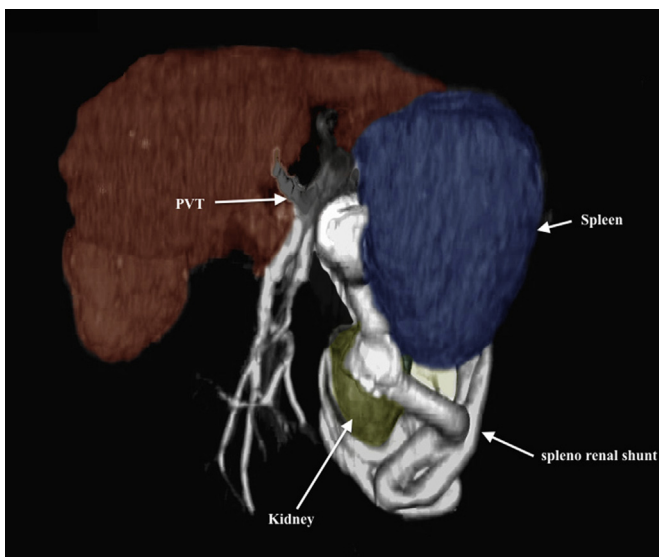
A 37-year-old female patient with autoimmune hepatitis/primary biliary cirrhosis overlap syndrome underwent deceased-donor LT. Pre-operative computed tomography (CT) scan showed extensive thrombosis of the portal vein extending to the origin of the SMV [Yerdel Grade 3 (2)], with severe porto-systemic collateral veins, including a SRS > 1 cm in diameter (Fig. 1). At the time of LT, the Model End-Stage Liver Disease score was 24 and the Mayo Risk Score was 9.0.

After right subcostal incision, we accessed the omentum retrocavity in order to expose the large SRS and verify the usability of the vein so as to safely perform a portal venous shunt anastomosis. Since a calcific portal vein sclerosis extending into the proximal superior mesenteric vein was confirmed, portal thrombectomy was ruled out; hence the proximal (splenic side) and distal (renal side) SRS were prepared circumferentially and the small vessels arising from the shunt ligated (Fig. 2). We performed the transplant procedure using a 1992-Belghiti piggyback technique [4]. The SRS was sectioned at the confluence to the left renal vein after side to side

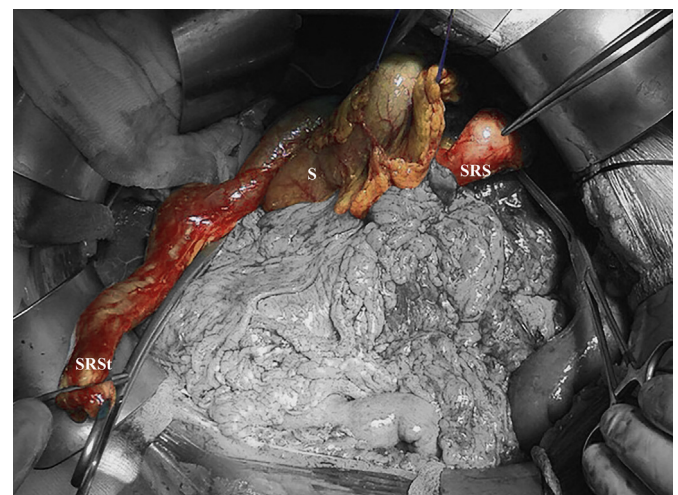


**Fig. 2.** Spleno-renal shunt after surgeon dissection. On the blue vessel loop the splenic and renal side of the shunt SRS: spleno-renal shunt; GB: Gallbladder; L: Liver.

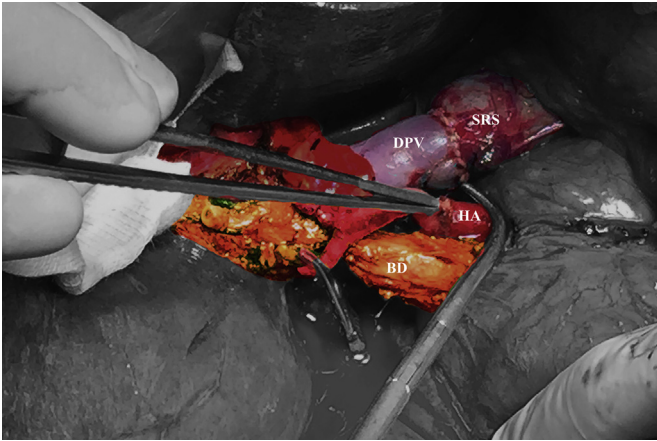
vena cava anastomosis and the renal side was brought behind the stomach (Fig. 3); A running suture, with a 5/0 prolene stitch, was used to perform a T-T anastomosis between portal vein and venous-shunt (Fig. 4). We observed good graft reperfusion without surgical or medical problems. The intraoperative Doppler ultrasound



**Fig. 1.** Preoperative Radiological Imaging 3D. In white, the massive and tortuous shunt arising from splenic and reaches left renal vein. PVT: portal vein thrombosis.



**Fig. 3.** The "spleno-renal shunt stump". The shunt sectioned at the confluence of left renal vein was brought behind to the stomach to safely perform portal anastomosis. S: Stomach; SRSt: Spleno renal stump; SRS: spleno-renal shunt.



**Fig. 4.** Portal anastomosis. The portal vein was anastomosed to the renal side of the shunt vein using a 5-0 prolene running suture. DPV: Donor Portal Vein; BD: Bile Duct; HA: Hepatic Artery.

showed a mean portal vein flow of 16.4 cm/sec (nv > 15 cm/sec) [5]. The cold ischemic time was 5.40 hours and warm ischemic time was 50 minutes. Total operative time was 7 hours. During the operation the patient required transfusion of three red blood cell units and eight fresh plasma units. The patient was kept in the Intensive Care Unit (ICU) 24 hours. Post-operative course was uneventful and the liver ultrasounds performed at 1, 3 and 7 post-operative days were comparable to intra-operative sonography. Subcutaneous low molecular weight heparin was given from day 1, at dosage of 4000 UI/day, in order to prevent portal thrombosis. Patient was discharged on postoperative day 7 with excellent graft function. After hospital discharge, the patient was treated with warfarin at starting dose of 5 mg and the therapy was adjusted after outpatient visit to maintain PT-INR between 2 and 3.

Eight months after LT, the patient is in good clinical condition with normal portal flow.

### 3. Discussion

In the early 1990s, PVT ceased to be considered a contraindication for LT [6]. Although most authors agree that there is no contraindication for Grades I-II, the procedure is questionable in patients with advanced PVT (Grade III and IV); this condition, in fact, increases mortality and morbidity rate during or immediately after LT by 50%, thus excluding LT in these candidates [2–7]. PVT has been associated with increased operative times, more red blood cell transfusions, higher rate of reoperation, longer ICU and hospital stays [8]. Currently there is no standard surgical technique for performing LT in PVT patients; jump vascular graft with venous conduit, renal-portal anastomosis or cavo-portal hemi-transposition are surgical options available for managing PVT discovered during surgery [9]. In fact, although a complete vascular evaluation with CT-scan is usually performed before LT, nearly half of PVT cases are found accidentally during the LT procedure [10].

In the context of greatly advanced cirrhosis, the incidence of SRS is approximately 30% [11]. Management of SRS remains controversial, as there is still no consensus on indications to LT and modalities of care. When PVT is associated with a large SRS, splenectomy and Portal-SRS anastomosis represent a therapeutic option in case of hypersplenism, in order to avoid postoperative portal steal syndrome and ensure an adequate flow to the liver. Other authors suggest the ligation of left renal vein (LRV) and portal-renal anastomosis as an option to overcome complete mesenteric-portal thrombosis [12–14].

In our case, the preoperative enhanced CT-scan clearly showed *Grade III PVT* and SRS. A multidisciplinary meeting (including a radiologist, a hepatologist and a transplant surgeon) was held to evaluate the pros and cons of liver transplantation. Given the age of the patient (37 years), and the 20% estimated survival expectancy without transplantation (according to Mayo Clinic Risk score, [www.mayoclinic.org](http://www.mayoclinic.org)) the patient was put on the Regional Liver Transplant waiting list despite surgical complexity and the intra- and post-operative risks. During surgery, given the presence of a large shunt and good blood flow towards to the left renal vein (confirmed by intraoperative sonography), we followed the vein to the renal side. A second check on flow direction was performed after clamping the shunt at mid-length, noting the deflation of the shunt on the renal side and a greater filling on the splenic side. We therefore decided to preserve the renal vein and perform the anastomosis on the renal side of the shunt; moreover, since there was no hypersplenism, splenectomy was avoided, thus preventing immune damage and other surgical complications [13].

### 4. Conclusion

Since nowadays there is no surgical consensus on portal revascularization in case of *Grade III-IV PVT*, the use of SRS for portal anastomosis on the renal shunt side could represent a valid option, once flow direction has been confirmed by intraoperative ultrasound.

Cases with unusable portal veins in the context of large retroperitoneal-shunt development should not necessarily be considered a contraindication to LT. A multidisciplinary meeting including liver surgeons, radiologists and hepatologist is crucial to evaluate both the feasibility of surgery and transplant benefit. Finally, liver transplantation surgery in the PVT setting must always be led by a highly experienced liver transplant surgeon, due to the complexity of the surgery involved.

### Ethical Approval

Since the current manuscript is not a research study but a descriptive case report, the paper was not submitted for ethical committee consideration.

### Sources of funding

No funding sources were received to support the study.

### Author contribution

Tommaso Maria Manzia, Laura Fazzolari wrote the paper; Marco Pellicciaro and Matteo Manuelli take and edit the photos. Giuseppe Tisone and Leonardo Baiocchi edit and revised the paper and all authors approved the final version of the manuscript.

### Conflicts of interest

Tommaso Maria Manzia, Laura Fazzolari, Marco Pellicciaro, Matteo Manuelli, Leonardo Baiocchi and Giuseppe Tisone disclose any financial and personal relationships with other people or organisations that could inappropriately influence this manuscript.

### Guarantor

Prof. Giuseppe Tisone.

## Acknowledgments

The authors thank Ms Serena Rotunno for English editing.

## References

- [1] N. Awad, M.M. Horrow, A. Parkisia, P. Brady, R. Zaki, M.D.C. Fishman, et al., Perioperative management of spontaneous splenorenal shunts in orthotopic liver transplant patients, *ExpClin Transpl.* 10 (2012) 475–481.
- [2] M.A. Yerdel, B. Gunson, D. Mirza, K. Karayalçin, S. Olliff, J. Buckels, et al., Portal vein thrombosis in adults undergoing liver transplantation: risk factors, screening, management, and outcome, *Transplantation* 69 (2000) 1873–1881.
- [3] <http://www.care-statement.org/>.
- [4] J. Belghiti, R. Noun, A. Sauvanet, Temporary portocaval anastomosis with preservation of caval flow during orthotopic liver transplantation, *Am. J. Surg.* 169 (1993) 277–279.
- [5] L.N. Uzochukwu, E.I. Bluth, D.H. Smetherman, L.A. Troxclair, G.E. Loss Jr., A. Cohen, et al., Early postoperative hepatic sonography as a predictor of vascular and biliary complications in adult orthotopic liver transplant patients, *AJR Am. J. Roentgenol.* 185 (6) (2005 Dec) 1558–1570.
- [6] A.N. Langnas, W.C. Marujo, R.J. Stratta, R.P. Wood, D. Ranjan, C. Ozaki, B.W. Shaw Jr., A selective approach to preexisting portal vein thrombosis in patients undergoing liver transplantation, *Am. J. Surg.* 163 (1992) 132–136.
- [7] M.K. Schaubel DE, Guidinger, S.W. Biggins, J.D. Kalbfleisch, E.A. Pomfret, P. Sharma, Merion RM. Survival benefit-based deceased- donor liver allocation, *Am. J. Transpl.* 9 (2009) 970–981.
- [8] A. Doenecke, Ty Tsui, C. Zuelke, M.N. Scherer, A.A. Schnitzbauer, H.J. Schlitt, et al., Pre-existent portal vein thrombosis in liver transplantation: influence of preoperative disease severity, *ClinicalTransplant* 24 (2010) 48–55.
- [9] G. D'amico, G. Tarantino, M. Spaggiari, R. Ballarin, V. Serra, G. Rumpianesi, et al., Multiple ways to manage portal thrombosis during liver transplantation: surgical techniques and outcomes, *Transpl. Proc.* 45 (2013) 2692–2699.
- [10] J. Dumortier, Poncet G. CzyglikO, M.C. Blanchet, C. Boucaud, L. Henry, et al., Eversion thrombectomy for portal vein thrombosis during liver transplantation, *Am. J. Transpl.* 2 (10) (2002) 934–938.
- [11] F. Chikamori, S. Nishida, G. Selvaggi, P. Tryphonopoulos, J.I. Moon, D.M. Levi, et al., Effect of liver transplantation on spleen size, collateral veins, and platelet counts, *World J. Surg.* 34 (2010) 320–326.
- [12] N. Golse, P.O. Bucur, F. Faitot, M. Bekheit, G. Pittau, O. Ciacio, et al., Spontaneous splenorenal shunt in liver transplantation: results of left renal vein ligation versus renoportal anastomosis, *Transplantation* 99 (2015) 2576–2585.
- [13] N. Golse, K. Mohkam, A. Rode, S. Mezoughi, H. Demian, C. Ducerf, et al., Surgical management of large spontaneous portosystemicsplenorenal shunts during liver transplantation: splenectomy or left renal vein ligation? *Transpl. Proc.* 47 (2015) 1866–1876.
- [14] T. Kato, D.M. Levi, W. DeFaria, S. Nishida, A.G. Tzakis, Liver transplantation with renoportal anastomosis after distal splenorenal shunt, *Arch. Surg.* 135 (12) (2000 Dec) 1401–1404.