

ORIGINAL ARTICLE

Simplified negative pressure wound therapy: clinical evaluation of an ultraportable, no-canister system

Donald A Hudson¹, Kevin G Adams¹, Adriaan Van Huyssteen², Robin Martin³ & Elizabeth M Huddleston³

¹ Department of Plastic and Reconstructive Surgery, Groote Schuur Hospital and University of Cape Town, Cape Town, South Africa

² Orthopaedic Hip and Knee Surgery, Panorama Medi-Clinic, Cape Town, South Africa

³ Advanced Wound Management Division, Smith & Nephew Medical Ltd, Hull, UK

Key words

Closed surgical incision; Negative pressure wound therapy; Portable; Postoperative care; Wound healing

Correspondence to

EM Huddleston
Advanced Wound Management Division
Smith & Nephew Medical Ltd
PO Box 81
101 Hessle Road
Hull, UK
E-mail:
elizabeth.huddleston@smith-nephew.com

doi: 10.1111/iwj.12080

Hudson DA, Adams KG, Van Huyssteen A, Martin R, Huddleston EM. Simplified negative pressure wound therapy: clinical evaluation of an ultraportable, no-canister system. *Int Wound J* 2015; 12:195–201

Abstract

The aim of this study was to evaluate a prototype negative pressure wound therapy (NPWT) system that has been developed to simplify NPWT for wounds at the lower end of the acuity scale. The new device has a single preset pressure of -80 mmHg, is single use and operates without an exudate canister. The disposable NPWT system (PICO™) was tested in a prospective, non-comparative, multicentre clinical trial to assess device functionality and clinical acceptance. Twenty patients were recruited for a maximum treatment period of 14 days. The NPWT devices were fitted with data log chips to enable longitudinal assessment of negative pressure and leak rates during therapy. Sixteen (80%) patients had closed surgical wounds, two (10%) patients had traumatic wounds and two (10%) patients received meshed split thickness skin grafts. The mean study duration was 10.7 days (range: 5–14 days) and the mean dressing wear time per individual patient was 4.6 days (range: 2–11). Fifty-five percent of wounds had closed by the end of the 14-day study or earlier, with a further 40% of wounds progressing to closure. Real-time pressure monitoring showed continuous delivery of NPWT. Three cases are discussed representing different wound locations and different patient factors that can increase the risk of post-surgical complications. Clinical studies of the disposable NPWT system confirmed the ability of the simplified single-use device to function consistently over the expected wear time. The anticipated reduced costs, ease of use and increased mobility of patients using this system may enable NPWT benefits to be available to a greater proportion of patients.

Introduction**The evolution of negative pressure wound therapy (NPWT)**

Since its inception, NPWT has revolutionised the management and outcome of many different wound types including chronic wounds such as diabetic foot ulcers (1), pressure ulcers (2) and venous leg ulcers (3) as well as acute or traumatic wounds such as split thickness skin grafts (STSGs) (4), burns (5), orthopaedic or soft tissue traumatic wounds (6) and to prevent infection or dehiscence in closed surgical incisions (7).

The copyright line for this article was changed on 17 July 2013 after original online publication.

Key Messages

- studies were carried out to evaluate a novel portable single-use NPWT system that does not require a canister for exudate management, but uses a patented multi-layer dressing that allows greater mobility and patient compliance
- the use of NPWT as a postoperative system to manage closed incisions in high-risk patients is a relatively new concept with a growing body of evidence. Single-use, lower cost devices are likely to be important in expanding NPWT for use as a widespread preventative therapy, with the potential of reducing

short-term hospital readmissions caused by wound-healing problems

- twenty patients, most of them with higher risk of wound-healing complications, were treated using PICO. Fifty-five percent of wounds had closed by the end of the 14-day study or earlier, with a further 40% of wounds progressing to closure. Of the surgical incisions, 11 of 16 (69%) were closed by the end of the study (14 days); 4 were progressing to closure and 1 was static
- this study has demonstrated the ability of the simplified PICO device to operate reliably in a clinical setting and provide good clinical outcomes
- the anticipated reduced costs, ease of use and increased mobility of patients using this system may enable NPWT benefits to be available to a greater proportion of patients

NPWT is undergoing a period of rapid innovation as manufacturers begin to work with clinicians and patients in order to develop improvements to the equipment and everyday practice. Initial NPWT devices were large and cumbersome. Patient mobility was frequently compromised with devices often clamped to IV stands or attached to a bed or wheel chair. NPWT has increasingly been seen as an enabling technology with which to move suitable patients out of the high-cost acute care hospital environment into the home. Smaller, more portable pumps have steadily been introduced to improve patient mobility and implicitly, perhaps, their quality of life and feeling of well-being. The use of portable mini-NPWT devices such as the KCI Mini-VAC[®] (Kinetic Concepts Inc, San Antonio, TX) was first described 10 years ago to enable patients to regain mobility and freedom at home by using NPWT to provide extra security for the adhesion of skin grafts (8). Bendewald *et al.* described the use of a portable device with a 300-ml canister to manage a series of young active patients with pilonidal disease (9). More recently, ultraportable NPWT devices have been described. The SNaP NPWT device (Spiracur Inc., Sunnyvale, CA) uses a spring-loaded piston to deliver a constant negative pressure to a disposable 60-ml canister for managing lower extremity wounds (10–12). Other single-use disposable devices are also available: Prevena[®] (13) and Via[®] (14) (KCI Inc.). As devices become smaller and more portable, manufacturers are challenged with ensuring that for equivalent wounds small devices can perform as well as their larger counterparts.

A novel ultraportable NPWT system (PICO[™], Smith & Nephew Medical Ltd, Hull, UK) was recently developed. The device is lightweight, single use and operates without an exudate canister, and is therefore ideally suited for delivery of NPWT to outpatients, patients at home and patients who do not want to have restricted mobility. The system works with a range of dressing sizes to enable the treatment of many wound types. Pre-clinical studies undertaken in an established porcine animal model confirmed the ability of this novel NPWT system to function in a manner consistent with the biological properties of NPWT, including fluid handling, pressure transmission to the wound bed,

tissue contraction and changes in blood flow expected from larger, durable NPWT devices (these findings are published elsewhere).

The emergent use of NPWT in closed incision management and its role in preventing postoperative complications in high-risk patients

The use of NPWT as a postoperative dressing for closed incisions in areas with high rates of wound complications is a relatively new concept, but with a growing body of evidence. Studies have demonstrated a number of benefits of applying NPWT on closed incisions including earlier cessation of wound drainage, reduction in seromas and haematomas and a reduction in dehiscence and infection rates in high-risk patients (7, 15–18). These issues are particularly important in the elderly and in patients with comorbidities such as obesity, hypertension, steroid use and history of smoking (19–21). The novel disposable NPWT system lends itself well to the treatment of closed incisions and traumatic wounds; however, with such a simplified format, it is absolutely critical to demonstrate that the technology can deliver NPWT effectively and provide a therapeutic benefit in clinically relevant settings. Therefore, the novel NPWT system was tested in a non-comparative clinical study to assess device functionality and clinical performance on a variety of acute wounds including higher risk closed surgical incisions. The devices were fitted with data log chips to enable longitudinal assessment of negative pressure levels and leak rates during therapy. To our knowledge, this is the first study that has reported real-time monitoring of therapy in applicable clinical settings including inpatient and outpatient care.

Materials and methods

Construction of the disposable canister-less NPWT system

The appearance of the new NPWT system is shown in Figure 1A. Exudate is managed predominantly by evaporation through the dressing (Figure 1B), thereby negating the need for a canister. The system delivers negative pressure at a single preset pressure of -80 mmHg. The device weighs only 70 g and is powered by two AA lithium batteries with a single button on-off control, leak detection and low-battery indicators. Dressings have a maximum wear time of up to 7 days and can be used either without fillers for shallow wounds or with conventional foam or gauze NPWT fillers for deeper cavities.

Clinical evaluation in patients

Subject recruitment and selection

A prospective, open, non-comparative, multicentre study was carried out to evaluate the functionality and dressing performance of the new NPWT system in acute and closed surgical wounds. The study protocol was reviewed and approved by the South African Medical Association Research Ethics Committee (SAMAREC) prior to study commencement and informed

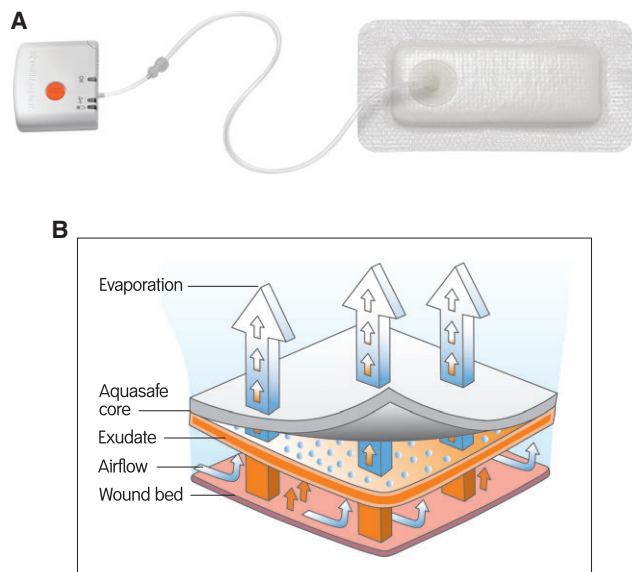


Figure 1 Simplified disposable negative pressure wound therapy (NPWT) system. (A) Pump and dressing: the ultraportable pump (PICO™, Smith & Nephew) is single use and disposable after 7 days of continual use, operates without a canister and is 85 × 85 × 25 mm in size. The device simplifies NPWT by replacing the exudate canister with a high evaporative loss dressing, which has a wear time of up to 7 days and can be replaced if necessary by detaching at the device. (B) Illustration of fluid flow through the layers of the dressing and evaporative fluid loss through the high moisture vapour transmission rate (MVTR) upper layer.

consent was obtained from all patients prior to their participation in the study. Patients were recruited from two centres in South Africa: A Plastics & Reconstructive unit (Library Square Claremont) and an Orthopaedic Reconstruction unit (Panorama Medic Clinic). Patients were enrolled into the study with the following wounds: incision wounds that were at high risk of developing a healing complication and would require a dressing to manage the exudate, trauma wounds with moderate to high levels of exudate and meshed STSGs. Exclusion criteria included wounds closed by surgical glue, wounds requiring daily inspection, active bleeding, exposed blood vessels or organs and untreated wound infection. In the environment of a closely monitored clinical trial, patients with potential comorbidities that might put them at risk of delayed wound healing were not excluded from the study so as to provide a robust test for the capabilities of the investigational device.

Objectives and assessment

The aim of this study was to demonstrate that the novel technology worked in applicable clinical settings. Study objectives were to assess overall functionality and performance of the disposable NPWT system including the ability of the system to manage exudate without a canister, concomitant delivery of NPWT and wound progression towards healing during the treatment phase. The prototype devices used in this study were built with a small flash chip to monitor device functionality. Data logs for each pump were downloaded following completion of the study and analysis was able to determine total device operating time, negative pressure levels, times

when the device was paused or turned off and volume of air leak experienced by each device during clinical use. Initial assessments included patient demographics, medical history and details of surgical procedure and wound assessment. Daily assessments of the device functionality were made such as any interventions required, maintenance of vacuum, air leaks, dressing seal and alarms. Wound assessments were made and photographs were taken at each dressing change over the 14-day treatment period including level of exudate, clinical signs of infection and condition of surrounding skin.

Wound treatment and protocol

Patients received treatment with the investigational product for up to 14 days. Daily visual assessments were carried out to evaluate the functional performance of the dressing and to determine if a dressing needed changing. Dressings were changed as and when required, with an expectant wear time of 3–5 days. Treatment was discontinued on day 14 or earlier if the wound was closed prior to this date or did not require a dressing to manage the exudate, returning thereafter to standard care as prescribed by the clinician. No topical antibiotics, other topical agents (e.g. medicated dressings) or absorbent dressing were applied to the reference wound in addition to the investigational product for the duration of the treatment period. The use of postoperative surgical drains continued as is normal practice within the respective centres ensuring that drainage tubes exited the skin outside of the area covered by the NPWT dressing.

Results

Patient demographics are summarised in Table 1. Twenty patients were treated with the disposable NPWT system. Sixteen (80%) patients had surgical wounds, two (10%) had traumatic wounds and two (10%) received meshed STSGs. Six (31.6%) patients had hip implants (one revision and five primary) and four (21.1%) had knee implants (one revision and three primary). Seven of the 20 patients (35%) were undergoing revision surgery of some kind including hip revisions, knee revisions and incisional hernia repairs. Mean patient age was 55.2 years (range: 27–79) with a mean body mass index (BMI) of 30.9 kg/m² (range: 21.8–44.3). Comorbidities included diabetes (35%), peripheral vascular disease (5%), rheumatoid arthritis (5%), osteoarthritis (45%), hypertension (35%) and a history of smoking (30%).

Figure 2 shows that 55% of wounds had closed by the end of the 14-day study or earlier, with a further 40% of wounds progressing to closure. Of the surgical incisions, 11 of 16 (69%) had closed by the end of the study (14 days); 4 were progressing to closure and 1 was static. The static surgical wound was due to removal of an infected hip implant with soft tissue infection at recruitment. There were no incidences of wound deterioration or dehiscence. Both the trauma patients were progressing to closure as were the two skin graft patients, where more than 80% graft take was achieved at the end of the study duration. There was no evidence of an increased risk of de novo infection during treatment with the disposable NPWT system. Seventeen wounds showed no infection or

Table 1 Patient demographics

Patient demographics	Mean
Patient	(n = 20)
Age (years)	55.2 (27–79)
Male	9 (45%)
Female	11 (55%)
BMI (kg/m ²)	30.9 (21.8–44.3)
Wound-related comorbidities	
Hypertension	7 (35%)
Diabetes	2 (10%)
Peripheral vascular disease	1 (5%)
Rheumatoid arthritis	1 (5%)
Osteoarthritis	9 (45%)
Smoking	6 (30%)
Wound type	
Surgical site	16 (80%)
Trauma	2 (10%)
Skin graft	2 (10%)
Wound dimensions	
Length (cm)	20.4 (5.2–41.8)
Width (cm)	1.5 (0.1–6.0)
Wound closure method	
Suture	7 (35%)
Suture + other	8 (40%)
Staples	3 (15%)
Other	2 (10%)
Wound location	
Chest/abdomen	6 (30%)
Hips/buttocks	6 (30%)
Upper leg (including knee)	5 (25%)
Lower leg	2 (10%)
Ankle/foot	1 (5%)

BMI, body mass index.

Wound progression at treatment discontinuation

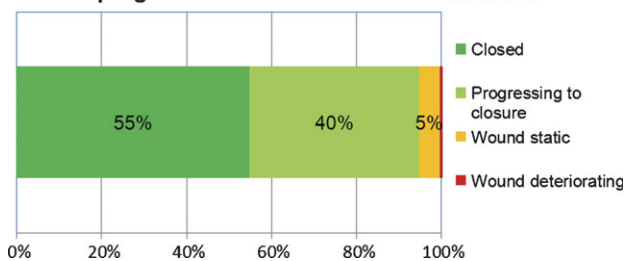


Figure 2 Reference wound progression at treatment discontinuation. Treatment was discontinued either at the end of the study period (14 days) or earlier if the wound was deemed closed. Mean treatment duration was 10.7 days.

clinical signs of infection at any point during the study. Two wounds were clinically infected and a further wound had clinical signs of infection at recruitment. Two of these wounds were successfully skin grafted during the treatment period.

The mean study duration was 10.7 days (range: 5–14 days). At treatment discontinuation, the majority of patients were discharged (15; 88.2%). The Kaplan–Meier estimate for the median time to discharge was 6 days (95% CI: 3–7). Mean dressing wear time per individual patient was 4.6 days (range:

2–11), ranging from 7.7 (range: 5–11) for patients with no exudate at baseline to 4.2 (range: 2.6–6) for light and 3.5 days (range: 2–5) for patients with moderate exudate at baseline. There was one device-related adverse event observed in this study, which was detailed as small blister-like lesions around the wound associated with the removal of adhesive film fixation strips. There was no evidence of skin maceration in any patient at any time. Likewise, there was no evidence of skin damage caused by the application of negative pressure to healthy skin through the perforated silicone adhesive lower wound contact layer. No tissue in-growth was observed at any dressing change assessment (54; 100%). There was no damage caused to the wound on dressing removal in 98% of dressing changes and only 2% incidence of slight damage. There was no damage to the surrounding skin on dressing removal in the majority (91%) of cases with 7% slight damage and 2% severe damage. Patients felt no pain in the majority of dressing applications (49; 92.5%) and dressing removals (48; 88.9%).

Case examples

Case 1

A 41-year-old woman post-mastectomy had been receiving treatment for breast cancer. Following radiotherapy, the patient underwent surgery for breast reconstruction and a tissue expander was inserted (Figure 3). The surgical wound was treated with disposable NPWT for 11 days with pump and battery changes as necessary. Following application of the NPWT system, the patient was allowed to go home with the NPWT system in place and was seen daily as an outpatient from day 2 as a participant in the study. No wound-related complications were observed. By day 11, the wound had no exudate and the incision was flat and closed, so the patient was discharged from the study. In the photograph, the site of an indwelling catheter removed at the same time is visible on the upper chest. This was not treated with NPWT and the incision scar is still raised. The data logger showed that a mean pressure of -77.6 mmHg was applied over the 11 days of therapy (Table 2). No significant air leaks were present in the dressings (0.01–0.14 ml/min), and therapy was delivered to the wound for 263.5 of a total of 264.5 hours of use (the device was paused on the second day for 1 hour by the patient).

Case 2

A 65-year-old woman with osteoarthritis, hypertension, type II diabetes and BMI of 34.28 kg/m² underwent surgery for a hip implant (Figure 4). Following surgery, the wound was closed with sutures and Steri-Strips™ (3M, St. Paul, MN). The disposable NPWT system was applied and the patient remained in hospital for 5 days before being discharged. The NPWT system was changed after 7 days. The wound was progressing well, with no exudate or infection, and a new dressing was placed over the wound in just 3 minutes. At the next routine dressing change on the ninth day, the wound was deemed to be closed and treatment with NPWT was discontinued. No significant air leaks were present in the dressings (0.02–0.04 ml/min). A mean pressure of

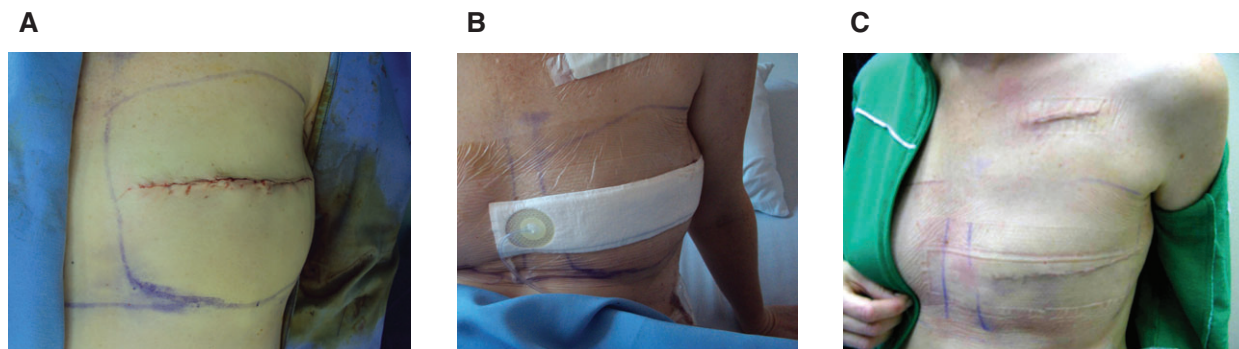


Figure 3 Case 1 – Post-surgical wound following breast reconstruction. A 41-year-old woman recently received radiotherapy following a mastectomy. The patient underwent surgery for breast reconstruction and tissue expander placement. (A) The wound measured 15 cm in length and 0.5 cm in width. Note that the closed incision is raised above the level of surrounding skin. (B) Patient with NPWT dressing system in place on first assessment (day 1). (C) Post-surgical wound after dressing removal, day 11. The surgical incision is closed, there is no exudate and the incision is flat. Note the tunnelled IV site wound that remains raised. The device was changed after 7 days.

Table 2 Device data logger statistics

	Dressing air leak range (ml/min)	Mean pressure (mmHg)	Total therapy time (hours)	Total hours outside of therapy limits	% of time pressure within set limits
Case 1	0.01–0.14	77.56	264.5	1	99.99
Case 2	0.02–0.04	78.3	193.1	2	99.99
Case 3	3.15–3.51	76.58	193.4	0	100

The prototype devices used in this study were built with a small flash chip to monitor device functionality. Data logs for each pump were downloaded following completion of the study. Therapy was deemed outside limits if pressure recordings dropped below -60 mmHg.

-78.3 mmHg was maintained over the 8 days of therapy (Table 2). Only during 2 of a total of 193 hours of therapy, pressure fell below the acceptable level (-60 mmHg). The data logger showed that the first device was used beyond the recommended 7 days, for a further 8 hours. The pump is programmed to stop working after 7 days, yet the pressure dropped slowly over the 8-hour period (presumably because of good dressing seals) and only fell below -60 mmHg in the final 2 hours before the next dressing change was due. Despite therapy being turned off, the dressing remained in place and continued to manage the exudate effectively.

Case 3

A 48-year-old woman was treated with disposable NPWT after knee implant surgery (Figure 5). The patient had previously undergone two procedures to the knee, so she was at a higher risk of downstream wound-related complications. The dressing was easy to apply and treatment continued without complication until the routine dressing change on day 6, when the wound was seen to be progressing well. Exudate levels were minimal. On day 10, the dressing was removed, the wound was found to be closed and no further treatment was needed. The calculated leak rate was higher in this case (3.15–3.51 ml/min), which likely reflects the location of the wound and the challenges faced in obtaining sufficient closure around the knee. Nevertheless, continuous levels of therapeutic negative pressure were delivered to the wound (mean pressure: -76.6 mmHg) and the wound made very good progress.

Discussion

Performance of the simplified single-use NPWT system

Twenty patients, some with higher risks for wound-healing complications, were treated with a new simplified disposable NPWT system. Experimental studies have confirmed the ability of this NPWT system to deliver identical functions to multiuse NPWT devices with respect to fluid handling, pressure transmission to the wound bed, tissue contraction and changes in blood flow (to be communicated elsewhere). Incorporating data loggers into the present clinical study enabled a real-time evaluation of how devices truly perform in applicable clinical settings. Therapeutic levels of negative pressure were maintained continuously in the majority of treated wounds, despite the presence of small air leaks that occur in clinical practice. Dressing application technique, wound location and even patient mobility can significantly affect the integrity of the seal on NPWT dressing systems. For larger devices, such air leaks can be easily managed. However, as pumps become smaller and a balance is struck between portability and power, the importance of good dressing design and application in order to minimise air leaks is paramount.

The means by which the new disposable NPWT system manages exudate is fundamentally different from traditional NPWT systems. Studies have shown that around 80% of fluid is evaporated through the dressing and high MVTR upper layer. Dressing integrity was maintained throughout the use with 100% of dressings deemed to remain in place over 212 assessments. The mean dressing wear time per individual patient was 4.6 days, ranging from 3.5 to 7.7 days, depending

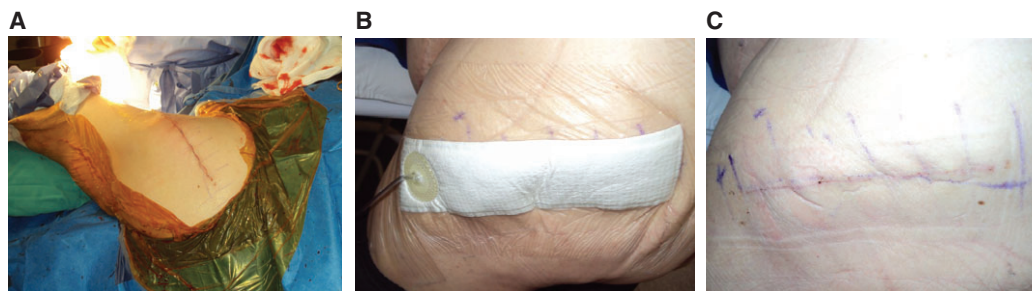

Figure 4 Case 2 – Post-surgical wound following a hip replacement procedure. A 65-year-old woman with hypertension, diabetes, high body mass index (BMI) and osteoarthritis who underwent surgery for a hip replacement. (A) Hip implant wound immediately after surgery was closed with sutures and Steri-Strips™. (B) Negative pressure wound therapy (NPWT) system in place over the hip on day 1. (C) Wound progressing to closure on day 7 before being discontinued on the ninth day. The device was changed after 7 days.

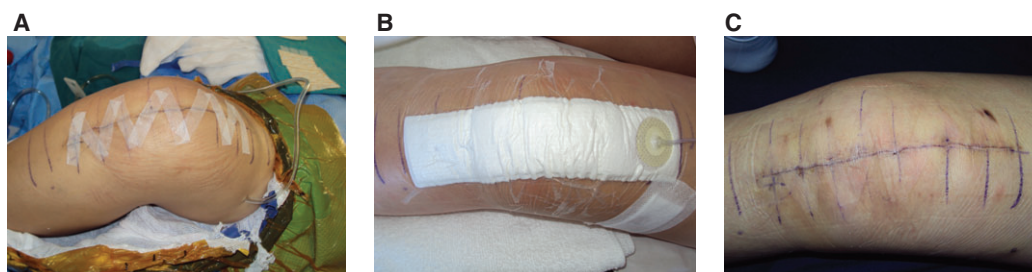

Figure 5 Case 3 – Post-surgical wound following revision knee surgery. A 48-year-old woman had undergone two previous procedures to the knee. (A) Wound immediately post-surgery was closed with sutures and Steri-Strips™ prior to application of disposable negative pressure wound therapy (NPWT) system. (B) NPWT dressing system in place at day 3. (C) Surgical wound at dressing change on day 10. The wound was deemed to be closed and therapy discontinued at day 10. The device was changed after 6 days.

on the exudate levels. The NPWT dressing was well tolerated by patients with respect to pain and trauma upon removal. The low adherence properties of the silicone adhesive layer in contact with the wound observed under NPWT in this study are in keeping with the performance of a silicone adhesive hydrocellular foam dressing that displayed no reported pain on removal at 93% (542 of 583) of dressing removals and also no trauma to the wound or surrounding skin reported at 98% (574 of 583) of dressing removals amongst a study of 153 patients (22).

Clinical benefits

Overall, 95% of these wounds had either closed or were progressing to closure at the end of the 14-day study. There were no incidences of wound deterioration or dehiscence, or any evidence of an increased risk of de novo infection during treatment with disposable NPWT. This pattern is entirely consistent with previous studies on closed incisions treated with NPWT (16,18). It is thought that one of the primary mechanisms of action of NPWT on post-surgical wounds is the reduction of soft tissue oedema and swelling, which leads to improved tissue perfusion and removal of inflammatory mediators (23–26). It has also been suggested that the NPWT-related biomechanical forces applied to incisions play a key role in improving outcomes. Traditional closure methods such as sutures and staples create concentrated points of tensions along the wound, which are thought to result in ischaemia or

even necrosis of wound tissue. This is particularly relevant in obese patients, oedematous tissue or incisions over joints where greater stress is placed on the tissue as a result of movement. Wilkes *et al.* propose that NPWT over incisions normalises the distribution of tension around an incision to enhance apposition of the incisional tissue, effectively providing a bolstering effect (27). Others have demonstrated in pigs that the mechanical strength of the closed incision is greater after NPWT is discontinued (28). Whilst the use of incisional NPWT may not be necessary for all surgical patients, certain patients with a number of known risk factors may be suitable candidates for a therapeutic system that enhances the healing of surgically closed incisional wounds and prevents potential postoperative wound complications. Single-use, lower cost devices are likely to be important in expanding NPWT for use as a widespread preventative therapy.

This study has a number of limitations because of its small sample size and being non-comparative in nature. Randomised prospective clinical trials comparing simple occlusive dressings or traditional NPWT devices with the simplified NPWT system would be recommended to provide more robust conclusions regarding improvements in clinical outcomes. Nevertheless, as a first step, it is important to validate that simplified NPWT technology can perform safely and effectively in a clinical setting. Further comparative studies will be required to demonstrate statistically that simplified NPWT devices facilitate earlier discharge from acute care and

lead to a reduction in wound-healing complications in closed incisional wounds.

Acknowledgements

This work was funded by Smith & Nephew Ltd. EH and RM are employees of Smith & Nephew. The authors would like to thank Ben Askem (Smith & Nephew Hull) for providing data analysis and evaluation of the device data loggers and 3 Degree Clinical Research Organisation in South Africa for clinical trial monitoring services.

References

1. Armstrong DG, Lavery LA. Negative pressure wound therapy after partial diabetic foot amputation: a multicentre, randomised controlled trial. *Lancet* 2005;**366**:1704–10.
2. Wanner MB, Schwarzl F, Strub B, Zaech GA, Pierer G. Vacuum-assisted wound closure for cheaper and more comfortable healing of pressure sores: a prospective study. *Scand J Plast Reconstr Surg Hand Surg* 2003;**37**:28–33.
3. Vuerstaek JDD, Vainas T, Wuite J, Nelemans P, Neumann MH, Veraart JC. State-of-the-art treatment of chronic leg ulcers: a randomized controlled trial comparing vacuum-assisted closure (V.A.C.) with modern wound dressings. *J Vasc Surg* 2006;**44**:1029–37, discussion 1038.
4. Llanos S, Danilla S, Barraza C, Armijo E, Piñeros JL, Quintas M, Searle S, Calderon W. Effectiveness of negative pressure closure in the integration of split thickness skin grafts: a randomized, double-masked, controlled trial. *Ann Surg* 2006;**244**:700–5.
5. Kamolz L-P, Andel H, Haslik W, Winter W, Meissl G, Frey M. Use of subatmospheric pressure therapy to prevent burn wound progression in human: first experiences. *Burns* 2004;**30**:253–8.
6. Stannard JP, Volgas DA, Stewart R, McGwin G, Alonso JE. Negative pressure wound therapy after severe open fractures: a prospective randomized study. *J Orthop Trauma* 2009;**23**:552–7.
7. Stannard JP, Volgas DA, McGwin G 3rd, Stewart RL, Obrebsky W, Moore T, Anglen JO. Incisional negative pressure wound therapy after high-risk lower extremity fractures. *J Orthop Trauma* 2012;**26**:37–42.
8. Sposato G, Molea G, Di Caprio G, Scioli M, La Rusca I, Ziccardi P. Ambulant vacuum-assisted closure of skin-graft dressing in the lower limbs using a portable mini-VAC device. *Br J Plast Surg* 2001;**54**:235–7.
9. Bendewald FP, Cima RR, Metcalf DR, Hassan I. Using negative pressure wound therapy following surgery for complex pilonidal disease: a case series. *Ostomy Wound Manage* 2007;**53**:40–6.
10. Landsman A. Analysis of the SNaP Wound Care System, a negative pressure wound device for treatment of diabetic lower extremity wounds. *J Diabetes Sci Technol* 2010;**4**:831–2.
11. Lerman B, Oldenbrook L, Ryu J, Fong KD, Schubart PJ. The SNaP Wound Care System: a case series using a novel ultraportable negative pressure wound therapy device for the treatment of diabetic lower extremity wounds. *J Diabetes Sci Technol* 2010;**4**:825–30.
12. Fong KD, Hu D, Eichstadt S, Gupta DM, Pinto M, Gurtner GC, Longaker MT, Lorenz HP. The SNaP system: biomechanical and animal model testing of a novel ultraportable negative-pressure wound therapy system. *Plast Reconstr Surg* 2010;**125**:1362–71.
13. Colli A, Camara M-L. First experience with a new negative pressure incision management system on surgical incisions after cardiac surgery in high risk patients. *J Cardiothorac Surg* 2011;**6**:160.
14. Khanbhai M, Fosah R, Oddy MJ, Richards T. Disposable NPWT device to facilitate early patient discharge following complex DFU. *J Wound Care* 2012;**21**:180–182.
15. Stannard JP, Robinson JT, Anderson ER, McGwin G Jr, Volgas DA, Alonso JE. Negative pressure wound therapy to treat hematomas and surgical incisions following high-energy trauma. *J Trauma* 2006;**60**:1301–6.
16. Atkins BZ, Wooten MK, Kistler J, Hurley K, Hughes GC, Wolfe WG. Does negative pressure wound therapy have a role in preventing poststernotomy wound complications? *Surg Innov* 2009;**16**:140–6.
17. Reddix RN, Tyler HK, Kulp B, Webb LX. Incisional vacuum-assisted wound closure in morbidly obese patients undergoing acetabular fracture surgery. *Am J Orthop* 2009;**38**:446–9.
18. Gomoll AH, Lin A, Harris MB. Incisional vacuum-assisted closure therapy. *J Orthop Trauma* 2006;**20**:705–9.
19. Riou JP, Cohen JR, Johnson H. Factors influencing wound dehiscence. *Am J Surg* 1992;**163**:324–30.
20. Wilson JA, Clark JJ. Obesity: impediment to postsurgical wound healing. *Adv Skin Wound Care* 2004;**17**:426–35.
21. Abbas SM, Hill AG. Smoking is a major risk factor for wound dehiscence after midline abdominal incision; case-control study. *ANZ J Surg* 2009;**79**:247–50.
22. Hurd T, Gregory L, Jones A, Brown S. A multi-centre in-market evaluation of ALLEVYN Gentle Border. *Wounds UK* 2009;**5**:32–44.
23. Webb LX, Dedmond B, Schlatterer D, Laverty D. The contaminated high-energy open fracture: a protocol to prevent and treat inflammatory mediator storm-induced soft-tissue compartment syndrome (IMSICS). *J Am Acad Orthop Surg* 2006;**14**:S82–6.
24. Webb LX. Perspectives on modern orthopaedics new techniques in wound management: vacuum-assisted wound closure. *J Am Acad Orthop Surg* 2002;**10**:303–11.
25. Young SR, Hampton S, Martin R. Non invasive assessment of negative pressure wound therapy using high frequency diagnostic ultrasound: oedema reduction and new tissue accumulation. *Int Wound J* 2012. DOI: 10.1111/j.1742-481X.2012.00994.x [Epub ahead of print].
26. Kilpadi DV, Cunningham MR. Evaluation of closed incision management with negative pressure wound therapy (CIM): hematoma/seroma and involvement of the lymphatic system. *Wound Repair Regen* 2011;**19**:588–96.
27. Wilkes RP, Kilpad DV, Zhao Y, Kazala R, McNulty A. Closed incision management with negative pressure wound therapy (CIM): biomechanics. *Surg Innov* 2012;**19**:67–75.
28. Meeker J, Weinhold P, Dahners L. Negative pressure therapy on primarily closed wounds improves wound healing parameters at 3 days in a porcine model. *J Orthop Trauma* 2011;**25**:756–61.