

# Granulocytic sarcoma presenting as monoparesis: A rare case report

Ashok Gupta, Amit Chanduka, I. Vijay Sundar, Verma Jitender, Sanjeev Chopra

Department of Neurosurgery, SMS Medical College, Jaipur, Rajasthan, India

## ABSTRACT

Granulocytic sarcomas (GSs) or myeloid sarcoma or chloroma are rare, destructive, extramedullary tumor masses that consist of immature granulocytic cells. We present case of a 35-year-old man presenting as monoparesis, diagnosed to have cervical intradural extramedullary mass lesion with an extradural extension. Although the history or physical examination had no symptoms and signs suggestive of leukemia, bone marrow study and blood picture indicated chronic myeloid leukemia. Surgical decompression was done, and histopathological examination was consistent with GS. GSs have been observed in patients with acute myelogenous leukemia, chronic myelogenous leukemia, and other myeloproliferative disorders, but rarely have been reported as first presentation of the disease.

**Key words:** Acute myeloid leukemia, chronic myeloid leukemia, epidural mass, granulocytic sarcoma

## Introduction

GSs are a part of the spectrum of myeloproliferative disorders which usually occur in a patient with leukemia. GS occurring primarily in the epidural location is very rare with only fifteen reported cases. We present a case of GS where the patient presented with a focal neurological defect but was found to have a systemic disease on evaluation.

## Case Report

A 35-year-old male was admitted with 1.5 months history of numbness and tingling, followed by pain radiating from nape of the neck to the inner side of right forearm and hand with progressive weakness of right upper limb (UL). He had no associated complaints or history of trauma. On examination, patient had right -UL monoparesis with power 3/5 from C6 to T1. Bulk was normal, and tone was increased in right UL. Pain, touch and temperature modalities were diminished in C6-T1 dermatomes. Posterior column sensations were intact. All the other limbs were normal in examination except an

incidental postpolio paralysis in right lower limb. Bladder bowel was not involved. Magnetic resonance imaging of the cervical spine revealed large intradural extramedullary mass at C5-C7 level with an extradural component with extension into right paraspinous and paravertebral region through C8-T1 intervertebral foramen [Figure 1]. Heterogeneous uptake with gadolinium contrast was noted [Figure 2]. Routine investigation revealed total leukocyte counts > 1 lakh/cumm. Patient was evaluated for a suspected leukemia. Peripheral smear revealed increased number of mature and immature cells of the myeloid series. Bone marrow aspirate was hyper cellular with myeloid hyperplasia and shift to left suggestive of chronic myeloid leukemia. Computed tomography abdomen revealed hepatosplenomegaly [Figure 3]. Patient was offered surgery because of rapidly developing neurologic deficits. C5-T1 laminectomy with decompression of extradural and intradural extramedullary lesion with debulking of the paraspinal extension was done. However, patient's neurological status deteriorated postoperatively. Respiration was inadequate, and patient was taken on ventilator support. Patient died on postoperative day 4 because of respiratory failure. Biopsy of the lesion confirmed it to be a granulocytic sarcoma (GS).

## Discussion

Granulocytic sarcoma is generally observed as a complication of myelogenous leukemia, myelodysplastic syndromes, or myeloproliferative disorders. Diagnosis of GS poses a diagnostic dilemma particularly in the absence of clinical features of underlying disorder.<sup>[1,2,3]</sup> GSs are often the initial presenting feature even when both are present at diagnosis.<sup>[1,3,4]</sup> However they may occur alone without peripheral blood or bone marrow evidence of leukemia,<sup>[5]</sup> with subsequent development

### Access this article online

#### Quick Response Code:



#### Website:

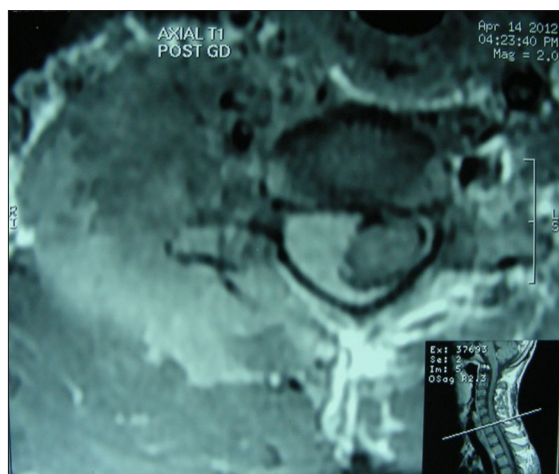
www.asianjns.org

#### DOI:

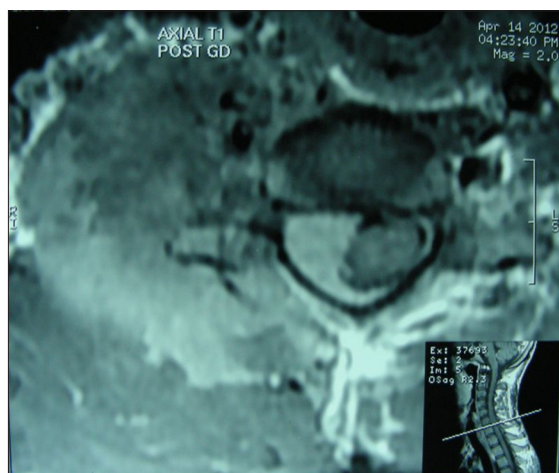
10.4103/1793-5482.146641

### Address for correspondence:

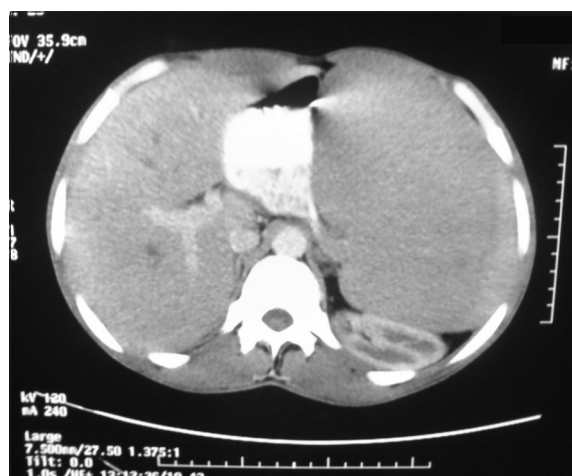Dr. Ashok Gupta, B-46, Jai Jawan 1<sup>st</sup>, JLN Marg, Jaipur, Rajasthan, India. E-mail: drashokjp@yahoo.com



**Figure 1:** Contrast enhanced axial magnetic resonance imaging showing extramedullary tumor extending to paraspinous region



**Figure 2:** Magnetic resonance imaging cervical spine showing large intradural extramedullary mass with extradural component and extension into right paraspinous and paravertebral region



**Figure 3:** Computed tomography abdomen showing hepatosplenomegaly

of leukemia or as a site of leukemia relapse.<sup>[6]</sup> The incidence of GSs is rising due to early diagnosis, better chemotherapeutic

and radio therapeutic facilities resulting in a longer survival of leukemia patients.<sup>[1-3]</sup> Only 15 patients with primary epidural GS of the spine in the literature have been reported.<sup>[1-5,7-10]</sup>

Granulocytic sarcomas usually occur in the bone, skin, and lymph nodes. Bony involvement is most common in the orbit, sacrum, spine, and ribs.<sup>[1,4,5]</sup> The origin of the tumor is thought to be a bone marrow, with migration to extra osseous locations achieved via the haversian canals.<sup>[3]</sup> All levels of the spine may be affected by myeloid sarcoma. The thoracic spine was most commonly involved (73%) followed by the lumbar (34%), sacral (23%), and cervical (5%) regions. The most common misdiagnoses included large cell lymphoma, malignant lymphoma, reticulum cell lymphoma, and histiocytic lymphoma neuroblastoma, Ewing's sarcoma, rhabdomyosarcoma, and osteosarcoma.<sup>[1,3,5,11]</sup> A diagnosis of GS is cannot be ruled out when bone marrow biopsy specimens show no evidence of leukemia infiltration.

Granulocytic sarcoma should be considered in the differential diagnosis of an epidural mass in patients with or without acute leukemia, because early diagnosis followed by appropriate combined chemotherapy and radiation may obviate surgical intervention and eventually prevent leukemic transformation.<sup>[1,4,9-11]</sup> Combined chemotherapy and radiation therapy is the first choice in the treatment of isolated myeloid sarcoma. Treatment options include surgical decompression, chemotherapy, radiation therapy or any combination of these treatment methods.<sup>[3,4,5,11]</sup> Surgery is generally preferred for cases of acute spinal cord compression. Surgical excision is not indicated except in the presence of progressive neurological deficits which are uncontrollable by the conservative treatment. Surgery could increase the risk of infection and central nervous system dissemination. However, it has been documented that surgery of early-stage tumor may lead to a long symptom-free period, and good response to external radiation-even though surgical excision and/or irradiation may only achieve local control, with no influence on survival.

### Conclusion

Granulocytic sarcoma causing spinal cord compression is infrequent in itself. More significantly it should be kept in mind that GS might be a presentation of a more systemic and dangerous disease such as myeloid leukemia. Complete work up will usually diagnose the underlying disease. Primary treatment of GS is combined chemoradiotherapy. Surgical intervention although indicated in progressive neurological deterioration does not prolong survival.

### References

1. Buckland ME, Scolyer RA, Donellan MB, Brew S, McGee-Collett M, Harper CG. Spinal chloroma presenting with triplegia in an aleukaemic patient. *Pathology* 2001;33:386-9.

2. Ripp DJ, Davis JW, Rengachary SS, Lotuaco LG, Watanabe IS. Granulocytic sarcoma presenting as an epidural mass with cord compression. *Neurosurgery* 1989;24:125-8.
3. Suzer T, Colakoglu N, Cirak B, Keskin A, Coskun E, Tahta K. Intracerebellar granulocytic sarcoma complicating acute myelogenous leukemia: A case report and review of the literature. *J Clin Neurosci* 2004;11:914-7.
4. Yamamoto K, Hamaguchi H, Nagata K, Hara M, Tone O, Tomita H, *et al.* Isolated recurrence of granulocytic sarcoma of the brain: Successful treatment with surgical resection, intrathecal injection, irradiation and prophylactic systemic chemotherapy. *Jpn J Clin Oncol* 1999;29:214-8.ss
5. Ugras S, Cirak B, Karakok M, Guven B. Spinal epidural granulocytic sarcoma (chloroma) in a non-leukemic child. *Pediatr Int* 2001;43:505-7.
6. Cho WH, Choi YJ, Choi BK, Cha SH. Isolated recurrence of intracranial granulocytic sarcoma mimicking a falx meningioma in acute myeloblastic leukemia. *J Korean Neurosurg Soc* 2010;47:385-8.
7. Deme S, Deodhare SS, Tucker WS, Bilbao JM. Granulocytic sarcoma of the spine in nonleukemic patients: Report of three cases. *Neurosurgery* 1997;40:1283-7.
8. Kook H, Hwang TJ, Choe K, Yang DW, Nam JH, Park CS. Spinal epidural granulocytic sarcoma preceding acute myelogenous leukemia. *J Korean Med Sci* 1992;7:291-6.
9. Kwatra KS, Prabhakar BR, Arora Y. Bilateral granulocytic sarcoma (chloroma) of the breast in CML in blast crisis: A case report. *Indian J Pathol Microbiol* 2004;47:66-8.
10. Mostafavi H, Lennarson PJ, Traynelis VC. Granulocytic sarcoma of the spine. *Neurosurgery* 2000;46:78-83.
11. Frohna BJ, Quint DJ. Granulocytic sarcoma (chloroma) causing spinal cord compression. *Neuroradiology* 1993;35:509-11.

**How to cite this article:** Gupta A, Chanduka A, Sundar IV, Jitender V, Chopra S. Granulocytic sarcoma presenting as presenting as monoparesis: A rare case report. *Asian J Neurosurg* 2014;9:241.

**Source of Support:** Nil, **Conflict of Interest:** None declared.